

The outcome of endoscopic management of bile leakage after hepatobiliary surgery

Seon Ung Yun, Young Koog Cheon, Chan Sup Shim, Tae Yoon Lee, Hyung Min Yu, Hyun Ah Chung, Se Woong Kwon, Taek Gun Jeong, Sang Hee An, Gyung Won Jeong, and Ji Wan Kim

Department of Internal Medicine,
Konkuk University School of
Medicine, Seoul, Korea

Received: June 10, 2015
Revised : February 19, 2016
Accepted: May 12, 2016

Correspondence to

Young Koog Cheon, M.D.

Department of Internal Medicine,
Konkuk University School of
Medicine, 120-1 Neungdong-ro,
Gwangjin-gu, Seoul 05030, Korea
Tel: +82-2-2030-7490
Fax: +82-2-2030-7748
E-mail: ykskyo01@hanmail.net

Background/Aims: Despite improvements in surgical techniques and postoperative patient care, bile leakage can occur after hepatobiliary surgery and may lead to serious complications. The aim of this retrospective study was to evaluate the efficacy of endoscopic treatment of bile leakage after hepatobiliary surgery.

Methods: The medical records of 20 patients who underwent endoscopic retrograde cholangiopancreatography because of bile leakage after hepatobiliary surgery from August 2009 to September 2014 were reviewed retrospectively. Endoscopic treatment included insertion of an endoscopic retrograde biliary drainage stent after endoscopic sphincterotomy.

Results: Most cases of bile leakage presented as percutaneous bile drainage through a Jackson-Pratt bag (75%), followed by abdominal pain (20%). The sites of bile leaks were the cystic duct stump in 10 patients, intrahepatic ducts in five, liver beds in three, common hepatic duct in one, and common bile duct in one. Of the three cases of bile leakage combined with bile duct stricture, one patient had severe bile duct obstruction, and the others had mild strictures. Five cases of bile leakage also exhibited common bile duct stones. Concerning endoscopic modalities, endoscopic therapy for bile leakage was successful in 19 patients (95%). One patient experienced endoscopic failure because of an operation-induced bile duct deformity. One patient developed guidewire-induced microperforation during cannulation, which recovered with conservative treatment. One patient developed recurrent bile leakage, which required additional biliary stenting with sphincterotomy.

Conclusions: The endoscopic approach should be considered a first-line modality for the diagnosis and treatment of bile leakage after hepatobiliary surgery.

Keywords: Bile leakage; Hepatobiliary surgery; Stents; Sphincterotomy, endoscopic

INTRODUCTION

Despite the steady improvements in surgical techniques and postoperative patient care over the past decade, postoperative bile leakage remains a complication of various hepatobiliary surgeries. The incidence of bile leakage after laparoscopic cholecystectomy was reported

to be 1.1% to 4.0% [1-5]. In addition, bile leakage occurs following ~15% of liver resections [6-12]. The frequency of hepatobiliary surgery for neoplastic diseases has increased due to early screening; this has resulted in an increase in the number of cases of bile leakage after surgery. Therapeutic options for bile leakage include percutaneous drainage (PCD) of fluid collection (such

as bilomas), therapeutic biliary endoscopy, and surgery. Recently, biliary endoscopic procedures including biliary stenting and/or endoscopic sphincterotomy (EST) have become the first choice for diagnosis and treatment of postoperative bile leakage. The primary aim of this study was to evaluate the efficacy of endoscopic treatment of bile leakage after hepatobiliary surgery.

METHODS

A retrospective review of 20 patients referred for post-hepatobiliary surgery bile leakage from August 2009 to September 2014 was performed. The biliary tract and leakage site in each patient were visualized during endoscopic retrograde cholangiopancreatography (ERCP). The medical records, endoscopic, and radiologic findings were reviewed retrospectively. Three experienced pancreatobiliary endoscopists performed all ERCP procedures. ERCP was performed using a side-viewing duodenoscope (TJF-240, Olympus Optical Co., Tokyo, Japan). Wire-guided cannulation of the biliary tract was performed, and cholangiograms were obtained. Endoscopic therapy in all patients consisted of EST to reduce intraductal pressure and facilitate transpapillary bile flow. A plastic stent with a diameter of 7 or 10 Fr was inserted, as determined by the endoscopist. Patients were discharged after resolution of leakage-related clinical symptoms, and follow-up ERCP was performed at 4 weeks for cases of postcholecystectomy bile leakage and at 4 to 8 weeks for cases of major hepatectomy to confirm complete healing of the leak and to remove the biliary stent. Success of ERCP was determined primarily as a decrease in percutaneous bile drainage volume through a Jackson-Pratt bag. Success was confirmed when extravasation of contrast medium was not seen on follow-up ERCP. If bile leakage was detected at follow-up cholangiography, stent patency was maintained for up to 8 weeks.

The study protocol was approved by the Institutional Review Board of Konkuk University Medical Center, which confirmed that the study was in accordance with the ethical guidelines of the Helsinki Declaration.

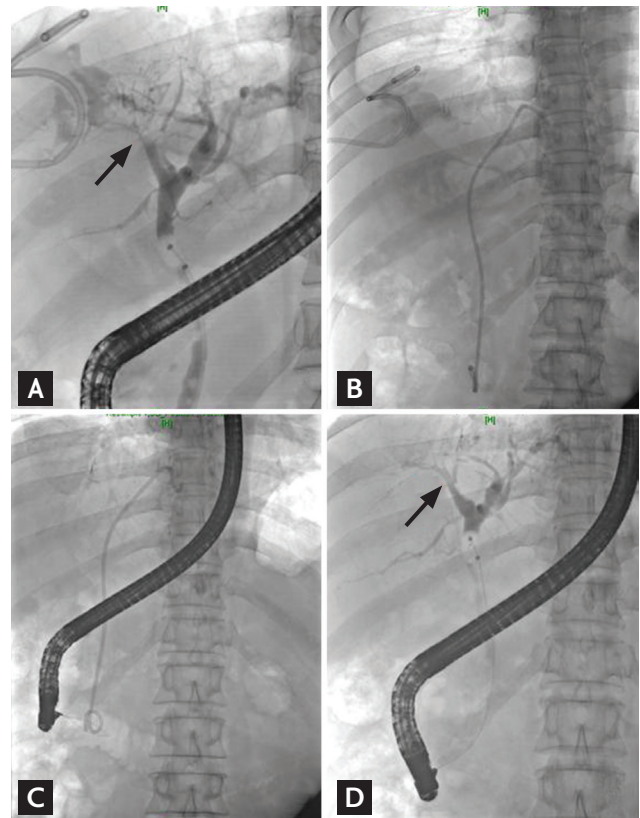


Figure 1. Representative patient: bile leak after S4 segmentectomy, endoscopic retrograde cholangiopancreatography (ERCP), and follow-up cholangiogram of a left medial segment branch bile leak. (A) Bile leak in the left medial segment branch (arrow), (B) plastic stent insertion, (C) follow-up ERCP for stent removal, and (D) resolution of previous bile leak at 10 weeks postprocedure (arrow).

RESULTS

A total of 20 patients (18 males, two females; mean age, 51.4 ± 14.1 years) with postoperative bile leakage were referred for endoscopic management (Table 1). The surgical department of our hospital referred 16 patients; the remaining four patients were transferred to other institutions for treatment.

Thirteen patients had undergone laparoscopic cholecystectomy (65%) because of cholecystitis, two patients were living-donor recipients and had undergone lobectomy (10%) because of liver transplantation, three had undergone segmentectomy (15%) because of hepatocellular carcinoma, one had undergone segmentectomy (5%) because of rectosigmoid carcinoma with liver metastasis,

Table 1. Baseline characteristics of the 20 cases

Characteristic	Value
Age, yr	51.4 ± 14.1
Sex, male/female	18/2 (90/10)
Cause of operation	
Acute cholecystitis	13 (65)
Hepatocellular carcinoma	5 (25)
Rectosigmoid carcinoma with liver metastasis	2 (10)
Types of surgery	
Laparoscopic cholecystectomy	13 (65)
Segmentectomy	4 (20)
Lobectomy	2 (10)
Partial resection	1 (5)
Mode of presentation	
Bile drainage through a Jackson-Pratt bag	15 (75)
Abdominal pain	4 (20)
Fever	1 (5)
Site of bile duct injury	
Cystic duct stump	10 (50)
Right/left intrahepatic ducts	3/2 (25)
Liver bed	3 (15)
Common hepatic duct	1 (5)
Common bile duct	1 (5)
Types of injury	
Leak only	12 (60)
Leak combined with ductal stricture	3 (15)
Leak combined with common bile duct stone	5 (25)
Interval period, day	
From surgery to diagnosis of the bile leak	9.0 ± 6.4
Operation to ERCP	12.4 ± 8.5
ERCP to stent removal	77.6 ± 21.7

Values are presented as mean ± SD or number (%).

ERCP, endoscopic retrograde cholangiopancreatography.

and one had undergone partial resection (5%) because of rectosigmoid carcinoma with liver metastasis (Fig. 1).

The mean time from surgery to diagnosis of bile leakage was 9.0 ± 6.4 days (range, 1 to 22). Most bile leakages presented as percutaneous bile drainage through a Jackson-Pratt bag (75%), followed by abdominal pain (20%) and fever (5%). The mean interval from hepatobiliary surgery to referral for ERCP was 12.4 ± 8.5 days (range, 2 to 31). The mean interval was longer than that reported in a previous study [13-15]. The four patients referred for treatment from other institutions had longer intervals

than those of the other patients.

The mean interval from endoscopic retrograde biliary drainage (ERBD) to stent removal was 77.6 ± 21.7 days. The stent was not removed in three patients. Two of these three patients were lost to follow-up and the other patient died because of cancer aggravation. Bile drainage through a Jackson-Pratt bag was stopped at a mean interval of 5 days (range, 3 to 12), and percutaneous catheters were able to be removed at a mean interval of 6 days (range, 5 to 16) after endoscopic procedures.

The sites of bile leaks were the cystic duct stump in 10 patients (50%), right/left intrahepatic ducts in five (25%; right, three; left, two), liver beds in three (15%; duct of Luschka, two; cystic duct orifice, one), common hepatic duct in one (5%), and common bile duct (CBD) in one (5%). Of the 20 patients with postoperative bile leakage, three cases were combined with bile duct stricture (15%); one patient had severe CBD obstruction, and the others had mild stricture. Bile leakage occurred together with CBD stones in five cases. After EST and controlled radial expansion wire-guided papillary balloon dilatation, stone removal was performed using an extraction basket. A plastic stent was then placed at the site of bile leakage.

Concerning endoscopic modalities, endoscopic therapy for bile leak was successful in 19 patients (95%). One patient developed microperforation during cannulation, which was mild, and recovered without clinical sequelae. In one case, the amount of percutaneous bile drainage through a Jackson-Pratt bag increased 3 days after the endoscopic procedure. Additional biliary stenting with sphincterotomy was performed, which stopped the bile leakage.

One patient was diagnosed with hepatocellular carcinoma and underwent a right anterior sectionectomy. After the operation, bile leakage from the right inferior intrahepatic duct was detected. An endoscopic approach failed because a guidewire could not be passed from the CBD to the right inferior intrahepatic duct. A percutaneous transhepatic approach also failed because the guidewire could not be inserted across the bile leakage site. Radiologic-guided percutaneous transhepatic biliary drainage (PTBD) was performed at the right inferior intrahepatic duct, which reduced the amount of percutaneous bile drainage. However, after PTBD clamping, the amount of PCD increased, and the PTBD catheter

Table 2. Complications and failures

Parameter	No. (%)
ERBD-related complication	
Microperforation during cannulation	1 (5)
Failure	
Failure of guide-wire insertion at the bile leak site	1 (5)

ERBD, endoscopic retrograde biliary drainage.

could not be removed. The PCD catheter was removed 2 weeks later. In this case, reoperation was judged in the previous hospital to be difficult, with which our surgeon agreed. Therefore, this patient was discharged with PTBD and transferred to another hospital. At the other hospital, the stricture was resolved by positioning the magnet at the stricture site via PTBD and ERCP (Table 2).

DISCUSSION

Postoperative bile leakage is a severe clinical problem that may cause significant morbidity and mortality. Despite improvements in hepatobiliary surgical techniques and postoperative patient care, the incidence of postoperative bile leakage has not decreased significantly [8].

When bile leakage is suspected during the postoperative period, visualization of the biliary tract by ERCP is required to confirm the diagnosis, to locate the exact site of the defect, and to rule out the presence of retained biliary stones.

Bile leakage is more frequent after laparoscopic cholecystectomy than after open cholecystectomy, and the most frequent site of bile leakage is the cystic duct stump [1,3]. Studies of endoscopic treatment for bile leaks of the cystic stump after laparoscopic cholecystectomy have reported promising results. Indeed, in our study endoscopic therapy for bile leaks after laparoscopic cholecystectomy yielded a 100% success rate.

Endoscopic treatment for bile leakage after liver resection shows a lower success rate (75%) than that for bile leakage after laparoscopic cholecystectomy (70% to 100%) [14,16]. In the failed case in our study, peripheral bile leakage occurred because of disconnection between the right posterior intrahepatic duct and common hepatic duct during segmentectomy. In this case, both an

endoscopic and percutaneous approach failed. Donatelli et al. [17] proposed the rendezvous technique (passage of a guidewire through the distal CBD and into the subhepatic space by ERCP, and simultaneous snaring via a percutaneous transhepatic cholangioscopy approach allowed for a biliary-duodenal catheter to be placed and the continuity of the biliary tree to be maintained) for this difficult case.

Available endoscopic procedures for bile leakage include EST, endoscopic nasobiliary drainage (ENBD), ERBD with or without EST, or a combination of these procedures. ENBD was not performed in our study because of its inconvenience and risk of accidental tube removal. EST alone is not a good option for treatment of postoperative bile leakage. Marks et al. [18] reported, in a randomized and controlled study using a canine model, that biliary stenting facilitates more rapid resolution of leakage than does EST alone. The theoretical mechanism of resolution of bile leakage is lowering the transpapillary pressure gradient through ampullary orifice and bridging of the leak site. EST alone can lead to equalization of the pressure gradient between the bile duct and duodenum, which decreases flow resistance and diverts bile flow into the duodenum, consequently facilitating leak sealing [3,19]. After EST, placement of a plastic stent at the leak site offers a more predictable pressure gradient-lowering effect and prevents mucosal damage due to bile contents by means of a bridging effect. In addition, stenting can induce bile flow preferentially toward the ampulla [3,20-22]. According to Kaffes et al. [13], endoscopic therapy was carried out in 97 of 100 patients with bile leakage. The endoscopic procedures included stent insertion alone (40 patients), sphincterotomy alone (18 patients), and the combination of both procedures (31 patients). The number of treatment failures was significantly greater in the EST-only group than in the stent-only and combination groups [13]. In our study, the optimum treatment of bile leakage after hepatobiliary surgery was EST plus biliary stenting, which was performed in all cases of postoperative bile leakage. Thirteen cases of bile leakage occurred after laparoscopic cholecystectomy, and all underwent successful endoscopic treatment. One of the seven cases in which bile leakage occurred after liver resection experienced treatment failure, resulting in a failure rate of 14.2% in this study.

Table 3. Type of inserted stent

Variable	No. (%)
Length, cm	
5	1 (4.5)
7	3 (13.6)
9	2 (9.1)
10	9 (41)
12	5 (22.7)
15	2 (9.1)
Size, Fr	
7	19 (86.4)
10	3 (13.6)
Shape	
Straight	7 (31.8)
Double pig tail	15 (68.2)

The length, size, and type of plastic stent used varied. Plastic stents of various lengths (5 cm in 4.5%, 7 cm in 13.6%, 9 cm in 9.1%, 10 cm in 41%, 12 cm in 22.7%, and 15 cm in 9.1%), sizes (7 Fr in 86.4% and 10 Fr in 13.6%), and types (straight in 31.5% and double pig tail in 68.5%) were inserted at the sites of bile leakage (Table 3). However, the optimum length, size and type of plastic stent, and the time required for complete resolution have not been determined. A large review of endoscopic intervention for biliary leaks after laparoscopic cholecystectomy by the Midwest Pancreatico Biliary Group concluded that the diameter of the stent does not appear to be important for the treatment of biliary leaks, and 7 Fr stents are a sufficient size for that purpose [15]. A similar conclusion was reached by a large Australian retrospective review of endoscopic intervention in patients with postcholecystectomy bile leakage [13]. In our study, the length, size, and type of plastic stents inserted did not affect the treatment outcomes.

Bile leakage sealing generally takes 1 week after stent placement, and complete closure of the leak site takes 4 to 7 weeks. Therefore, it is usually recommended to remove plastic stents 4 to 6 weeks after placement [2,4,19,22,23]. The average stent maintenance period was 10 to 12 weeks (mean, 77.6 ± 21.7 days) in our study, which is longer than that in previous reports. Nevertheless, no stent malfunction occurred during the maintenance period, and good treatment outcomes were reported.

Based on our results, the overall success rate of ERBD with EST for treatment of bile leakage was 95%. Furthermore, there was no severe endoscopic procedure-induced complication. In conclusion, endoscopic therapy is safe and effective for management of hepatobiliary surgery-induced bile leakage. The endoscopic approach should be considered the first-line modality for the diagnosis and treatment of bile leakage after hepatobiliary surgery.

KEY MESSAGE

1. Bile leakage can occur after hepatobiliary surgery and can lead to serious complications.
2. Endoscopic treatment is a safe and effective method for management of hepatobiliary surgery-induced bile leakage

Conflict of interest

No potential conflict of interest relevant to this article was reported.

Acknowledgments

This study was supported by Konkuk University.

REFERENCES

1. Binmoeller KF, Katon RM, Shneidman R. Endoscopic management of postoperative biliary leaks: review of 77 cases and report of two cases with biloma formation. *Am J Gastroenterol* 1991;86:227-231.
2. Bjorkman DJ, Carr-Locke DL, Lichtenstein DR, et al. Postsurgical bile leaks: endoscopic obliteration of the transpapillary pressure gradient is enough. *Am J Gastroenterol* 1995;90:2128-2133.
3. Barkun AN, Rezieg M, Mehta SN, et al. Postcholecystectomy biliary leaks in the laparoscopic era: risk factors, presentation, and management. *McGill Gallstone Treatment Group. Gastrointest Endosc* 1997;45:277-282.
4. Agarwal N, Sharma BC, Garg S, Kumar R, Sarin SK. Endoscopic management of postoperative bile leaks. *Hepatobiliary Pancreat Dis Int* 2006;5:273-277.
5. Davids PH, Rauws EA, Tytgat GN, Huijbregtse K. Postoperative bile leakage: endoscopic management. *Gut* 1992;33:1118-1122.
6. Ijichi M, Takayama T, Toyoda H, Sano K, Kubota K,

- Makuuchi M. Randomized trial of the usefulness of a bile leakage test during hepatic resection. *Arch Surg* 2000;135:1395-1400.
7. Lam CM, Lo CM, Liu CL, Fan ST. Biliary complications during liver resection. *World J Surg* 2001;25:1273-1276.
 8. Li J, Malago M, Sotiropoulos GC, et al. Intraoperative application of "white test" to reduce postoperative bile leak after major liver resection: results of a prospective cohort study in 137 patients. *Langenbecks Arch Surg* 2009;394:1019-1024.
 9. Lo CM, Fan ST, Liu CL, Lai EC, Wong J. Biliary complications after hepatic resection: risk factors, management, and outcome. *Arch Surg* 1998;133:156-161.
 10. Nagano Y, Togo S, Tanaka K, et al. Risk factors and management of bile leakage after hepatic resection. *World J Surg* 2003;27:695-698.
 11. Pace RF, Blenkarn JI, Edwards WJ, Orloff M, Blumgart LH, Benjamin IS. Intra-abdominal sepsis after hepatic resection. *Ann Surg* 1989;209:302-306.
 12. Paquet JC, Dziri C, Hay JM, et al. Prevention of deep abdominal complications with omentoplasty on the raw surface after hepatic resection: the French Associations for Surgical Research. *Am J Surg* 2000;179:103-109.
 13. Kaffes AJ, Hourigan L, De Luca N, Byth K, Williams SJ, Bourke MJ. Impact of endoscopic intervention in 100 patients with suspected postcholecystectomy bile leak. *Gastrointest Endosc* 2005;61:269-275.
 14. Sandha GS, Bourke MJ, Haber GB, Kortan PP. Endoscopic therapy for bile leak based on a new classification: results in 207 patients. *Gastrointest Endosc* 2004;60:567-574.
 15. Ryan ME, Geenen JE, Lehman GA, et al. Endoscopic intervention for biliary leaks after laparoscopic cholecystectomy: a multicenter review. *Gastrointest Endosc* 1998;47:261-266.
 16. Dechene A, Jochum C, Fingas C, et al. Endoscopic management is the treatment of choice for bile leaks after liver resection. *Gastrointest Endosc* 2014;80:626-633.
 17. Donatelli G, Vergeau BM, Derhy S, et al. Combined endoscopic and radiologic approach for complex bile duct injuries (with video). *Gastrointest Endosc* 2014;79:855-864.
 18. Marks JM, Ponsky JL, Shillingstad RB, Singh J. Biliary stenting is more effective than sphincterotomy in the resolution of biliary leaks. *Surg Endosc* 1998;12:327-330.
 19. Kim KH, Kim TN. Endoscopic management of bile leakage after cholecystectomy: a single-center experience for 12 years. *Clin Endosc* 2014;47:248-253.
 20. Tzovaras G, Peyser P, Kow L, Wilson T, Padbury R, Toouli J. Minimally invasive management of bile leak after laparoscopic cholecystectomy. *HPB (Oxford)* 2001;3:165-168.
 21. Peters JH, Ollila D, Nichols KE, et al. Diagnosis and management of bile leaks following laparoscopic cholecystectomy. *Surg Laparosc Endosc* 1994;4:163-170.
 22. Barton JR, Russell RC, Hatfield AR. Management of bile leaks after laparoscopic cholecystectomy. *Br J Surg* 1995;82:980-984.
 23. Wootton FT, Hoffman BJ, Marsh WH, Cunningham JT. Biliary complications following laparoscopic cholecystectomy. *Gastrointest Endosc* 1992;38:183-185.