



ELSEVIER

Contents lists available at ScienceDirect

Toxicology Reports

journal homepage: www.elsevier.com/locate/toxrep

Case report

Extended release potassium salts overdose and endoscopic removal of a pharmacobezoar: A case report



Pérez Tuñón Jorge Guillermo^{a,*}, Pérez Hernández Juan Carlos^{b,1},
Bautista Albitzer Mayré Ivonne^{b,2}, Terán Flores Herminio^{b,3},
Ramírez Pérez Rubén^{c,4}

^a Jefe del Centro Toxicológico Hospital Angeles Lomas, Vialidad de la Barranca No. 14, Colonia Valle de las Palmas, Huixquilucan, Estado de México CP 52787, Mexico

^b Adscrito al Centro Toxicológico Hospital Angeles Lomas, Vialidad de la Barranca No. 14, Colonia Valle de las Palmas, Huixquilucan, Estado de México CP 52787, Mexico

^c Residente de Toxicología Hospital Angeles Lomas, Vialidad de la Barranca No. 14, Colonia Valle de las Palmas, Huixquilucan, Estado de México CP 52787, Mexico

ARTICLE INFO

Article history:

Received 7 February 2014

Received in revised form 4 April 2014

Accepted 4 April 2014

Available online 22 May 2014

Keywords:

Pharmacobezoar

Endoscopy

Extended release potassium salts

ABSTRACT

Background: Reported cases of potassium overdoses have shown that this condition could generate several morbidities, mainly related to cardiac dysrhythmias even with fatal outcomes in some cases.

Potassium salts in extended release tablets could form pharmacobezoars if a large amount is ingested. In relation to the above, when the patient has a pharmacobezoar, clinical findings may be delayed and may persist.

The techniques available for removal of a pharmacobezoar are whole bowel irrigation (WBI), endoscopy or in some surgery [1]. Endoscopy as a decontamination method has shown promising results.

Case report: A 42 year old woman, who intentionally ingested 100 tablets of extended release potassium chloride, 50 mg of clonazepam and an undisclosed amount of ethanol, presented with metabolic acidosis, hyperlactatemia and sinus tachycardia 2 h after ingestion. Gastric lavage and activated charcoal were applied initially, specific measures were not necessary. However, a transcutaneous pacemaker was placed. Because of her background, we considered a pharmacobezoar and an endoscopy were performed to remove 99 tablets of potassium that were isolated or forming concretions.

Discussion: The readily available techniques to remove a pharmacobezoar are whole bowel irrigation (WBI) and endoscopy; nevertheless there is not a consensus about their relative merits. Our patient was treated by endoscopy because we found on the X-ray a conglomerate of radiopaque images suggesting a pharmacobezoar. In this case we did not have any adverse effect.

Conclusions: We consider that endoscopy could be an effective and safe method to remove a drug bezoar from the stomach in uncomplicated patients.

© 2014 The Authors. Published by Elsevier Ireland Ltd. This is an open access article under the CC BY-NC-ND license (<http://creativecommons.org/licenses/by-nc-nd/3.0/>).

* Corresponding author. Tel.: +52 1 55 52465056; mobile: +52 1 55 19177028.

E-mail addresses: jtunon80@hotmail.com, toxicologia_angeles@yahoo.com.mx (P.T.J. Guillermo), jcmედურგ@hotmail.com (P.H.J. Carlos), nakkko@live.com.mx (B.A.M. Ivonne), wayne_gt@hotmail.com (T.F. Herminio), saymeno@hotmail.com (R.P. Rubén).

¹ Mobile: +52 1 55 48706380.

² Mobile: +52 1 722 5189242.

³ Mobile: +52 1 55 39896337.

⁴ Mobile: +52 1 55 45832697.

<http://dx.doi.org/10.1016/j.toxrep.2014.04.002>

2214-7500/© 2014 The Authors. Published by Elsevier Ireland Ltd. This is an open access article under the CC BY-NC-ND license (<http://creativecommons.org/licenses/by-nc-nd/3.0/>).

1. Background

Extended release potassium salts are indicated in induced or acquired hypokalemic conditions. The potassium overdose could generate hyperkalemic states, especially if the patient has impaired renal function or if there has been a large ingestion of salts (toxic dosage: 2 mEq/kg) [1]. When a patient presents a large ingestion of extended release potassium tablets, clinical manifestations could be delayed even more than 24 h and concretions could be formed in the stomach. Concretions complicates the decontamination by gastric lavage, so that after this procedure in these patients, it is possible to find tablets remaining in the stomach, even in 88.2% of cases [2].

The great absorption that follows to a massive ingestion of potassium salts causes myocardial conduction disturbances and metabolic acidosis.

The correct technique for gastrointestinal decontamination in cases of massive overdose of extended-release tablets is not well established, nowadays, toxicologists continue to consider use of whole bowel irrigation (WBI), endoscopy or even surgery to evacuate tablet remaining from the stomach [1].

2. Case report

A 42 year old woman with history of borderline personality disorder and a suicide attempt with potassium salts (50 tablets) one year earlier presented to the emergency room after intake of 100 tablets of extended release potassium chloride (1000 mEq), 50 mg of liquid clonazepam, and an undisclosed amount of ethanol at home.

She recognized this as a new suicide attempt and presented with somnolence, tachycardia and exhalation of ethanol odor 2 h after ingestion. Her vital signs were: blood pressure 130/90 mm Hg, pulse was 97 beats/min, respirations were 22 breaths/min, temperature was 36.5 °C, and oxygen saturation was 98% on room air.

A 12 lead electrocardiogram demonstrated sinus tachycardia with normal QRS duration and unaltered T-waves. Potassium level was 3.9 mmol/L, blood gas analysis revealed pH 7.25, HCO₃ 17.5 mEq/L and lactate 4.9 mmol/L. A standard toxicological screen was negative for all agents. Ethanol level was 90.80 mg/dl. Finally a plain film of the abdomen showed multiple opacities in the region of the stomach (Fig. 1). Other agents, including acetaminophen and salicylates were reported to be absent.

A venous access was placed. After that, a gastric lavage with a 20-french orogastric tube (maximum size in our hospital) was performed. However, no tablets were recovered during this procedure. Also, a single dose of activated charcoal was performed in order to treat a possible coingestant. Anti-hyperkalemic measures were not necessary at that time. However, a transcutaneous pacemaker was placed.

Given her background and the gastric lavage that was ineffective, an abdominal radiography was performed in order to identify the location of the tablets. The radiography showed multiple radiopacities in the stomach and the possibility of a pharmacobezoar was considered. Consultation with the gastroenterology service was done to request an endoscopy for removal of the suspected pharmacobezoar.

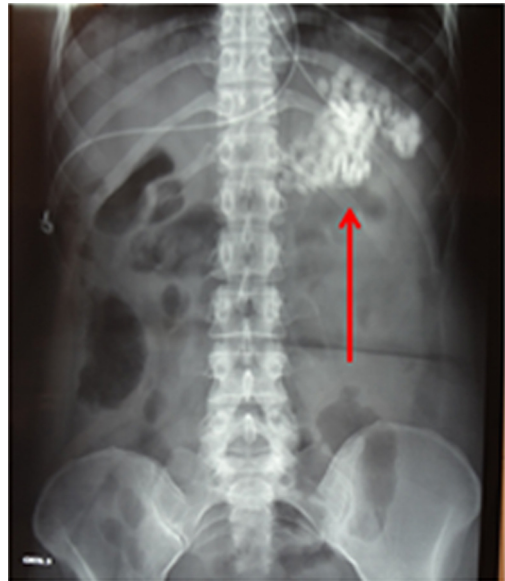

Fig. 1. Abdominal radiography with multiple radioopacities in the stomach (red arrow).

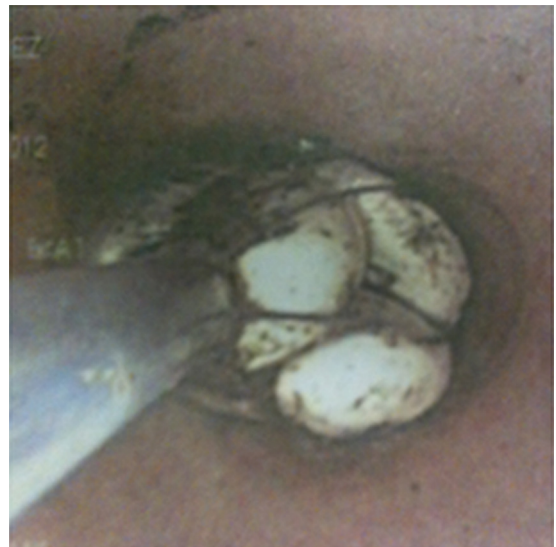

Fig. 2. Endoscopic removal of the tablets.

A total of 99 of the 100 tablets that were either isolated or forming concretions were removed with an endoscopic basket (Figs. 2 and 3).

After gastric decontamination, clinical outcome was satisfactory, pharmacological correction of acidosis was not needed and she did not develop hyperkalemia or cardiovascular impairments. The patient was intubated for the procedure and extubated 18 h later. After that, she was discharged to the psychiatry service 48 h later.

3. Discussion

The potassium excess could be absorbed by the intracellular compartment to maintain serum levels under




Fig. 3. Removed tablets.

5.5 mEq/L, but unfortunately this mechanism is saturable [3]. In this context, potassium serum levels over 6.0 mEq/L should be considered risky and need to be treated immediately [4,5]. Although there is no clear relationship between the serum level and heart rhythm disturbances, we know that the risk of dysrhythmias is increased if rapid absorption of potassium occurs [1,4,6,7].

Many drugs are capable to form concretions as in the case of amitriptyline, salicylates, carbamazepine, iron, potassium salts and other extended release preparations, with or without an enteric coat [8–11].

The gastric decontamination is an essential procedure in the treatment of patients with an oral drug overdose; however, the appropriate technique to remove a bezoar is still controversial.

The gastric lavage and activated charcoal administration have both been demonstrated to be poorly effective on patients with pharmacobezoars. Moreover, in Mexico there are no orogastric tubes with a recommended diameter to remove extended release tablets (36–40 Fr).

Nowadays, the available techniques to remove pharmacobezoars include: WBI (only small size bezoars), endoscopy and surgical extraction. In this context, the main factors to consider before selecting a decontamination technique are: drug toxicity, pharmacobezoar size and location, clinical condition of the patient and availability of the resources (polyethylene glycol, operating room, etc.) [10].

Despite the fact that WBI has been demonstrated in some reports be safe and to improve the clinical condition of these patients, at this time there is no strong evidence of its efficacy. It requires several hours to clarify the effluent, also, it is necessary to have a normal bowel function and it could not be effective if a big bezoar exists in the stomach. In the case of perforation, intestinal occlusion, active bleeding, hemodynamic instability or vomiting, the WBI are contraindicated [12]. Also, in the case of a potassium salts overdose, one of the most important causes of morbidity is the cardiac rhythm disturbance with hemodynamic instability, which limits the use of WBI.

We considered the high risk of massive absorption with hemodynamic implications and started management with airway protection, placement of a pacemaker and decontamination by endoscopy [13]. Furthermore, our patient had a history of a previous suicide attempt with 50 tablets of extended release potassium salts. She developed hyperkalemia, metabolic acidosis and hyperacute T waves, and was hospitalized seven days in an intensive care unit. In the second attempt, even though the patient increased the ingestion to 100 tablets of the same drug, she did not develop any complication and was discharged two days after ingestion. We strongly concur that if a pharmacobezoar is suspected endoscopy should be considered in order to avoid a massive absorption [10,14,21].

On the other hand, the multiple introductions of the endoscope could increase the risk of airway injuries and aspiration of gastric content [15]. Despite that, in our case, the equipment was introduced eighteen times and no complications were presented. For this reason, we consider the endoscopic removal of bezoars a therapeutical option for

Table 1
Case development.

Time	Serumpotassium, blood gas	Therapeutics
Arrival	K 3.9 mmol/L pH 7.25, HCO ₃ ⁻ 17, Lact 4.9 mmol/L	Parenteral solutions Not Anti hyperkalemic measures. Transcutaneouspacemaker Endoscopy
5 h (after endoscopy)	K 3.5 mmol/L pH 7.39, HCO ₃ ⁻ 18.3, Lact 0.6 mmol/L	Not Anti hyperkalemicmeasures
8 h	K 3.4 mmol/L	Not Anti hyperkalemicmeasures
18 h	K 4.3 mmol/L	Not Anti hyperkalemic measures. Transcutaneous pacemaker was removed

uncomplicated patients and should be performed early if the medical center is short of appropriate orogastric tubes [1,16].

Gunja [17] describes a case of a patient who ingested 100 tablets of extended release potassium chloride with severe hyperkalemia 5 h after the ingestion [17]. Also, Saxena [18] describes a case of a woman who ingested 16 mEq/Kg of potassium salts and developed severe hyperkalemia with cardiac arrest in the first hour after the ingestion. Finally, Colledge [19] reported another case with an intake of approximately 100 tablets with hyperkalemia and ventricular tachycardia demonstrating the effects of a rapid absorption in massive ingestions of potassium salts. In our case, due to the early endoscopic removal of tablets, the patient did not increase potassium serum levels and complications were not registered.

4. Conclusions

This was a case of intentional potassium, ethanol and clonazepam overdose resulting in mild metabolic acidosis, hyperlactatemia and sinus tachycardia at 2 h after ingestion, without hyperkalemia and after utilizing endoscopy in order to remove 100 isolated tablets and forming pharmacobezoars. In this case, the bezoar formation could lead to massive absorption of potassium and increase the risk of hyperkalemic disturbances. In addition to standard treatments for hyperkalemia, this case report demonstrates the benefit from endoscopy in extended-release potassium bezoar formation, considering the hospital resources, time from the ingestion and clinical status of the patient. Also, this study asks whether endoscopy should be used as an initial measure of decontamination in patients who have

Table 2
Reported cases.

Report	Patient	Time (intake)	Extended release KCl	Findings	Serum K	Therapy
Charles et al. (1978)	32, F	18 h	47 tabs (8 mmol)	Diarrhea, death	10.8 mmol/l (intraocular)	0
Illingworth (1980) [22]	36, M	5 h	Unknown Tabs, 8 mmol	Wide complex tachycardia (125×)	8.9 mmol/l	5, 6, 7, 9, 10
Colledge et al. (1988)	24, F	2 h	100 tabs	Hyperacute T waves, sinus tachycardia 110×. Ventricular tachycardia	6.4 mmol/l	1, 5, 6, 7
Steedman (1988) [25]	27, F	12 h	60 tabs (8 mmol)	1st degree AV blockade, QRS widening and hyperacute T waves	9.1 mmol/l	5, 6, 7, 9, 12
Peeters et al. (1998)	62, F	?	300 tabs (2.4 mmol)	Abdominal distension. One month later gastric necrosis	Not report	3
	58, M	5 h	20 tabs of extended release KCl (630 mg). Bendoflurazide and phenylbutazone	Left ventricular heart failure	8 mmol/l	1, 6, 9, 10
	26, M	3.5 h	10 tabs dextro-propoxyphene – acetaminophen 40 tabs of extended release KCl (8 mmol)	Unaltered EKG. Nausea and vomiting, Asystole, death in gastric lavage	9.3 mmol/l	1
Whitaker et al. (2000) [26]	2 months M	24 h	5 tabs (8 mmol)	Death	10.1 mmol/l	0
	30 months M	30 min	32 tabs	Tachycardia (155×) 1st degree AV blockade. Hyperacute T waves	9.2 mmol/l	2, 5, 6, 9, 10
Su (2001) [27]	50, F	1 h	100 tabs (10 mEq) Alprazolam and ibuprofen	Hyperacute T waves	8.2 mmol/l	1, 2, 4, 5, 6, 7, 9, 13
	17 a, M	10 h	20–30 tabs (10 mEq)	Tachycardia, nausea, vomiting and diarrhea	5.5 mmol/l	2
Wan (2007) [24]	86, M	Chronic	70 tabs (8 mmol)	Asthenia and adinamia	6.8 mmol/l	2, 5, 6, 7
Gunja (2011)	42, F	90 min	40 tabs (8 mmol)	Tachycardia (100×)	5.5 mmol/l	6, 2
	42, F	5 h	100 tab (8 mmol)	Tachycardia (124×)	8.5 mmol/l	5, 6, 7, 4
	6, M	2 h	10–20 tab (8 mmol)	Plane T waves	7.6 mmol/l	4, 5, 6, 7, 8.
Saxena (1988)	46, F	1 h	100 tab (8 mmol)	Cardiac arrest	9.6 mmol/l	1, 5, 6, 7, 9, 11, 14.
Briggs Albert et al. (2013) [28]	44, F	75 min	30 tab (20 mEq)	Mildly peaked T waves	7.3 mmol/L	2, 3, 5, 6, 7, 8.
Pérez et al. (2013)	42, F	2 h	100 tab (10 mEq)	Metabolic acidosis, hyperlactatemia and sinus tachycardia with normal T waves	3.9 mmol/L	1, 3, 11

1: gastric lavage; 2: whole bowel irrigation; 3: endoscopy; 4: hemodialysis; 5: calcium; 6: insulin/glucose; 7: sodium bicarbonate; 8: β -2 agonist; 9: ion exchange resin; 10: furosemide; 11: activated charcoal; 12: mannitol; 13: cardiac pacemaker and 14: advanced cardiac resuscitation.

ingested a large quantity of tablets, particularly in centers where there is a lack of adequate tubes for gastric lavage (Table 1).

We concur that in selected cases endoscopy could be used instead of gastric lavage as first decontamination measure, although, a clinical guideline for the use of endoscopy as a decontamination method still need to be created.

Cases of extended release potassium salts reported are summarized below (Table 2).

Conflict of interest

The authors declare that they have no competing interests.

Acknowledgement

Special thanks to Dr. Carlos Mitrani Boyle, gastroenterologist and endoscopist who performed the procedure.

Appendix A. Supplementary data

Supplementary data associated with this article can be found, in the online version, at [doi:10.1016/j.toxrep.2014.04.002](https://doi.org/10.1016/j.toxrep.2014.04.002).

References

- [1] N.A. Buckley, A.H. Dawson, A.D. Reith, Controlled release drugs in overdose, *Drug Saf.* 12 (1995) 73–84.
- [2] J.P. Saetta, D.N. Quinton, Residual gastric content after gastric lavage and ipecacuanha-induced emesis in self-poisoned patients: an endoscopic study, *J. R. Soc. Med.* 84 (1991) 35–38.
- [3] J.S. Timothy, W.W. Robert, Disorders of Potassium, *Emerg. Med. Clin. N. Am.* 23 (2005) 723–747.
- [4] F.J. Gennari, Disorders of potassium homeostasis: hypokalemia and hyperkalemia, *Crit. Care Clin.* 18 (2002) 273–288.
- [5] M.A. Perazella, R.L. Mahnensmith, Hyperkalemia in the elderly: drugs exacerbate impaired potassium homeostasis, *J. Gen. Intern. Med.* 12 (1997) 646–656.
- [6] C.G. Acker, J.P. Johnson, P.M. Palevsky, et al., Hyperkalemia in hospitalized patient: cause, adequacy of treatment, and results of an attempt to improve physician compliance with published therapy guidelines, *Arch. Intern. Med.* 158 (1998) 917–924.
- [7] D. Charytan, D.S. Goldfarb, Indications for hospitalization of patients with hyperkalemia, *Arch. Intern. Med.* 160 (2000) 1605–1611.
- [8] J.R. Taylor, D.S. Streetman, S.S. Castle, Medication bezoars: a literature review and report of a case, *Ann. Pharmacother.* 32 (1998) 940–946.
- [9] J.W.P.M. Peeters, S.D.J. Van Der Werf, Gastric stenosis after potassium chloride ingestion, *Endoscopy* 30 (1998) 110.
- [10] J. Höjer, M. Personne, Endoscopic removal of slow release clomipramine bezoars in two cases of acute poisoning, *Clin. Toxicol.* 46 (2008) 317–319.
- [11] R. Robert, J.-P. Frat, A. Veinstein, J. Rouffineau, Protective effect of medication bezoar after a massive beta-blocker, digoxin, and amitriptyline poisoning, *Clin. Toxicol.* 43 (2005) 381–382.
- [12] American Academy of Clinical Toxicology, European Association of Poison Centers and Clinical Toxicologists. position paper: whole bowel irrigation, *Clin. Toxicol.* 42 (2004) 843–854.
- [13] R. Whang, Hyperkalaemia: diagnosis and treatment, *Am. J. Med. Sci.* 272 (1976) 19–29.
- [14] D.L. Savitt, H.H. Hawkins, J.R. Roberts, The radiopacity of ingested medications, *Ann. Emerg. Med.* 16 (1987) 331–339.
- [15] H.W. Ng, M.L. Tse, F.L. Lau, W. Chu, Endoscopic removal of iron bezoar following acute overdose, *Clin Toxicol.* 46 (2008) 913–915.
- [16] W.L. Geng, C.H. Chen, Y.J. Tseng, H.D. Zong, Pharmacobezoar of the esophagus, *Clin. Toxicol.* 49 (2011) 348–349.
- [17] N. Gunja, Decontamination and enhanced elimination in sustained-release potassium chloride poisoning, *Emerg. Med. Australas* 23 (2011) 769–772.
- [18] K. Saxena, Death from potassium chloride overdose, *Postgrad. Med.* 84 (97-8) (1988) 101–102.
- [19] N.R. Colledge, B. Northridge, D.M. Fraser, Survival after massive overdose of slow release potassium, *Scott. Med. J.* 33 (1988) 279.
- [20] C. Schwerk, M. Schulz, N. Schwerk, S. Blüher, W. Kiess, W. Siekmeyer, Etilefrin hydrochloride tablet ingestion: successful therapy by endoscopic removal of tablet conglomerate, *Klin. Padiatr.* 221 (2009) 93–96.
- [21] N.R. Illingworth, Rapid poisoning with slow-release potassium, *Br. Med. J.* (1980) 485–486.
- [22] C.K. Wan, H.K. Tong, A case of slow release potassium chloride overdose, *Hong Kong J. Emerg. Med.* 14 (2007) 169–173.
- [23] D.J. Steedman, Poisoning with sustained release potassium, *Arch. Emerg. Med.* 5 (1988) 206–211.
- [24] R.J. Whitaker, J.E. Maguire, Slow-release potassium overdose: clinical features and the role of wholebowel lavage in management, *Emerg. Med.* 12 (2000) 218–225.
- [25] M. Su, C. Stork, S. Ravuri, T. Lavoie, et al., Sustained-release potassium chloride overdose, *Clin. Toxicol.* 39 (2001) 641–648.
- [26] A.L. Briggs, L.L. Deal, Endoscopic removal of pharmacobezoar in case of intentional potassium overdose, *J. Emerg. Med.* 08 (2013) 1–4.