



Incidental echocardiographic findings of a quadricuspid aortic valve associated with aortic regurgitation in a cat

Journal of Feline Medicine and Surgery

Open Reports

1–4

© The Author(s) 2015

Reprints and permissions:

sagepub.co.uk/journalsPermissions.nav

DOI: 10.1177/2055116915596356

jfmsopenreports.com



Takashi Nakamura, Tamotsu Sawada and Mayumi Takagi

Abstract

Case summary A 10-month-old male domestic shorthair cat was brought to Kitanomori Animal Hospital for routine castration. Preoperative thoracic radiography revealed a mildly enlarged heart silhouette, and transthoracic echocardiography (ECHO) suggested a quadricuspid aortic valve associated with central aortic regurgitation (regurgitant fraction 31%). After sedation with intramuscular medetomidine and midazolam for castration, heart rate decreased from 193 to 76 beats per minute. ECHO under sedation revealed two equally small and two equally large aortic valve cusps, suggesting a type C quadricuspid aortic valve. The findings were confirmed by real-time three-dimensional ECHO.

Relevance and novel information This case reveals the echocardiographic features of a feline quadricuspid aortic valve and shows that transthoracic ECHO is useful to examine aortic valve morphology in cats. It also suggests that echocardiographic screening may be beneficial for detecting congenital cardiac anomalies in apparently healthy cats.

Accepted: 16 June 2015

Introduction

An aortic valve is usually composed of three cusps. However, excess division of a primitive aortic valve swelling during embryogenesis results in four cusps, forming a quadricuspid aortic valve.¹ A quadricuspid aortic valve is a congenital cardiac anomaly with an incidence of 0.008–0.033% in humans,^{2,3} and has also been described in the dog, cat, Syrian hamster and greater white-toothed shrew.^{4–9} Transthoracic echocardiography (ECHO) has been used for diagnosis in dogs.^{7–9} However, its echocardiographic features in cats are unknown. This case report details the echocardiographic features of a quadricuspid aortic valve associated with aortic regurgitation in an apparently healthy cat.

Case description

A 10-month-old male domestic shorthair cat weighing 3.8 kg was brought to Kitanomori Animal Hospital for routine castration. The cat appeared alert and healthy. Its heart rate was 193 beats per minute (bpm) and had a regular rhythm. No cardiac murmur was detected on auscultation. Physical examination did not reveal other remarkable findings. The haematological and

biochemical results were within the reference intervals. Preoperative routine transthoracic ECHO was performed with concomitant electrocardiographic tracing (GE Vivid E9; GE Medical Systems) using a 12 MHz phased-array transducer. Two-dimensional and M-mode ECHO showed no left ventricular (internal diameter 17.5 mm [reference interval 10.8–21.4 mm]) or left atrial (internal diameter 13.5 mm [reference interval 7.0–17.0 mm]) enlargement,¹⁰ and no abnormalities in the left ventricular free wall (3.9 mm) or interventricular septal (3.7 mm) thickness at diastole. The parasternal short-axis view at the aortic valve level revealed four aortic valve cusps (Figure 1).

Colour Doppler ECHO revealed central aortic regurgitation (Figure 2). The flow velocity was 5.3 m/s at

Kitanomori Animal Hospital, Sapporo-shi, Hokkaido, Japan

Corresponding author:

Takashi Nakamura DVM, PhD, Kitanomori Animal Hospital, 17-1-35, Shinkotoni 11-jo, Kita-ku, Sapporo-shi, Hokkaido 001-0911, Japan

Email: takashi-n@t00.itscom.net



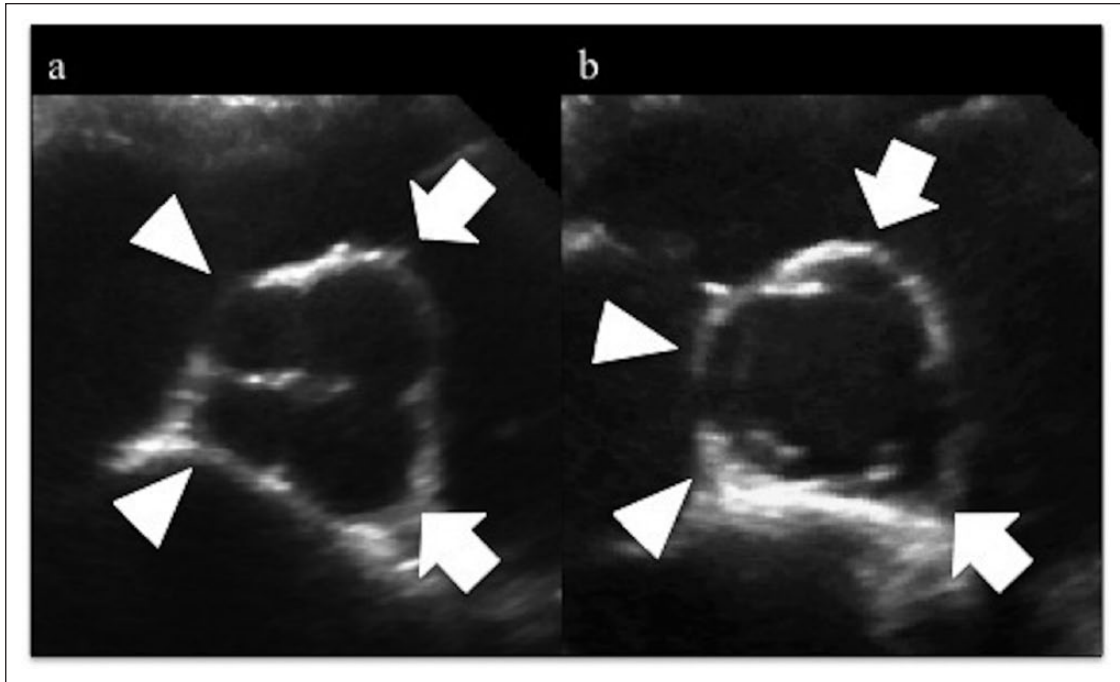


Figure 1 Two-dimensional echocardiographic images from the right parasternal short-axis view at the aortic valve level during (a) diastole and (b) systole showing two equally large (arrows) and two equally small (arrowheads) aortic valve cusps

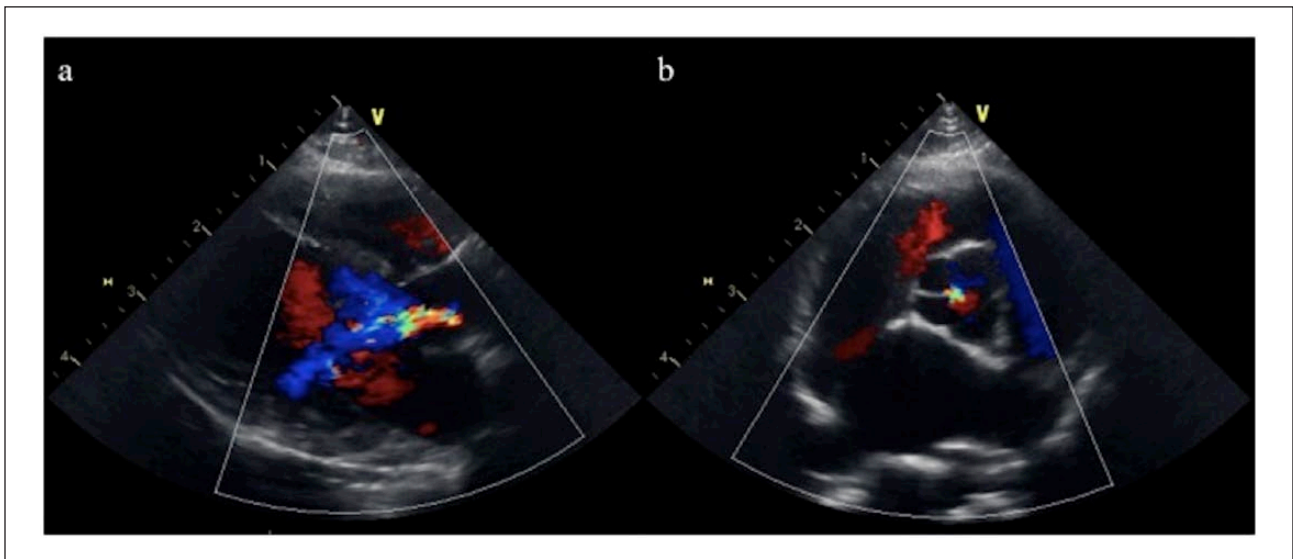


Figure 2 Colour Doppler echocardiographic images from the right parasternal (a) long-axis and (b) short-axis views at the aortic valve level, demonstrating moderate central aortic regurgitation (long-axis view)

early diastole and 4.3 m/s at end-diastole. The pressure half-time and deceleration slope were 221 ms and 8.4 m/s², respectively. The aortic flow was of normal velocity (1.2 m/s), and aortic valve stenosis was not observed. The regurgitant fraction was estimated by the pulsed Doppler method on the basis of aortic and mitral stroke volumes.^{11,12} The aortic stroke volume was measured by multiplying the aortic valve area ($3.14 \times [\text{aortic valve diameter in the parasternal long-axis view}]^2/4$) and the velocity time integral of

the aortic valve flow. The mitral stroke volume was measured by multiplying the mitral valve area ($3.14 \times [\text{mitral valve diameter in the apical four-chamber view}]/2 \times [\text{mitral valve diameter in the apical two-chamber view}]/2$) and the velocity time integral of the mitral valve flow. Finally, the regurgitant fraction (%) was calculated as $(\text{aortic stroke volume} - \text{mitral stroke volume})/\text{aortic stroke volume} \times 100$. In this case, the aortic and mitral stroke volumes were 9.2 and 6.3 ml, respectively, and the regurgitant fraction was 31%.

The ratio of jet width to outflow tract diameter, as measured just below the aortic valve in the long-axis view, was 34%.¹² These findings suggested moderate aortic regurgitation.^{11,12}

Additional cardiac examinations including electrocardiography, blood pressure measurements and thoracic radiography were performed because of the detection of the congenital cardiac abnormalities. Electrocardiography (model D700; Fukuda M-E Kogyo) revealed normal sinus rhythm; the intervals and amplitudes and the duration of each wave was within the reference intervals. Systolic, diastolic and mean blood pressures measured by the oscillometric method (Pettrust monitor; BioCare) were 168, 111 and 130 mmHg, respectively. Thoracic radiography showed a mildly enlarged cardiac silhouette and vertebral heart size of 8.5 vertebrae (reference interval 6.9–8.1 vertebrae) in the right lateral view.¹³

After the cat was sedated with intramuscular medetomidine (0.05 mg/kg, Dolpene; Kyoritsu Seiyaku) and midazolam (0.2 mg/kg, Midazolam; Sandoz) for castration, its heart rate decreased to 76 bpm. Grade II/VI diastolic murmur was detected by auscultation at the left cardiac base. Colour Doppler transthoracic ECHO showed aortic regurgitation and trivial mitral regurgitation. The aortic regurgitant fraction estimated by the pulsed Doppler method at this time was 24%, which may be an overestimation because of the coexisting mitral regurgitation. The ratio of jet width to outflow tract diameter was 21%. Pressure half-time and deceleration slope were 590 ms and 2.6 m/s², respectively. These findings indicated mild aortic regurgitation after sedation. ECHO under sedation revealed two equally small and two equally large aortic valve cusps. Real-time three-dimensional (3D) ECHO confirmed the findings; however, the images did not enable detailed analysis of aortic valve morphology (Figure 3).

Subsequently, the cat was anaesthetised with intramuscular ketamine (5 mg/kg, Ketalar; Daiichi Sankyo) and castrated. It recovered from anaesthesia uneventfully. One year after the initial diagnosis, the cat continues to show no clinical signs and has not received medication.

Discussion

In humans and dogs, a quadricuspid aortic valve appears as an aortic valve with four cusps on transthoracic ECHO in the parasternal short-axis view at the aortic valve level.^{7–9,14} The quadricuspid aortic valve in our patient was diagnosed on the basis of similar echocardiographic findings.

A human quadricuspid aortic valve is classified according to the relative size of each cusp.³ A type C valve has two equally large and two equally small cusps. This type has been reported in dogs.^{8,9} ECHO revealed that our patient, a cat, also had two equally large cusps, corresponding to the left and right coronary cusps, and two equally small cusps, corresponding to the non-coronary cusp. Therefore, our patient had a type C quadricuspid aortic valve.

Aortic regurgitation is the most frequent valvular dysfunction in human quadricuspid aortic valves.¹⁴ In

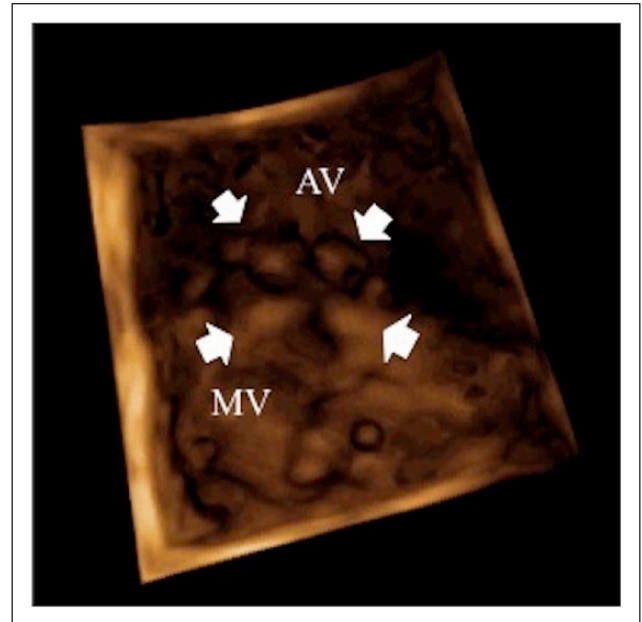


Figure 3 Real-time three-dimensional echocardiographic images after sedation with medetomidine and midazolam. The aortic valve (AV) and mitral valve (MV) were viewed from below during diastole. The aortic valve comprises four cusps (arrows)

dogs, all reported cases have involved mild-to-moderate aortic regurgitation.^{7–9} The sequelae of aortic regurgitation include abnormal leaflet coaptation, fibrous thickening and asymmetrical mechanical stress around the four cusps.¹⁵ A cat with a quadricuspid aortic valve in a previous report had aortic stenosis.⁶ Although quadricuspid aortic valves were not associated with haemodynamic abnormalities, the present case suggests that they cause aortic valvular dysfunction, even in cats.

Many dogs have no clinical signs associated with a quadricuspid aortic valve at diagnosis.^{7–9} In our patient, the abnormality was discovered incidentally during pre-operative screening for castration, and no clinical signs were noted. Cardiac anomalies are often not detected on physical examination in asymptomatic cats, even when heart disease is evident on ECHO.^{16,17} Riesen et al reported that congenital cardiac malformations are detectable by echocardiographic screening in 4.2% of purebred cats.¹⁸ Therefore, echocardiographic examination is recommended for early detection of cardiac anomalies in apparently healthy cats.

The severity of the aortic valve regurgitation was evaluated based on colour jet size (or height), pressure half-time and slope, and regurgitant volume and fraction. A combination of the above methods should be evaluated, and an overall assessment of haemodynamic significance and severity should be performed. There are no standards for measurement of these parameters in cats.¹⁹ Therefore, we adopted the guidelines of the

American Society of Echocardiography for our cat.¹² The above-mentioned echocardiographic parameters in our cat with aortic valve regurgitation before sedation showed that the severity was moderate; however, there was mild cardiac remodelling and no change of blood pressure. Therefore, these findings indicated that the aortic valve regurgitation in our cat was moderate, but the insufficiency was haemodynamically insignificant.

Recently, real-time 3D ECHO has been used to evaluate human quadricuspid aortic valves.^{20,21} However, Sugeng et al have reported limitations in the ability to depict aortic valve morphology in humans.²² This technique presents additional problems in veterinary medicine, including the low frequency (4 MHz) of the 3D echocardiographic probe and the high heart rate and small heart size of dogs and cats compared with humans. In our patient, real-time 3D ECHO did not reveal the quadricuspid aortic valve during tachycardia before sedation, indicating limited usefulness in small animals.

Medetomidine is a synthetic α_2 -adrenoreceptor agonist that provides reliable sedation, analgesia, muscle relaxation and anxiolysis in small animals; however, it also induces hypertension because of its peripheral action.²³ Hypertension contributes to the deterioration of aortic regurgitation.²⁴ However, cats sedated with medetomidine show no significant change in arterial blood pressure.²⁵ The echocardiographic findings of the present case did not indicate that sedation with medetomidine worsened aortic regurgitation.

Conclusions

Transthoracic ECHO is useful to examine aortic valve morphology in cats. Echocardiographic screening may be beneficial for detecting congenital cardiac anomalies in apparently healthy cats.

Acknowledgements The authors wish to acknowledge Editage (www.editage.jp) for English language editing.

Funding The authors received no specific grant from any funding agency in the public, commercial or not-for-profit sectors for the preparation of this case report.

Conflict of interest The authors do not have any potential conflicts of interest to declare.

References

- 1 Fernández B, Fernández MC, Durán AC, et al. **Anatomy and formation of congenital bicuspid and quadricuspid pulmonary valves in Syrian hamsters.** *Anat Rec* 1998; 250: 70–79.
- 2 Feldman BJ, Khandheria BK, Warnes CA, et al. **Incidence, description and functional assessment of isolated quadricuspid aortic valves.** *Am J Cardiol* 1990; 65: 937–938.
- 3 Hurwitz LE and Roberts WC. **Quadricuspid semilunar valve.** *Am J Cardiol* 1973; 31: 623–626.
- 4 Durán AC. **Quadricuspid aortic valve and single coronary artery in a greater white-toothed shrew, *Crocidura russula*.** *J Wildl Dis* 1996; 32: 658–660.

- 5 Fernández B, Durán AC, Martire A, et al. **New embryological evidence for the formation of quadricuspid aortic valves in the Syrian hamster (*Mesocricetus auratus*).** *J Comp Pathol* 1999; 121: 89–94.
- 6 Harpster NK. **Cardiovascular diseases of the domestic cat.** *Adv Vet Sci Comp Med* 1977; 21: 39–74.
- 7 Kettner F, Côté E and Kirberger RM. **Quadricuspid aortic valve and associated abnormalities in a dog.** *J Am Anim Hosp Assoc* 2005; 41: 406–412.
- 8 Serres F, Chetboul V, Sampedrano CC, et al. **Quadricuspid aortic valve and associated abnormalities in the dog: report of six cases.** *J Vet Cardiol* 2008; 10: 25–31.
- 9 Sisson D and Riepe R. **Congenital quadricuspid aortic valve anomaly in two dogs.** *J Vet Cardiol* 2000; 2: 23–26.
- 10 Drouin L, Lefbom BK, Rosenthal SL, et al. **Measurement of M-mode echocardiographic parameters in healthy adult Maine Coon cats.** *J Am Vet Med Assoc* 2005; 226: 734–737.
- 11 Bekeredjian R and Grayburn PA. **Valvular heart disease: aortic regurgitation.** *Circulation* 2005; 112: 125–134.
- 12 Zoghbi WA, Enriquez-Sarano M, Foster E, et al. **Recommendations for evaluation of the severity of native valvular regurgitation with two-dimensional and Doppler echocardiography.** *J Am Soc Echocardiogr* 2003; 16: 777–802.
- 13 Litster AL and Buchanan JW. **Vertebral scale system to measure heart size in radiographs of cats.** *J Am Vet Med Assoc* 2000; 216: 210–214.
- 14 Tutarel O. **The quadricuspid aortic valve: a comprehensive review.** *J Heart Valve Dis* 2004; 13: 534–537.
- 15 Armen TA, Vandse R, Bickle K, et al. **Three-dimensional echocardiographic evaluation of an incidental quadricuspid aortic valve.** *Eur J Echocardiogr* 2008; 9: 318–320.
- 16 Paige CF, Abbott JA, Elvinger F, et al. **Prevalence of cardiomyopathy in apparently healthy cats.** *J Am Vet Med Assoc* 2009; 234: 1398–1403.
- 17 Smith S and Dukes-McEwan J. **Clinical signs and left atrial size in cats with cardiovascular disease in general practice.** *J Small Anim Pract* 2012; 53: 27–33.
- 18 Riesen SC, Kovacevic A, Lombard CW, et al. **Echocardiographic screening of purebred cats: an overview from 2002 to 2005.** *Schweiz Arch Tierheilkd* 2007; 149: 73–76.
- 19 Boon JA. **Veterinary echocardiography.** 2nd ed. Oxford: Wiley-Blackwell, 2011, pp 309–318.
- 20 Burri MV, Nanda NC, Singh A, et al. **Live/real time three-dimensional transthoracic echocardiographic identification of quadricuspid aortic valve.** *Echocardiography* 2007; 24: 653–655.
- 21 Janosi RA, Lind T, Buck T, et al. **Quadricuspid aortic valve revealed by real-time, 3-dimensional transesophageal echocardiography.** *Tex Heart Inst J* 2013; 40: 207–208.
- 22 Sugeng L, Shernan SK, Salgo IS, et al. **Live 3-dimensional transesophageal echocardiography: initial experience using the fully-sampled matrix array probe.** *J Am Coll Cardiol* 2008; 52: 446–449.
- 23 Sinclair MD. **A review of the physiological effects of α_2 -agonists related to the clinical use of medetomidine in small animal practice.** *Can Vet J* 2003; 44: 885–897.
- 24 Mokadam NA, Stout KK and Verrier ED. **Management of acute regurgitation in left-sided cardiac valves.** *Tex Heart Inst J* 2011; 38: 9–19.
- 25 Lamont LA, Bulmer BJ, Grimm KA, et al. **Cardiopulmonary evaluation of the use of medetomidine hydrochloride in cats.** *Am J Vet Res* 2001; 62: 1745–1749.