



ELSEVIER

Contents lists available at [ScienceDirect](https://www.sciencedirect.com)

Trauma Case Reports

journal homepage: www.elsevier.com/locate/tcr

Case Report

Management of a traumatic avulsion of the right upper lobe bronchus

Jiwon V. Park^a, Aaron M. Williams^{b,c}, John W. Scott^{a,c}, Ross Blank^d, Rishindra M. Reddy^{a,c,*}^a University of Michigan Medical School, Ann Arbor, MI, United States of America^b Department of Cardiothoracic Surgery, Duke University Hospital, Durham, NC, United States of America^c Department of Surgery, Michigan Medicine, Ann Arbor, MI, United States of America^d Department of Anesthesia, Michigan Medicine, Ann Arbor, MI, United States of America

ARTICLE INFO

Keywords:

Lobectomy

Avulsion

Tracheobronchial injury

Thoracic trauma

ABSTRACT

Tracheobronchial injuries are rare but life-threatening and require early diagnosis, appropriate airway management, and emergent surgical intervention. We report a case of a post-traumatic, isolated avulsion of the right upper lobe bronchus in a 60-year-old woman involved in a pedestrian versus motor vehicle accident. After transfer from an outside hospital with a single lumen endotracheal tube and multiple right sided chest tubes with large air leaks, the patient was taken to the OR for bronchoscopy and surgical exploration. Intraoperatively, a complete avulsion of the right upper lobe was noted. Due to the extended time period from original injury and excellent reported functional status, our patient underwent completion lobectomy of the right upper lobe, primary bronchial repair, with an azygous vein flap.

Introduction

Tracheobronchial injury is a rare but life-threatening event in thoracic trauma associated with high morbidity and mortality. Of these injuries, the most common location is the right upper lobe bronchus [1,2]. While tracheobronchial injuries secondary to penetrating trauma are easily identified, injuries secondary to blunt trauma are difficult to diagnose [3]. Management of tracheobronchial injury is based on location of injury, extent of major airway destruction, comorbidities, and degree of distal pulmonary parenchymal destruction [4]. Here, we present the initial airway management and surgical approach of a complete blunt right upper lobe bronchus avulsion (Fig. 1). The Institutional Review Board (IRB) approved the study protocol and publication of data. The patient provided informed written consent for the publication of the study data.

Case description

A 60-year-old woman involved in a pedestrian versus motor vehicle crash was admitted to our Trauma Burn Intensive Care Unit from an outside hospital with concern for a right sided airway injury. At the outside hospital, she was initially alert and oriented in the emergency department but became hypoxemic and subsequently intubated. She then went into cardiac arrest. Return of spontaneous

* Corresponding author at: University of Michigan, Department of Surgery, 2101 Taubman Center, 1500 E. Medical Center Dr., Ann Arbor, MI 48109-5362, United States of America.

E-mail address: redrym@med.umich.edu (R.M. Reddy).

<https://doi.org/10.1016/j.tcr.2022.100660>

Accepted 21 May 2022

Available online 24 May 2022

2352-6440/© 2022 The Authors. Published by Elsevier Ltd. This is an open access article under the CC BY-NC-ND license (<http://creativecommons.org/licenses/by-nc-nd/4.0/>).

circulation was obtained after one round of advanced cardiovascular life support. Two chest tubes were placed for left sided pneumothorax and three chest tubes were placed for right sided pneumohemothorax. She had a significant right sided air leak with suspected right sided airway or lung injury, consistent with the findings of the chest X-ray and CT scan (Fig. 2A and B).

She was transferred to our trauma ICU for higher level care. The patient arrived intubated with a 6.0 mm single-lumen endotracheal tube (ETT) and initial ventilator settings were pressure-regulated volume control (PRVC)-intermittent mandatory ventilation (IMV) with a target tidal volume of 350 mL, set respiratory rate of 20 bpm, PEEP of 5 cm H₂O, and FiO₂ of 100% giving an arterial blood gas of 7.31/54/107. Of note, the patient was over-breathing the ventilator generating a total respiratory rate of 32 and inhaled tidal volumes in the 400–600 mL range with a large continuous leak from her right-sided chest tubes. In the first several hours of her admission, her ventilation deteriorated with subsequent blood gas of 7.17/79/93. A bedside bronchoscopy with a pediatric scope confirmed ETT position above the carina with blood and possible injury to the right upper lobe bronchus. Respiratory interventions included an increase in respiratory rate to 28 bpm and pharmacologic neuromuscular blockade with cisatracurium infusion. Gas exchange improved with these adjustments to 7.36/45/128. An 85% by volume leak persisted.

The catalogue of injuries at this point included bilateral pneumothoraces, suspected right upper lobe bronchus vs tracheal injury, flail chest with right sided fractures of ribs 1–9, right scapula fracture, right acromioclavicular joint separation, and T1–9 spinous process fractures. There was a multidisciplinary pre-operative discussion with the ICU, trauma surgery, thoracic surgery, ECMO service, and anesthesia teams regarding the safest approach and timing for surgical intervention. Given her large ongoing air leak and tenuous ventilatory status, the decision was to proceed to the operating room urgently for repeat bronchoscopy, esophagogastroduodenoscopy, placement of a left-sided double-lumen ETT, and right sided thoracotomy. In the operating room under anesthesia, the 6.0 mm single-lumen ETT was replaced by an 8.0 mm single lumen ETT over an airway exchange catheter (AEC). This allowed repeat bronchoscopy by the surgical team with an adult scope, which showed right upper lobe injury with at least partial transection of the right upper lobe bronchus. Subsequently, the ETT was replaced again with a 37 Fr silicone left-sided double-lumen endotracheal tube (DLT), now over a soft-tipped, extra firm AEC designed for DLTs. After placement of the DLT, the AEC was removed and a pediatric bronchoscope was placed through the bronchial lumen and directed into the left upper lobe bronchus. The DLT was then advanced over the bronchoscope into the left upper lobe bronchus. Repeat bronchoscopy through the tracheal lumen confirmed appropriate left-sided placement of the DLT and the bronchial cuff was inflated. Upon initiation of left-sided one-lung ventilation, the large air leak disappeared from the right-sided chest tubes. An esophagogastroduodenoscopy was also performed and did not reveal any evidence of esophageal injury.

For the duration of the surgery, the patient was on single left-lung ventilation. Ventilator settings were adjusted (PCV with a driving pressure of 20 cm H₂O, RR of 12–14 bpm, PEEP 5–8 cm H₂O, FiO₂ 80–100%). This resulted in tidal volumes in the 300–400 mL range while maintaining peak airway pressures less than or equal to 28 cm H₂O. Gas exchange was acceptable with the first ABG 7.23/66/61. A posterolateral thoracotomy was made to enter the 4th intercostal space and achieve access to the carina. The right upper lobe bronchus was noted to be completely avulsed (Fig. 3A). The thoracic and trauma teams discussed reattaching the bronchus versus

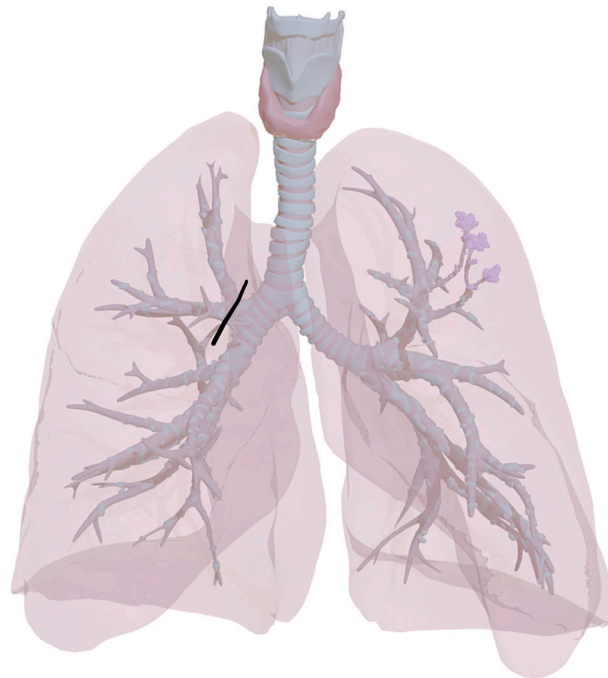


Fig. 1. Graphic of the anatomical location of right upper lobe avulsion in the patient. Black line depicts site of avulsion. “Anatomy of the airways” by E-learning UMCG is marked with CC BY-NC-SA 4.0.

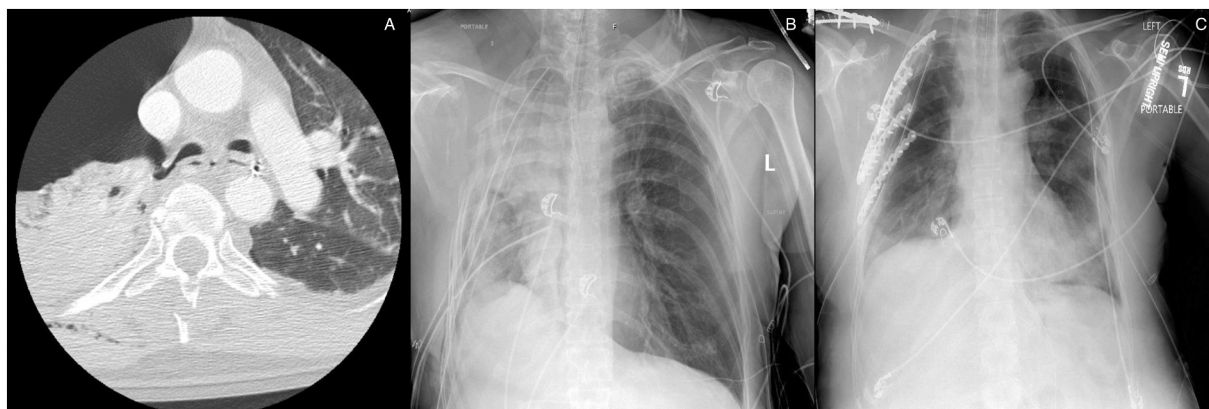

Fig. 2. (A) Axial CT showing complete transection of right mainstem bronchus. (B) Chest X-Ray showing extent of right lung collapse prior to surgery; (C) chest X-ray on post-op day 11.

resection, but given the long time period from the original injury, lack of ventilation and possible contusion versus pneumonia to the right upper lobe, and the patient's excellent baseline functional status, the decision was made to resect the right upper lobe. The right upper lobe bronchial stump was closed primarily with interrupted 4-0 vicryl sutures (Fig. 3B). The superior pulmonary vein branches to the upper lobe were isolated and divided. Next, the pulmonary artery branches to the upper lobe with the truncus and posterior segmental branches were isolated and divided. The major and minor fissures were resected with several stapler loads to complete the right upper lobectomy. After ensuring that the air leak tests were negative, the azygos vein was divided and oversewn over the top of the bronchial stump for protection (Fig. 3C). Following the azygos vein flap placement, rib fixation was performed. Numerous fractures were found throughout ribs 3, 4, 5, and 6. These were then plated across the rib interspaces using the Synthese© rib plating system. Afterwards, two chest tubes were placed through the old chest tube insertion sites.

At the end of the surgical case, the DLT was removed and replaced by a 7.5 single-lumen ETT, once again over an AEC. The patient was transported intubated to the trauma ICU. The first ABG in the ICU on two-lung ventilation was 7.37/42/326. The FiO₂ was weaned down from 100% to 40% and the air leak was 12%. The patient's chest tubes were placed to waterseal on post-operative day 4. The medial right and medial left chest tubes were removed on post-operative day 6. She was extubated on post-operative day 12, with the remaining chest tubes removed on post-operative day 13. She was on room air at time of discharge, post-operative day 25.

Discussion

Isolated tracheobronchial injuries (TBI) resulting from blunt trauma are rare but life-threatening. Most TBIs occur due to blunt or penetrating traumas. Diagnosis of TBIs must be established as quickly as possible, given the urgency to stabilize patients. Despite the importance of diagnosis, TBIs are not diagnosed immediately in 25% to 68% of patients [5]. Patients may be asymptomatic at time of injury or develop varied symptoms, such as tachypnea, respiratory distress, or hemoptysis. CT scan may show mediastinal air or avulsion in the tracheobronchial air column. CT scans are contraindicated if the patient is hemodynamically unstable. Additionally, subcutaneous emphysema and massive air leak through chest drainage are hallmarks for diagnosis of TBI [6]. Our patient was noted to have a massive air leak after placement of chest tubes due to avulsion of the right upper lobe.

The initial airway management is important for stabilization of acute TBIs. Due to the complexity of managing these TBIs, collaboration between anesthesiologists and surgeons is essential. Patients with high clinical suspicion of TBI should be intubated under flexible bronchoscopy to avoid further injury to the airway. In the operating room, our anesthesia team replaced the single-lumen ETT, which the patient arrived with from the outside hospital, with a left-sided DLT, over an AEC. After removing the AEC, a pediatric bronchoscope was directed into the left upper lobe bronchus. A bronchial cuff was inflated after repeated bronchoscopy through the tracheal lumen to confirm appropriate placement of the DLT. The technique described above was utilized to minimize the chance of the endotracheal tube inadvertently passing into the right upper lobe bronchus and thereby worsening the traumatic injury and/or making ventilation impossible. Alternatively, an ETT can be threaded over a 2–5 mm bronchoscope so that the bronchoscope can be passed into the bronchus distal to the defect and the cuff can be inflated distal to the tear, thus stopping the air leak [7]. A right-sided bronchial blocker was not an option for lung isolation in our patient given the proximal injury of the right upper lobe bronchus at the takeoff of the right upper lobe.

Surgical treatment for TBIs should be individualized depending on patient comorbidities, location of lesion, and time since injury. Although TBIs are generally treated surgically, there are reports of non-surgical, conservative treatment if the tracheal injury length is less than 4 cm [8–10]. The two main types of surgical management for TBIs are repair and resection. For simple transverse lacerations without airway devascularization, repair with interrupted, absorbable suture, such as 4-0 vicryl, is ideal. Of note, atelectasis of the upper lobe is not a contraindication to repair. If extensive damage is present, circumferential resection and end-to-end anastomosis is preferable to partial wedge resection [1]. Intraoperatively, after confirming in our patient that the right upper lobe bronchus was avulsed and the right upper lobe had some injury, we felt that repair could result in complications with poor healing at the anastomotic

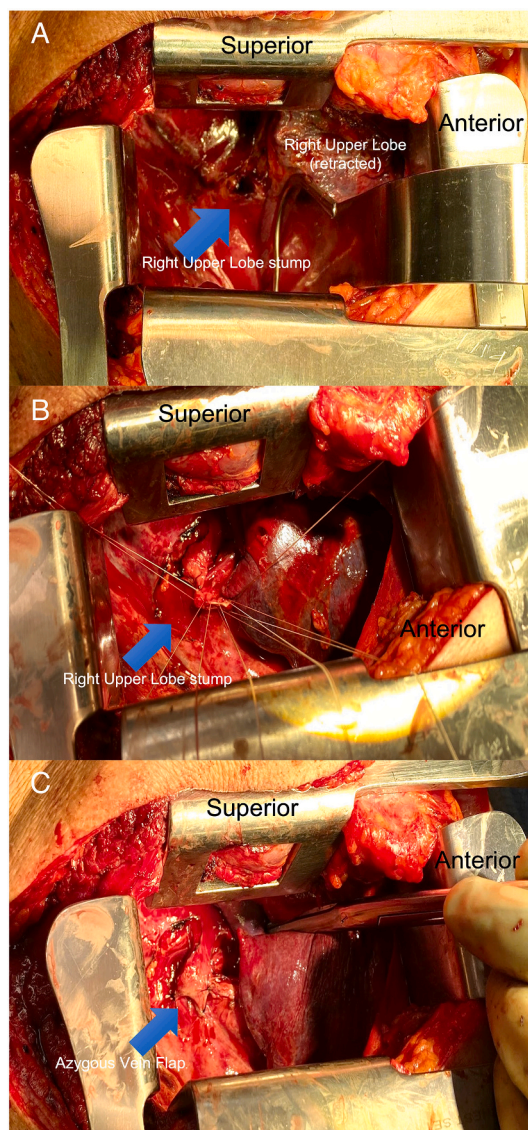


Fig. 3. Transection site after right upper lobectomy (A), oversewing of right mainstem bronchus (B), azygos vein flap placement (C).

site and therefore proceeded with an upper lobectomy. An azygos vein flap was done afterwards as there were limited options for intercostal muscle or pericardial fat, due to the extensive musculoskeletal injuries. Overall, successful management of complete bronchial resections requires early identification, proper airway management, and emergent surgical intervention.

Declaration of competing interest

J. Park, A. Williams, and J. Scott have no conflicts to disclose.

R. Reddy receives fees from Intuitive Surgical, Auris Surgical, Medtronic, and On Target Laboratories (none are relevant to this manuscript).

References

- [1] A. Rieth, E. Varga, T. Kovács, A. Otlakán, T. Németh, J. Furák, Contemporary management strategies of blunt tracheobronchial injuries, *Injury* 52 (Suppl 1) (2021) S7–S14, <https://doi.org/10.1016/j.injury.2020.07.026>.
- [2] Z. Zhao, T. Zhang, X. Yin, J. Zhao, X. Li, Y. Zhou, Update on the diagnosis and treatment of tracheal and bronchial injury, *J. Thorac. Dis.* 9 (2017) E50–E56.
- [3] E.S. Glazer, S.L. Meyerson, Delayed presentation and treatment of tracheobronchial injuries due to blunt trauma, *J. Surg. Educ.* 65 (2008) 302–308.
- [4] H.S. Grewal, N.S. Dangayach, U. Ahmad, S. Ghosh, T. Gildea, A.C. Mehta, Treatment of tracheobronchial injuries: a contemporary review, *Chest* 155 (3) (2019) 595–604, <https://doi.org/10.1016/j.chest.2018.07.018>.

- [5] A.C. Kiser, S.M. O'Brien, F.C. Detterbeck, Blunt tracheobronchial injuries: treatment and outcomes, *Ann. Thorac. Surg.* 71 (6) (2001) 2059–2065, [https://doi.org/10.1016/s0003-4975\(00\)02453-x](https://doi.org/10.1016/s0003-4975(00)02453-x).
- [6] T. Altinok, A. Can, Management of tracheobronchial injuries, *Eurasian J.Med.* 46 (3) (2014) 209–215, <https://doi.org/10.5152/eajm.2014.42>.
- [7] C. Prokakis, E.N. Koletsis, P. Dedeilias, F. Fligou, K. Filos, D. Dougenis, Airway trauma: a review on epidemiology, mechanisms of injury, diagnosis and treatment, *J. Cardiothorac. Surg.* 9 (2014) 117, <https://doi.org/10.1186/1749-8090-9-117>. Published 2014 Jun 30.
- [8] J. Jougon, M. Ballester, E. Choukroun, J. Dubrez, G. Reboul, J.F. Velly, Conservative treatment for postintubation tracheobronchial rupture, *Ann. Thorac. Surg.* 69 (2000) 216–220, [https://doi.org/10.1016/S0003-4975\(99\)01129-7](https://doi.org/10.1016/S0003-4975(99)01129-7).
- [9] A. Gomez-Caro, F.J. Moradiellos, V. Diaz-Hellin, et al., Role of conservative medical management of tracheobronchial injuries, *J. Trauma* 61 (2006) 1426–1435, <https://doi.org/10.1097/01.ta.0000196801.52594.b5>.
- [10] P. Carbognani, A. Bobbio, L. Cattelani, et al., Management of postintubation membranous tracheal rupture, *Ann. Thorac. Surg.* 77 (2004) 406–409.