

Systemic sclerosis with malignant acanthosis nigricans in a patient with gastric adenocarcinoma



Daniel A. Nadelman, BA,^a David Orbuch, MD,^b Sabina Sandigursky, MD,^c and Alisa N. Femia, MD^b
Ann Arbor, Michigan and New York, New York

Key words: acanthosis nigricans; gastric cancer; paraneoplastic; systemic sclerosis.

INTRODUCTION

Systemic sclerosis (SSc) is an idiopathic sclerosing condition that may affect both the skin and internal organs.¹ Although SSc has been associated with an increase in the development of malignant neoplasms, the disease can present in a paraneoplastic manner months to years after initial cancer diagnosis in rare cases.^{1,2} Malignant acanthosis nigricans is a rare paraneoplastic skin syndrome that presents with sudden onset of hyperpigmented velvety plaques, most commonly in intertriginous areas. Here, we report a case of newly acquired SSc and acanthosis nigricans in a patient with a 2-year history of gastric adenocarcinoma being treated with capecitabine.

CASE REPORT

A 34-year-old woman with a 6-year history of metastatic gastric adenocarcinoma presented with 2 months of abrupt-onset Raynaud phenomenon, fingertip ulcerations, stiffness in the joints of her hands, lethargy, and shortness of breath. The patient had been receiving capecitabine chemotherapy for 2 years before the onset of symptoms. Before this, she had been treated with 5-fluorouracil, oxaliplatin, epirubicin, and doxorubicin. Her cancer was responding moderately well to capecitabine. On examination, healing erosions of the finger tips (Fig 1, A), capillary dropout (Fig 1, B), and cutaneous sclerosis with pigmentary changes were present. Mild sclerodactyly extended to the metacarpophalangeal joints (Fig 2). Hyperpigmented velvety

Abbreviation used:

SSc: systemic sclerosis

plaques of the posterior neck, axillae, malar cheeks, forearms, and palms (Fig 3) consistent with acanthosis nigricans were present.

Laboratory testing results were notable for an elevated anti-RNA polymerase III of 59 units (normal, <20 units) and an antinuclear antibody of 1:640 in a speckled pattern. Results of other tests, including anti-SSa, anti-SSb, aldolase, myositis panel, C-reactive protein, anti-Scl 70, and anti-centromere, were unremarkable. Basic blood test results were unremarkable other than a hemoglobin level of 9.4 g/dL. The patient declined pulmonary function testing and chest imaging to evaluate for interstitial lung disease. An echocardiogram was unremarkable.

The patient met criteria for SSc based on 2013 European League Against Rheumatism/American College of Rheumatology scoring, which incorporates skin thickening, Raynaud phenomenon with fingertip ulcerations or scars, cutaneous telangiectasias, nail-fold capillary changes, and presence of autoantibodies relevant to SSc. Hydroxychloroquine therapy was initiated and resulted in improvement of her shortness of breath and fatigue, and nifedipine reduced the frequency of Raynaud phenomenon symptoms and resulted in healing of associated erosions and ulcerations. The patient continued

From the Department of Dermatology, University of Michigan Medical School, Ann Arbor^a; Ronald O. Perelman Department of Dermatology, New York University School of Medicine^b; and Division of Rheumatology, Department of Medicine, New York University School of Medicine.^c

Funding sources: None.

Conflicts of interest: None disclosed.

Correspondence to: Daniel A. Nadelman, BA, University of Michigan Medical School, 1500 E Medical Center Dr, Ann Arbor, MI, 48109. E-mail: dnadelma@med.umich.edu.

JAAD Case Reports 2019;5:1045-7.

2352-5126

© 2019 by the American Academy of Dermatology, Inc. Published by Elsevier, Inc. This is an open access article under the CC BY-NC-ND license (<http://creativecommons.org/licenses/by-nc-nd/4.0/>).

<https://doi.org/10.1016/j.jidcr.2019.10.003>

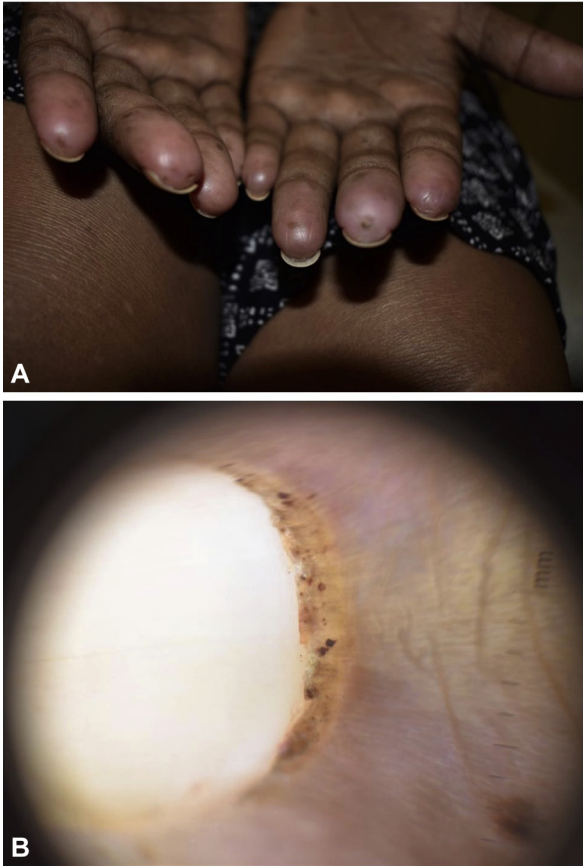


Fig 1. A, Healing erosions of the fingertips and (B) capillary dropout.

receiving capecitabine chemotherapy for her gastric adenocarcinoma without significant progression of the cancer.

DISCUSSION

Paraneoplastic syndromes are characterized as symptoms occurring in patients with cancer that are not directly related to tumor invasion or metastases. The precise mechanisms involved in the development of paraneoplastic syndromes are unknown, although it has been suggested that ectopic hormone production and cancer-induced autoimmunity play a role.^{3,4} It is estimated that 7% of patients with cancer experience paraneoplastic phenomena.³ Paraneoplastic syndromes may exhibit a variety of clinical manifestations, including endocrine, neurologic, and rheumatologic symptoms.^{3,4} Acanthosis nigricans may result as a paraneoplastic phenomenon in a number of different cancers; in these situations, unusual body surface areas may be affected, and the term *malignant acanthosis nigricans* is applied. Malignant acanthosis nigricans is particularly likely to occur in patients with gastric adenocarcinoma, as in the case of our patient.⁵

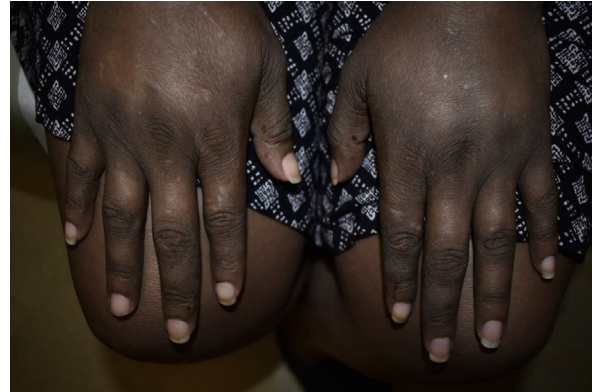

Fig 2. Mild sclerodactyly.

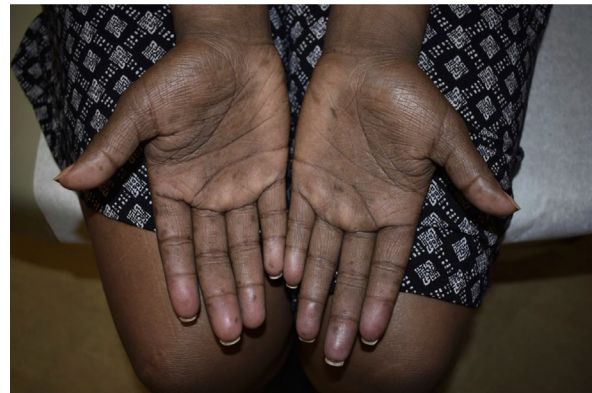

Fig 3. Hyperpigmented velvety plaques consistent with acanthosis nigricans.

Although polymyositis and dermatomyositis are more common rheumatologic disorders of paraneoplastic origin, SSc may also develop as a paraneoplastic phenomenon.⁴ Acute onset of SSc symptoms with rapid progression, as occurred in our patient, should raise suspicion for the possibility of a paraneoplastic etiology.^{4,6} The presence of RNA polymerase III autoantibodies is also consistent with paraneoplastic SSc; recent reports have shown a close association between RNA polymerase III autoantibodies and SSc in the setting of malignancy.⁷ This association is significant; in fact, patients with RNA polymerase III-positive SSc have been shown to be 5 times more likely to have an underlying neoplasm.² It has been suggested that RNA polymerase antigens are overexpressed in neoplastic cells, which, in turn, stimulates an immune response resulting in the formation of anti-RNA polymerase III antibodies.

Sudden onset and rapid progression of clinical symptoms is also characteristic of paraneoplastic, as opposed to idiopathic SSc. Anti-centromere and anti-Scl 70 antibodies, although typically elevated in idiopathic SSc, are notably absent in many paraneoplastic cases.⁴

Although several chemotherapeutic agents, including paclitaxel, bleomycin, and doxorubicin, have been implicated in the development of SSc, drug-induced SSc has not been shown to be associated with elevated RNA polymerase III autoantibodies as in the case of paraneoplastic SSc. Several case reports describe scleroderma-like changes in the setting of capecitabine chemotherapy, yet again, none of these cases showed positive RNA polymerase III autoantibodies.⁸ It therefore seems unlikely that SSc in our patient was induced by chemotherapy.

Paraneoplastic SSc with positive RNA polymerase III autoantibodies has been described in the setting of hematologic malignancies and colorectal, lung, pancreatic, and solid breast tumors.^{4,6} However, to the best of our knowledge, this patient is the first reported case of paraneoplastic SSc in the setting of gastric cancer. Our case supports the growing body of literature associating RNA polymerase III autoantibodies with paraneoplastic SSc.

REFERENCES

1. Shah AA, Hummers LK, Casciola-Rosen L, et al. Examination of autoantibody status and clinical features associated with cancer risk and cancer-associated scleroderma. *Arthritis Rheumatol*. 2015;67:1053-1061.
2. Shah AA, Rosen LC. Cancer and scleroderma: a paraneoplastic disease with implications for malignancy screening. *Curr Opin Rheumatol*. 2015;27(6):563-570.
3. Bajjens LW, Manni JJ. Paraneoplastic syndromes in patients with primary malignancies of the head and neck. Four cases and a review of the literature. *Eur Arch Otorhinolaryngol*. 2006;263(1):32-36.
4. Samotij D, Maj J, Reich A. Paraneoplastic systemic sclerosis associated with colorectal carcinoma. *Reumatologia*. 2018;56(3):194-198.
5. Yu Q, Li XL, Ji G, et al. Malignant acanthosis nigricans: an early diagnostic clue for gastric adenocarcinoma. *World J Surg Oncol*. 2017;15(1):208.
6. Onishi A, Sugiyama D, Kumagai S, Morinobu A. Cancer incidence in systemic sclerosis: meta-analysis of population-based cohort studies. *Arthritis Rheum*. 2013;65(7):1913-1921.
7. Shah AA, Xu G, Rosen A, et al. Brief report: anti-rnpc-3 antibodies as a marker of cancer-associated scleroderma. *Arthritis Rheumatol*. 2017;69(6):1306-1312.
8. Saif MW, Agarwal A, Hellinger J, Park DJ, Volkmann E. Scleroderma in a patient on capecitabine: is this a variant of hand-foot syndrome? *Cureus* 2016;8(6):e663.