



Case Report

# Treatment of refractory giant suprasellar arachnoid cyst by endoscopic expansion of a fenestrated stoma

Nobuaki Naito, Masahiro Nonaka, Mayuko Miyata, Katsuya Ueno, Takamasa Kamei, Akio Asai

Department of Neurosurgery, Kansai Medical University, Hirakata, Osaka, Japan.

E-mail: Nobuaki Naito - bonbon.0930.bonbon@gmail.com; \*Masahiro Nonaka - nonakamasa65@gmail.com; Mayuko Miyata - loved4clover@gmail.com; Katsuya Ueno - ueno1315@gmail.com; Takamasa Kamei - tkamei108@yahoo.co.jp; Akio Asai - aasaikun@hirakata.kmu.ac.jp



\*Corresponding author:  
Masahiro Nonaka,  
Department of Neurosurgery,  
Kansai Medical University,  
Hirakata, Osaka, Japan.  
nonakamasa65@gmail.com

Received : 24 January 2022

Accepted : 02 March 2022

Published : 31 March 2022

DOI

10.25259/SNI\_99\_2022

Quick Response Code:



## ABSTRACT

**Background:** Although endoscopic ventriculo-cysto-cisternostomy is considered to be effective for suprasellar arachnoid cysts, we encountered a giant suprasellar arachnoid cyst that recurred despite surgery using this technique.

**Case Description:** The patient was a 9-month-old boy. Magnetic resonance imaging revealed a huge suprasellar arachnoid cyst extending from the suprasellar region to the anterior skull base and both middle cranial fossa. First, an endoscopic procedure was performed to open the cyst wall between the right ventricle and the cyst and between the cyst and the prepontine cistern. Although the cyst initially shrank, it recurred over the next 2 months, and hence, we performed another endoscopic surgery. At the second surgery, both the previously opened stomas were found to be occluded. To reopen the cyst wall between the ventricle and the cyst, multiple holes were made with monopolar electrodes, and forceps were used to connect the holes by grasping and twisting the cyst wall so that the stoma was much larger than at the previous surgery. Postoperatively, the cyst shrank and the patient's head circumference stopped expanding.

**Conclusion:** Following the treatment of large cysts, the stoma might become narrower as the cyst shrinks, resulting in obstruction. Using the technique reported here might prevent occlusion of large arachnoid cysts.

**Keywords:** Endoscopic fenestration, Flexible endoscope, Suprasellar arachnoid cyst

## INTRODUCTION

The accepted treatment for suprasellar arachnoid cysts is creation of a window using an endoscope, while ventriculo-cysto-cisternostomy (VCC) in the arachnoid cyst<sup>[3]</sup> and cauterization of the cyst wall to reduce its size<sup>[12]</sup> are reported to be useful for preventing reocclusion of the cyst. However, no standard treatment has been established for cases that recur even after surgery using these methods. We created a large stoma in the cyst wall between the cyst and ventricle in a patient with the treatment of refractory giant suprasellar arachnoid cyst. In this report, we describe the methods and results of the procedure.

## CASE REPORT

The patient was a 9-month-old boy born by normal delivery at 38 weeks.

This is an open-access article distributed under the terms of the Creative Commons Attribution-Non Commercial-Share Alike 4.0 License, which allows others to remix, transform, and build upon the work non-commercially, as long as the author is credited and the new creations are licensed under the identical terms.

©2022 Published by Scientific Scholar on behalf of Surgical Neurology International

At the 4-month checkup, his head circumference was large for age and his neck was not yet fixed.

At 5 months, his head circumference had enlarged to 46.9 cm and he was unable to raise his head in the prone position and did not show grasping movements.

Magnetic resonance imaging (MRI) of the head showed a huge arachnoid cyst extending from the suprasellar region to the anterior skull base and middle cranial fossa bilaterally [Figure 1], and hence, the child was admitted to the hospital for surgical treatment at the age of 9 months. There was no other medical history to be noted. At the time of admission, his head circumference was 50 cm [Figure 2], and he had left internal strabismus.

### Surgical findings (at the first surgery)

A flexible endoscope (Olympus VEF-V) was inserted through the right anterior horn of the lateral ventricle, and the cyst wall was seen through the foramen of Monro [Figure 3a]. The cyst wall was perforated and dilated with a balloon catheter followed by coagulation and reduction of the cyst wall with an Elliquence Surgi-Max radiofrequency generator (Elliquence LLC, Baldwin, NY, USA) and RAF electrodes (Aims Co, Osaka, Japan) [Figure 3b]. The endoscope was advanced into the cyst for observation, which indicated the absence of a communication with the prepontine cistern. The cyst wall was perforated and expanded with a Phycon expander balloon catheter (Fuji Systems Co., Japan) [Figure 3c], and a stoma was established between the cyst and the prepontine cistern [Figure 3d].

### Postoperative course

Postoperative MRI 2 days after the surgery showed reduction in the size of the cyst, and the patient was discharged without complications. The patient was subsequently monitored on an outpatient basis. However, 2 months later, at the age of 11 months, MRI again showed enlargement of the arachnoid cyst, leading to the suspicion of obstruction of the stoma.

### Surgical findings (at the second surgery)

As in the first surgery, a flexible endoscope (Olympus VEF-V) was introduced into the right anterior horn of the lateral ventricle. The cyst wall was seen through the foramen of Monro and the previous stoma was seen to be occluded [Figure 4a]. Multiple holes were created in the cyst wall with an RAF electrode [Figures 4b and c] and the holes were enlarged by grasping and nibbling the cyst wall with biopsy forceps [Figures 4d-f]. When the endoscope was advanced inside the cyst, the previous stoma to the prepontine cistern was also found to be closed [Figure 4g]. Hence, two mechanical fenestrations without cauterization were

made in this area, and each perforation was expanded with a Phycon expander balloon catheter to form a single large hole [Figure 4h]. In addition, the edges of the stoma were coagulated.

### Postoperative course

MRI performed immediately after the surgery showed reduction in the size of the cyst. MRI at 3 months and 8 months after the second surgery showed diminution of the cyst over time. Developmentally, the child was able to walk unaided at the age of 1 year and 6 months and babbling increased at 1 year and 9 months. His head circumference was approximately within the normal range.

### IRB/ethics committee approval

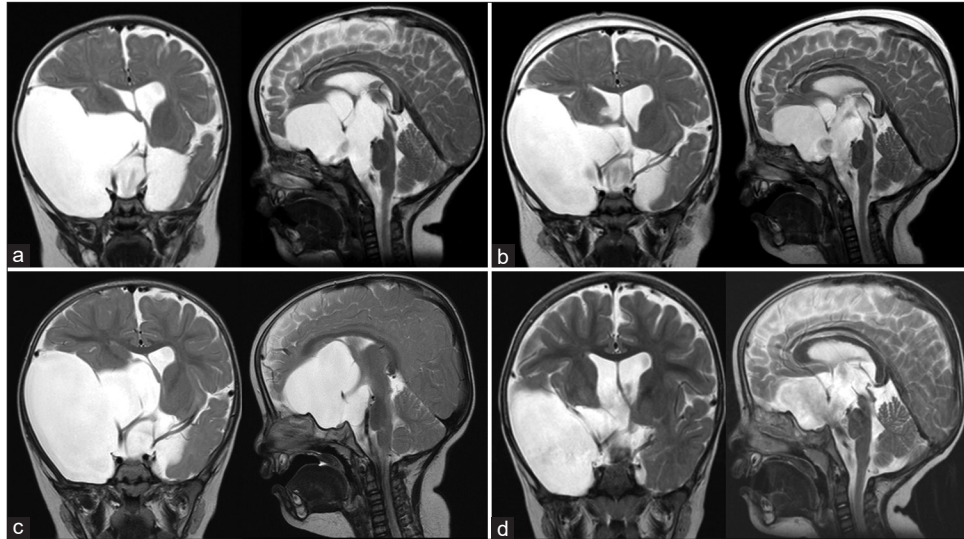
This study has been approved by the Ethical Review Committee of Kansai Medical University (No. 2019302).

## DISCUSSION

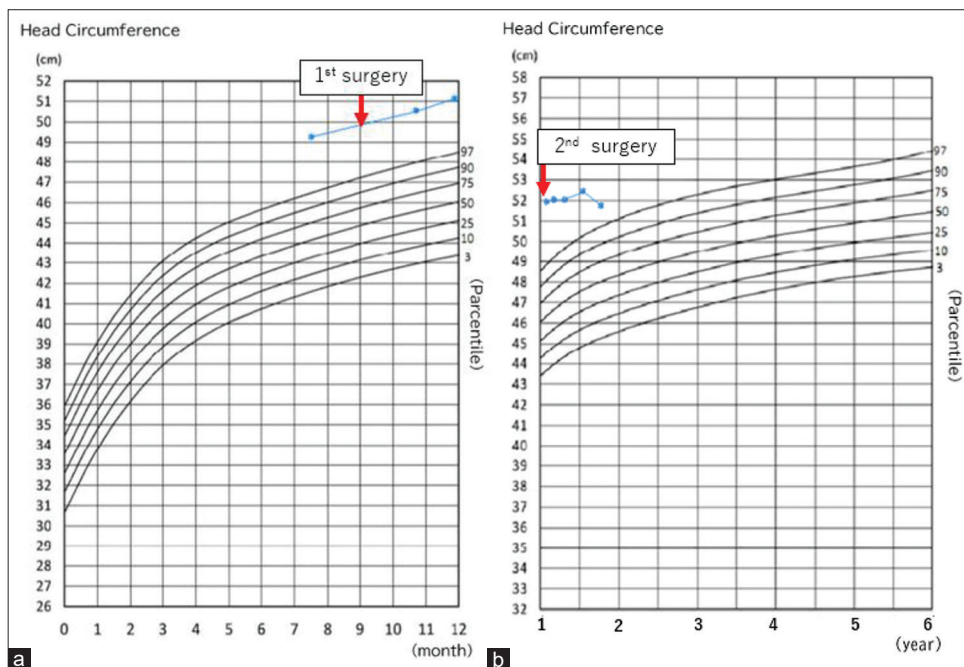
We described here a congenital giant suprasellar arachnoid cyst extending to the anterior skull base and middle cranial fossa, which was discovered due to an enlarged head circumference and developmental delay. Endoscopic cyst fenestration was performed, although the patient required a second endoscopic surgery due to cyst recurrence. Suprasellar arachnoid cysts account for about 5–12% of intracranial arachnoid cysts<sup>[5,9]</sup> and 8–15% of arachnoid cysts that grew and became symptomatic were reported to be suprasellar arachnoid cysts. Enlargement of these cysts can cause visual disturbances and hydrocephalus due to the close proximity to the optic chiasma and third and lateral ventricles. The treatment options include craniectomy, insertion of a shunt, and endoscopic fenestration.<sup>[1,3,7,11-13]</sup>

Although shunt insertion can be effective, there is a risk of postoperative infection and shunt malfunction. When an arachnoid cyst is shunted, the cyst shrinks or disappears, and the cerebrospinal fluid (CSF) that flows into the cyst flows out through the shunt. If the shunt malfunctions, however, the diagnosis is delayed because the cyst does not increase in size and only intracranial pressure rises, and shunt reconstruction is difficult in this situation because there is no place to insert the proximal catheter.<sup>[10]</sup> Thus, there is an opinion that shunting should not be the first choice of treatment for arachnoid cysts.<sup>[10]</sup>

Endoscopic fenestration was associated with the fewest complications in the previous reports, although the anatomical location of the blood vessels and cranial nerves in the cistern must be understood when fenestrating the



**Figure 1:** T2-weighted MRI of the head (axial and sagittal views). (a) Before the first surgery, (b) immediately after the first surgery, (c) at the time of recurrence, and (d) 8 months after the second surgery.

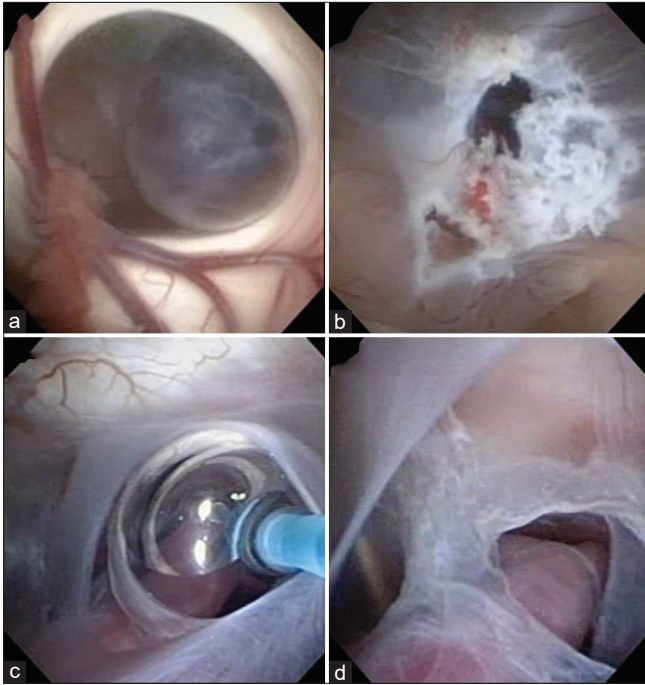


**Figure 2:** Head circumference curve. (a) From birth to 12 months. (b) From 12 months.

wall between the cyst and the cistern.<sup>[2]</sup> In the present case, we performed VCC as the initial treatment. We coagulated the edges of the stomas to prevent adhesion. El-Ghandour reported that the cysts shrank in 81% of ventriculocystostomy (VC) cases and 100% of VCC cases.<sup>[4]</sup> The reason for the greater efficacy of VCC is that the CSF is transported to the ventricles and cisterns through the two stomas, which facilitates drainage of the CSF and reduces the risk of recurrence.<sup>[4,8]</sup>

In this case, although VCC was performed as the initial treatment, the cyst recurred. We hypothesized that as the cyst shrank, the cyst walls began to overlap, resulting in stomal adhesion and obstruction.

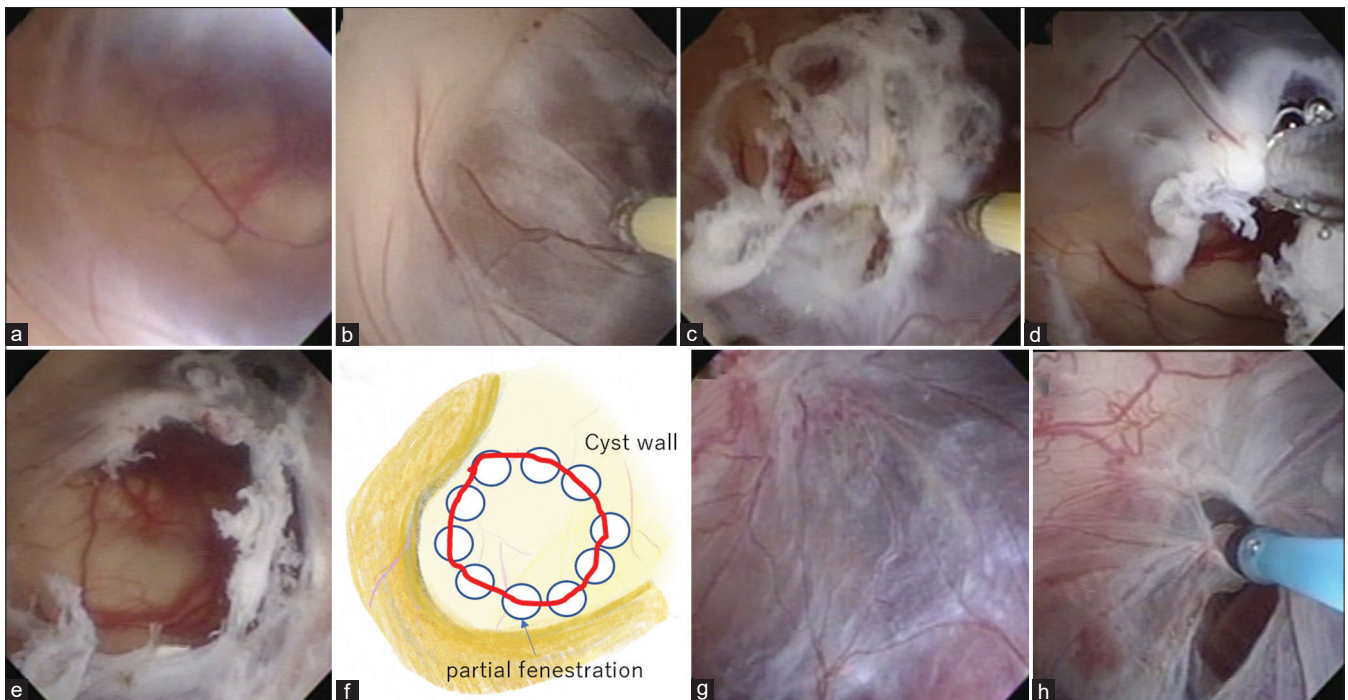
Various methods have been reported for the prevention of stomal occlusion, including cauterization of the cyst itself to reduce its size<sup>[12]</sup> and partial resection of the cyst wall using two endoscopes.<sup>[6]</sup> Although the simple VCC method was not effective in the first attempt in this case, considering the



**Figure 3:** Intraoperative endoscopic findings during the first surgery. (a) The cyst wall was seen through the foramen of Monro. (b) Cauterization and perforation of the cyst wall was performed using a monopolar electrode (RAF electrode, Aims Co., Japan). (c) A balloon catheter was used to expand the stoma. (d) Fenestration between the cyst and the prepontine cistern.

method of inserting two endoscopes as being too invasive, we used the method of creating a large stoma by opening multiple small holes with electrodes and connecting them with biopsy forceps. This method can be safely used in areas where there are no important blood vessels or nerves, such as the wall between the ventricles and the cyst. However, we did not use this method to open the cistern from the cyst, as there are nerves and blood vessels running through the cistern and these structures could have been damaged. In the past, Caemaert *et al.* have emphasized the importance of a large window and presented a method of making a large window in a cyst by making multiple holes with a YAG laser.<sup>[1]</sup> However, YAG laser equipment is expensive, and limited facilities are currently using this device for neuroendoscopy. On the other hand, this paper shows that a similar procedure can be performed with a radiofrequency coagulator. The depth of penetration of the high radiofrequency generator we used (Elliquence Surgi-Max, <https://www.elliquence.com/products/surgimax/>) is 0.2 mm, which is lower than YAG's 3 mm, and we believe that it can be used safely.

The patient did well after the second surgery, and no untoward effects were observed at the 1-year follow-up. Although there is no fixed opinion on the size of the window for endoscopic fenestration of the arachnoid cyst wall, our experience suggests that in cases with a very large cyst, the hole should be made as large as possible because



**Figure 4:** Intraoperative endoscopic findings during the second surgery. (a) Obstructed cyst wall. (b) Cauterization and perforation of the cyst wall. (c) Multiple perforations were performed. (d and e) The cyst wall was grasped by biopsy forceps and the hole was enlarged. (f) Schema of cyst wall fenestration enlargement. (g) Reocclusion of the space between the cyst and the prepontine cistern. (h) Enlargement of the stoma to the prepontine cistern using a balloon catheter.

the cyst wall might overlap and cause stomal occlusion as it shrinks.

## CONCLUSION

In this case, we first performed VCC and coagulation of the cyst wall for a huge arachnoid cyst extending from the suprasellar region to the anterior and middle cranial fossa, although the cyst re-expanded due to obstruction of the stomas. By creating another larger fenestration, good stomal patency and smooth drainage of CSF were obtained.

## Declaration of patient consent

Institutional Review Board (IRB) permission obtained for the study.

## Financial support and sponsorship

Grant-in-Aid from the Research Committee of CNS Degenerative Diseases, Research on Policy Planning and Evaluation for Rare and Intractable Diseases, Health, Labour and Welfare Sciences Research Grants, The Ministry of Health, Labour, and Welfare, Japan (20FC1049).

## Conflicts of interest

There are no conflicts of interest.

## REFERENCES

1. Caemaert J, Abdullah J, Calliauw L, Carton D, Dhooge C, van Coster R. Endoscopic treatment of suprasellar arachnoid cysts. *Acta Neurochir (Wien)* 1992;119:68-73.
2. Chen Y, Fang HJ, Li ZF, Yu SY, Li CZ, Wu ZB, *et al.* Treatment of middle cranial fossa arachnoid cysts: A systematic review and meta-analysis. *World Neurosurg* 2016;92:480-90.e482.
3. Crimmins DW, Pierre-Kahn A, Sainte-Rose C, Zerah M. Treatment of suprasellar cysts and patient outcome. *J Neurosurg* 2006;105:107-14.
4. El-Ghandour NM. Endoscopic treatment of suprasellar arachnoid cysts in children. *J Neurosurg Pediatr* 2011;8:6-14.
5. Fewel ME, Levy ML, McComb JG. Surgical treatment of 95 children with 102 intracranial arachnoid cysts. *Pediatr Neurosurg* 1996;25:165-73.
6. Fujio S, Bunyamin J, Hirano H, Oyoshi T, Sadamura Y, Bohara M, *et al.* A novel bilateral approach for suprasellar arachnoid cysts: A case report. *Pediatr Neurosurg* 2016;51:30-4.
7. Gangemi M, Colella G, Magro F, Maiuri F. Suprasellar arachnoid cysts: Endoscopy versus microsurgical cyst excision and shunting. *Br J Neurosurg* 2007;21:276-80.
8. Gangemi M, Seneca V, Colella G, Cioffi V, Imperato A, Maiuri F. Endoscopy versus microsurgical cyst excision and shunting for treating intracranial arachnoid cysts. *J Neurosurg Pediatr* 2011;8:158-64.
9. Gosalakkal JA. Intracranial arachnoid cysts in children: A review of pathogenesis, clinical features, and management. *Pediatr Neurol* 2002;26:93-8.
10. Laviv Y, Michowitz S. Acute intracranial hypertension and shunt dependency following treatment of intracranial arachnoid cyst in a child: A case report and review of the literature. *Acta Neurochir (Wien)* 2010;152:1419-23; discussion 1422-13.
11. Maher CO, Goumnerova L. The effectiveness of ventriculocystocisternostomy for suprasellar arachnoid cysts. *J Neurosurg Pediatr* 2011;7:64-72.
12. Sood S, Schuhmann MU, Cakan N, Ham SD. Endoscopic fenestration and coagulation shrinkage of suprasellar arachnoid cysts. Technical note. *J Neurosurg* 2005;102:127-33.
13. Wang JC, Heier L, Souweidane MM. Advances in the endoscopic management of suprasellar arachnoid cysts in children. *J Neurosurg* 2004;100:418-26.

**How to cite this article:** Naito N, Nonaka M, Miyata M, Ueno K, Kamei T, Asai A. Treatment of refractory giant suprasellar arachnoid cyst by endoscopic expansion of a fenestrated stoma. *Surg Neurol Int* 2022;13:112.