

Look what else we found - clinically significant abnormalities detected during routine ROP screening

Chaitra Jayadev, Anand Vinekar, Noel Bauer¹, Shwetha Mangalesh, Padmamalini Mahendradas, Vasudha Kemmanu, Ashwin Mallipatna, Bhujang Shetty

Purpose: The purpose of this study was to report the spectrum of anterior and posterior segment diagnoses in Asian Indian premature infants detected serendipitously during routine retinopathy of prematurity (ROP) screening during a 1 year period. **Methods:** A retrospective review of all Retcam (Clarity MSI, USA) imaging sessions during the year 2011 performed on infants born either <2001 g at birth and/or <34.1 weeks of gestation recruited for ROP screening was performed. All infants had a minimum of seven images at each session, which included the dilated anterior segment, disc, and macula center and the four quadrants using the 130° lens. **Results:** Of the 8954 imaging sessions of 1450 new infants recruited in 2011, there were 111 (7.66%) with a diagnosis other than ROP. Anterior segment diagnoses seen in 31 (27.9%) cases included clinically significant cataract, lid abnormalities, anophthalmos, microphthalmos, and corneal diseases. Posterior segment diagnoses in 80 (72.1%) cases included retinal hemorrhages, cherry red spots, and neonatal uveitis of infective etiologies. Of the 111 cases, 15 (13.5%) underwent surgical procedures and 24 (21.6%) underwent medical procedures; importantly, two eyes with retinoblastoma were detected which were managed timely. **Conclusions:** This study emphasizes the importance of ocular digital imaging in premature infants. Visually significant, potentially life-threatening, and even treatable conditions were detected serendipitously during routine ROP screening that may be missed or detected late otherwise. This pilot data may be used to advocate for a possible universal infant eye screening program using digital imaging.

Key words: Community, digital imaging, Karnataka Internet-assisted Diagnosis of Retinopathy of Prematurity, retinopathy of prematurity, telemedicine, universal screening

Wide-field digital imaging for retinopathy of prematurity (ROP) screening is competing with the standard binocular indirect ophthalmoscopic examination as the possible new “gold standard.”^[1,2] Images allow an objective record of the retinal condition and have several medico-legal, teaching, counseling, and research advantages especially in the context of screening programs catering to the outreach which lack ROP specialists.^[3-7]

A structured sequence of imaging modified from the photo ROP study^[8,9] recommendations allows comprehensive capture of the anterior and posterior segments wherein both anatomical and pathological entities are recorded. Although the primary intention of photo-documentation of the retina during such screening is to detect ROP, the diagnosis of other conditions is coincidentally possible during routine screening. These could be important reasons for referral for further management. This has so far not been well-documented in literature.

We report the spectrum of anterior and posterior segment diagnoses that were detected serendipitously during routine ROP screening in a one year period. Our observations give us an insight into the “other” ocular conditions that may affect

premature infants. Universal ocular screening of all infants at birth is a recently suggested program by the Indian government and data from this study will help strengthen the argument for such an exercise.^[10,11]

Materials and Methods

This is a retrospective review performed at a tertiary care center, which manages a tele-ROP program that performs over 1200 imaging sessions every month. All images captured between 1st January, 2011 and 31st December, 2011 were reviewed and analyzed for this study.

All infants who were imaged were born <2001 g at birth and/or at < 34.1 weeks of gestational age and were recruited for ROP screening from one of the enrolled neonatal intensive care units (NICUs) across the state of Karnataka, India. All images were captured by level three accredited pediatric retinal imaging technicians on a Retcam Shuttle (Clarity MSI, CA, USA).^[3] All recruited infants had at least one imaging session between 2 and 14 weeks of postnatal age and the total number of imaging sessions depended on the prescribed protocol for ROP screening.^[12]

All infants had undergone a minimum of seven images per eye at each session. This included the dilated anterior segment, disc, and macula center and the four peripheral quadrants using the 130° lens.^[3] For this study, all images of all sessions were reviewed and analyzed for the presence or absence of “other” (non-ROP) ocular conditions by a pediatric retinal specialist. Hospital records of infants who received cross-consultation between the ROP services and other departments were retrieved and the clinical outcome and treatment details, where present were recorded.

Access this article online

Website:
www.ijo.in

DOI:
10.4103/0301-4738.159859

Quick Response Code:



Department of Pediatric Retina, Narayana Nethralaya Postgraduate Institute of Ophthalmology, Bengaluru, Karnataka, India, ¹Department of Ophthalmology, University of Maastricht, Maastricht, Limburg, Netherlands

Correspondence to: Dr. Anand Vinekar, Department of Pediatric Retina, Narayana Nethralaya Postgraduate Institute of Ophthalmology, Bengaluru, Karnataka, India. E-mail: anandvinekar@yahoo.com

Manuscript received: 31.12.14; **Revision accepted:** 20.04.15

Results

During the study period, 10,236 imaging sessions were completed, of which 8954 sessions of 1450 premature infants were eligible for analysis. In all, 127,856 images of these eligible infants were analyzed from the archived database. Of the 1450 infants, 984 (67.9%) were male and 466 (32.1%) were female. Infants enrolled from urban NICUs were 609 (42%) and the remaining 841 (58%) were from rural centers.

Of the 1450 enrolled infants, 111 (7.66%) were positive for diagnoses other than ROP. These diagnoses were made within 30 days of life in 95 babies (85.6%), between 31 and 90 days of birth in 13 babies (11.7%) and older than 90 days of life in 3 infants (2.7%), respectively.

Of the 111 cases, 31 (27.9%) were anterior segment, lid, and adnexal conditions whereas the remaining 80 (72.1%) were posterior segment pathologies. The most common anterior pathology was congenital cataract [Fig. 1], which was observed in 14 cases (45.2% of all anterior segment) and was bilateral in 12 infants. The most common posterior segment pathology was retinal hemorrhages [Fig. 2] seen in 33 infants (41.3% of all posterior segment), which was further sub-classified into grade 1 (10 infants), grade 2 (14 infants), and grade 3 (9 infants) based on Egge's classification.^[13]

Of significance are 15 cases of neonatal uveitis, which were of infective etiology included toxoplasma retinochoroiditis (6) [Fig. 3], fungal (2), bacterial (3), *Mycobacterium tuberculosis* (1), rubella retinitis (1), *Cytomegalovirus* (1), and varicella retinitis (1) and were managed by the ocular inflammation services of the institute. Other retinal vascular conditions detected included familial exudative vitreoretinopathy (12), Coats disease (2) [Fig. 4], and incontinentia pigmenti (1) [Fig. 5]. Importantly, two eyes with retinoblastoma [Fig. 6] were detected which were clinically proven and managed. Cherry red spots [Fig. 7] were seen in 15 infants and these were referred to a neonatologist for a metabolic and storage disorder evaluation and management.

Of the 111 cases, 15 (13.5%) underwent surgical procedures (12 cataracts, 1 corneal pathology, and 2 retinoblastoma) and 24 (21.6%) underwent medical procedures including laser

photocoagulation (15 uveitis, 5 cornea, 3 familial exudative vitreoretinopathy, and 1 incontinentia pigmenti). Hence overall, 35.1% of all positive diagnoses underwent intervention. Conditions not amenable to any intervention underwent early visual rehabilitation (anophthalmos [Fig. 8], microphthalmos) or observation (hemorrhages and lid abnormalities).

Discussion

The study highlights the prevalence of ocular pathologies in premature Asian Indian infants born below 2000 g in a multicenter setting in Southern India. ROP screening is now widely regarded as an "essential newborn" service by the Government of India; under its Rashtriya Bal Swasthya Karyakram (RBSK), 2013, universal screening of all infants has been advocated with limited data on ocular diseases of the newborn. This manuscript reports the "other" diseases that may exist in premature infants, thereby emphasizing the need for the treating neonatologist and ophthalmologist to have a high degree of clinical suspicion in all cases that undergo routine ROP screening. In this series, 7.66% of all premature infants born <2000 g had positive findings other than ROP.

Significantly, over one-third of the diagnoses, that is, 35.1%, were amenable to surgical (13.5%) or medical (21.6%) intervention. Owing to the wide-field digital imaging used for ROP screening, these conditions are more easily documented and followed up. In our study, multiple consultations with subspecialties such as the pediatric uveitis, pediatric ophthalmology, and retinoblastoma services were possible by sharing these images on our tele-ROP platform. It is important to emphasize that in addition to the posterior segment images obtained with the standard 130° lens, it is essential to capture the anterior segment as well. In some conditions, we have also imaged the face of the child for lesions of the lid and adnexa. Appropriate and adequate imaging provides successful cross-consultation and the ability to manage multiple diseases by relevant specialists.

In our setting, images are captured by accredited level three technicians whose chief proficiency lies in diagnosing and "triage-reporting" ROP.^[3] However, with increasing expertise, experience, and the principle of pattern recognition, it is also

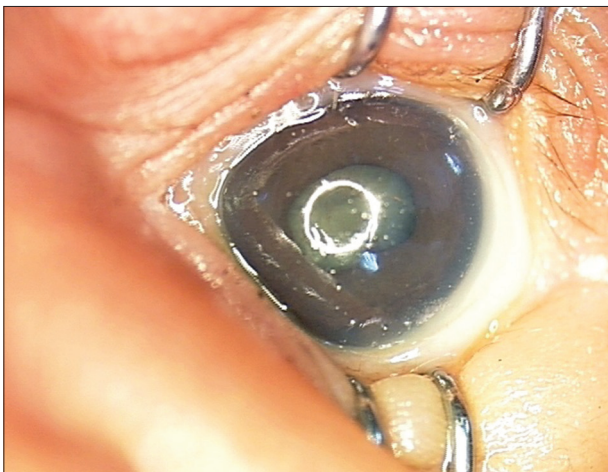


Figure 1: Congenital cataract - the most common anterior segment abnormality detected

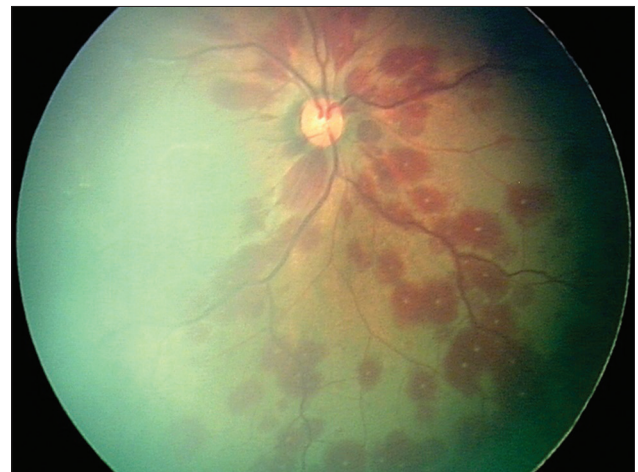

Figure 2: White-centered superficial retinal hemorrhages - the most common posterior segment abnormality detected

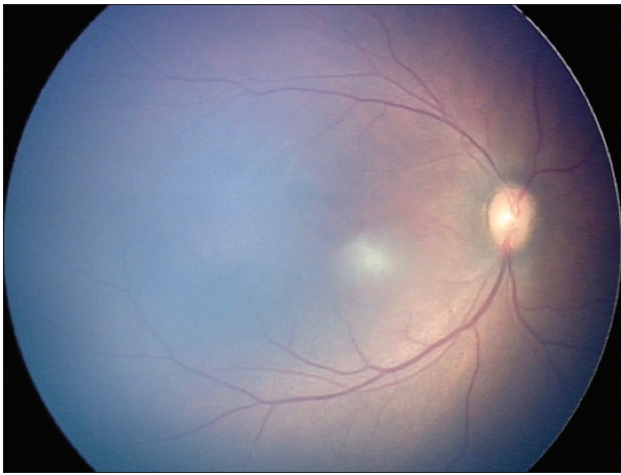


Figure 3: Toxoplasma retinochoroiditis (active)

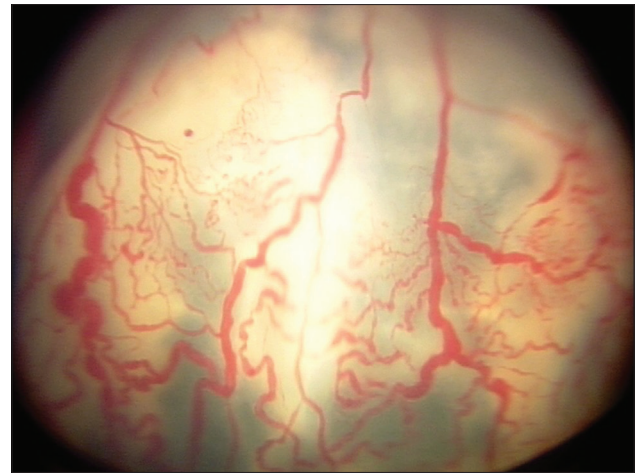


Figure 4: Coats disease

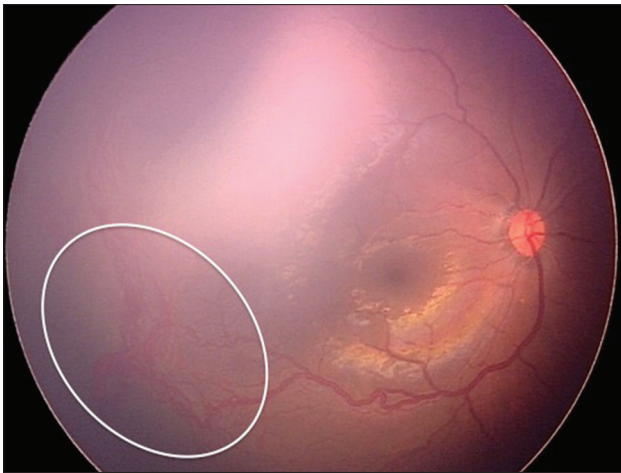


Figure 5: Incontinentia pigmenti with neovascularization (white circle)

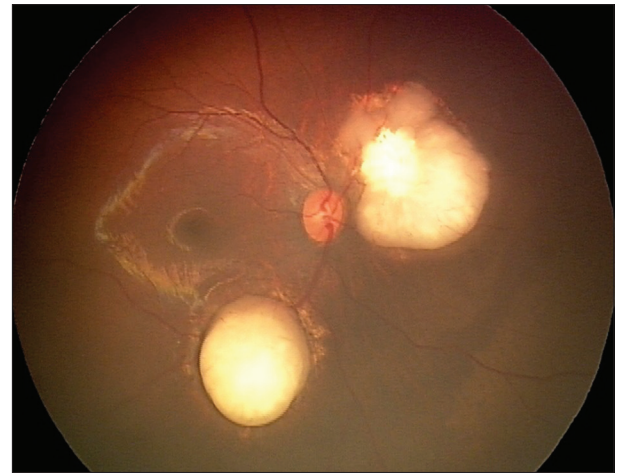


Figure 6: Retinoblastoma incidentally imaged during retinopathy of prematurity screening

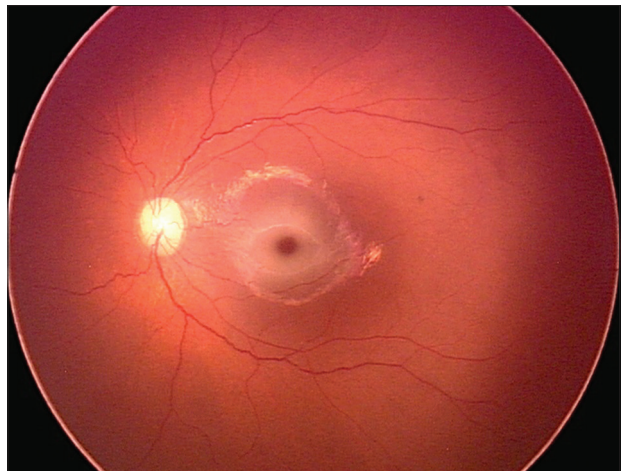


Figure 7: Cherry red spot in an infant with storage disorder

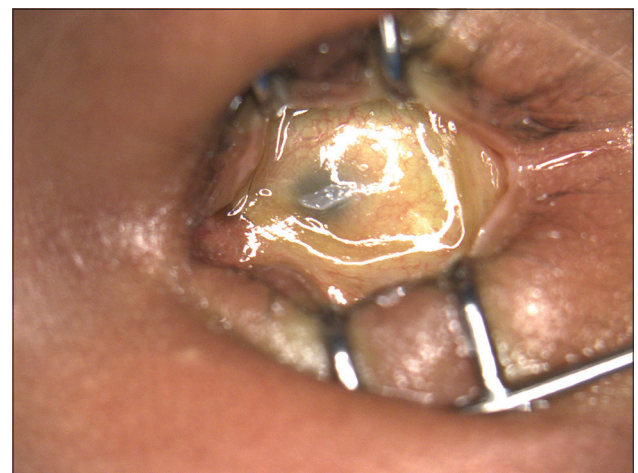

Figure 8: Anophthalmos

possible to report other diagnoses as well. In this study, a specialist retrospectively reviewed all images captured during the study period and found 111 of 1450 (7.66%) infants had one or more “positive” findings. During the same period the imaging technicians had diagnosed all these 111 cases as

“abnormal” and additionally reported 7 more cases (5.93%) as “abnormal” due to an “altered retinal pigmentation” which were deemed “within physiological limits” by the specialist. Despite these “false positives,” it is reassuring that

technicians did not miss any of the other cases that were marked "positive" by the specialist. Importantly, all cases eventually requiring medical or surgical intervention had been marked as "abnormal" by the technicians. Wide-field digital imaging shows promise as a primary screening tool for all infant ocular conditions.

It provides an interesting observation that the anterior segment abnormalities are far less common than posterior segment conditions during the 1st few months of a premature infant's life. We found 72% of all positive cases were posterior segment compared to 28% of anterior segment pathologies, despite the apparently more obvious nature of anterior segment entities. Neonatal uveitis was seen in 13.51% of all the positive diagnosis. To our best knowledge, this is the largest series of such an entity to be reported in this age-cohort and highlights an important, probably under-reported condition. Again, the role of imaging in classifying the etiology of the uveitis entities is highlighted. Moreover, co-managing some of the ocular conditions with neonatologists, pediatricians, and oncologists were easier owing to an image-based follow-up. This included syndromic associations in cherry red spots, deafness, and cardiac abnormalities in TORCH infections and retinoblastoma management.

The strength of the study lies in its relatively large numbers. Over 8954 sessions of 1450 premature infants accounting for 127,856 Retcam images were analyzed. Secondly, the enrolled cohort was from urban and rural centers thus providing a more holistic prevalence of these ocular entities. Thirdly, the study links the image-based diagnosis with real world clinical and treatment outcomes of the co-managed entities. To the best of our knowledge, such a large series of image-based recording of infant ocular conditions has not been described previously.

The limitations include its retrospective nature of analysis and the fact that the exact timeline of appearance of some pathologies cannot be ascertained since infants were imaged on the frequency of the ROP screening protocol and these were merely serendipitous observations. Moreover, no term infants were imaged and hence the general prevalence of ocular conditions in infants cannot be compared. A longitudinal study including all healthy term infants universally provides that data.^[14]

From a public health perspective, there are two considerations:

- Premature infants are a sicker cohort compared to term infants and suffer from several co-morbid systemic conditions. It may explain a relatively higher incidence of ocular conditions. Although arguably entities like retinal hemorrhage may resolve spontaneously, its relative amblyogenic potential cannot be ruled out.^[15,16] In India, with 3.5 million premature infants born annually, extrapolating our study results, 7.66% or 266,000 infants are likely to have abnormalities of which 93,366 (35.1%) are likely to require intervention. This is an important factor when considering universal screening in our country
- Wide-field digital ocular imaging performed by trained and accredited technicians provides a feasible and accurate method of screening of premature infants for all ocular pathologies, besides ROP, in the neonatal period. It provides an objective record that allows cross-consultation of experts with appropriate and comprehensive management of these

pathologies. This is an important strategy for ophthalmic screening of infants that must be considered during the implementation of the RBSK (universal screening) program.

Conclusions

Wide-field digital imaging is an excellent tool to detect and monitor anterior and posterior pathologies in premature infants in the neonatal period. Besides ROP, these babies are also prone to several other conditions including those that are amenable to medical and surgical correction. The treating team of physicians including the neonatologist, pediatrician, neonatal nurse, and the ophthalmologist must maintain a high degree of clinical suspicion during the screening and care of these infants.

References

1. Trese MT. What is the real gold standard for ROP screening? *Retina* 2008;28:51-2.
2. Vinekar A, Jayadev C, Bauer N. Need for telemedicine in retinopathy of prematurity in middle-income countries: E-ROP vs KIDROP. *JAMA Ophthalmol* 2015;133:360-1.
3. Vinekar A, Gilbert C, Dogra M, Kurian M, Shainesh G, Shetty B, *et al.* The KIDROP model of combining strategies for providing retinopathy of prematurity screening in underserved areas in India using wide-field imaging, tele-medicine, non-physician graders and smart phone reporting. *Indian J Ophthalmol* 2014;62:41-9.
4. Vinekar A, Avadhani K, Dogra M, Sharma P, Gilbert C, Braganza S, *et al.* A novel, low-cost method of enrolling infants at risk for Retinopathy of Prematurity in centers with no screening program: The REDROP study. *Ophthalmic Epidemiol* 2012;19:317-21.
5. Hungi B, Vinekar A, Datti N, Kariyappa P, Braganza S, Chinnaiah S, *et al.* Retinopathy of Prematurity in a rural Neonatal Intensive Care Unit in South India – a prospective study. *Indian J Pediatr* 2012;79:911-5.
6. Vinekar A. IT-enabled innovation to prevent infant blindness in rural India: The KIDROP experience. *J Indian Bus Res* 2011;3:98-102.
7. Vinekar A, Avadhani K, Braganza S, Shetty B, Dogra M, Gilbert C. Outcomes of a protocol-based management for zone 1 retinopathy of prematurity: The Indian Twin Cities ROP Screening Program report number 2. *Am J Ophthalmol* 2011;152:712.
8. Photographic Screening for Retinopathy of Prematurity (Photo-ROP) Cooperative Group, Balasubramanian M, Capone A Jr, Hartnett ME, Pignatto S, Trese MT. The Photographic Screening for Retinopathy of Prematurity Study (Photo-ROP): Study design and baseline characteristics of enrolled patients. *Retina* 2006;26:S4-10.
9. Vinekar A, Trese MT, Capone A Jr, Photographic Screening for Retinopathy of Prematurity (PHOTO-ROP) Cooperative Group. Evolution of retinal detachment in posterior retinopathy of prematurity: Impact on treatment approach. *Am J Ophthalmol* 2008;145:548-55.
10. Operational Guidelines for Rashtriya Bal Swasthya Karyakram. Child Health Screening and Early Intervention Services under NRHM. Ministry of Health and Family Welfare; Available from: http://www.mdm.nic.in/Files/School%20Health%20Programme/Nutrition_Support/Rastriya_Bal_Swaasthya_Karyakram.pdf. [Last accessed on 2014 Dec 31].
11. Vinekar A, Jayadev C, Shetty B. Has the time come to consider universal eye screening for all 'healthy' infants in India? *J Neonatol* 2013;27:36-8.
12. Pejaver RK, Bilagi A, Vinekar A. National Neonatology Foundation's Evidence Based Clinical Practice Guidelines for Retinopathy of Prematurity, NNF India, Guidelines. 2010. p. 253-62.
13. Egge K, Lyng G, Maltau JM. Retinal haemorrhages in the newborn. *Acta Ophthalmol (Copenh)* 1980;58:231-6.

14. Vinekar A, Govindaraj I, Jayadev C, Kumar AK, Sharma P, Mangalesh S, *et al.* Universal ocular screening of 1021 term infants using wide-field digital imaging in a single public hospital in India - a pilot study. *Acta Ophthalmol* 2015 Feb 26.
15. Hughes LA, May K, Talbot JF, Parsons MA. Incidence, distribution, and duration of birth-related retinal hemorrhages: A prospective study. *J AAPOS* 2006;10:102-6.
16. Watts P, Maguire S, Kwok T, Talabani B, Mann M, Wiener J, *et al.*

Newborn retinal hemorrhages: A systematic review. *J AAPOS* 2013;17:70-8.

Cite this article as: Jayadev C, Vinekar A, Bauer N, Mangalesh S, Mahendradas P, Kemmanu V, *et al.* Look what else we found - clinically significant abnormalities detected during routine ROP screening. *Indian J Ophthalmol* 2015;63:373-7.

Source of Support: Nil. **Conflict of Interest:** None declared.