

Clinical Report

Serum antibody-negative Goodpasture syndrome with delta granule pool storage deficiency and eosinophilia

Ashleigh Kussman and Amira Gohara

Department of Pathology, University of Toledo Medical Center, Toledo, OH, USA

Correspondence and offprint requests to: Ashleigh Kussman; E-mail: ashleigh.kussman@rockets.utoledo.edu

Abstract

Goodpasture syndrome is a rare, life-threatening autoimmune disease characterized by a triad of rapidly progressive glomerulonephritis, a hemorrhagic pulmonary condition and the presence of anti-glomerular basement membrane (anti-GBM) antibodies. The antibodies initiate destruction of the kidney glomeruli, resulting in a focal necrotizing glomerulonephritis, which may progress rapidly to renal failure. Autoantibody-mediated damage of alveolar basement membranes leads to diffuse pulmonary hemorrhage, which in some cases may be severe enough to cause respiratory failure. Many clinicians use a variety of assays to detect serum anti-GBM antibodies; however, these tests may be falsely negative in up to 15% of patients with Goodpasture syndrome. Here, we report an unusual case of a 40-year-old man with clinical evidence of Goodpasture syndrome, a negative anti-GBM antibody serum result, eosinophilia and delta granule pool storage deficiency. After a 14-day hospital stay and extensive workup, as well as treatment with antibiotics, steroids and ventilator support for respiratory failure, the patient continued to deteriorate and entered multisystem organ failure. The family decided to withdraw ventilator support, and the patient expired. Immunofluorescence testing for anti-GBM autoantibodies on lung and kidney tissues during an autopsy confirmed the diagnosis of Goodpasture syndrome.

Keywords: antibody-negative Goodpasture syndrome; delta granule pool storage deficiency; diffuse pulmonary hemorrhage; eosinophilia

Background

Characterized by a triad of rapidly progressive glomerulonephritis, hemoptysis and the presence of anti-glomerular basement membrane (anti-GBM) antibodies, Goodpasture syndrome is a rare, life-threatening autoimmune disease. The autoantibodies are targeted against the non-collagen domain 1 of the $\alpha 3$ chain of Type IV collagen. This component is usually hidden from immune system surveillance via molecular interactions. The $\alpha 3$ chain of Type IV collagen is restricted to the basement membranes of the kidney, cochlear tissue, lung, Bruch's membrane of the retina and the testis [1]. The autoantibodies initiate destruction of the basement membranes of the kidney glomeruli, resulting in a focal necrotizing glomerulonephritis, which can be rapidly progressive and cause renal failure. Autoantibody-mediated damage of alveolar basement membranes leads to diffuse pulmonary hemorrhage, which if severe enough, can lead to respiratory failure. Pulmonary symptoms often precede renal symptoms, and may occur weeks to months earlier [2]. The trigger for this autoantibody formation is unknown; however, environmental factors are believed to unmask the usually hidden epitopes, eliciting autoantibody formation. Postulated environmental factors

include viral infection, hydrocarbon solvent exposure and smoking [3, 4]. Diffuse pulmonary hemorrhage in patients with anti-GBM autoantibodies is seen almost exclusively in active smokers [5]. Additionally, this autoimmune disease is associated with certain human leukocyte antigen (HLA) subtypes, such as HLADRB1*1501 and *1502 and HLA-DR4, has a slight male preponderance and is known to occur in two age peaks: the third decade and the fifth and sixth decades [5, 6]. Here, we report an unusual case of a 40-year-old man with clinical evidence of Goodpasture's syndrome, a negative anti-GBM antibody serum result, eosinophilia and delta granule pool storage deficiency.

Case report

A 40-year-old Caucasian man was admitted to the hospital complaining of a 3-week history of slight cough and increased shortness of breath on exertion and a 2-week history of occasional hemoptysis. Increased hemoptysis, fatigue and dyspnea prompted his visit to the emergency department.

The patient's medical history was scarce as he had not seen a doctor in over 20 years. Upon questioning, he

reported a 33 pack-year history of smoking, a 27-kg weight gain over the previous 5 years due to inactivity, no sexual contact or activity, no contact with sick people and no intravenous drug use in the past or present. Besides being morbidly obese, he had no other known medical illnesses.

Chest X-ray imaging revealed bilateral haziness, with extensive involvement of the right lung and the left lower lobe. The patient was admitted and given antibiotics for a presumed pneumonia. On physical examination, the patient was afebrile, and he had coarse breath sounds bilaterally with rare rhonchi. A complete blood count demonstrated a white blood count of 9.6×10^9 cells/L ($4.4\text{--}11.3 \times 10^9$ cells/L) with 0.96×10^9 eosinophils/L ($0\text{--}0.45 \times 10^9$ eosinophils/L). He was put on nasal oxygen to improve oxygenation; however, despite this intervention, blood gases worsened. He was transferred to the intensive care unit and received high-flow oxygen. Bronchoscopy was performed, which revealed diffuse airway bleeding; however, an active bleeding site was not identified. His respiratory function deteriorated, and he was intubated, mechanically ventilated and sedated. A significant amount of blood was seen in the patient's mouth on intubation, and suctioning through a nasogastric tube yielded '200 mL of coffee ground contents.'

An extensive workup was done in an attempt to discern the etiology of his hemorrhagic lung disease. Tests included those for autoimmune diseases, acquired hemolytic anemias, microbial infection and coagulation disorders. A cold agglutinin titer was reported positive; however, a Coomb's test was negative. Rheumatoid factor and C-reactive protein levels were elevated at 23 U/L (<20 U/L) and 44.67 mg/dL ($0\text{--}3$ mg/dL), respectively. He tested negative for anti-neutrophil cytoplasmic antibodies (ANCA) and anti-GBM antibodies. Flow cytometry revealed no deficiency in complement regulatory proteins. One of two blood cultures revealed Gram-positive cocci in clusters, later identified as oxacillin-resistant *Staphylococcus hominis*. All other fungal and viral tests were negative, including cultures on bronchial washings. The patient's international normalized ratio remained slightly elevated at around 1.4 during his stay, with an unknown etiology. Blood was consequently sent for platelet electron microscopy study, which revealed platelets with an average of 2.79 delta granules per platelet (4–6 delta

granules/platelet) consistent with delta granule storage pool deficiency.

The patient's condition continued to deteriorate during his 14-day hospital stay, with worsening anemia requiring receipt of multiple blood products, worsening oxygenation refractory to increased fraction of inspired oxygen (FiO_2), hypertension, hypernatremia, hypocalcemia, hypermagnesemia, blood urea nitrogen and creatinine reaching as high as 35 mmol/L ($2.9\text{--}8.2$ mmol/L) and 230 $\mu\text{mol/L}$ ($8\text{--}31$ $\mu\text{mol/L}$), respectively, indicating kidney failure, and alanine amino transferase (ALT or serum glutamic pyruvic transaminase) and aspartate amino transferase (AST or serum glutamic oxaloacetic transaminase) of 371 U/L ($4\text{--}36$ U/L at 37°C) and 173 U/L ($8\text{--}33$ U/L at 37°C), respectively, indicating liver failure. Efforts to treat his hypertension and hypernatremia were made with various medications. The patient was also put on steroids, in addition to antibiotics. Still, the patient developed progressive lung consolidation bilaterally, persistent hypoxia and recurrence of a significant output of 'coffee ground material' through his nasogastric tube. Eventually, chest X-rays revealed bilateral 'white out' of the lungs and an accumulation of right pleural fluid. A lung biopsy was considered at various points during his decline; however, the patient was never well enough to undergo such a procedure. By the 14th day in the hospital, the patient was oozing blood from multiple mucosal sites and areas of needle sticks, and the patient was deemed critically ill with a poor prognosis due to worsening kidney failure and anemia. The family decided to withdraw ventilator support, and the patient expired.

An autopsy was performed to determine the cause of this patient's demise. The major gross autopsy finding was severe diffuse pulmonary hemorrhage. Significant microscopic findings included those in the lungs and kidneys. Sections of the lungs revealed extensive intra-alveolar hemorrhage, edema, hemosiderin-laden macrophages, focal neutrophilic infiltration, wide-spread chronic inflammation and total disruption of the normal lung architecture (Figures 1 and 2). Microscopic examination of the kidneys revealed extensive tubular cell nuclei dropout, consistent with acute tubular necrosis, which was caused by his persistent hypoxia secondary to his respiratory failure, and mesangial cell proliferation in the glomeruli, fibrin in the Bowman spaces and occasional

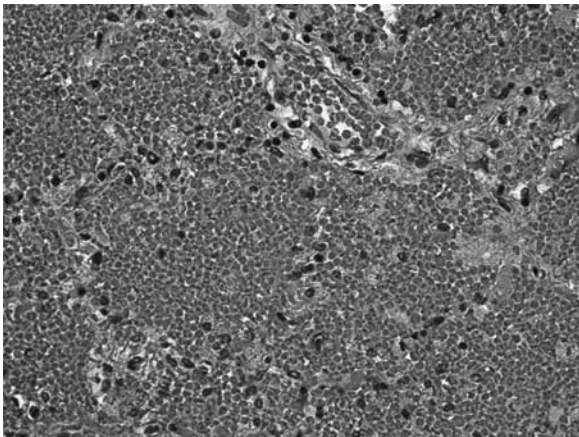


Fig. 1. Photomicrograph of a lung tissue section demonstrating severe diffuse pulmonary hemorrhage.

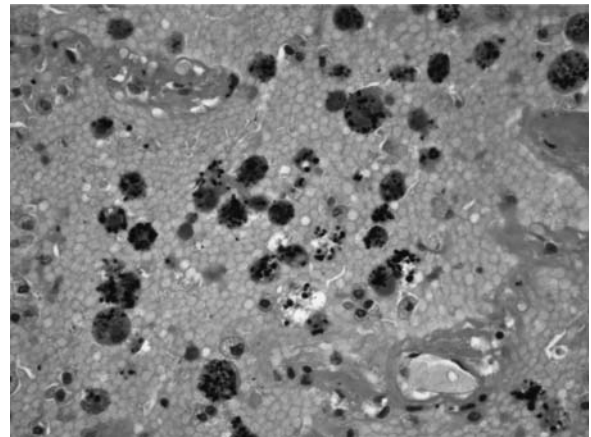


Fig. 2. Photomicrograph of a lung tissue section demonstrating hemosiderin-laden macrophages.




Fig. 3. (a) Low-power photomicrograph of linear IgG deposits in alveolar septa on immunofluorescence in a lung tissue section. (b) High-power photomicrograph of linear IgG deposits in alveolar septa on immunofluorescence in a lung tissue section.

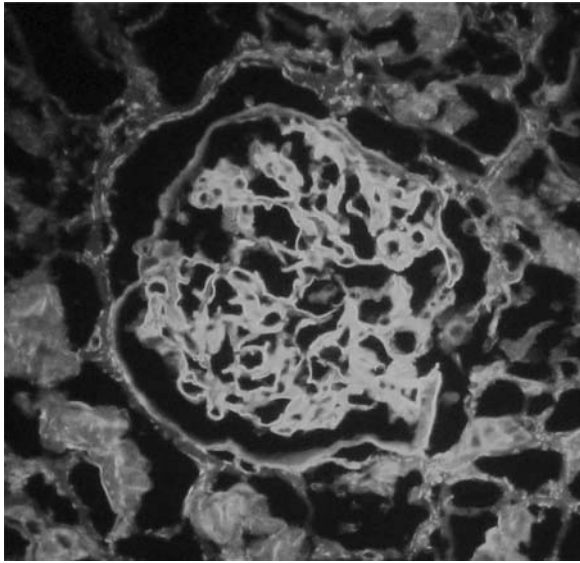


Fig. 4. Photomicrograph of linear IgG deposits along the GBM of a kidney tissue section shown via immunofluorescence.

early crescent formation secondary to inflammatory destruction of the basement membranes in the renal glomeruli. The most significant study involved immunofluorescence, which revealed focal faint linear immunoglobulin G (IgG) deposits along the alveolar septa and strong extensive peripheral linear IgG deposits in the capillary loops of the renal glomeruli (Figures 3 and 4). These findings are consistent with Goodpasture's syndrome.

Discussion

Goodpasture syndrome is a rare autoimmune disorder characterized by glomerulonephritis, hemoptysis and autoantibodies directed against a non-collagenous domain of the $\alpha 3$ chain of collagen Type IV present in a few tissue basement membranes. If not diagnosed and treated early, patients with Goodpasture syndrome may develop respiratory and renal failure and die, or become dependent on dialysis if they survive.

Many clinicians diagnose this syndrome with a variety of assays used to detect serum anti-GBM antibodies.

Renal and lung tissue biopsies are also viewed as valuable in making the diagnosis, as the anti-GBM antibodies may be detected in these specimens by immunohistochemistry or immunofluorescence techniques. A linear pattern of immunoglobulin along the basement membrane of renal glomerular capillaries and alveolar septa seen by immunofluorescence or immunohistochemistry is consistent with Goodpasture syndrome. The latter diagnostic tests are important in suspected clinical cases in which the serum anti-GBM antibody test is negative, as up to 15% of patients with Goodpasture syndrome may have no detectable circulating antibodies [7]. This was the case in our patient, in which his repeated anti-GBM antibody tests came back negative; however, the presence of these antibodies was confirmed by immunofluorescence in lung and renal tissue sections. Further interesting findings in our patient, which to our knowledge have not been reported with any other case of Goodpasture syndrome, were those of delta granule pool storage deficiency and eosinophilia.

There are at least a few cases of Goodpasture syndrome to our knowledge that have been reported to occur in the context of negative anti-GBM serum results. Stolk *et al.* reported a case of a 55-year-old woman who presented with dyspnea and hemoptysis, bronchoscopy revealing diffuse alveolar hemorrhage, negative anti-GBM antibody by enzyme-linked immunosorbent assay, positive perinuclear ANCA at a dilution of 1:160 and glomerular crescents in renal biopsies under light microscopy. Immunofluorescence also demonstrated weak linear staining of the GBMs with anti-complement 3 (anti-C3) sera and strong linear staining with anti-IgG sera [1]. Another case of anti-GBM serum antibody-negative Goodpasture syndrome reportedly occurred in a 44-year-old female with a 3 year history of recurrent hemoptysis and shortness of breath, yet clinically normal renal function. Initially, she had been treated for *Klebsiella pneumoniae* after a positive sputum culture. On repeat presentation with hemoptysis during this period, her illness had been labeled as recurrent acute respiratory distress syndrome. On her fourth presentation with hemoptysis, a bronchoalveolar lavage demonstrated a large number of hemosiderin-laden macrophages. Other test results included a positive rheumatoid factor, autoantibodies, weakly positive anti-double stranded deoxyribonucleic acid negative cytoplasmic-ANCA and extensive ground glass appearance on a chest computed tomography scan. Lung biopsies showed linear deposition of IgG in the alveolar capillary basement membranes using immunoperoxidase

staining, and linear IgG and C3 were seen along the renal capillary walls with immunofluorescence [7]. Finally, a case of a 27-year-old male with Goodpasture syndrome and undetectable anti-GBM circulating antibodies was reported by Hellmann *et al.* This patient, similar to our patient, developed dyspnea and hemoptysis, which eventually led to respiratory failure requiring intubation and mechanical ventilation. Also like our patient, he was a heavy smoker and tested negative for ANCA, anti-nuclear antibodies and a multitude of other autoantibodies. His disease was confirmed on histological lung section by the presence of a faint but linear deposition of IgG antibodies along the alveolar basement membranes [6].

Several proposed mechanisms for why serum anti-GBM tests may be negative in some patients with Goodpasture syndrome have been offered. One proposed explanation is that the antibodies are of high affinity and are removed from the patient's plasma by being bound to the kidney and alveolar basement membranes. On the contrary, the circulating serum antibodies may be of lower affinity than those that are tissue bound and thus are more easily washed away during the wash-out step of the assay. Finally, the assay's renal tissue may have a different epitope than that present in the native kidney [1, 7]. For patients who present promptly with hemoptysis and subsequently receive steroid therapy early in the disease process, negative anti-GBM serum results along with only focal linear deposits in tissues may be due to steroid-induced immune suppression [6].

Two unusual aspects of our patient's case, unknown to us to have occurred concomitantly in other patients with Goodpasture syndrome, include delta granule pool storage deficiency and eosinophilia. Delta granule pool storage deficiency is a heterogeneous disorder presenting with abnormalities in the second wave of platelet aggregation, a bleeding tendency and a decreased number of delta granules in platelets. Most commonly, patients experience mucocutaneous hemorrhage, excessive bleeding postoperatively and postpartum, epistaxis and easy bruising [8]. This bleeding condition likely exacerbated his autoimmune disease course. The etiology of his eosinophilia is not easily explained. No evidence of parasites was found during the autopsy or in microscopic examination of tissues, nor ova or parasites detected in stool samples. Also, no vasculitis was observed in tissue samples on histologic examination. In an article published in the Cleveland Clinic Journal of Medicine on diffuse alveolar hemorrhage, eosinophilia is said to be rare or mild in Goodpasture syndrome; however, the parameters of 'mild' are not defined [9]. Still, it is possible that his eosinophilia was the result of an allergy developed from his reported unsanitary living conditions, which included an abundance of trash, dead mice and black mold.

A combination of factors probably contributed to our patient's demise. The diffuse pulmonary hemorrhage

associated with Goodpasture syndrome occurs almost exclusively in active smokers, and is a postulated cause of unmasking the epitope which elicits the formation of the anti-GBM autoantibodies. Thus, his 33 pack-year smoking history put him at risk of developing this autoimmune disease, as well as increased his risk of diffuse pulmonary alveolar hemorrhage. Additionally, his platelet disorder likely worsened his hemorrhagic lung condition by increasing his likelihood to bleed excessively. Finally, his negative anti-GBM antibody serum result and rapidly progressive condition prevented the ability to attain a lung or renal biopsy to establish the etiology of his disease, and thus, the correct treatment could not be determined. This case demonstrates the difficulty in diagnosing Goodpasture syndrome in an unusual patient in whom the anti-GBM antibody serum results are negative and a biopsy is unattainable, and the grave consequences in missing such a diagnosis.

Conflict of interest statement. None declared.

(See related Editorial comment by A.S. Bomback. Anti-glomerular basement membrane nephritis: why we still 'need' the kidney biopsy. *Clin Kidney J* 2012; 5: 496–497)

References

1. Stolk M, Carl D, Massey HD. Antibody-negative Goodpasture's disease. *NDT Plus* 2010; 3: 253–256
2. Bergs L. Goodpasture syndrome. *Crit Care Nurse* 2005; 25: 50–58
3. Alenzi FQ, Salem ML, Alenazi FA *et al.* Cellular and molecular aspects of Goodpasture syndrome. *Iran J Kidney Dis* 2012; 6: 1–2
4. Clyne S, Frederick C, Arndt F *et al.* Concurrent and discrete clinicopathological presentations of Wegener granulomatosis and anti-glomerular basement membrane disease. *Am J Kidney Dis* 2009; 54: 1118
5. Kluth DC, Rees AJ. Anti-glomerular basement membrane disease. *J Am Soc Nephrol* 1999; 10: 2446–2453
6. Hellmann MA, Gerhardt TM, Rabe C *et al.* Goodpasture's syndrome with massive pulmonary haemorrhage in the absence of circulating anti-GBM antibodies? *Nephrol Dial Transplant* 2006; 21: 526–529
7. Ramaswami A, Kandaswamy T, Rajendran T *et al.* Goodpasture's syndrome with positive C-ANCA and normal renal function: a case report. *J Med Case Rep* 2008; 2: 223
8. Gunay-Aygun M, Gahl WA. Molecular defects that affect platelet dense granules. *Semin Thromb Hemost* 2004; 30: 537–539
9. Ioachimescu O, Stoller J. Diffuse alveolar hemorrhage: diagnosing it and finding the cause. *Cleve Clin J Med* 2008; 75: 258–280

Received for publication: 15.5.12; Accepted in revised form: 18.7.12