

Technical considerations in robotic nephrectomy with vena caval tumor thrombectomy

Ronney Abaza

Department of Urology, Ohio Health Dublin Methodist Hospital, Dublin, Ohio, USA

ABSTRACT

Robotic surgery has been applied to increasingly complex urologic procedures since its initial widespread adoption for prostatectomy. While laparoscopic nephrectomy was initially reported over 2 decades ago, renal tumors involving the inferior vena cava (IVC) appeared to be a limitation to the application of laparoscopy. Laparoscopic management had only been reported in a limited fashion for short tumor thrombi not requiring cross-clamping of the IVC. The first robotic nephrectomy for renal cancer with IVC tumor thrombus was performed in 2008 with the first series reported in 2011, including for larger tumor thrombi requiring IVC cross-clamping for thrombus extraction. Since then, several surgeons at various institutions have adopted robotic surgery for these complex procedures. With experience and meticulous surgical technique, the procedure can be reproduced in properly selected cases. Further adoption and reports of multi-institutional experiences are necessary to validate this still relatively new procedure, and such work is already underway.

Key words: Inferior vena cava, thrombectomy, renal cell carcinoma

INTRODUCTION

Since its introduction in 1992, laparoscopic nephrectomy has gained widespread adoption among urologists and has been applied increasingly for complex pathology, except for tumors with vena caval inferior vena cava (IVC) extension.^[1] Laparoscopy has gained only limited application for IVC tumor thrombi and only for short thrombi that could be milked out of the IVC or in conjunction with an open incision for the IVC manipulation and tumor extraction.^[2-8]

The robotic surgical platform as an adjunct to laparoscopy combines three-dimensional vision and scalable, articulating instrumentation that can provide a level of precision and control that may facilitate more complex procedures. In contrast to standard

laparoscopy, nephrectomy in the setting of significant IVC tumor thrombi requiring cross-clamping of the IVC has been successfully performed. The first robotic nephrectomy for a tumor with IVC extension was performed in 2008 with the first series reported in 2011.^[9] Since then, other institutions have begun to adopt this procedure with limited reports thus far in the literature.^[10,11] Currently, at least 25 such procedures have been performed at more than 10 institutions (personal correspondence, unpublished data) with multi-institutional data currently being compiled.

PROCEDURE

Until date, nearly all robotic nephrectomies with IVC tumor thrombectomy that have been performed have been for right-sided tumors with only few left-sided tumors. All reported procedures have been performed in transperitoneal fashion, although a retroperitoneal approach is likely feasible. Preoperative angioembolization of the kidney is not necessary. Tumor thrombi extending to the level of the hepatic veins have been managed robotically, but techniques for the management of more cranial tumor thrombus extension are still under development.^[11] The following represents the author's preferred approach for these procedures and focuses on right-sided tumors. However, several technical modifications have been performed and are likely subject to surgeon preference.

Bowel preparation aimed at decompressing the colon is preferred, and an orogastric tube is beneficial with duodenal

For correspondence: Dr. Ronney Abaza,
7450 Hospital Drive, Suite 300, Dublin, OH 43016, USA.
E-mail: ronney.abaza@ohiohealth.com

Access this article online

Quick Response Code:	Website: www.indianjurol.com
	DOI: 10.4103/0970-1591.134252

decompression. Full left lateral decubitus positioning (90°) allows gravity retraction of the bowel and duodenum after thorough mobilization. A midline camera port allows ideal visualization of the medial aspect of the peritoneal cavity, including the interaortocaval space. Periumbilical placement of this port allows extraction of the specimen around the umbilicus by extending this port site through the linea alba without cutting muscle. Robotic instrument ports (8 mm) should be triangulated around the level of the hilum of the kidney with the use of the robotic 4th-arm recommended and entering from the right lower quadrant.

Assistant ports should be placed to the extent needed for surgeon comfort and control. A single 12 mm port is adequate for suction and introduction of sutures particularly when using the robotic 4th-arm for retraction, but additional ports can be used as desired. Placement of a port for liver retraction may be prudent depending on the size of the liver and cranial extent of the IVC thrombus. Finally, if a laparoscopic Satinsky clamp is to be used, it can be placed through a stab incision percutaneously without a port to avoid the need for a 15 mm port to allow passage of curved end of the clamp into the abdomen. If used, it should enter the abdomen from the medial right lower quadrant to avoid dislodgement by external movement of the robotic arms.

The robot should approach the patient bed diagonally from the right head of the bed and hence that the robotic arms externally are in the ideal position for the majority of the procedure and not “reaching” toward the head if the robot is docked perpendicularly to the bed as this will cause more external arm clashes. Once the robot is docked, the initial steps of the procedure mimic standard laparoscopic or robotic nephrectomy.

The colon should be widely dissected to allow gravity retraction, so as to obviate need for retraction by an assistant instrument or the robotic 4th-arm instrument. In a similar fashion, the duodenum should be Kocherized and mobilized enough medially to access the interaortocaval space without having to retract the duodenum.

The renal artery can be accessed in typical fashion after lifting the kidney within Gerota’s fascia off the underlying psoas and approaching the artery behind the renal vein, but this may not be safe or possible when the renal vein is distended with tumor thrombus. Evaluation of preoperative imaging studies will determine the ideal approach to the renal artery, but interaortocaval control prevents undue manipulation of the renal vein and tumor thrombus before controlling the IVC. In addition, access to the interaortocaval space will be required anyway during circumferential dissection of the IVC and control of all lumbar veins such that beginning the operation in this space to control the renal artery is often more prudent.

The renal artery can be ligated with robotic clips, which allows for full surgeon control, but laparoscopic stapling can be performed as well or with a soon to be introduced robotic stapling device. Early arterial ligation is recommended before manipulation of the kidney as this may allow partial retraction of the tumor thrombus once it is devascularized and will reduce venous bleeding from the typical parasitic veins surrounding the main tumor.

After arterial ligation, the IVC must be circumferentially controlled above and below the level of the tumor thrombus and ideally along its entire length to minimize the risk that a lumbar vein may be missed. Laparoscopic ultrasound is crucial to identify the cranial-most extent of the tumor thrombus as inadvertent cross-clamping across the tumor thrombus will lead to tumor embolism and potentially death. The Doppler function on the laparoscopic ultrasound can also help differentiate tumor thrombus from associated bland thrombus within the IVC. The IVC containing tumor thrombus must be very carefully manipulated to prevent embolism of a portion of the thrombus from a fracture or disruption of associated bland thrombus. The left renal vein must also be circumferentially dissected for control prior to IVC cross-clamping.

The posterior aspect of the kidney should be mobilized off the underlying psoas muscle, and the plane should be developed between the renal upper pole and adrenal or between the adrenal and liver if the adrenal is to be removed. This will leave only the lateral attachments of the kidney in place before the IVC is to be cross-clamped while the ureter and lower attachments can be divided at this time or later.

In selected cases of short thrombi, some can be milked back into the renal vein after arterial ligation has allowed some retraction and with 4th-arm lateral displacement of the kidney to place the renal vein on stretch. Other shorter thrombi that cannot be completely manipulated into the renal vein may not require cross-clamping, but can be managed with tangential clamping of the IVC.^[9] In such cases, a laparoscopic Satinsky clamp can be used to clamp a portion of the IVC lumen to exclude the thrombus within the arc of the clamp, but while IVC drainage continues through the remainder of the lumen. The portion of IVC to the right of the Satinsky clamp is excised with the specimen, and the left side is oversewn before removing the Satinsky with the goal of preserving at least 50% of the IVC width. Also described is stapling across the IVC tangentially to exclude the thrombus from the lumen,^[11] but the stapling device head is straight and must be able to reliably cross the IVC completely despite its lack of curvature. Most likely, this will only be possible at the very base of the renal vein and incorporating little of the IVC wall itself.

Cross-clamping of the IVC can be performed once all lumbar veins, the gonadal vein, and the left renal vein have been

controlled. Lumbar veins can be controlled by robotic clips, and can either be doubly clipped and divided or simply clipped once and left intact. Most lumbar veins will need to be divided to allow adequate mobilization of the IVC, but smaller lumbar veins can often be controlled simply with bipolar cautery alone without clips.

The author's preferred technique for cross-clamping the IVC above and below the level of the thrombus and for clamping the left renal vein is to use modified Rommel tourniquets. Any of these three sites of clamping can also be achieved with a laparoscopic Satinsky clamp or bulldog clamps of adequate length, but the disadvantage of these will be that they may be obstructive to full movement of the robotic instruments during the critical clamp time either by obscuring visibility or out of fear of dislodging them.

The modified Rommel tourniquets are simply created as previously described^[9] by doubly wrapping them around the IVC or renal vein and then placing a clip once pulled up and tightened to begin the clamping time [Figure 1]. They can be loosened to test the IVC repair or cut to release them if confident that reclamping won't be needed. Care must be taken to place the Rommel tourniquets well enough away from the planned opening to be made in IVC so that they do not slide beyond the edge of the opening and lose control of the lumen as bleeding will be severe. Having a large grasping instrument in the robotic 4th-arm (prograsp or larger) can salvage such situations or if bleeding between sutures is encountered as direct grasping of the IVC at the site of bleeding can temporarily restore hemostasis [Figure 2].

A minor technical point that can save a surgeon from erroneously incising a still perfused IVC is to make a small incision in the clipped stump of the gonadal vein where it enters the IVC after clamping, but prior to incising the IVC at the level of the right renal vein to extract the thrombus. If continued bleeding is encountered from the gonadal vein incision, a clip can easily be placed closer to the IVC to restore hemostasis prior to looking for a likely missed lumbar vein. This is easier than making a small incision in the IVC itself to test for bleeding as this will then require a suture to restore hemostasis if not yet ready to fully open the IVC. If the incision in the gonadal veins stump ceases to bleed after initial drainage of blood within the clamped IVC, then the desired bloodless field will be achieved during thrombus extraction. A completely bloodless field is a necessity as even one missed lumbar vein or other source of venous bleeding from the opened IVC will likely result in massive blood loss within minutes.

During IVC clamping, the IVC is incised anteriorly near the base of the right renal vein, and the incision is carried cranially until large enough to deliver the tumor thrombus intact. Once the tumor thrombus is delivered and retracted upwards, the posterior wall of the right renal vein can be incised to release

the specimen from the IVC and leave a linear defect in the IVC for sutured closure [Figure 3]. The IVC is closed with 4-0 polypropylene and the IVC lumen irrigated with heparinized

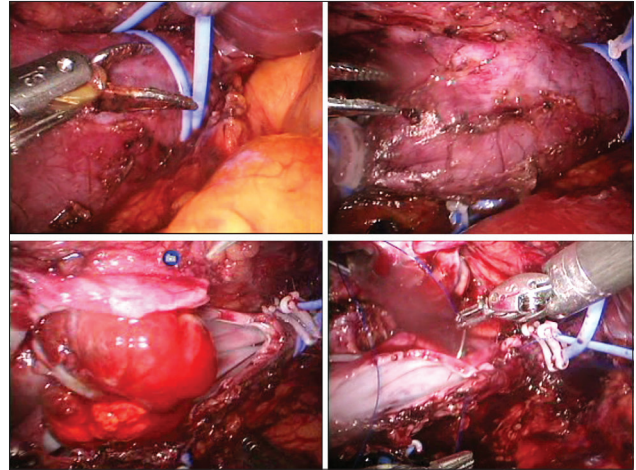


Figure 1: Inferior vena cava (IVC) cross-clamping for tumor thrombectomy including modified Rommel tourniquet preparation with doubly-looped vessel loop around IVC (upper left), IVC just prior to incision with all tourniquets in place (upper right), opened IVC with tumor thrombus extracted (lower left), and sutured closure of IVC (lower right)

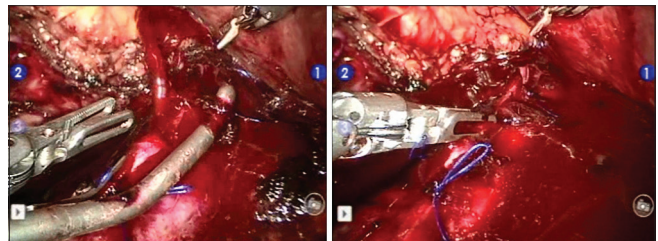


Figure 2: Intraoperative bleeding from tangentially clamped inferior vena cava (IVC) managed with prograsp in 4th-arm that was in the field as a precaution. As laparoscopic Satinsky clamp was removed from sutured IVC, bleeding between sutures (left) was immediately controlled by grasping with 4th-arm instrument (right) until additional sutures could be placed

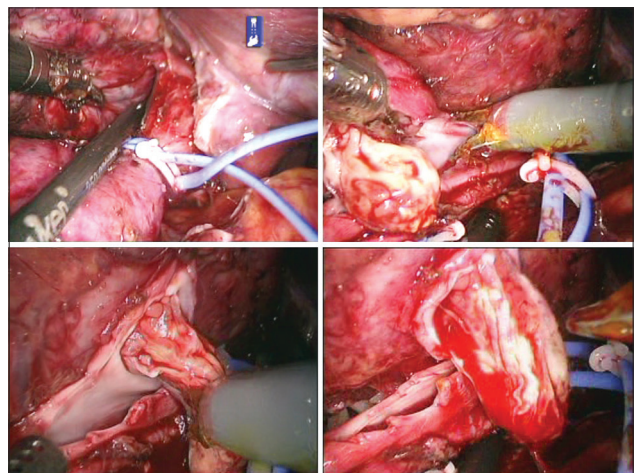


Figure 3: Modified Rommel tourniquet placed just below the level of liver (upper left) with anterior incision of the inferior vena cava (IVC) to extract tumor thrombus (upper right) and visualize posterior edge of incision in IVC (lower right) to allow division of posterior edge of the right renal vein until tumor thrombus freed from IVC (lower right)

saline prior to completion to remove any luminal air, which can be easily, achieved using a five-French ureteral catheter introduced by the bedside assistant. A lymphadenectomy is advisable due to the advanced stage of these tumors and likelihood of occult metastasis as compared with typical renal tumors,^[12,13] and can be performed robotically as thoroughly as with open surgery.^[14]

After reperfusion of the IVC while attempting to minimize the IVC clamp time, the lateral attachments of the kidney are divided and the specimen placed in a laparoscopic extraction bag. After tumor thrombus extraction from the IVC, the tumor thrombus itself will be exposed until the IVC is closed and the remaining renal attachments divided. To avoid this, the author prefers to cover the tumor thrombus as soon as it is extracted and the posterior renal vein has been divided. This is done by introducing the cut end of a laparoscopic extraction bag into the peritoneum and then using it to cover the thrombus, securing it in place with a robotic clip between the thin plastic of the bag edge to the perinephric fat at the renal end of the renal vein. Extraction of the kidney can be from various locations, but the author prefers to avoid muscle cutting by extracting in the midline, which can be periumbilical or suprapubic in location taking advantage of any previous surgical scars.

POSTOPERATIVE CARE

While not standardized, some degree of postoperative anticoagulation is likely prudent and can be achieved with subcutaneous low molecular weight heparin when renal function allows or alternatively with oral aspirin that can be continued upon discharge. We have managed these patients on a common clinical pathway that we use for typical robotic nephrectomies as well as most other robotic procedures such as prostatectomy, partial nephrectomy, nephroureterectomy, and others.^[15-17] This involves immediate ambulation and diet, avoidance of narcotics, and targeted discharge on the 1st postoperative day, which is successful in the vast majority of patients. To aid with postoperative pain control in nephrectomy patients given the often large extraction incision, a subcutaneous catheter delivering local anesthetic for 3 days (ON-Q®, I-Flow, Lake Forest, CA) is placed intraoperatively at the extraction incision.

CONCLUSION

Robotic surgery continues to be applied to increasingly complex conditions not previously felt possible to reliably manage in minimally-invasive fashion. Renal masses with IVC extension are still excised predominantly with open surgery, but robotic nephrectomy for such cases is being applied carefully and selectively at several institutions with expertise in robotics. Although complex and fraught with potential dangers, these procedures can be performed

reproducibly in experienced hands with adequate precaution. Additional adoption will allow continued evolution and perfection of techniques for these advanced procedures.

REFERENCES

1. Ono Y, Hattori R, Gotoh M, Yoshino Y, Yoshikawa Y, Kamihira O. Laparoscopic radical nephrectomy for renal cell carcinoma: The standard of care already? *Curr Opin Urol* 2005;15:75-8.
2. Sundaram CP, Rehman J, Landman J, Oh J. Hand assisted laparoscopic radical nephrectomy for renal cell carcinoma with inferior vena caval thrombus. *J Urol* 2002;168:176-9.
3. Varkarakis IM, Bhayani SB, Allaf ME, Inagaki T, Gonzalgo ML, Jarrett TW. Laparoscopic-assisted nephrectomy with inferior vena cava tumor thrombectomy: Preliminary results. *Urology* 2004;64:925-9.
4. Disanto V, Pansadoro V, Portoghese F, Scalese GA, Romano M. Retroperitoneal laparoscopic radical nephrectomy for renal cell carcinoma with infrahepatic vena caval thrombus. *Eur Urol* 2005;47:352-6.
5. Romero FR, Muntener M, Bagga HS, Brito FA, Sulman A, Jarrett TW. Pure laparoscopic radical nephrectomy with level II vena caval thrombectomy. *Urology* 2006;68:1112-4.
6. Martin GL, Castle EP, Martin AD, Desai PJ, Lallas CD, Ferrigni RG, *et al.* Outcomes of laparoscopic radical nephrectomy in the setting of vena caval and renal vein thrombus: Seven-year experience. *J Endourol* 2008;22:1681-5.
7. Hoang AN, Vaporcyian AA, Matin SF. Laparoscopy-assisted radical nephrectomy with inferior vena caval thrombectomy for level II to III tumor thrombus: A single-institution experience and review of the literature. *J Endourol* 2010;24:1005-12.
8. Kovac JR, Luke PP. Hand-assisted laparoscopic radical nephrectomy in the treatment of a renal cell carcinoma with a level II vena cava thrombus. *Int Braz J Urol* 2010;36:327-31.
9. Abaza R. Initial series of robotic radical nephrectomy with vena caval tumor thrombectomy. *Eur Urol* 2011;59:652-6.
10. Lee JY, Mucksavage P. Robotic radical nephrectomy with vena caval tumor thrombectomy: Experience of novice robotic surgeons. *Korean J Urol* 2012;53:879-82.
11. Sun Y, de Castro Abreu AL, Gill IS. Robotic inferior vena cava thrombus surgery: Novel strategies. *Curr Opin Urol* 2014;24:140-7.
12. Blute ML, Leibovich BC, Chevillet JC, Lohse CM, Zincke H. A protocol for performing extended lymph node dissection using primary tumor pathological features for patients treated with radical nephrectomy for clear cell renal cell carcinoma. *J Urol* 2004;172:465-9.
13. Canfield SE, Kamat AM, Sánchez-Ortiz RF, Detry M, Swanson DA, Wood CG. Renal cell carcinoma with nodal metastases in the absence of distant metastatic disease (clinical stage TxN1-2M0): The impact of aggressive surgical resection on patient outcome. *J Urol* 2006;175:864-9.
14. Abaza R, Lowe G. Feasibility and adequacy of robot-assisted lymphadenectomy for renal-cell carcinoma. *J Endourol* 2011;25:1155-9.
15. Abaza R, Shah K. A single overnight stay is possible for most patients undergoing robotic partial nephrectomy. *Urology* 2013;81:301-6.
16. Khemees TA, Novak R, Abaza R. Risk and prevention of acute urinary retention after robotic prostatectomy. *J Urol* 2013;189:1432-6.
17. Khemees TA, Nasser SM, Abaza R. Clinical Pathway After Robotic Nephroureterectomy: Omission of Pelvic Drain With Next-day Catheter Removal and Discharge. *Urology* 2014; 83 (4):818-23.

How to cite this article: Abaza R. Technical considerations in robotic nephrectomy with vena caval tumor thrombectomy. *Indian J Urol* 2014;30:283-6.

Source of Support: Nil, **Conflict of Interest:** None declared.