

Use of remdesivir in the presence of elevated LFTs for the treatment of severe COVID-19 infection

Andrew J Sabers ¹, Amber L Williams ¹, T Michael Farley ^{1,2}

¹Pharmacy Practice and Science, University of Iowa College of Pharmacy, Iowa City, Iowa, USA
²Pharmacy, Mercy Hospital Iowa City, Iowa City, Iowa, USA

Correspondence to

Dr T Michael Farley;
mike-farley@uiowa.edu

Accepted 8 October 2020

SUMMARY

An 82-year-old man with an extensive medical history presented to the emergency room with complaints of generalised weakness and cough. He tested positive for COVID-19 10 days prior to presenting to the emergency room. Although his symptoms started a week prior to diagnosis, his weakness increased, warranting emergency response. A comprehensive metabolic panel was drawn from the patient on admission, indicating markedly high liver function tests (LFTs) ≥ 20 times above the upper limit of normal. On day 1 of admission, the decision was still made to start remdesivir (5-day course) due to decompensated acute respiratory failure as well as dexamethasone. The patient's LFTs significantly improved throughout his hospital stay. The patient made a full recovery and was discharged on day 10 of hospitalisation.

BACKGROUND

On 31 December 2019, the WHO was first alerted to a number of cases of pneumonia of unknown aetiology.¹ Since then, COVID-19 has spread at an alarming rate. According to WHO data, as of August 2020, there have been more than 24 million confirmed cases and more than 800 000 deaths globally due to COVID-19.² Remdesivir, originally studied for the treatment of Ebola, is an adenosine nucleotide prodrug that halts RNA replication. This medication was developed as a potential therapeutic agent for COVID-19 and received an emergency use authorisation from the Food and Drug Administration on 1 May 2020 based on data that it shortened the time to recovery.³ Current treatment guidelines recommend the use of remdesivir in patients with COVID-19 that require supplemental oxygen despite varying efficacy data.^{4,5} There is a paucity of data for use in smaller subgroups, such as hepatically impaired patients. Currently, it is not recommended to initiate remdesivir in patients with liver function tests (LFTs) exceeding five times the upper limit of normal (ULN), as remdesivir has been associated with increases in both alanine aminotransferase (ALT) and aspartate aminotransferase (AST).⁶ This warning limits the use of remdesivir, as COVID-19 has been associated with increased LFTs without remdesivir.^{7,8} LFT elevations vary widely among trials of remdesivir. Reported elevations range from 1% to 32% of trial participants.^{3,9,10} Due to the recent approval of remdesivir, experience with its use despite elevated liver transaminases is currently lacking, especially in the elderly population. As new data emerge regarding clinical trials and investigational drugs, we are unaware of any case reports

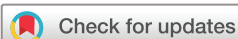that include initiation of remdesivir in patients with markedly high liver transaminases.

CASE PRESENTATION

An 82-year-old man presented to the emergency department via emergency medical service (EMS) in due to increasing weakness (especially in his legs) and cough. He reported testing positive for COVID-19 10 days earlier and had developed initial symptoms 1 week prior to this. Prior to admission, he was prescribed hydroxychloroquine and azithromycin by his primary care physician. His condition continued to deteriorate, and EMS was contacted. On examination, the patient was found to be hypoxic with a respiratory rate of 32 breaths/min. He was unable to complete full sentences and was subsequently placed on high flow nasal cannula. He required 10L of supplemental oxygen to maintain a saturation of 94%. The patient was hypotensive with a blood pressure of 94/54 and tachycardic with a heart rate of 106 beats/min. There were diffuse crackles and wheezing bilaterally on auscultation of the lungs. A chest CT was completed and showed diffuse ground-glass infiltrates and pleural effusions consistent with COVID-19. Additional relevant labs include a D-dimer $>4.00 \mu\text{g/mL}$ (normal range $<0.45 \mu\text{g/mL}$), brain natriuretic peptide (BNP) of 3600 pg/mL (normal range $<852 \text{pg/mL}$), white cell count 14.3 (normal range 4.5–10.8), total bilirubin 1.1 mg/dL (normal range 0.1–1.2) and an AST/ALT of 1526/1075 (normal range AST: 0–40, ALT: 0–41). The patient had a medical history of coronary artery disease, systolic heart failure with reduced ejection fraction, polio, hypertension and hyperlipidaemia. Prior to admission, his daily medications included aspirin 81 mg daily, clopidogrel 75 mg daily, isosorbide mononitrate 30 mg daily, atorvastatin 40 mg daily, lisinopril 10 mg daily, metoprolol succinate 25 mg daily, furosemide 40 mg two times per day and 'several supplements'. The patient was a wheelchair user due to his history of polio. He denied any tobacco or recreational drug use. The patient was diagnosed with sepsis and acute respiratory failure secondary to COVID-19 infection.

TREATMENT

The patient was admitted to the intensive care unit (ICU) for assessment and treatment of COVID-19. On hospital day (HD) 1, he was initiated on 1 unit of convalescent plasma, dexamethasone 6 mg intravenously daily for 7 days and remdesivir (200 mg intravenously on day 1 and 100 mg intravenously on days 2–5). The patient also received levofloxacin



© BMJ Publishing Group Limited 2020. No commercial re-use. See rights and permissions. Published by BMJ.

To cite: Sabers AJ, Williams AL, Farley TM. *BMJ Case Rep* 2020;**13**:e239210. doi:10.1136/bcr-2020-239210

750 mg intravenously on HD 1 and ceftriaxone 1 g on HD 2–5 due to concern for a superimposed bacterial infection. The patient additionally received amiodarone, aspirin, budesonide/formoterol, clopidogrel, enoxaparin, guaifenesin/codeine, diltiazem, docusate, furosemide, lisinopril, metoprolol, Miralax, potassium chloride, acetaminophen, albuterol and topical nystatin. Of note, amiodarone, clopidogrel, ceftriaxone and levofloxacin have been reported to elevate LFTs in a minority of patients. A drug interaction review in hospital was notable for the combination of levofloxacin and amiodarone (additive effects on QT prolongation) but no known drug–drug interactions expected to impact LFTs.

The patient's use of hydroxychloroquine prior to admission may have contributed to LFT elevations. At treatment initiation, AST and ALT were 1526 and 1075, respectively. On HD 3, concern was expressed for the use of remdesivir in the presence of elevated LFTs. At this point, AST and ALT were trending down, and the patient's oxygen requirements were improving, so a decision was made to continue with the treatment and monitor LFTs. The patient was able to complete a 5-day course of remdesivir and LFTs continued to trend downward through discharge.

OUTCOME AND FOLLOW-UP

The patient responded well to therapy. After HD 2, the patient's oxygen requirements began to decrease. His blood pressure, heart rate and respiratory rate normalised. He was able to continue to titrate down and was able to maintain his oxygen saturation on room air on HD 6. On HD 10, the patient was discharged to home. He was scheduled for follow-up with his primary care physician and cardiology after discharge. With regard to the patient's LFTs, at presentation his AST was 38 times the ULN and ALT was 26 times the ULN. It was believed these elevations were secondary to the patient's infection and hypotension. The values peaked on HD 2 with an AST and ALT of 2105 and 1573, respectively. The patient's condition and LFTs improved on HD 3. There were marked decreases in both AST and ALT. This trend continued through the remainder of the patient's hospitalisation. LFTs were last drawn on HD 7, and AST and ALT had fallen to 39 and 226, respectively. LFT trends can be found in figure 1.

DISCUSSION

The hepatotoxicity of remdesivir has been controversial. It is not yet listed in the LIVER-TOX database and there have been no trials focused on the use of remdesivir in patients with hepatic impairment. Current trials have excluded anyone with an ALT or AST greater than five times the ULN. While remdesivir likely does cause

some degree of hepatotoxicity, the magnitude and mechanism of this effect are poorly understood. In two phase 1 trials of remdesivir in healthy volunteers, grade 1 and 2 transaminase elevations were observed and resolved on discontinuation.¹¹ Multiple trials have recently examined remdesivir in the COVID-19 population. In a trial comparing remdesivir treatment for either 5 or 10 days, severe but not immediately life-threatening ALT/AST elevations were reported in 5%–8% of patients and life-threatening AST/ALT elevations in 2%–3% of patients, necessitating treatment discontinuation.⁹ A recently published randomised controlled trial of remdesivir versus standard of care found a similar rate of LFT elevations between groups. AST elevations were seen in 32% of individuals receiving 10 days of remdesivir, 34% of those receiving 5 days of remdesivir and 39% of patients in the standard of care group.¹⁰ A National Institutes of Health-sponsored, randomised controlled trial in hospitalised adults with COVID-19 found a lower rate of LFT elevations occurring in 4.1% of remdesivir recipients and 5.9% of placebo recipients.³ The compassionate use of remdesivir resulted in the administration of remdesivir to 61 patients with severe COVID-19. One of the most common adverse effects in this trial was increased hepatic enzymes, including two patients who discontinued remdesivir due to elevated aminotransferases. Twelve patients (23%) experienced hepatic enzyme elevations during their treatment course.¹² One study looking at the characteristics of 1099 individuals infected with COVID-19 found that 22.2% of all patients had an AST > 40 U/L and 21.3% had an ALT > 40 U/L. This effect was greater in those with severe disease, with 39.4% of patients with elevated AST and 28.1% with elevated ALT.¹³ A group of 41 patients in Wuhan, China, with COVID-19 had similar findings. In this study, 37% of all patients had an AST > 40 U/L. This effect was amplified in patients requiring ICU care with 62% of ICU patients with an AST > 40 U/L.⁷

It has been hypothesised that in COVID-19, hepatic effects may be due to infection of hepatocytes or a secondary effect of immune-mediated inflammation and hypoxia.⁸ Since our patient was treated with dexamethasone, this may have mitigated inflammatory damage to hepatocytes. Alternative explanations include drug–drug interactions. A case report proposed increased remdesivir levels due to concomitant p-gp inhibitors as a potential mechanism of toxicity. They point to the fact that hepatotoxic levels are only minimally higher than the upper limit of the therapeutic range for remdesivir. A small change in drug transport could therefore result in a toxic concentration.¹⁴ Avoidance of drug–drug interactions, especially p-gp inhibitors, likely limits the risk of hepatotoxicity.

Potential hepatotoxicity with remdesivir has limited its use in patients with elevated LFTs at baseline. The magnitude of this hepatotoxicity may be overstated as the LFT elevations seen in trials were likely multifactorial in nature.¹⁵ Many of these trials have been conducted in patients with severe COVID-19, which is known to cause LFT elevations. In this case, we have documented that remdesivir was used in a patient with significantly elevated LFTs at baseline without apparent harm, indeed with LFT improvement concurrent to use. To our knowledge, this is the first case report of remdesivir use in a patient with significantly elevated LFTs. Remdesivir use may be appropriate in patients with elevated LFTs at baseline. Intense monitoring is a necessity in these patients to avoid undue harm. The choice to use remdesivir in this population should take into the consideration the risk and benefits of therapy. However, further research is needed to develop a better understanding of the nature of hepatotoxicity risk and drug–drug interactions with remdesivir in COVID-19 before this strategy can be broadly suggested.

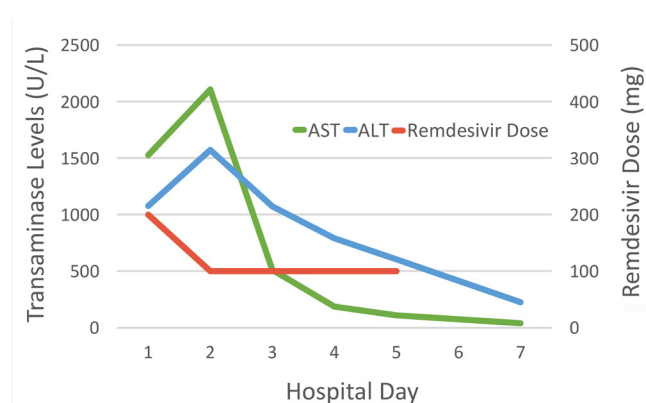


Figure 1 Daily remdesivir dose, aspartate aminotransferase (AST) and alanine aminotransferase (ALT) levels during the hospital course.

Learning points

- ▶ Remdesivir risk versus benefit in patients with elevated liver function tests (LFTs) is poorly understood.
- ▶ COVID-19, especially in severe form, is known to increase LFTs.
- ▶ Elevated LFTs seen in trials with remdesivir may be partially secondary to infection, rather than solely due to the remdesivir hepatotoxicity.
- ▶ With further study, it may be possible to use remdesivir in patients with elevated LFTs at baseline.

Contributors All authors (ALW, AJS, TMF) contributed to the planning, chart review, acquisition of data, interpretation of data, and writing and approval of this manuscript.

Funding The authors have not declared a specific grant for this research from any funding agency in the public, commercial or not-for-profit sectors.

Competing interests None declared.

Patient consent for publication Obtained.

Provenance and peer review Not commissioned; externally peer reviewed.

This article is made freely available for use in accordance with BMJ's website terms and conditions for the duration of the covid-19 pandemic or until otherwise determined by BMJ. You may use, download and print the article for any lawful, non-commercial purpose (including text and data mining) provided that all copyright notices and trade marks are retained.

ORCID iDs

Andrew J Sabers <http://orcid.org/0000-0002-2450-4428>

Amber L Williams <http://orcid.org/0000-0003-2423-8761>

T Michael Farley <http://orcid.org/0000-0003-4218-7718>

REFERENCES

- 1 World Health Organization. Pneumonia of unknown cause – China. Available: <https://www.who.int/csr/don/05-january-2020-pneumonia-of-unknown-cause-china/en/> [Accessed 27 Aug 2020].
- 2 World Health organization disease (Covid-19) Dashboard. Available: <http://covid19.who.int> [Accessed 27 Aug 2020].
- 3 Beigel JH, Tomashek KM, Dodd LE, *et al.* Remdesivir for the treatment of Covid-19 — final report. *N Engl J Med Overseas Ed* 2020.
- 4 Bhimraj A, Morgan RL, Shumaker AH, *et al.* Infectious diseases Society of America guidelines on the treatment and management of patients with COVID-19. *Clin Infect Dis* 2020:ciaa478.
- 5 COVID-19 Treatment Guidelines Panel. Coronavirus disease 2019 (COVID-19) treatment guidelines. National Institutes of health. Available: <https://www.covid19treatmentguidelines.nih.gov/> [Accessed 25 Aug 2020].
- 6 Bertolini A, van de Peppel IP, Bodewes FAJA, *et al.* Abnormal liver function tests in COVID-19 patients: relevance and potential pathogenesis. *Hepatology* 2020. doi:10.1002/hep.31480. [Epub ahead of print: 23 Jul 2020].
- 7 Huang C, Wang Y, Li X, *et al.* Clinical features of patients infected with 2019 novel coronavirus in Wuhan, China. *Lancet* 2020;395:497–506.
- 8 Zhang C, Shi L, Wang F-S. Liver injury in COVID-19: management and challenges. *Lancet Gastroenterol Hepatol* 2020;5:428–30.
- 9 Goldman JD, Lye DCB, Hui DS, *et al.* Remdesivir for 5 or 10 days in patients with severe Covid-19. *N Engl J Med* 2020.
- 10 Spinner CD, Gottlieb RL, Criner GJ, *et al.* Effect of Remdesivir vs standard care on clinical status at 11 days in patients with moderate COVID-19: a randomized clinical trial. *JAMA* 2020;324:1048–57.
- 11 Fact sheet for health care providers emergency use Authorization (EUA) for use of Veklury® (remdesivir), 2020. Available: <http://www.fda.gov/media/137566>
- 12 Grein J, Ohmagari N, Shin D, *et al.* Compassionate use of Remdesivir for patients with severe Covid-19. *N Engl J Med* 2020;382:2327–36.
- 13 Guan W-J, Ni Z-Y, Hu Y, *et al.* Clinical characteristics of coronavirus disease 2019 in China. *N Engl J Med* 2020;382:1708–20.
- 14 Leegwater E, Strik A, Wilms EB, *et al.* Drug-Induced liver injury in a COVID-19 patient: potential interaction of remdesivir with P-glycoprotein inhibitors. *Clin Infect Dis* 2020. doi:10.1093/cid/ciaa883. [Epub ahead of print: 28 Jun 2020].
- 15 Oly A, Meunier L, Délire B, *et al.* Drug-Induced liver injury and COVID-19 infection: the rules remain the same. *Drug Saf* 2020;43:615–7.

Copyright 2020 BMJ Publishing Group. All rights reserved. For permission to reuse any of this content visit <https://www.bmj.com/company/products-services/rights-and-licensing/permissions/>
BMJ Case Report Fellows may re-use this article for personal use and teaching without any further permission.

Become a Fellow of BMJ Case Reports today and you can:

- ▶ Submit as many cases as you like
- ▶ Enjoy fast sympathetic peer review and rapid publication of accepted articles
- ▶ Access all the published articles
- ▶ Re-use any of the published material for personal use and teaching without further permission

Customer Service

If you have any further queries about your subscription, please contact our customer services team on +44 (0) 207111 1105 or via email at support@bmj.com.

Visit casereports.bmj.com for more articles like this and to become a Fellow