



OPEN ACCESS

CASE REPORT

Abundant dystrophic calcifications mimicking aortic valve abscess in a patient undergoing elective aortic valve replacement

Adam L Booth, Christine Q Li, Ghannam Ayed Al-Dossari, Heather L Stevenson

Department of Pathology,
University of Texas Medical
Branch, Galveston, Texas, USA

Correspondence to
Dr Heather L Stevenson,
hlstevenson@utmb.edu

Accepted 21 June 2017

SUMMARY

Dystrophic calcifications of the aortic valve may cause symptomatic aortic stenosis and account for a significant portion of patients who undergo elective valve replacement. Calcifications appearing grossly as a cloudy fluid surrounding the aortic valve leaflets are an uncommon finding. Normally, calcified aortic valves are characterised by large, nodular masses within the aortic cusps. We report a case of dystrophic calcifications on a stenotic aortic valve encountered intraoperatively, which was suggestive of infective endocarditis and abscess formation. Aortic valve leaflets and necrotic-appearing thymic lymph node tissue were submitted for histology and special stains. Cultures were negative and histology did not show evidence of infection. Tissue histology demonstrated extensive dystrophic calcifications, which were polarised to reveal abundant calcium oxalate crystals. The benign nature of this unique pathological finding ruled out any suspicion of infection, avoiding a prolonged course of intravenous antibiotics in this patient.

BACKGROUND

Calcification of tissues in the body occurs due to precipitation of insoluble salts of calcium carbonate or calcium phosphate. When calcium deposits occur within soft tissues, they are categorised into three different types: (1) dystrophic, (2) metastatic or (3) calcinosis.^{1,2}

Dystrophic calcifications occur in patients with normal serum calcium and phosphorus levels, and most commonly occur in injured or compromised tissues. This can be influenced by multiple physiological factors such as serum calcium, phosphorus and alkaline phosphatase, pH of the tissue, vitamin D, hormonal balance, blood supply, and injury of soft tissues.³ Damaged or necrotic tissues have a decreased metabolic rate, leading to lower levels of carbon dioxide. The lower levels of carbon dioxide in the tissue increase the pH, permitting calcium and phosphorus salts to precipitate out of solution. Common manifestations that result in or contain dystrophic calcifications include tumours, arterial calcifications such as atherosclerosis, trauma and crystal deposition disorders such as gout.^{1,4} Metastatic calcifications occur in patients with abnormal calcium phosphate metabolism, specifically when the calcium phosphorus level is greater than 70 mg/dL. Diseases in which metastatic calcifications are observed include hyperparathyroidism, neoplasms,

milk-alkali syndrome and hypervitaminosis D. Although some place calcinosis in the dystrophic calcification category, examples of calcinosis include calcinosis universalis, calcinosis circumscripta, scleroderma, dermatomyositis and systemic lupus erythematosus.¹

Calcific aortic valvular disease is the main indication for surgical valve replacement in the western world. Diabetes mellitus, hypertension, hypercholesterolaemia, smoking and male gender have been identified as the risk factors for both calcific valve disease and atherosclerosis.⁵ The pathophysiology of aortic calcification is similar to that of atherosclerosis and involves oxidative stress, inflammation and endothelial dysfunction.⁶ Haemodynamic stress, genetic dysregulation and oxidative stress lead to an active inflammatory process, which can result in severe calcific aortic stenosis. Chronic inflammation seems to be a central factor in aberrant soft tissue calcification in general. Sites of chronic inflammation in the vasculature have been shown to become sites of atherosclerotic calcification, which supports that the atherosclerotic calcification in humans is a similar physiological process as that which occurs in soft tissues.

Hypercholesterolaemia is a known risk factor for the development of soft tissue calcifications. Animal studies have shown that lipids play an important role in pathogenesis through the activation of molecular cell signals, such as Wnt/Lrp5, receptor activator of nuclear factor-kappa B (RANK)/RANKL and osteoprotegerin, which induce the transition of valvular myofibroblasts towards an osteogenic phenotype, resulting in calcium and even bone deposition. However, this theory is still controversial since lipid-lowering agents in controlled trials have failed to demonstrate slower progression of aortic stenosis.^{7,8}

Underlying degenerative valvular disease, including calcific aortic stenosis, is an important risk factor for infective endocarditis.⁹ *Streptococcus* spp and *Staphylococcus* spp are the predominant organisms, accounting for 80% of cases.¹⁰ A high index of suspicion and diagnostic approach via the Duke criteria are required to ensure timely diagnosis.^{11,12} Once infective endocarditis is suspected, it is prudent to start antibiotics immediately, as it may be fatal if not aggressively treated.¹² Antibiotic regimens are generally intravenous and can range from 2 weeks for uncomplicated,



CrossMark

To cite: Booth AL, Li CQ, Al-Dossari GA, et al. *BMJ Case Rep* Published Online First: [please include Day Month Year]. doi:10.1136/bcr-2017-220368

streptococcal infective endocarditis to 6 weeks for enterococcal infections.¹⁰

We report a case in a 71-year-old man who was undergoing an elective aortic valve replacement (AVR) for aortic stenosis and had abundant dystrophic calcifications that grossly appeared similar to abscess formation surrounding his native aortic valve as well as in the adjacent mediastinal soft tissue. Polarisation of the smears obtained from the valve and necrotic-appearing tissue facilitated diagnosis. Proper diagnosis of prominent dystrophic calcifications in this case spared our patient a longer hospital stay, intravenous antibiotics, and other unnecessary medical interventions as well as their associated complications.

CASE PRESENTATION

A 71-year-old man with a medical history significant for hypertension, hyperlipidaemia, and aortic stenosis presented with worsening symptom of dyspnoea on exertion over the past 2 years. He was afebrile and normotensive, with normal serum ionised calcium level. Physical examination revealed a grade 3 out of 6 systolic murmur over the right sternal border. He did not have any thrills or heaves, nor any jugular venous distension. Transthoracic echocardiogram (TTE) was performed and significant for normal left ventricular wall, enlarged left atrium (31 mL/m²), and calcified aortic valve leaflets with aortic valve area of 0.94 cm² and mean aortic valve gradient measuring 40.1 mm Hg. Laboratory includes white blood cell of $6.8 \times 10^3/\mu\text{L}$ and electrolytes within normal limits. Per the American Heart Association/American College of Cardiology guidelines, the patient was a candidate for AVR, as he was symptomatic and had diagnostic TTE findings.¹³

Our patient was admitted for elective AVR by cardiothoracic surgery. A routine transesophageal echocardiography (TEE) was performed intraoperatively, which incidentally revealed an abscess in the area of the non-coronary cusp of the aortic valve. The surgeon found a small cavitory lesion with a white, milky

substance after the decalcification of the aortic valve annulus, which resembled a small aortic annulus abscess. The cavity was debrided and closed with a pericardial patch. Cultures were sent to microbiology. In addition, a large (6.0×5.0×1.0 cm) necrotic 'mediastinal lymph node' was sent to microbiology and surgical pathology for culturing and microscopic evaluation, respectively. A 21 mm St Jude Trifecta tissue prosthesis was implanted. Due to the presence of the potential perivalvular and aortic root abscess noted during the operation, he was started on cefazolin and doxycycline, and a peripherally inserted central catheter (PICC) was placed a couple of days after the surgery in anticipation of prolonged antibiotic therapy, as recommended by the infectious disease consult team.

The aortic valve tissue submitted to surgical pathology showed abundant dystrophic calcifications in a background of myxoid degeneration, without any evidence of infection, such as neutrophils or other acute inflammation. The submitted lymph node tissue was actually atrophic thymus gland that contained areas of necrosis with abundant calcium phosphate and calcium oxalate crystals. The calcium crystals were enhanced by polarisation of the H&E slides (figure 1). Smears made from the cloudy fluid/stenotic aortic valve by the microbiology laboratory also showed aggregates of calcium crystals (figure 1) without any evidence of inflammation, including neutrophils. The valve tissue and 'lymph node' were sent for aerobic, anaerobic, fungal and acid-fast cultures, which were all negative. Thus, the PICC line was removed and antibiotics were discontinued on postoperative day 6 and the patient was discharged on the following day.

OUTCOME AND FOLLOW-UP

Our patient had an uncomplicated postoperative course. He was followed up closely with cardiothoracic surgery and infectious disease teams for which he continued to show a rapid recovery without any signs or symptoms of IE. A repeat TTE at 3-month

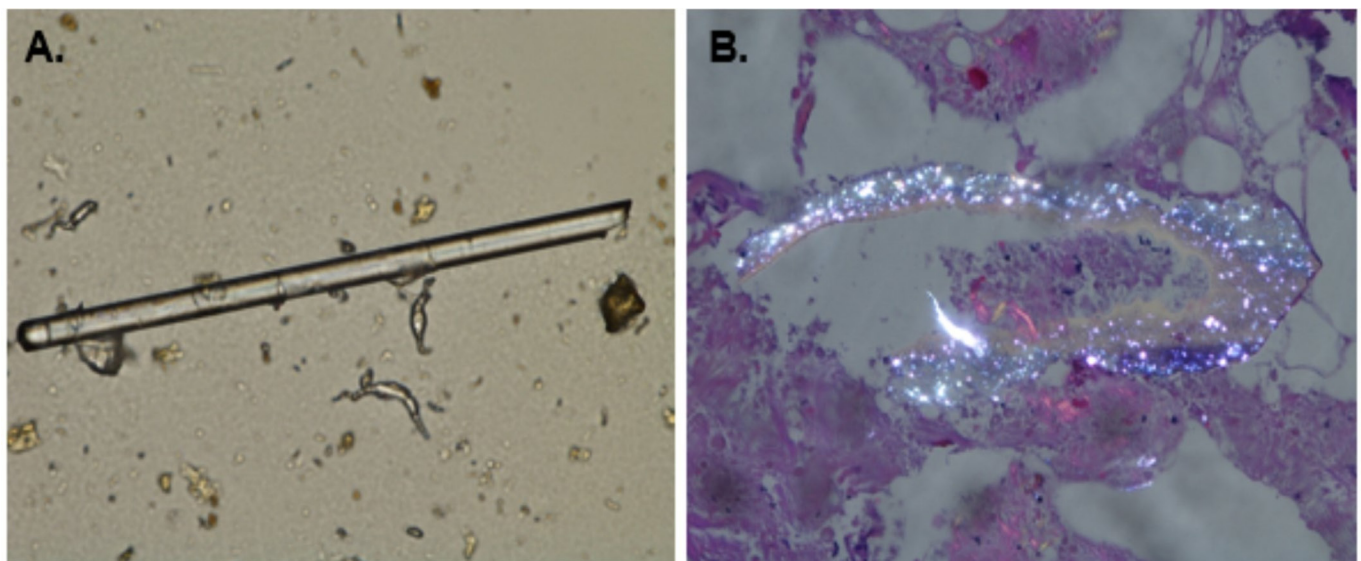


Figure 1 Tissue samples from our patient contained abundant dystrophic calcifications. The cloudy fluid obtained from the aortic valve was sent to microbiology. Panel A shows a representative example of the abundant calcium phosphate crystals that were observed in the smear made from this specimen. Panel B is a representative image from the atrophic thymus tissue, which showed focal areas of coagulative and fat necrosis, and did not contain any acute inflammation or other evidence of infection. Frequent calcium phosphate crystals were observed, and when the necrotic areas were polarised abundant calcium oxalate crystals were also present. The native aortic valve connective tissue did not show any evidence of infection, however also contained abundant calcifications (data not shown).

follow-up demonstrated a well-functioning prosthetic aortic valve without vegetations.

DISCUSSION

Dystrophic calcifications can be a result of spontaneous precipitation of calcium phosphate crystals.⁶ Extraosseous biomineralisation may be driven by upregulation of activating factors and by downregulation of such inhibiting factors.² This is usually held in balance at baseline. A consecutive series of 912 surgically excised aortic valves were evaluated by means of macroscopic and histological study; dystrophic calcifications were the cause in 23% of the cases.¹⁴ Calcium deposition on soft tissue passively builds over time, with hyperlipidaemia and atherosclerosis as risk factors to increased aggregation.^{5 15} Our patient's advanced age and history of dyslipidemia predisposed him for development of dystrophic calcifications at his aortic valve. Normally, even in advanced stages of valve mineralisation and microcalcification, calcified aortic valves are nodular in appearance, not like the white cloudy, milky appearance observed in our patient.¹⁵ The presence of dystrophic calcifications in the patient's damaged native aortic valve most likely propagated increased deposition of calcium within the region of the valve annulus, resulting in an exudative appearance that was mistaken for an infection. The degenerating thymus gland also is known to have a lower metabolic rate, leading to lower levels of carbon dioxide and a more alkaline environment, allowing calcium and phosphorus salts to precipitate out of solution and result in the abundant dystrophic calcifications observed microscopically in the patient. Trauma or previous cardiothoracic surgery was also considered as a possible cause of the soft tissue necrosis and calcium deposition; however, he denied any history of previous operations or causes of chest injury. Furthermore, caseous annular calcification was on the differential; however, microscopically, the patient's tissue lacked eosinophilic material with surrounding macrophages and lymphocytes, typically seen with caseous calcification.¹⁶

As the normal aortic valve undergoes calcification and becomes more stenotic, increased turbulence leads to elevated risk by a factor of 10 for infective endocarditis.¹⁷ Prior to surgery, there was no reason to suspect infective endocarditis in the patient, as he did not have fever or evidence of abscess or vegetation on the preoperative TTE. However, after surgery, he did satisfy one major criterion, a suspected abscess was incidentally visualised on a routine intraoperative TEE, and one minor criterion was satisfied by our patient having a predisposed valvular heart condition, according to the Duke criteria for diagnosing IE. Although he did not meet all of the criteria for a definite diagnosis of infective endocarditis, clinical suspicion remained high. In addition, grossly, the aortic valve appeared to have exudates, unlike the nodules typically seen with valvular calcifications. Thus, it was appropriate to empirically treat our patient with antibiotics while we were awaiting the results of microbiological cultures and microscopic evaluation by surgical pathology.

In conclusion, it is critical for clinicians, surgeons and pathologists to be aware that abundant dystrophic calcifications can appear similar to infectious exudates and abscess formation in both aortic valves and adjacent mediastinal soft tissue. If the proper procedures are followed and tissues are appropriately sent to microbiology and surgical pathology, the correct diagnosis can be made, which will save undue stress to the patient and clinical teams, prevent unnecessary medical intervention, inappropriate use of antibiotics and development of potential resistance, and prolonged hospitalisation. We also

Patient's perspective

'My best description of my experience with this surgery is that it was a 'roller coaster' ride. I went into the surgery with concern for the initial and long term effect that it might have on my quality of life after surgery since I have always been very active. I had known for several years that the surgery was inevitable and the only way to resolve my problem. I was mentally prepared for the procedure and was extremely relieved when I woke up in ICU and feeling fairly comfortable. After surgery my surgeon and all of the medical staff told me that everything went very well and that the surgery was a success.'

'I was feeling really good until a day later when five physicians marched into my room and informed me that, based on visual observations during surgery, they suspected that the aortic valve that was removed might have been infected and that there might also be other infected tissue remaining in my heart. They informed me that they would run exhaustive tests to confirm or deny their suspicions, but that they were recommending that I undergo long-term antibiotic therapy. The news that I might have an infection in my heart and would have to undergo this somewhat invasive therapy was the most devastating news regarding my current and future health that anyone could have given me. The antibiotic therapy began that day and a port was installed in my right arm the next day. Two of the original five physicians continued to visit me at least once a day and give me updates on the results of tests that were being run. They were obviously very interested in my case and encouraged me to stay positive. They were the best 'medicine' that I could have been given at the time.'

'On the seventh day of my stay, I was informed by the original five physicians that all of the tests that had been run on all of the tissues collected from my surgery had not identified a single infected cell. I do not recall ever having been so relieved or excited about my future. The antibiotic therapy was stopped, I was discharged the next day, and the port was removed by one of the two physicians that continued to give me daily updates, in her office a day later. I went through an extensive Cardiac Rehab Program after discharge where I underwent strength and endurance training. It was very beneficial and I have incorporated these exercises into my weekly training program. I continue to feel great, my wife and I went snow skiing this year, and I hope that this report is helpful to other patients that encounter a similar experience such as mine.'

Learning points

- ▶ Abundant dystrophic calcifications can mimic an infectious process, at the region of the aortic valve at the time of valvular replacement and within adjacent mediastinal soft tissues, including lymph nodes or atrophic thymus gland.
- ▶ Awareness of this possibility can ensure adequate specimen processing, polarisation of the tissue sections and diagnosis of dystrophic calcifications rather than infection.
- ▶ A correct diagnosis can save patients from unnecessary medical interventions, unnecessary treatment with antibiotics and prolonged hospital stays.

recommend that pathologists polarise smears and submitted tissue, particularly if a lesion is designated as an abscess or appears necrotic, but no evidence of acute inflammation is observed microscopically.

Acknowledgements We would like to thank Drs. Clinton White, Scott Lea and Lia Suazo Hernandez from the infectious disease team for providing clinical information and assisting with patient care. Dr. Paul Boor reviewed the pathology slides and concurred with the histopathologic diagnosis. We would also like to thank our patient for consenting and contributing his own perspective to this report.

Contributors ALB wrote the majority of the paper. CQL, HLS and GAA-D wrote and contributed as well. Every author played a significant role in drafting this case report.

Competing interests None declared.

Patient consent Obtained.

Provenance and peer review Not commissioned; externally peer reviewed.

Open Access This is an Open Access article distributed in accordance with the Creative Commons Attribution Non Commercial (CC BY-NC 4.0) license, which permits others to distribute, remix, adapt, build upon this work non-commercially, and license their derivative works on different terms, provided the original work is properly cited and the use is non-commercial. See: <http://creativecommons.org/licenses/by-nc/4.0/>

Published by the BMJ Publishing Group Limited. For permission to use (where not already granted under a licence) please go to <http://www.bmj.com/company/products-services/rights-and-licensing/>

REFERENCES

- 1 Black AS, Kanat IO. A review of soft tissue calcifications. *J Foot Surg* 1985;24:243–50.
- 2 Hussmann J, Russell RC, Kucan JO, *et al.* Soft-tissue calcifications: differential diagnosis and therapeutic approaches. *Ann Plast Surg* 1995;34:138–47.
- 3 Stewart VL, Herling P, Dalinka MK. Calcification in soft tissues. *JAMA* 1983;250:78–81.
- 4 Portigliatti Barbos M, Cadario A, Canavese C, *et al.* Clinical, histological, and chemical characterization of ectopic calcification in dialyzed and non-dialyzed patients. *Ital J Orthop Traumatol* 1991;17:523–32.
- 5 Sathyamurthy I, Alex S. Calcific aortic valve disease: is it another face of atherosclerosis? *Indian Heart J* 2015;67:503–6.
- 6 Stewart BF, Siscovick D, Lind BK, *et al.* Clinical factors associated with calcific aortic valve disease. Cardiovascular Health Study. *J Am Coll Cardiol* 1997;29:630–4.
- 7 Parisi V, Leosco D, Ferro G, *et al.* The lipid theory in the pathogenesis of calcific aortic stenosis. *Nutr Metab Cardiovasc Dis* 2015;25:519–25.
- 8 Demer LL, Tintut Y. Inflammatory, metabolic, and genetic mechanisms of vascular calcification. *Arterioscler Thromb Vasc Biol* 2014;34:715–23.
- 9 Bischof T, Schneider J. [Degenerative calcification of mitral and aortic valves]. *Schweiz Rundsch Med Prax* 1992;81:626–31.
- 10 Hoen B, Duval X. Infective Endocarditis. *N Engl J Med Overseas Ed* 2013;368:1425–33.
- 11 Selton-Suty C, Célard M, Le Moing V, *et al.* Preeminence of Staphylococcus aureus in infective endocarditis: a 1-year population-based survey. *Clin Infect Dis* 2012;54:1230–9.
- 12 Cahill TJ, Prendergast BD. Infective endocarditis. *Lancet* 2016;387:882–93.
- 13 Nishimura RA, Otto CM, Bonow RO, *et al.* 2014 AHA/ACC guideline for the management of patients with valvular heart disease: executive summary: a report of the American College of Cardiology/American Heart Association Task Force on Practice Guidelines. *J Am Coll Cardiol* 2014;63:2438–88.
- 14 Agozzino L, Falco A, De Luca Tuppiti Schinosa L, *et al.* [Surgical pathology of the aortic valve: a morphologic study on 912 surgically excised valves]. *G Ital Cardiol* 1992;22:1169–77.
- 15 Liu X, Xu Z. Osteogenesis in calcified aortic valve disease: from histopathological observation towards molecular understanding. *Prog Biophys Mol Biol* 2016;122:156–61.
- 16 Harpaz D, Auerbach I, Vered Z, *et al.* Caseous calcification of the mitral annulus: a neglected, unrecognized diagnosis. *J Am Soc Echocardiogr* 2001;14:825–31.
- 17 Dhawan VK. Infective endocarditis in elderly patients. *Clin Infect Dis* 2002;34:806–12.

Copyright 2017 BMJ Publishing Group. All rights reserved. For permission to reuse any of this content visit <http://group.bmj.com/group/rights-licensing/permissions>.
BMJ Case Report Fellows may re-use this article for personal use and teaching without any further permission.

Become a Fellow of BMJ Case Reports today and you can:

- ▶ Submit as many cases as you like
- ▶ Enjoy fast sympathetic peer review and rapid publication of accepted articles
- ▶ Access all the published articles
- ▶ Re-use any of the published material for personal use and teaching without further permission

For information on Institutional Fellowships contact consortiasales@bmjgroup.com

Visit casereports.bmj.com for more articles like this and to become a Fellow