

Successful prenatal management of ventricular tachycardia and second-degree atrioventricular block in fetal long QT syndrome



Akira Miyake, MD,^{*} Heima Sakaguchi, MD,^{*} Aya Miyazaki, MD,^{*} Takekazu Miyoshi, MD,[†] Takeshi Aiba, MD,[‡] Isao Shiraishi, MD^{*}

From the ^{*}Department of Pediatric Cardiology, National Cerebral and Cardiovascular Center, Osaka, Japan, [†]Department of Perinatology and Gynecology, National Cerebral and Cardiovascular Center, Osaka, Japan, and [‡]Department of Cardiovascular Medicine, National Cerebral and Cardiovascular Center, Osaka, Japan.

Introduction

Long QT syndrome (LQTS) is an inherited channelopathy that causes sudden death in all ages owing to polymorphic ventricular tachycardia. Although it is uncommon, individuals affected by certain LQTS mutations present in utero with ventricular tachycardia with or without second-degree atrioventricular block (AVB). Fetuses manifesting these rhythms are at risk of intrauterine heart failure and fetal demise.¹

Fetal LQTS can be suspected by echocardiography but is diagnosed by fetal magnetocardiography (fMCG), which can be performed from mid-second trimester to term.² Findings of a prolonged corrected QT interval (QTc) and the distinct characteristics of torsades de pointes (TdP) in a fetus with ventricular tachycardia (VT) and either sinus bradycardia or second-degree AVB confirms the clinical suspicion of LQTS. Transplacental antiarrhythmic drug administration is effective for rescuing fetuses that have developed, or are at high risk of developing, fetal hydrops.³ fMCG can also monitor transplacental antiarrhythmic drug treatment given to rescue the fetuses. The purpose of this report is to describe the treatment of 2 LQTS fetuses with hydrops and complex arrhythmia guided by fMCG.

Case reports

Case 1

A 32-year-old woman in the 28th week of her fifth pregnancy was referred to our institution with a 3-week history of fetal bradycardia (fetal heart rate 60 beats per minute [bpm]). She had no personal or family histories of cardiac arrest, seizures, or syncope. Of her 4 pregnancies, only 1 had ended in a

miscarriage. The initial fetal echocardiogram at our institution revealed a structurally normal heart with normal size, normal function, and second-degree AVB (V rate 60 bpm, atrial rate 120 bpm). Her antibody screen was negative for anti-SSA and anti-SSB antibodies. One week later, a follow-up fetal echocardiogram showed a ventricular rate of 220 bpm (atrial rate was 130 bpm) (Figure 1A). An fMCG was then performed which revealed nonsustained VT alternating with sinus rhythm (rate 130 bpm) (Figure 1B). The VT was present about 75% of the time. The QTc was 591 ms (Figure 1C).

Over the ensuing days, the TdP continued and the fetus developed severe hydrops. We therefore decided to administer an intravenous loading dose of magnesium (4 g) followed by a continuous infusion (1–1.4 g/h) to maintain a maternal serum level of 1.2–1.4 (normal = 0.65–1.05 mmol/L). The mother's baseline magnesium level was 0.72 mmol/L. Within 3 days of magnesium infusion the frequency of TdP decreased (by fMCG the fetus was in sinus rhythm 80% of the time). Because of the concern for an SCN5A R1623Q mutation, we began treatment with mexiletine (600 mg orally per day). The fetus remained in sinus rhythm (rate 100 bpm) with continuous magnesium infusion and oral mexiletine given to the mother. At 35 weeks the fetus became bradycardic and was found to be in second-degree AVB.

The mother underwent an elective cesarean section at 35 weeks' gestation and a 2334-g male infant was delivered. The heart rate at birth was 56 bpm owing to functional second-degree AVB with 2:1 conduction (Figure 2A). Immediately after delivery, temporary transvenous pacing wires were placed. On the second day of life, a permanent pacemaker was implanted. We also administered oral mexiletine (4 mg/kg/d) and intravenous propranolol (0.02 mg/kg/h); no VT was observed. On the 14th day of life, the infant's electrocardiography showed sinus rhythm with a left bundle branch block pattern (Figure 2B). On the 40th day of life, the mexiletine blood levels declined, and TdP occurred

KEYWORDS Congenital long QT syndrome; Ventricular arrhythmia; Prenatal management; Ventricular tachycardia/torsades de pointes; Fetal magnetocardiography (Heart Rhythm Case Reports 2017;3:53–57)

Address reprints and correspondence: Dr Heima Sakaguchi, Department of Pediatric Cardiology, National Cerebral and Cardiovascular Center, 5-7-1 Fujishiro-dai, Suita, Osaka 565-8565, Japan. E-mail address: hsakaguc@hsp.ncvc.go.jp.

KEY TEACHING POINTS

- In severe cases of congenital long QT syndrome (LQTS), ventricular tachycardia / torsades de pointes during fetal life can cause fetal hydrops.
- Fetal magnetocardiography proved useful for not only diagnosing the fetal arrhythmia but monitoring the fetal heart rhythm during fetal treatment.
- Two hydropic fetuses with LQTS with ventricular arrhythmias and heart block were successfully managed in utero.

despite ventricular pacing (VVI 80 bpm). The TdP spontaneously terminated.

The VVI pacing rate was increased to 110 bpm. When the infant was at the age of 5 months, weighing 6.6 kg, we placed an implantable cardioverter-defibrillator (ICD). The shock lead was implanted subcutaneously through the left thoracodorsal region, and the generator was placed under the right abdominal rectus muscle (Figure 2C). Following implantation of the ICD, the child did not experience any appropriate or inappropriate shocks during 4 years of

follow-up. He received oral mexiletine (12 mg/kg/d) and propranolol (2 mg/kg/d).

Genetic testing of this case revealed a *KCNH2* missense mutation (S624R). To date, there has been no functional analysis of this mutation. His mother's QTc was 440 ms, and his father's was 390 ms. Neither of the parents had any mutation in this locus. However, we did not exclude parental germinal mosaicism.

Case 2

A 35-year-old woman was referred to our institution at 24 weeks' gestation because of a fetal pericardial effusion and fetal tachycardia. The family history was positive for a paternal *KCNH2* missense mutation (T613M) diagnosed after a syncopal episode. The fetal echocardiogram revealed a persistent tachycardia with atrioventricular dissociation (Figure 3A). The fMCG confirmed the clinical diagnosis of VT with a rate of 220 bpm (Figure 3B) with a prolonged (511 ms) QTc during brief (<20% of the recording time) episodes of sinus rhythm (rate 110–120 bpm) (Figure 3C). The mother was admitted to the hospital for continuous intravenous magnesium treatment to terminate the fetal VT. However, despite maternal serum magnesium levels of 1.28 mmol/L (normal range 0.65–1.05 mmol/L), the VT persisted and the fetus became hydropic (Figure 3D). Ten days after the

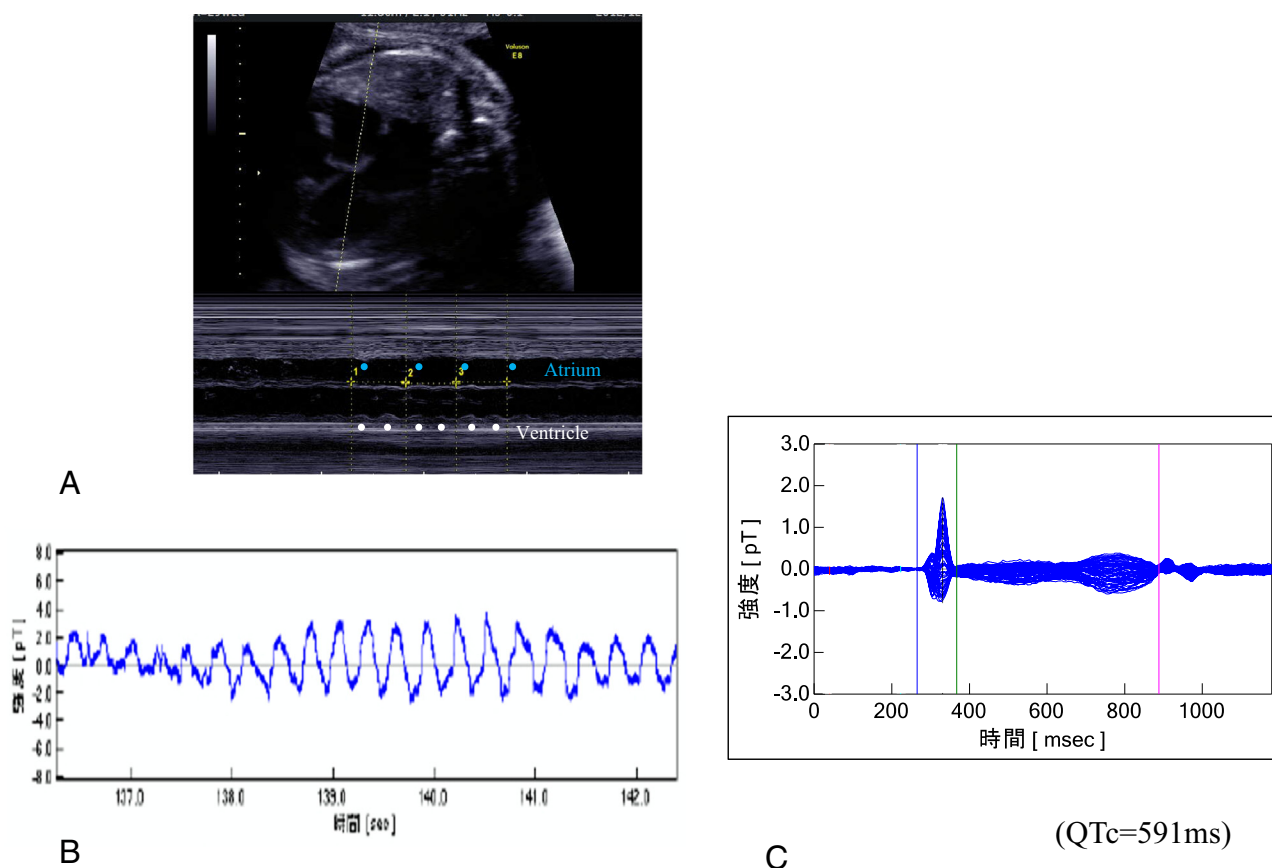


Figure 1 Case 1. **A:** At 29 weeks, a fetal echocardiogram showed ventricular tachycardia (VT) with a ventricular rate of 220 beats per minute (bpm), compared with an atrial rate of 130 bpm. **B:** Fetal magnetocardiography (fMCG) revealed polymorphic VT. **C:** fMCG showed a prolonged QT interval (591 ms) during sinus rhythm.

mother was on magnesium, we initiated propranolol (initial dose 60–120 mg orally per day), following which the VT resolved. We continued magnesium by a continuous infusion (1.4 g/h) after we started propranolol. fMCG revealed a decreased fetal sinus rate from 120 to 110 bpm. The hydrops then improved gradually. The mother's daily total heart beats decreased from 129,108 to 103,206 (average heart rate decreased from 90 to 71 bpm) after propranolol administration, indicating beta-adrenergic blocking effect. Subsequently, the fetal sinus rhythm (rate 110 bpm) was maintained. A 2100-g female infant was delivered by elective cesarean delivery at 37 weeks' gestation. After birth, the infant's electrocardiography showed an intermittent left bundle branch block pattern. On the fifth day of life, she developed second-degree AVB with a ventricular rate of 60–80 bpm and metabolic acidemia owing to poor cardiac output. She urgently underwent temporary epicardial ventricular pacing lead implantation. At the age of 3 months, sustained VT occurred immediately after permanent pacemaker implantation and was successfully terminated by cardioversion. Hypokalemia (serum potassium level was 2.9 mmol/L) during intensive care likely contributed to the VT. VT did not recur after the potassium was corrected. Her genetic testing identified the *KCNH2* missense mutation (T613M), identical to that of her father. She received oral

mexiletine (7 mg/kg/d) and propranolol (3 mg/kg/d) with pacing (VVI 110 bpm) for 23 months.

Discussion

In rare severe cases of congenital LQTS, VT/TdP or the combination of TdP and second-degree AVB during fetal life can cause fetal hydrops and intrauterine fetal demise.⁴ We report the successful intrauterine management of 2 fetuses with ventricular arrhythmias and hydrops. Both had *KCNH2* mutations in the pore region.⁵ But effective intrauterine management was different.

Fetal-onset LQTS is a rare and difficult-to-diagnose condition. In utero, the fetal presentation of LQTS can manifest as a reduced baseline fetal heart rate <3rd percentile for gestational age or 2 standard deviations below the mean for normal fetuses.¹ In more severe cases, ventricular tachycardia, second-degree AVB, and hydrops may be present.⁶ Fetal LQTS has been successfully diagnosed by fMCG.² In the present cases, fMCG proved useful for revealing the fetal arrhythmia and determining the correction of the fetal QT interval.

Intervention should be considered for fetal hydrops attributable to TdP or sustained VT. There are 2 types of intervention: delivery or fetal therapy. Intrauterine man-

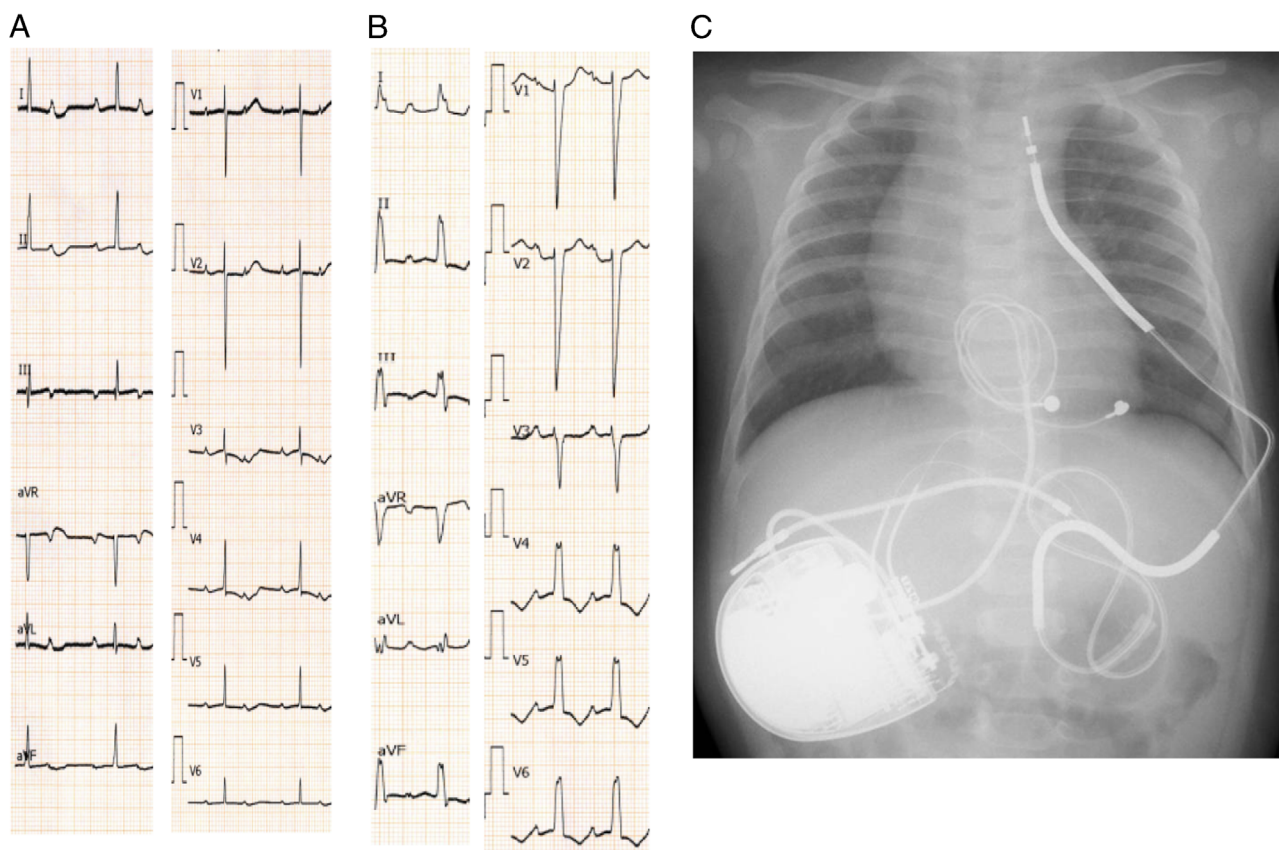


Figure 2 Case 1. **A:** The infant's heart rate at the time of birth was 56 beats per minute (bpm), and he had a 2:1 atrioventricular block. **B:** On the 14th day of life, the electrocardiogram showed a sinus rhythm with a left bundle branch block pattern. **C:** At the age of 5 months, an implantable cardioverter-defibrillator was implanted.

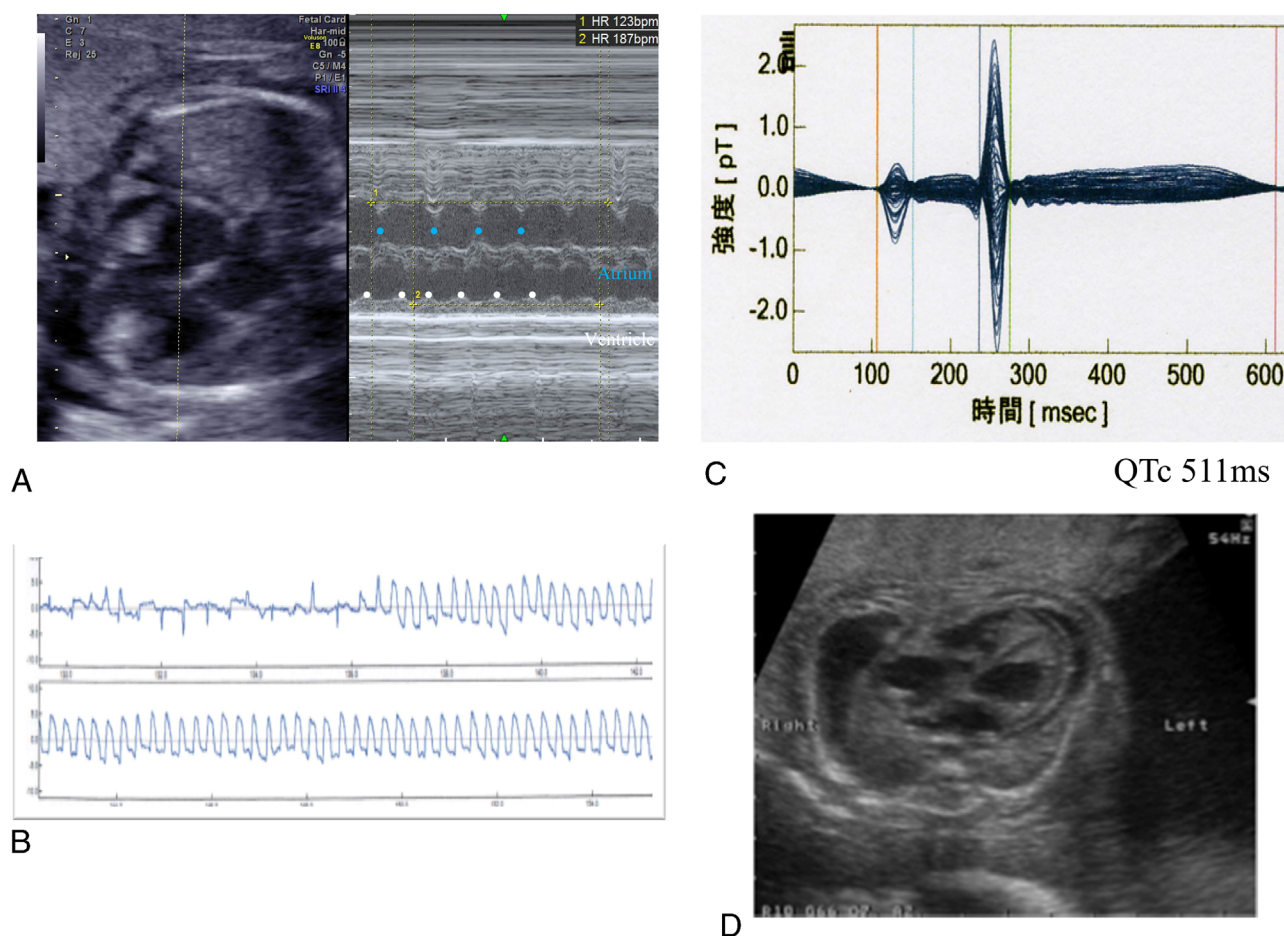


Figure 3 Case 2. **A:** At 24 weeks' gestation, the initial fetal echocardiography showed fetal ventricular tachycardia with a ventricular rate of 187 beats per minute (bpm) and an atrial rate of 123 bpm. **B:** Fetal magnetocardiography (fMCG) revealed sustained ventricular tachycardia with a V rate of 220 bpm. **C:** fMCG showed a prolonged QT interval (511 ms) during transient sinus rhythm. **D:** At this time, the fetus also developed ascites, skin edema, and pericardial effusion as symptoms of severe hydrops.

agement of the fetus with LQTS can control the potentially lethal ventricular arrhythmias and postpone delivery, thus avoiding ICD or pacemaker implantation in a premature infant and other morbidities of prematurity. A few previous reports have detailed the fetal treatment in such cases, but the effective drugs differed between the reports and a consensus regarding appropriate drug selection has not yet been established.³ In case 1, magnesium was effective for the ventricular fibrillation/TdP. Magnesium has successfully restored sinus rhythm in several case reports,⁷ but in our second case beta-blockers were effective for the sustained VT. Magnesium not only reduced the occurrence of 1 type of early afterdepolarization but also abolished it, providing an insight into the mechanism of TdP.⁸ Beta-blockers have a transplacental transfer rate of only 25%–30%, and their therapeutic effect for TdP is limited.¹ However, Chang et al⁹ described successful transplacental therapy for VT using a beta-blocker. In our case, the fetal heart rate during sinus rhythm decreased from 120 to 110 bpm during treatment with propranolol, which may indicate drug effect despite the unfavorable pharmacokinetics.

Transplacental antiarrhythmic drug administration is an effective treatment for the rescue of fetuses that have developed or have a high risk of developing fetal hydrops. However, the selection of the appropriate drugs in these cases has not yet been established and requires further study.

Conclusion

Severe cases of LQTS presenting during fetal life with VT/TdP and hydrops can be successfully treated in utero. Historically, and in the first case described here, intravenous magnesium given to the mother has a high likelihood of terminating VT/TdP. But if magnesium fails, other treatment, including transplacental propranolol, can be considered and would be preferable to the preterm delivery of a hydropic newborn.

References

1. Cuneo BF. The beginnings of long QT syndrome. *Curr Opin Cardiol* 2015;30: 112–117.

2. Cuneo BF, Strasburger JF, Yu S, Horigome H, Hosono T, Kandori A, Wakai RT. In utero diagnosis of long QT syndrome by magnetocardiography. *Circulation* 2013;128:2183–2191.
3. Simpson JM, Maxwell D, Rosenthal E, Gill H. Fetal ventricular tachycardia secondary to long QT syndrome treated with maternal intravenous magnesium: case report and review of the literature. *Ultrasound Obstet Gynecol* 2009;34:475–480.
4. Cuneo BF, Etheridge SP, Horigome H, Sallee D, Moon-Grady A, Weng HY, Ackerman MJ, Benson DW. Arrhythmia phenotype during fetal life suggests long-QT syndrome genotype: risk stratification of perinatal long-QT syndrome. *Circ Arrhythm Electrophysiol* 2013;6:946–951.
5. Shimizu W, Moss AJ, Wilde AA, et al. Genotype-phenotype aspects of type 2 long QT syndrome. *J Am Coll Cardiol* 2009;54:2052–2062.
6. Ishikawa S, Yamada T, Kuwata T, Morikawa M, Yamada T, Matsubara S, Minakami H. Fetal presentation of long QT syndrome—evaluation of prenatal risk factors: a systematic review. *Fetal Diagn Ther* 2013;33:1–7.
7. Cuneo BF, Ovadia M, Strasburger JF, Zhao H, Petropulos T, Schneider J, Wakai RT. Prenatal diagnosis and in utero treatment of torsades de pointes associated with congenital long QT syndrome. *Am J Cardiol* 2003;91:1395–1398.
8. Davidenko JM, Cohen L, Goodrow R, Antzelevitch C. Quinidine-induced action potential prolongation, early afterdepolarizations, and triggered activity in canine Purkinje fibers. Effects of stimulation rate, potassium, and magnesium. *Circulation* 1989;79:674–686.
9. Chang IK, Shyu MK, Lee CN, Kau ML, Ko YH, Chow SN, Hsieh FJ. Prenatal diagnosis and treatment of fetal long QT syndrome: a case report. *Prenat Diagn* 2002;22:1209–1212.