



Contents lists available at ScienceDirect

## International Journal of Surgery Case Reports

journal homepage: [www.casereports.com](http://www.casereports.com)

## Cecal bascule after spinal cord injury: A case series report



Yuichi Ishida\*, Susan F. McLean, Alan H. Tyroch

Texas Tech University Health Sciences Center, Paul L. Foster School of Medicine, Department of Surgery, 4800 Alberta Ave., El Paso, TX 79905, United States

## ARTICLE INFO

## Article history:

Received 19 December 2015  
 Received in revised form 24 March 2016  
 Accepted 24 March 2016  
 Available online 1 April 2016

## Keywords:

Cecal bascule  
 Volvulus  
 Trauma  
 Spinal cord injury  
 Case report

## ABSTRACT

**INTRODUCTION:** Cecal bascule is a rare cause of intestinal obstruction associated with upward and anterior folding of the ascending colon. We report three patients who presented with spinal cord injury complicated with a cecal bascule. Diagnosis and management of cecal bascule is discussed.

**PRESENTATION OF CASES:** Patient 1: 59-year-old male sustained a traumatic brain injury and cervical spinal cord injury after a motorcycle crash. He had abdominal distension and the diagnosis of cecal bascule was made. Cecopexy was performed.

Patient 2: 51-year-old male sustained an unstable C7 vertebral fracture with a cord contusion and quadriplegia after a diving incident. After an unsuccessful medical management of the colonic distension, the patient was taken for a laparotomy and cecal bascule was found. A cecostomy and a cecopexy were performed.

Patient 3: 63-year-old male was transferred after a fall. He had diffuse degenerative changes in the thoracic and lumbar spine. He was found to have a perforated cecal bascule. He had a right hemicolectomy with an ileocolic anastomosis.

**DISCUSSION:** We suggest the possibility of spinal cord injury being a risk factor for cecal bascule. Currently, right hemicolectomy is recommended for the treatment of cecal bascule. Cecopexy is also acceptable treatment option for a case in which the patient will be undergoing an operation with an insertion of hardware.

**CONCLUSION:** The diagnosis of cecal bascule should be considered for trauma patients with cecal distension without delay in order to prevent disastrous complications.

© 2016 The Authors. Published by Elsevier Ltd. on behalf of IJS Publishing Group Ltd. This is an open access article under the CC BY-NC-ND license (<http://creativecommons.org/licenses/by-nc-nd/4.0/>).

## 1. Introduction

Bowel problems, such as constipation and distension, occur in 27%–62% of patients with spinal cord injuries [1]. Acute abdominal pathology might be difficult to diagnose in a spinal cord injury patient due to its indolent course.

Cecal volvulus is axial twisting that involves the cecum, terminal ileum, and ascending colon. Cecal bascule is a rare type of this condition associated with upward and anterior folding of the cecum (Fig. 1) [2,3]. “Bascule”, originally in French, means ‘seesaw’ or ‘counterbalanced bridge’. Cecal bascule is an extremely rare and accounts for less than 0.1% of causes of large bowel obstruction [4,5].

Cecal bascule usually requires surgical management. It is important to make the diagnosis without delay since it can lead to severe complications like colonic perforation or gangrenous necrosis. We present three cases of cecal bascule occurring after spinal cord injury. The importance of promptly identifying this rare diagnosis and providing the appropriate management will be discussed.

## 2. Presentation of cases

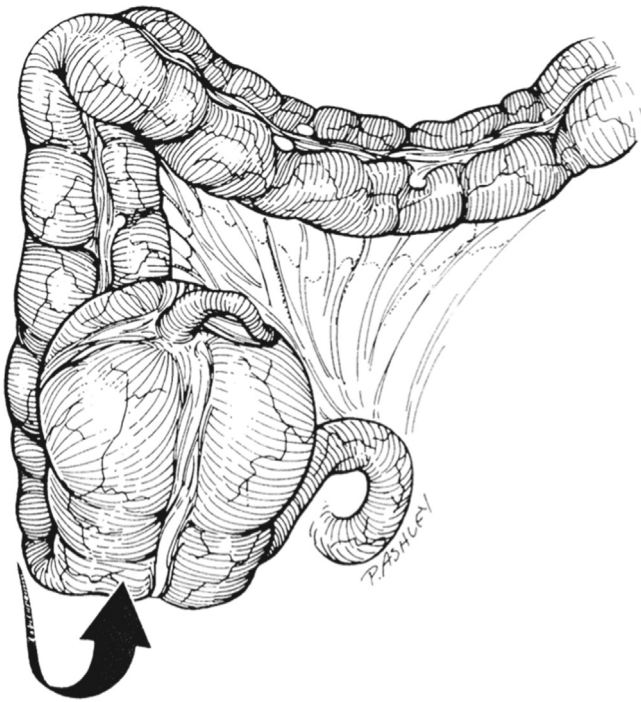
## 2.1. Patient 1

59-year-old male presented after a motorcycle crash with the following injuries: traumatic brain injury, C6–C7 fracture, C5–C6 spinal cord contusion, and T6 fracture. The patient remained bedridden on the ventilator. On the fifth hospital day, abdominal distention led to an abdominal radiograph, which showed marked distension of the cecum (Fig. 2). A subsequent computed tomography (CT) scan showed an anteromedially displaced cecum with 8.2 cm dilation (Fig. 3). Laparotomy was performed for the diagnosis of cecal bascule. Intraoperative findings demonstrated that the cecum was rotated anteriorly in the right upper quadrant. Cecopexy was performed. After the patient had facial fracture repair as well as cervical and thoracic spine fixation, he tolerated a diet and was discharged 31 days after his injury. On one-month follow-up, the patient was in good condition.

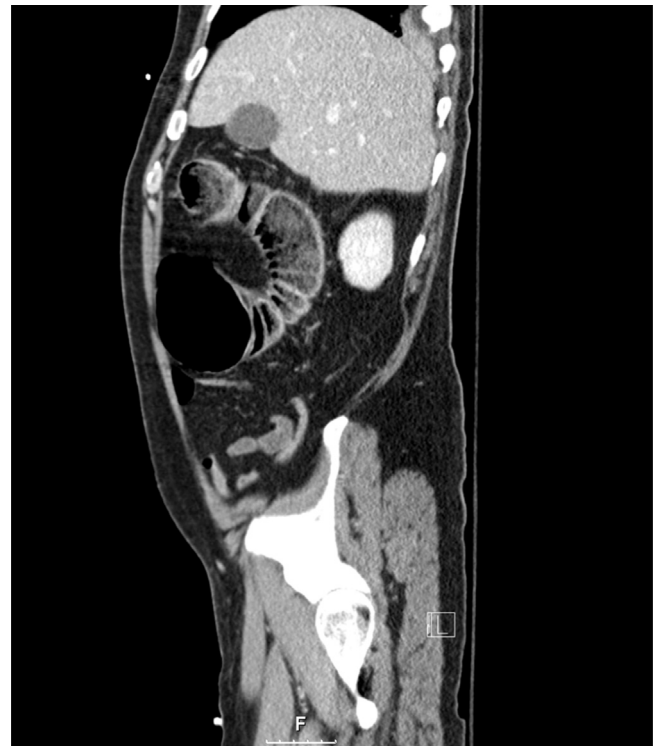## 2.2. Patient 2

51-year-old male was brought in after a diving incident. He sustained an unstable C7 vertebral fracture with a cord contusion and quadriplegia. On the second hospital day, he had his cervical spine

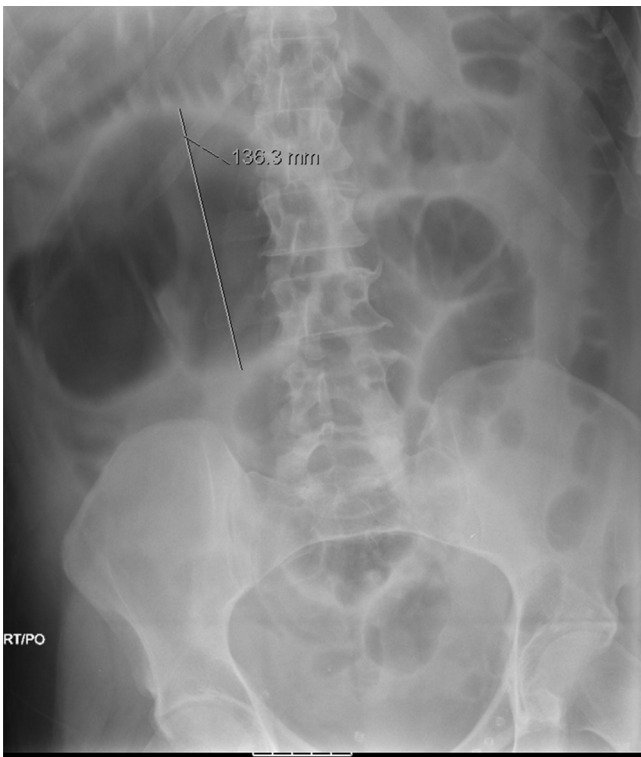
\* Corresponding author at: Texas Tech University Health Sciences Center, Department of Surgery, 4800 Alberta Ave., El Paso, TX 79905, United States.  
 E-mail address: [yuichi.ishida@ttuhsc.edu](mailto:yuichi.ishida@ttuhsc.edu) (Y. Ishida).



**Fig. 1.** Cecal bascule. The mobile cecum folds back upon itself (arrow) causing obstruction. (Reprinted with permission.)

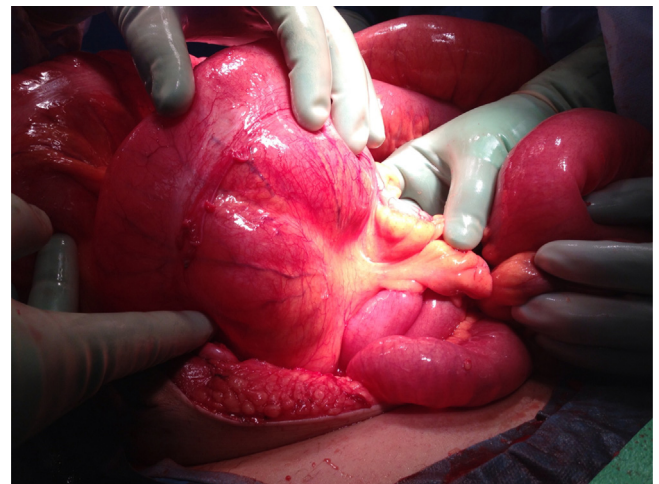


**Fig. 3.** CT sagittal section showing upward folding of the cecum.



**Fig. 2.** Abdominal radiograph showing a distended cecum.

fixation. On the twenty-sixth hospital day, colonic distension was noted. A CT scan did not show evidence of mechanical obstruction. Colonic distension persisted after decompressive colonoscopy and intravenous neostigmine administration. After two weeks of treating presumed Ogilvie syndrome, the patient was taken for a laparotomy. He was found to have a cecal bascule (Fig. 4). The patient was treated with a cecostomy tube using a Malecot drain



**Fig. 4.** Intraoperative finding of freely mobile and distended cecum.

through the appendiceal orifice and a cecopexy was performed. He was advanced to a regular diet and discharged to a rehabilitation hospital. He returned to the hospital once due to cecostomy tube dislodgement and colonic distension, which was treated with endoscopic and radiologic replacement of the cecostomy tube and decompression through the cecostomy tube. On fifteen-month follow-up, the patient was in a stable condition.

### 2.3. Patient 3

63-year-old male with morbid obesity (BMI=52) was transferred from an outlying facility after a fall. He experienced weakness in both legs and then fell. He had multi-degenerative changes to the thoracic and lumbar spine but had no acute injuries. MRI showed diffuse moderate to severe degenerative narrowing of the central spinal canal and the neural foramina. On the ninth hos-

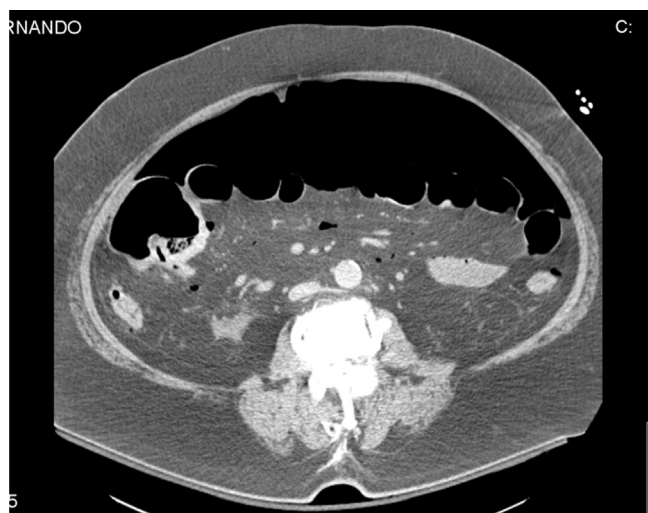

Fig. 5. CT axial section showing pneumoperitoneum with cecal bascule.

pital day, a CT myelogram showed extensive pneumoperitoneum with cecal bascule (Fig. 5). He had no abdominal complaints and abdominal exam was not significant likely due to masking by severe obesity and spinal cord injury. He had a right hemicolectomy with an ileocolic anastomosis. His postoperative course was complicated by a wound infection but he tolerated a diet well and was discharged on the twenty-seventh postoperative day. On two-month follow-up, the patient was in a stable condition.

These cases have been reported in line with the CARE criteria [6].

### 3. Discussion

Cecal bascule typically occurs in patients with a congenital failure of the fusion of the right colon mesentery to retroperitoneal structures that leads to increased cecal mobility. Mobile cecum syndrome presents with chronic intermittent abdominal pain with spontaneous resolution after passage of flatus and is considered as a risk factor for cecal bascule or volvulus [7]. The first patient most likely had this condition considering his pre-existing history of intermittent constipation and bloating with spontaneous resolution after passage of flatus. Other risk factors for cecal volvulus include previous abdominal surgery, high fiber intake, chronic constipation and distal obstruction [8]. Cecal bascule is less likely to strangulate as the mesentery is not frequently twisted compared to volvulus. However, it can still progress to necrosis or perforation which can be life-threatening.

Interestingly, in all the 3 cases spinal cord injury was involved. We suggest the possibility of spinal cord injury being a risk factor for cecal bascule and volvulus. We do not know the exact pathophysiology. However, it might be related to increased incidence of Ogilvie syndrome and bowel distension after spinal cord injury. It is considered that trauma, spinal anesthesia, or pharmacologic agents cause an impairment of the autonomic nervous system and interruption of the visceral parasympathetic fibers leaves an atonic distal colon and a functional proximal obstruction [9]. Nwanguma reported a case of a trauma patient who presented with Ogilvie's syndrome that evolved into a cecal bascule while being treated with neostigmine [10].

An abdominal radiograph is frequently obtained as the initial diagnostic imaging study for cecal bascule since most patients present with abdominal distension. It often shows a dilated cecum suggesting the diagnosis. CT scan confirms the diagnosis of cecal bascule in 90% of patients showing upward folding of the cecum

without torsion [11,12]. CT scan is a very valuable diagnostic tool as it not only distinguishes from other types of cecal volvulus, it also helps to analyze the complications such as circumferential wall thickening, pneumatosis intestinalis, increased density in the mesenteric fat, or pneumoperitoneum [12]. Multidetector CT with three-dimensional reconstruction also allows precise diagnosis by providing accurate assessment of the volvulus [13].

The optimal management for cecal volvulus is operative. There is a 20%–25% risk of cecal necrosis and the failure rate of nonoperative management approaches 95% [14,15]. The treatment strategy is the same for the cecal bascule. Colonoscopic treatment is rarely (5%) successful for cecal bascule and operative treatment is commonly necessary [10]. There are three surgical treatment options: cecopexy, cecostomy tube, and ileocectomy or right hemicolectomy. Cecopexy or cecostomy tube is reserved for debilitated or unstable patients. The recurrence rates vary from zero to 28% and the mortality ranges from zero to 14% [16]. Recurrence rate after right hemicolectomy is almost nonexistent and the mortality rate after resection is reported to be 5%–18% [17].

For the first patient, cecopexy was chosen. The patient had a traumatic brain injury and was bedridden with poor nutritional status. Since the patient needed to have hardware inserted for spinal stabilization, cecopexy was chosen. This decision was based on the concern for the risk of abdominal infection due to spillage or anastomotic failure.

For the second patient, a cecostomy tube was placed with a cecopexy because the entire colon was severely dilated due to concomitant Ogilvie syndrome and it was difficult to make a primary anastomosis. Since the patient was unstable for colectomy at that time, a cecostomy tube was chosen for surgical treatment. The patient had a minor leak around the tube and dislodgement of the tube. Considering these minor complications, a right hemicolectomy with diverting ileostomy or an end ileostomy with a mucous fistula were other options.

For the third patient, a right hemicolectomy with ileocolonic anastomosis was performed since the patient already had perforation. A cecopexy or cecostomy was not indicated. We believe a right hemicolectomy was the best treatment option for the patient.

Current literature recommends avoiding cecostomy since it does nothing to address the underlying cause and may result in tube leakage, infection, colcutaneous fistula, and recurrent torsion [10]. Since the outcome after resectional surgery for an acute cecal volvulus is markedly improved and the recurrence is almost nonexistent, an ileo-colectomy with primary anastomosis should be the preferred surgical treatment [18]. Cecopexy is also acceptable treatment option for a case in which the patient will be undergoing an operation with an insertion of hardware to prevent infection of hardware in the event of an anastomotic leak.

### 4. Conclusion

Cecal bascule is a rare disorder that can be complicated after trauma especially with spinal cord injury. The diagnosis should be considered for trauma patients with cecal distention without delay. The optimal management of cecal bascule is operative. Right hemicolectomy is the preferred surgical treatment, whereas cecopexy is also an acceptable treatment option if hardware is inserted.

### Conflict of interest

No disclosures.

### Funding

Nothing to declare.



### Ethical approval

Written informed consent was obtained from the patient for publication of this case report and accompanying images.

### Consent

Written informed consents were obtained from the patients for publication of this case series report and accompanying images.

### Author contribution

Yuichi Ishida, M.D. Role: Data collection, literature review, and writing the paper.

Susan F. McLean, M.D., F.A.C.S. Role: Study concept, design, and writing the paper.

Alan H. Tyroch, M.D. F.A.C.S., F.C.C.M. Role: Writing the paper.

### Guarantor

I, Yuichi Ishida, M.D. accept full responsibility for the work and/or the conduct of this study, had access to the data, and controlled the decision to publish.

### References

- [1] E. Ebert, Gastrointestinal involvement in spinal cord injury: a clinical perspective, *J. Gastrointest. Liver Dis.* 21 (1) (2012) 75–82.
- [2] D.A. Margolin, C.B. Whitlow, The pathogenesis and etiology of colonic volvulus, *Semin. Colon Rectal Surg.* 18 (1) (2007) 79–86.
- [3] S.G. Harper, Colonic volvulus, *Surg. Colon Rectum Anus* (1995) 657–669.
- [4] P.H. Haskin, S.K. Teplick, J.G. Teplick, M.E. Haskin, Volvulus of the cecum and right colon, *JAMA* 245 (23) (1981) 2433–2435.
- [5] J. Habre, N. Sautot-Vial, C. Marcotte, D. Benchimol, Caecal volvulus, *Am. J. Surg.* 196 (5) (2008) e48–e49.
- [6] J.J. Gagnier, G. Kienle, D.G. Altman, D. Moher, H. Sox, D. Riley, Group C. The CARE guidelines: consensus-based clinical case report guideline development, *J. Clin. Epidemiol.* 67 (1) (2014) 46–51.
- [7] E.T. Consorti, T.H. Liu, Diagnosis and treatment of caecal volvulus, *Postgrad. Med. J.* 81 (962) (2005) 772–776.
- [8] J. Ramsingh, R. Hodnett, T. Coyle, A. Al-Ani, Bascule caecal volvulus: a rare cause of intestinal obstruction, *J. Surg. Case Rep.* 2014 (4) (2014).
- [9] W.H. Ogilvie, William Heneage Ogilvie, 1887–1971. Large-intestine colic due to sympathetic deprivation. A new clinical syndrome, *Dis. Colon Rectum* 30 (12) (1987) 984–987.
- [10] O.R. Nwanguma, K. Matsushima, R. Grunfeld, H.L. Frankel, Colonic pseudo-obstruction (Ogilvie's syndrome) evolving into cecal bascule, *J. Trauma* 71 (4) (2011) 1082–1084.
- [11] Nihar Shah, Hiren Patel, Varun Patel, Robert Spira, Cecal bascule after colonoscopy—case report and review of literature, *North Am. J. Med. Sci.* 8 (3) (2015) 143–145.
- [12] E. Delabrousse, P. Sarlieve, N. Sailley, S. Aubry, B.A. Kastler, Cecal volvulus: CT findings and correlation with pathophysiology, *Emerg. Radiol.* 14 (6) (2007) 411–415.
- [13] C. Vandendries, M.C. Jules, I. Boulay-Coletta, J. Loriau, M. Zins, Diagnosis of colonic volvulus: findings on multidetector CT with three-dimensional reconstructions, *Br. J. Radiol.* 83 (995) (2010) 983–990.
- [14] W.J. Halabi, M.D. Jafari, C.Y. Kang, V.Q. Nguyen, J.C. Carmichael, S. Mills, A. Pigazzi, M.J. Stamos, Colonic volvulus in the United States: trends, outcomes, and predictors of mortality, *Ann. Surg.* 259 (2) (2014) 293–301.
- [15] S.Y. Lee, M. Bhaduri, Cecal volvulus, *CMAJ* 185 (8) (2013) 684.
- [16] S.A. Shoop, J.M. Sackier, Laparoscopic cecopexy for cecal volvulus: case report and a review of the literature, *Surg. Endosc.* 7 (5) (1993) 450–454.
- [17] B.R. Swenson, M.R. Kwaan, N.E. Burkart, Y. Wang, R.D. Madoff, D.A. Rothenberger, G.B. Melton, Colonic volvulus: presentation and management in metropolitan Minnesota, United States, *Dis. Colon Rectum* 55 (4) (2012) 444–449.
- [18] T. Katoh, T. Shigemori, R. Fukaya, H. Suzuki, Cecal volvulus: report of a case and review of Japanese literature, *World J. Gastroenterol.* 15 (20) (2009) 2547–2549.

### Open Access

This article is published Open Access at [sciendoirect.com](http://sciendoirect.com). It is distributed under the [IJSCR Supplemental terms and conditions](#), which permits unrestricted non commercial use, distribution, and reproduction in any medium, provided the original authors and source are credited.