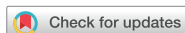

Research Article



Clinical and radiographic outcomes of regenerative endodontic treatment performed by endodontic postgraduate students: a retrospective study

Hadi Rajeh Alfahadi ,¹ Saad Al-Nazhan ,² Fawaz Hamad Alkazman ,³ Nassr Al-Maflehi ,⁴ Nada Al-Nazhan ^{1*}

¹College of Dentistry, Riyadh Elm University, Riyadh, Saudi Arabia

²Department of Restorative Dentistry – Endodontics, College of Dentistry, Riyadh Elm University, Riyadh, Saudi Arabia

³Periodontitis, Ministry of Health, Riyadh, Saudi Arabia

⁴Department of Preventive Dental Sciences – Biostatistics, College of Dentistry, King Saud University, Riyadh, Saudi Arabia



Received: Aug 25, 2021

Revised: Oct 21, 2021

Accepted: Nov 3, 2021

Published online: May 9, 2022

Alfahadi HR, Al-Nazhan S, Alkazman FH,
Al-Maflehi N, Al-Nazhan N

*Correspondence to

Saad Al-Nazhan, BDS, MSD

Professor, Department of Restorative Dentistry – Endodontics, College of Dentistry, Riyadh Elm University, P.O. Box 84891, Riyadh 11681, Saudi Arabia.

Email: saadnazhan@gmail.com

Copyright © 2022. The Korean Academy of Conservative Dentistry

This is an Open Access article distributed under the terms of the Creative Commons Attribution Non-Commercial License (<https://creativecommons.org/licenses/by-nc/4.0/>) which permits unrestricted non-commercial use, distribution, and reproduction in any medium, provided the original work is properly cited.

Conflict of Interest

No potential conflict of interest relevant to this article was reported.

ABSTRACT

Objectives: Regenerative endodontic treatment is a clinical procedure aimed at biologically regenerating damaged root canal tissue of immature permanent teeth. This study aimed to report the outcomes of regenerative endodontic treatment performed by endodontic postgraduate students.

Materials and Methods: Clinical and radiographic data of 27 patients, aged 10–22 years, who underwent regenerative treatment of immature permanent teeth from 2015 to 2019 were followed up, wherein clinical and radiographic examinations were performed for each patient. Postoperative success rate and tooth survival were analyzed, and the postoperative radiographic root area changes were quantified.

Results: A total of 23 patients attended the dental appointments, showing that all teeth survived and were asymptomatic. Specifically, 7 periapical pathosis cases were completely healed, 12 were incompletely healed, and 4 cases failed. Moreover, significant differences were found between discolored and non-discolored teeth, and between the presence or absence of periapical radiolucency. Additionally, 3 anterior teeth showed complete closure of the apical foramen, while the apical foramen width was reduced in 17 teeth and failed in 3 teeth. Root length was also found to have been increased in 7 anterior and 4 posterior teeth, and the average length ranged from 4.00–0.63 mm in the anterior teeth, 2.85–1.48 mm of the mesial root, and 2.73–2.16 mm of the molar teeth distal root. Furthermore, calcified tissue deposition was observed in 7 teeth.






Conclusions: A favorable outcome of regenerative endodontic treatment of immature permanent teeth with necrotic pulp was achieved with a high survival rate.

Keywords: Immature teeth; Necrotic pulp; Open apex; Regenerative endodontic; Treatment outcome

Author Contributions

Conceptualization: Al-Nazhan S; Data curation: Al-Nazhan S, Alfahadi HR, Al-Maflehi N; Formal analysis: Al-Maflehi N; Investigation: Al-Nazhan S, Alfahadi HR, Alkazman FH, Al-Nazhan N; Methodology: Al-Nazhan S, Alfahadi HR; Project administration: Alfahadi HR; Software: Al-Maflehi N; Supervision: Al-Nazhan S; Validation: Al-Nazhan S, Alfahadi HR; Visualization: Al-Nazhan N; Writing - original draft: Al-Nazhan S; Writing - review & editing: Al-Nazhan S.

ORCID iDs

Hadi Rajeh Alfahadi 
<https://orcid.org/0000-0002-0644-6420>
Saad Al-Nazhan 
<https://orcid.org/0000-0002-5997-0330>
Fawaz Hamad Alkazman 
<https://orcid.org/0000-0002-0085-8205>
Nassr Al-Maflehi 
<https://orcid.org/0000-0003-4931-6340>
Nada Al-Nazhan 
<https://orcid.org/0000-0002-3416-0390>

INTRODUCTION

Dealing with a necrotic immature tooth with apical periodontitis is usually difficult and challenging. The traditional apexification technique has several potential drawbacks and the conventional endodontic therapy cannot be consistently achieved [1]. Regenerative endodontics has been proposed as a favored alternative treatment option to manage such cases.

Regenerative endodontic therapy is a clinical procedure that treats teeth with the necrotic pulp of immature roots, with or without the apical disease. The therapy is defined as a biologically based procedure designed to replace damaged structures, including dentin and pulp-dentin complex cells [2]. Moreover, it uses the concept of tissue engineering to restore the root canals to a healthy state, allowing for continued development of the root and surrounding tissue, as well as increased dentinal wall thickness and apical closure [3-5].

The clinical protocol for regenerative endodontic therapy “revascularization” was introduced, wherein bleeding is stimulated from the periapical tissues after performing a modified disinfection technique, forming a blood clot within the canal. This is hypothesized to provide a scaffold, growth factors, and possibly stem cells that support continued root formation [3,6,7].

Although most studies have shown that regenerative endodontic therapy has the potential to promote canal wall thickening and continued root development (secondary goal), these observations are not always predictable [8,9]. Various techniques have been described with conflicting results of the success and survival of the studied teeth [10]. Additionally, even if the collected outcomes of regenerative endodontic therapy and those performed by the faculties with or without postgraduate residents have been reported, resident cases alone have only been evaluated in a few unpublished studies [9,11-15]. Therefore, this study aimed to report the outcomes of regenerative endodontic treatment performed by endodontic postgraduate students.

MATERIALS AND METHODS

The current study was approved by the Scientific Research and Ethics Committee, IRB approval number RC/IRB/2019/221. The records of 27 patients aged from 10 to 22 years old who underwent revascularization treatment of immature permanent teeth at the College of Dentistry, Riyadh Elm University, which were performed by endodontic postgraduate students from 2015 to 2019, were retrieved using the University Clinical Electronic System. None of the personal information of the patient was revealed in accordance with the regulations of the Health Insurance Portability and Accountability.

Regenerative endodontic therapy clinical protocols were standardized at the university clinics. The procedure is based on the recommendations of the American Association of Endodontics [16]. It was done in 2–3 visits under aseptic conditions. The canal was irrigated with 20 mL of 1.5% sodium hypochlorite after accessing the pulp chamber and working length determination followed by saline and/or EDTA with minimal or no instrumentation. The canals were filled with calcium hydroxide as intracanal medicament and the access cavity was sealed with glass ionomer filling material (GC Fuji II LC, GC America, Alsip, IL, USA). Triple antibiotic paste (400 mg of metronidazole, 250 mg of ciprofloxacin, and 50 mg of minocycline mixed in the proportion of 1:1) was used in one case only. Genteel laceration of the apical tissue to induce bleeding into the canal was done and a double seal of mineral trioxide aggregate (MTA;

ProRoot, Dentsply Tulsa, Tulsa, OK, USA) was used as capping material. The access cavity was closed with permanent resin restoration (Dentsply Spectrum, Jacksonville, FL, USA). All cases were performed under the supervision of the endodontic staff.

Afterwards, the patient records were reviewed, using a special form (one for each tooth) to collect the required information. Then, age, sex, medical status, and reason for revascularization treatment were collected. Moreover, pulpal and periapical diagnosis, type of treatment performed, history, and any complications that occurred during or after treatment, were documented.

Following data collection, the clinical database query was reviewed for follow-up eligibility using the following specific inclusion criteria:

1. Revascularization treatment, radiographic, and restorative records.
2. Treatment, which was done for at least 6 months.
3. Non-vital immature tooth.
4. Treatment performed by a postgraduate student.

Cases with missing information, incomplete records, and treatments performed by undergraduate students or university dental staff were excluded.

Each patient was called for a follow-up appointment and informed about the importance of the visit and the steps to be performed, whereas non-responders were contacted again to encourage them to attend. Each patient was allotted 15–20 minutes for the clinical examinations of the following: clinical signs and symptoms, coronal restoration status, and gingival and periodontal condition. A radiograph of the involved tooth was taken and evaluated for the presence or absence of periapical radiolucency, resorption, calcification, and radiographic root dimension changes, wherein the apical foramen width and root length were measured from both the preoperative and recall radiographic images using the Sidex radiographic program (Dentsply, Sirona, NC, USA). Moreover, radiographic periapical pathosis changes were checked, on the basis of clinical and radiographic finding evaluations depending on both survival (retention of the tooth in its socket at the time of the follow-up visit) and success using criteria from Alobaid *et al.* [8], Saoud *et al.* [12] and Jeeruphan *et al.* [17].

To quantify radiographic root dimension changes, the radiographic root area, apical foramen width, and root length were measured using both the preoperative and recall radiographs. The technique of Alobaid *et al.* [8] was followed using the ImageJ software program (National Institutes of Health, Bethesda, MD, USA). The preoperative and postoperative radiographic images were opened in the ImageJ software program, and then were aligned using the TurboReg plugin to minimize any dimensional changes. After alignment, the radiographic root area, root length, and root width were measured. Every measurement was completed in duplicate and averaged. In case of distortion problems between the 2 radiographs, a new exposure is taken or uses those films taken during early follow-up.

Treatment outcomes were assessed using the criteria of Bukhari *et al.* [13], which consisted of the following categories:

1. Complete healing; no clinical signs and symptoms, complete resolution of apical radiolucency, increased root and apical closure width/length.
2. Incomplete healing; no clinical signs and symptoms, the periapical lesion completely healed without any changes in terms of root maturation or thickening, periapical

radiolucency size is reduced or unchanged with/without increasing root dentin thickness/length radiographic signs, or apical closure.

3. Failure; persistent clinical signs and symptoms, persistent or increased peripheral radiolucency size with no apical closure.

The operator reviewed the history and data records of the entire revascularization treatment, and 2 qualified endodontists reviewed the clinical and radiographic examination results using a data collection form for each case. Preoperative and postoperative factors were evaluated for each tooth, and outcome assessment was reviewed, jointly reassessing the disagreement between the evaluators.

Statistical analysis

The data were collected, tabulated, and analyzed using the IBM SPSS software package version 25 (IBM Corp., Armonk, NY, USA). The McNemar and χ^2 for the goodness of fit tests were used to compare the proportion of cases with or without periapical radiolucency and with or without apical foramen closure on follow-up from 6 to 36 months versus the baseline proportion of cases. Inter- and intra-examiner reliability was measured using the Cohen's kappa coefficient (κ). All tests were interpreted at a 5% significance level ($p \leq 0.05$).

RESULTS

Of the 27 recalled patients, only 23 attended follow-up examinations, wherein the number of male patients (55.56%) was higher than that of female patients. The average follow-up time was 20 months for anterior and 17 months for posterior teeth. The patient demographics and baseline characteristics are summarized in **Table 1**. Anterior tooth trauma was the most common etiological factor of the disease as compared to posterior tooth caries, but there was no significant difference ($p = 0.411$). Asymptomatic apical periodontitis was 70.37% of the cases. The number of anterior teeth that received regenerative endodontic treatment was almost similar to that of the posterior teeth (**Table 1**).

Table 1. Patient demographics and baseline characteristics of the collected cases ($n = 27$)

Characteristics	Teeth (%)	<i>p</i> value
Sex		0.411
Male	15 (55.56)	
Female	12 (44.44)	
Etiology		0.411
Caries	12 (44.44)	
Trauma*	15 (55.56)	
Tooth type		0.784
Anterior	14 (51.85)	
Posterior	13 (48.15)	
Tooth location		0.784
Mandibular	13 (48.15)	
Maxillary	14 (51.85)	
Pulp diagnosis		
Necrotic†	27 (100)	
Periapical diagnosis		0.000
Asymptomatic apical periodontitis	19 (70.37)	
Symptomatic apical periodontitis	7 (25.93)	
Chronic apical abscess	1 (3.70)	

*One tooth had avulsion and one had cervical root resorption; †Three teeth failed the vital pulp therapy and was diagnosed with pulp necrosis.

Table 2. Clinical and radiographic findings of the evaluated cases ($n = 23$)

Characteristics	Teeth (%)	p value
Crown discoloration		0.0001
Discolored	7 (30.43)	
No discoloration	16 (69.57)	
Coronal restoration		0.019
Good (intact)	11 (47.80)	
Poor (open margin, recurrent caries, temporary filling)	10 (43.50)	
None	2 (8.70)	
Periapical radiolucency		0.0001
Absent	7 (30.43)	
Present	16 (69.57)	
Calcification		0.000
Intracanal	5 (21.74)	
Apical	2 (8.70)	

The observation period ranged from 6–36 months, and inter- and intra-examiner agreements were $\kappa = 0.75$ and 0.8 , respectively.

Clinical and radiographic findings of the evaluated cases are summarized in **Table 2**, showing significant differences between discolored and non-discolored teeth and the presence and absence of periapical radiolucency ($p = 0.0001$).

All treated teeth were found to be asymptomatic before and after treatment, and they had survived during the follow-up period. Specifically, 7 cases (30.43%) healed completely and were considered successful (**Figure 1**), 12 cases had incomplete healing (52.17%) (**Figure 2**), and 4 cases failed (17.4%) (**Figure 3**).

Periapical radiolucency was seen in 4 teeth (failed cases) and was reduced in size in 12 teeth (incomplete healing cases). Additionally, canal calcification was observed in 7 cases (**Table 2**).

The distribution of complete healing, incomplete healing, and failure within trauma (4, 7, and 3, respectively) were significantly different ($p = 0.023$). Meanwhile, the distribution of complete healing, incomplete healing, and failure were 3, 5, and 1, respectively, within caries ($p = 0.002$). However, the association between healing status and patient characteristics (caries, trauma, and dens vaginitis) was not significant (Fisher exact $p = 0.501$), meaning that the healing status pattern or the distribution of caries and trauma were the same (**Table 3**).

Moreover, the distribution of complete healing, incomplete healing, and failure within the anterior teeth (4, 7, and 3, respectively) was significantly different ($p = 0.023$). On the other hand, the distribution of complete healing, incomplete healing, and failure (3, 5, and 1, respectively) within the posterior teeth was also significantly different ($p = 0.002$). Despite these findings, the association between healing status and tooth type (anterior and posterior)

Table 3. Relationship between post-treatment healing status (outcome) and patient characteristics/tooth type

Characteristic/Tooth type (Etiology)	Healing status			Total	p value	
	Complete	Incomplete	Failure		t -test	Fisher's exact test*
Trauma (anterior)	4 (28.6)	7 (50)	3 (21.4)	14 (100)	0.023†	0.501*
Caries (posterior)	3 (33.3)	5 (55.6)	1 (11.1)	9 (100)	0.002†	
Total	7	12	4	23		

*Fisher's exact test was used to test the association between etiology levels and Healing status in place of χ^2 test, since χ^2 not failed to be used (there was more than 20% of expected cells had less than 5 observations then merging cells was done); †Proportions t -test or multinomial test was used to compare healing status levels within each etiology levels (trauma and caries).

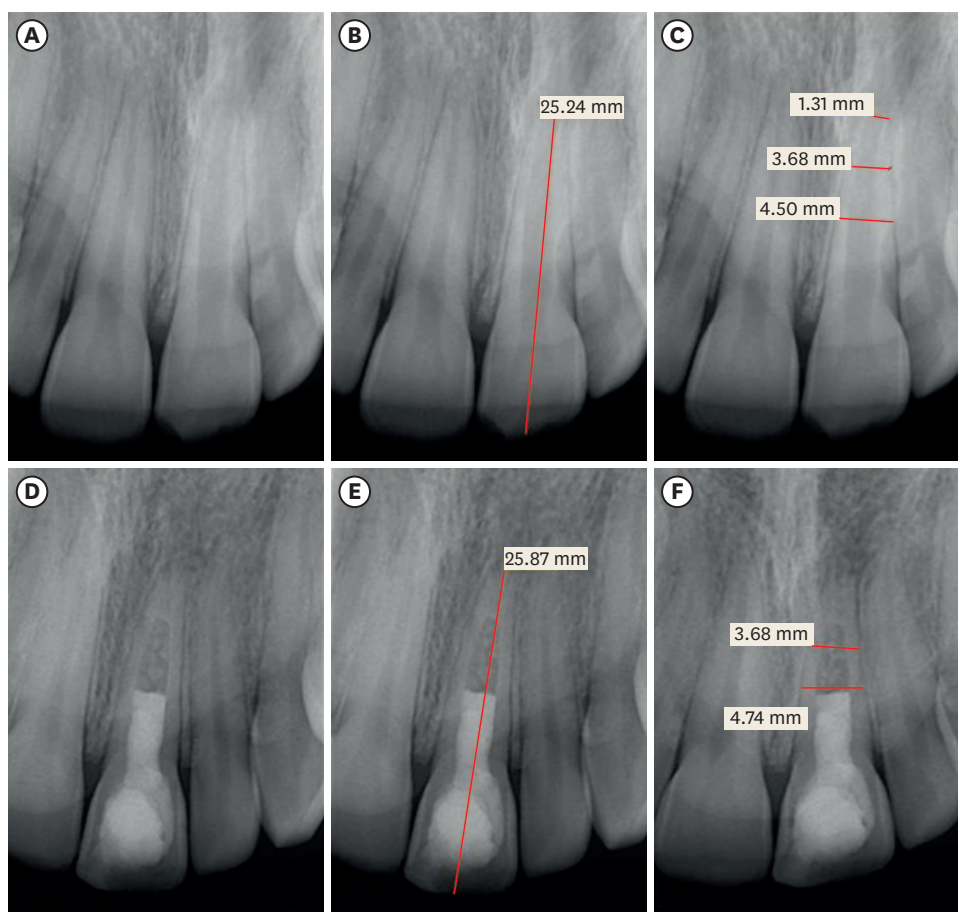


Figure 1. Maxillary left central incisor with open apex and apical radiolucency due to trauma (A-C). Calcium hydroxide was used as an intracanal medicament and the access was filled with mineral trioxide aggregate. 31-month postoperative radiographic follow-up shows complete apical closure, an increase in the tooth length, and healed (complete) apical radiolucency (D-F).

was not significant (Fisher exact $p = 0.502$), indicating that the healing status pattern or the distribution for the anterior and posterior regions were the same (**Table 3**).

The changes in root dimension, length, and apical foramen width of the recalled teeth are listed in **Tables 4** and **5**. Exactly 3 anterior teeth showed complete apical foramen closure, while the apical foramen width was reduced in 17 teeth and failed in 3 teeth. Root length was increased in 7 anterior and 4 posterior teeth, with an average length ranging from 4.00–0.63 mm in the anterior teeth, 2.85–1.48 mm of the mesial root, and 2.73–2.16 mm of the molar teeth distal roots.

DISCUSSION

Immature permanent teeth with necrotic pulp secondary to trauma or caries are difficult to manage due to thin dentinal root walls that may fracture during or after treatment. Moreover, the absence of apical stops makes it difficult to fill the canal using traditional root canal filling materials. As a way to circumvent this, these teeth are currently managed by regenerative endodontic treatment, which allows the continued development of the root

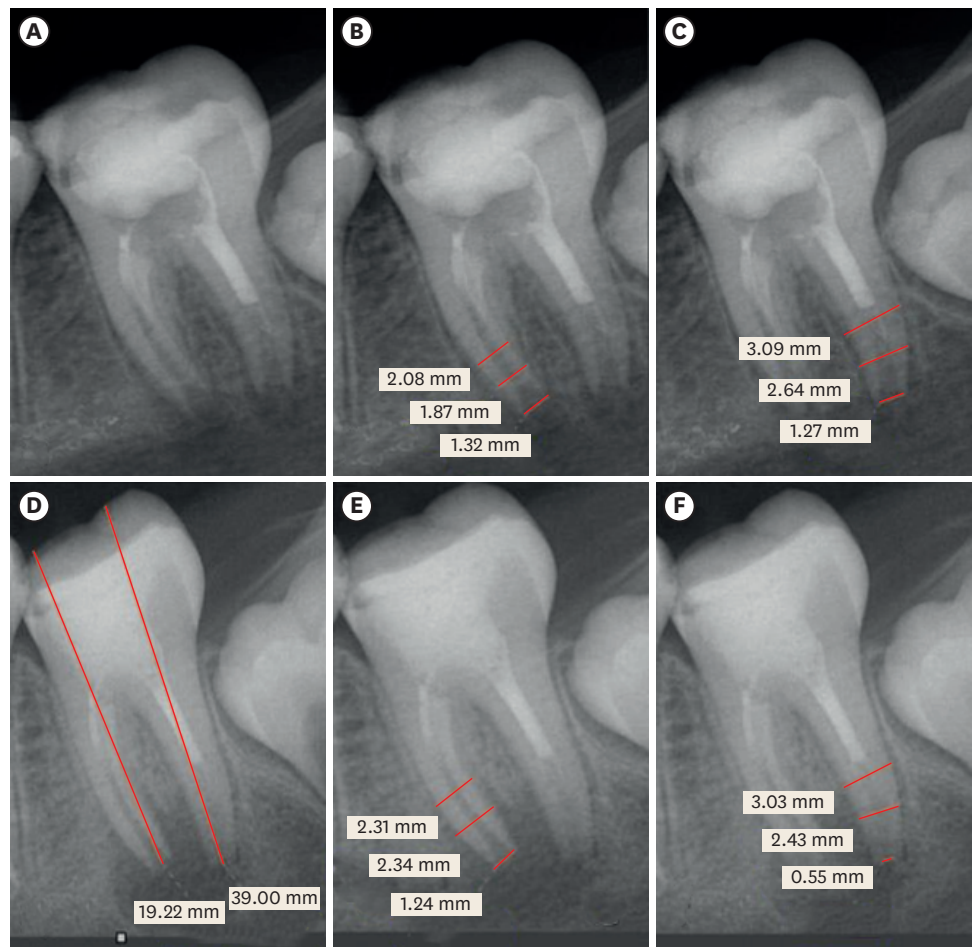


Figure 2. Mandibular left the second molar of 13-years old female patient with the open apex of both mesial and distal root and apical radiolucency due to caries. Calcium hydroxide was used as an intracanal medicament and the access and part of the canals were filled with mineral trioxide aggregate (A-C). 9 months post-operative radiograph shows complete apical closure of the distal root and reduction of the apical foramen width of the mesial root regardless of the increased apical radiolucency (D-F).

[4]. Infection control and blood clot formation are essential for connective tissue healing at the immature tooth apex, wherein blood clot formation in the root canal space seems to be organized by granulation tissue growth from the periapical area [18].

Kappa (κ) test was used to test the agreement between observer 1 and observer 2 and $\kappa = 0.81$ greater than 0.7 with p value = 0.000. Also, the intra-examiner was measured by measuring the agreement between the same observer twice in time and κ was 0.78 greater than 0.7 with p value = 0.000. The Kappa scores were considered very good following the criteria of Landis and Koch [19]. These results are almost similar to those of Jeeruphan *et al.* [17] and are better than those of Kahler *et al.* [11] who reported moderate reliability (0.46).

The number of teeth evaluated in the present study was low, which is similar to those in previously published retrospective cohort studies [8,11,14,15,17]. Additionally, all evaluated teeth, including those of patients who did not attend follow-up, survived (100%) during the follow-up period, which is in accordance with the findings of Saoud *et al.* [12], Bukhari *et al.* [13], Chatha [14], Jeeruphan *et al.* [17], and Cehreli *et al.* [20].

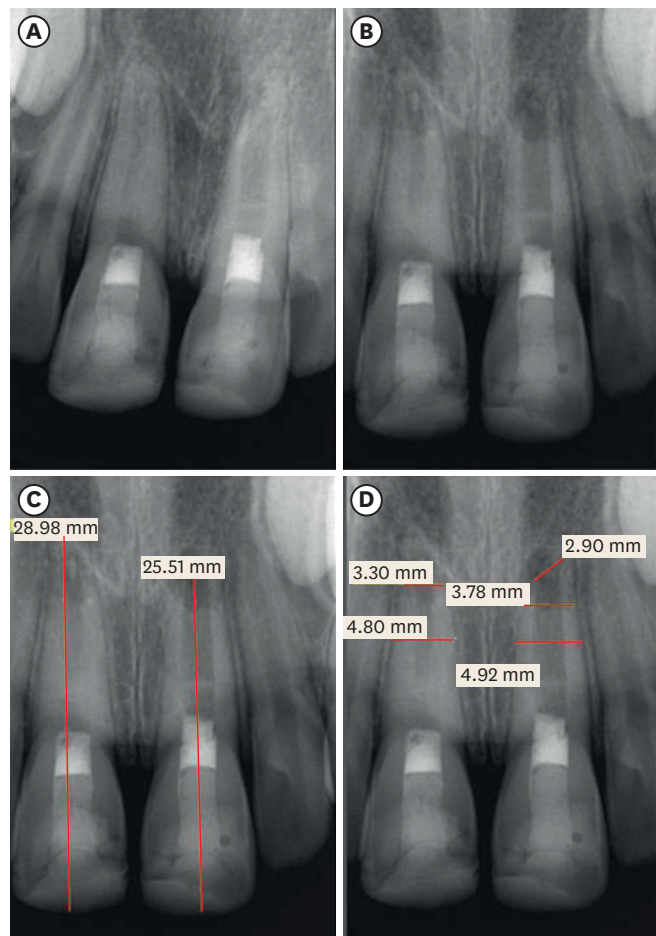


Figure 3. Maxillary left central incisor of 11-years old male patient with open apex and no apical radiolucency due to trauma. Calcium hydroxide was used as an intracanal medicament and the access and part of the canals were filled with mineral trioxide aggregate (A). The 6-months (B) and 12-months (C, D) post-operative radiograph shows the development of periapical radiolucency and the apical foramen failed to close.

Regarding periapical pathosis, 7 cases (30.43%) were completely healed and 12 cases revealed enhanced but incomplete healing (52.17%), which gives a success rate prediction of 82.6% using the condition's more lenient definition [21]. Given that all patients were free of clinical signs and symptoms, the chance of complete resolution in periapical pathosis cases that falls in the category of complete healing is reasonably high with a good chance for the tooth to remain asymptomatic and functional over time, provided that the tooth is well restored [21]. A study by Strindberg [22] further considered the absence of periapical radiolucency as a well-established measure of favorable healing outcomes. The pathological apical microenvironment can reserve its hard tissue formation ability, albeit to some degree and in a disturbed manner [23]. As a result, periapical pathosis might heal with fibrous periapical tissue (apical scar), showing bony trabeculation reduction or no changes with the tooth as it remains asymptomatic [24,25]. Based on previous studies, Kahler *et al.* [11] reported the resolution of periapical radiolucency in 90.3% of treated teeth, and Shah *et al.* [26] reported a resolution of 78%. In comparison, the findings of the present study (82.6%) fell between. Furthermore, Kahler *et al.* [11] suggested no further treatment in teeth with evidence of resolution of periapical pathology, even if no further root maturation has occurred.

Outcomes of regenerative endodontic treatment
Table 4. Changes of root length and apical foramen width of anterior teeth

Case	Tooth	Sex	Age	Root dimensions (mm)		Root length (mm)		Apical foramen width (mm)	
				Before	After	Before	After	Before	After
1	21	Female	14	Middle 4.50 Apical 3.68	4.74 3.68	25.24	25.87	1.31	0.00
3	11	Male	11	Middle 4.81 Apical 3.91	4.80 3.30	25.24	28.98	2.53	0.00
4	21	Male	11	Middle 4.92 Apical 4.09	4.92 3.78	22.82	25.51	1.66	2.90
5	11	Male	17	Middle 5.73 Apical 4.16	5.19 3.65	29.04	23.61	1.52	1.37
8	11	Male	10	Middle 6.14 Apical 5.07	6.26 4.67	21.40	23.55	4.00	2.02
9	21	Male	12	Middle 5.31 Apical 4.06	5.33 3.87	22.62	26.62	1.75	0.00
11	21	Female	19	Middle 5.07 Apical 3.59	4.20 3.21	20.02	17.32	2.34	2.18
12	11	Female	22	Middle 4.72 Apical 3.92	4.68 4.02	18.46	18.12	2.15	2.69
13	11	Male	10	Middle 6.20 Apical 5.05	5.60 4.40	26.16	25.04	3.42	3.31
16	11	Female	12	Middle 4.46 Apical 3.21	4.28 3.54	19.58	18.49	0.70	0.38
17	21	Female	30	Middle 5.80 Apical 4.27	6.10 4.36	28.46	28.66	1.57	0.80
21	21	Male	17	Middle 5.29 Apical 4.05	4.60 3.40	26.36	25.74	2.82	2.41
22	11	Female	14	Middle 4.50 Apical 3.39	4.38 3.57	19.88	19.49	0.60	0.34

Tooth type is based on the 2-digit Federation Dentaire Internationale numbering system.

The success rate of the present study was similar to that of Sedwick [15], but it was slightly lower compared to those of Saoud *et al.* [12], Jeeruphan *et al.* [17], and Cehreli *et al.* [20]. A high rate of clinical success (78% and 100%) and radiographic periapical lesion healing (93% and 100%) subsequent to regenerative treatment of immature teeth have been reported by several investigators [8,17,27]. However, a systemic review of the outcomes of this treatment reported a high number of failures (approximately 39%) 2 years after treatment initiation, which was due to tooth discoloration, fracture, signs of periapical pathosis, and presence of clinical symptoms [28]. Moreover, these studies vary depending on the type of study conducted as well as the factors that were considered to assess the success and failure outcomes [8,17,27-29]. This variation in the success and failure rates of the published reports could be attributed to several reasons as summarized by Almutairi *et al.* [28] and Lee *et al.* [30]: 1) no standardized technique was followed; 2) inadequate disinfection protocol; 3) insufficient healing process knowledge; and 4) type of scaffolds used.

Two retrospective studies were done evaluating endodontists and endodontic residents. Bukhari *et al.* [13] evaluated the outcome of 28 revascularized necrotic immature teeth of residents and faculty members at the University of Pennsylvania. Twenty-one (75%) healed completely, 4 cases (14%) presented with incomplete healing completely and 3 cases (10.7%) failed. Chatha [14] conducted a master thesis evaluating 28 cases treated by regenerative endodontic procedure that was performed by Endodontists (21 cases) and endodontic residents (7 cases). The absence of clinical symptoms and resolution of apical pathosis were shown in 27 cases (96.4%) at one-year follow-up; root width was increased in 19 cases (67.9%) and the root length was increased in 15 cases (53.6%). The results of the current

Outcomes of regenerative endodontic treatment

Table 5. Changes of root length and apical foramen width of posterior teeth

Case	Tooth	Sex	Age	Root dimensions (mm)		Root length (mm)		Apical foramen width (mm)		
				Before	After	Before	After	Before	After	
2	36	Female	14	Mesial root		Mesial 10.62	12.40	0.49	0.52	
				Middle	2.51	2.44				
				Apical	2.26	2.31				
				Distal root			Distal 9.92			
				Middle	2.84	2.71				
6	37	Female	13	Mesial root		Mesial 17.74	19.22	1.32	1.24	
				Middle	2.08	2.31				
				Apical	1.87	2.34				
				Distal root			Distal 18.66			
				Middle	3.09	3.03				
7	46	Male	13	Mesial root		Mesial 17.15	16.92	0.88	0.57	
				Middle	1.76	1.65				
				Apical	1.54	1.82				
				Distal root			Distal 18.84			
				Middle	3.07	2.28				
10	47	Male	13	Mesial root		Mesial 17.22	16.29	0.93	0.66	
				Middle	2.38	2.95				
				Apical	2.28	2.95				
				Distal root			Distal 17.04			
				Middle	2.36	3.07				
14	46	Female	10	Mesial root		Mesial 17.09	19.94	1.11	0.62	
				Middle	2.35	1.83				
				Apical	2.09	1.83				
				Distal root			Distal 16.64			
				Middle	2.84	2.74				
15	46	Female	10	Mesial root		Mesial 17.10	19.95	1.10	0.60	
				Middle	2.33	1.81				
				Apical	2.09	1.83				
				Distal root			Distal 16.74			
				Middle	2.84	2.74				
18	45	Male	14	Middle	5.44	5.67	19.52	20.10	1.28	0.56
				Apical	4.74	4.76				
19	24	Male	14	Middle	3.72	3.90	17.21	17.22	0.82	0.81
				Apical	2.78	2.87				
20	46	Female	10	Mesial root		Mesial 17.09	16.92	1.11	1.56	
				Middle	2.35	1.95				
				Apical	2.09	1.78				
				Distal root			Distal 16.47			
				Middle	3.38	2.48				
23	46	Female	10	Mesial root		Mesial 17.09	17.22	1.67	2.24	
				Middle	2.64	1.76				
				Apical	2.39	1.68				
				Distal root			Distal 15.68			
				Middle	3.87	2.65				
				Apical	3.17	2.13	15.42	1.37	1.55	

Tooth type is based on the 2-digit Federation Dentaire Internationale numbering system.

study cannot be compared to Bukhari *et al.* [13] and Chatha [14]. All cases of the current study were treated by Endodontic residents following a standardized regenerative procedure where the cases of faculty members and residents were not identified in Bukhari *et al.* [13] and the

results of the Endodontic residents were not identified as well as clinical procedure followed in Chatha [14] was not standardized.

The evaluated patients in the present study were young (mean age: 13-years). According to Sonoyama *et al.* [31], young patients may play a role in tooth regenerative potential through the stem cell population. This is related to the apical opening size, which allows vital tissue ingrowth and eventually leads to a successful outcome of the regenerative endodontic procedure. It has been reported that an apical opening greater than 1 mm is sufficient for successful revascularization; however, a smaller size (0.5 mm) did not prevent vital tissue ingrowth into the pulp space [5,32]. In comparison, almost all of the recalled cases in the present study had an apical foramen greater than 1 mm in diameter. In the current study, apical foramen size reduction of the recalled anterior teeth was observed in 11 out of 13 cases, occurring was more in the distal root than the mesial of the molar teeth, which could be related to the large size of the canal. Five root developmental patterns in response to regenerative endodontic therapy of immature permanent teeth with infected necrotic pulp were described by Chen *et al.* [9]. These types were categorized as follows: Type 1, increased canal wall thickening and continued root maturation; Type 2, no significant continuation of root development with blunting and closure of the root apex; Type 3, continued root development with the apical foramen remaining open; Type 4, severe canal space calcification (obliteration); and Type 5, a hard tissue barrier formed in the canal between the coronal MTA plug and the root apex. All of these types were observed in the current study, except for Type 4, which pertains to mild to moderate calcification (**Figure 4**). In the current study, the root length was increased in 5 anterior and 2 posterior teeth, with an average length ranging from 4.00–0.63 mm in the anterior teeth, 2.85–1.48 mm of the mesial, and 2.73–2.16 mm of the distal of the molar teeth roots. These findings have been reported by several researchers. Specifically, some researchers reported root development in all treated cases, and others reported this occurrence in most cases, such as 21 out of 23 by Chueh *et*

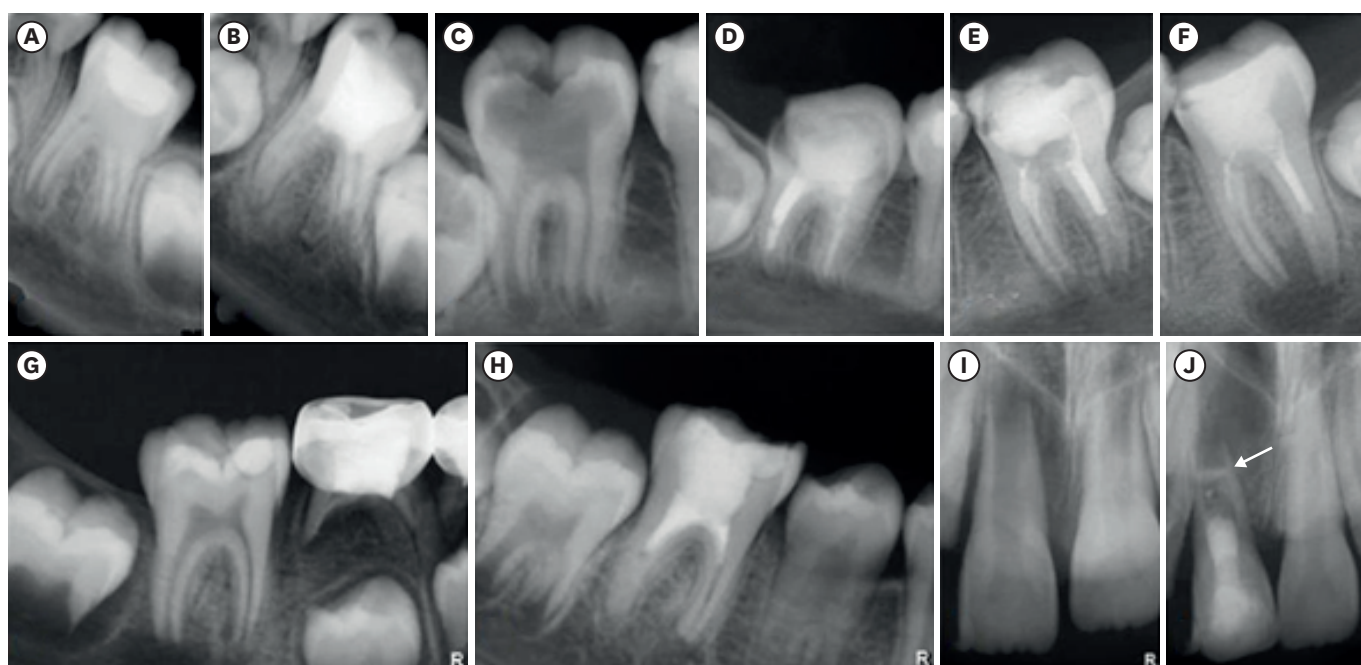


Figure 4. Root developmental patterns in response to regenerative endodontic therapy of immature permanent teeth with infected necrotic pulp described by Chen *et al.* [8] observed in the current study. Type 1 (A, B); Type 2 (C, D); Type 3 (E, F); Type 4 (G, H); and Type 5 (I, J).

al. [33] and 10 out of 14 by Shah *et al.* [26], or only a certain percentage of cases showed root length increase [29,34]. One of the limitations for determining an accurate measurement is the difficulty in identifying a clear landmark [11]. In response, Image J software (National Institutes of Health, Bethesda, MD, USA) has been used to circumvent this problem [29].

Continued root development was reported to be due to apical cementum deposition following successful revascularization procedures in animal studies [3,35,36]. In contrast, Chen *et al.* [9] believed that continued root development in humans does not appear to be a predictable outcome of immature permanent teeth with necrotic pulp and apical periodontitis/abscess following revascularization procedures. Yamauchi *et al.* [37] also reported that this is not even a constant finding in dog teeth. Furthermore, decreased root development potential might be attributed to the damaged Hertwig epithelial root sheath or the lack of remaining viable pulp tissue due to longstanding necrosis [11,38]. In the present study, the failed cases were related to findings of increased periapical radiolucency size without apical closure and further root development.

Pulp canal calcification (hard tissue formation) has been reported as a result of regenerative treatment of immature permanent necrotic teeth with apical periodontitis; however, its underlying mechanism remains unclear, which might be due to the internal replacement resorption complications or intracanal hard tissue and apical bone ankylosis [9]. It was also shown histologically in animal studies and in extracted teeth of a case report that the tissues formed in the canal space are similar to cementum-like or bone-like and fibrous connective tissue [39,40]. Additionally, partial pulp canal calcification was observed in only 7 teeth in the present study, with most of them having anterior teeth and a history of trauma. This finding is less reported as compared to those reported by Chueh *et al.* [33], who found complete and partial calcification in all of their cases. Complete calcification can be secondary to bone-like tissue as a result of internal replacement resorption or union between the intracanal hard tissue and apical alveolar bone [33]. Moreover, bridge formation at the apical third of the canal by intracanal cementum ingrowth in revascularized immature necrotic teeth with apical periodontitis was histologically demonstrated by Thibodeau *et al.* [3], da Silva *et al.* [35], and Wang *et al.* [36].

Crown discoloration was observed in 7 (30.43%) of the 23 teeth in the present study, which was attributed to the presence of bismuth oxide in the MTA material. The primary causative factor was attributed to the interaction of this component with tooth tissue collagen and sodium hypochlorite, as well as placing the MTA above the cemento-enamel junction. Additionally, the use of triple antibiotic paste containing minocycline has long been known to stain dentin [34,41,42]. Calcium hydroxide and MTA were used in all cases in the current study, and triple antibiotic paste was used in one case only. It should also be noted that although triple antibiotic paste is a very effective antimicrobial agent, high concentrations of this mixture might have a detrimental effect on stem cell survival [43].

Placement of a tight coronal seal is also important for the successful outcome of regenerative endodontic treatment, wherein a double seal consisting of MTA over the blood clot and permanent resin restoration has been used in most studies [42,44,45]. A similar technique was used for all evaluated cases in the present study, and coronal restoration was lost in only one case.

Despite all the findings of the study, the low number of cases was considered a limitation, which could be related to the number of visits that the patients needed for evaluation.

Furthermore, many issues remain to be clarified in the absence of histological evidence. Although regenerative endodontic therapy appears to have a generally high clinical success rate, studies with longer follow-up periods and a large number of cases are needed to better estimate long-term success.

CONCLUSIONS

The survival rate of the regenerative endodontic treatment of immature permanent teeth with necrotic pulp was very high and the clinical and radiographic outcome result of the cases was favorable.

REFERENCES

1. Huang GT. Apexification: the beginning of its end. *Int Endod J* 2009;42:855-866.
[PUBMED](#) | [CROSSREF](#)
2. Hargreaves KM, Diogenes A, Teixeira FB. Treatment options: biological basis of regenerative endodontic procedures. *J Endod* 2013;39 3 Supplement:S30-S43.
[PUBMED](#) | [CROSSREF](#)
3. Thibodeau B, Teixeira F, Yamauchi M, Caplan DJ, Trope M. Pulp revascularization of immature dog teeth with apical periodontitis. *J Endod* 2007;33:680-689.
[PUBMED](#) | [CROSSREF](#)
4. Al-Ghamdi NS, Al-Nazhan S. Pulp revascularization of immature maxillary first premolar. *J Conserv Dent* 2015;18:496-499.
[PUBMED](#) | [CROSSREF](#)
5. Estefan BS, El Batouty KM, Nagy MM, Diogenes A. Influence of age and apical diameter on the success of endodontic regeneration procedures. *J Endod* 2016;42:1620-1625.
[PUBMED](#) | [CROSSREF](#)
6. Murray PE, Garcia-Godoy F, Hargreaves KM. Regenerative endodontics: a review of current status and a call for action. *J Endod* 2007;33:377-390.
[PUBMED](#) | [CROSSREF](#)
7. Wigler R, Kaufman AY, Lin S, Steinbock N, Hazan-Molina H, Torneck CD. Revascularization: a treatment for permanent teeth with necrotic pulp and incomplete root development. *J Endod* 2013;39:319-326.
[PUBMED](#) | [CROSSREF](#)
8. Alobaid AS, Cortes LM, Lo J, Nguyen TT, Albert J, Abu-Melha AS, Lin LM, Gibbs JL. Radiographic and clinical outcomes of the treatment of immature permanent teeth by revascularization or apexification: a pilot retrospective cohort study. *J Endod* 2014;40:1063-1070.
[PUBMED](#) | [CROSSREF](#)
9. Chen MY, Chen KL, Chen CA, Tayebaty F, Rosenberg PA, Lin LM. Responses of immature permanent teeth with infected necrotic pulp tissue and apical periodontitis/abscess to revascularization procedures. *Int Endod J* 2012;45:294-305.
[PUBMED](#) | [CROSSREF](#)
10. Kontakiotis EG, Filippatos CG, Agrafioti A. Levels of evidence for the outcome of regenerative endodontic therapy. *J Endod* 2014;40:1045-1053.
[PUBMED](#) | [CROSSREF](#)
11. Kahler B, Mistry S, Moule A, Ringsmuth AK, Case P, Thomson A, Holcombe T. Revascularization outcomes: a prospective analysis of 16 consecutive cases. *J Endod* 2014;40:333-338.
[PUBMED](#) | [CROSSREF](#)
12. Saoud TM, Zaazou A, Nabil A, Moussa S, Lin LM, Gibbs JL. Clinical and radiographic outcomes of traumatized immature permanent necrotic teeth after revascularization/revitalization therapy. *J Endod* 2014;40:1946-1952.
[PUBMED](#) | [CROSSREF](#)
13. Bukhari S, Kohli MR, Setzer F, Karabucak B. Outcome of revascularization procedure: a retrospective case series. *J Endod* 2016;42:1752-1759.
[PUBMED](#) | [CROSSREF](#)

14. Chatha NR. Regenerative endodontics: chart review of treated cases [master thesis]. Boston, MA: Boston University; 2017.
15. Sedwick R. Observations of trends and successes of revascularization therapy at Virginia Commonwealth University: a retrospective study [master thesis]. Richmond, VA: Virginia Commonwealth University; 2018.
16. American Association of Endodontics. Clinical considerations for regenerative procedures [Internet]. Chicago, IL: American Association of Endodontics; 2013 [cited 2021 Aug 20]. Available from: www.aae.org/regenerativeendo. (updated 2016 Aug 6).
17. Jeeruphan T, Jantarat J, Yanpiset K, Suwannapan L, Khewsawai P, Hargreaves KM. Mahidol study 1: comparison of radiographic and survival outcomes of immature teeth treated with either regenerative endodontic or apexification methods: a retrospective study. *J Endod* 2012;38:1330-1336.
[PUBMED](#) | [CROSSREF](#)
18. Nygaard-Østby B, Hjørtdal O. Tissue formation in the root canal following pulp removal. *Scand J Dent Res* 1971;79:333-349.
[PUBMED](#) | [CROSSREF](#)
19. Landis JR, Koch GG. The measurement of observer agreement for categorical data. *Biometrics* 1977;33:159-174.
[PUBMED](#) | [CROSSREF](#)
20. Cehreli ZC, Isbitiren B, Sara S, Erbas G. Regenerative endodontic treatment (revascularization) of immature necrotic molars medicated with calcium hydroxide: a case series. *J Endod* 2011;37:1327-1330.
[PUBMED](#) | [CROSSREF](#)
21. Friedman S, Mor C. The success of endodontic therapy--healing and functionality. *J Calif Dent Assoc* 2004;32:493-503.
[PUBMED](#)
22. Strindberg LZ. The dependence of the results on pulp therapy on certain factors: an analytical study based on radiographic and clinical follow-up examinations. *Acta Odontol Scand* 1956;14(Supplement 21):1-175.
23. Xu R, Guo D, Zhou X, Sun J, Zhou Y, Fan Y. Disturbed bone remodeling activity varies in different stages of experimental, gradually progressive apical periodontitis in rats. *Int J Oral Sci* 2019;11:27.
[PUBMED](#) | [CROSSREF](#)
24. Anantula K, Annareddy A. Platelet-rich fibrin (PRF) as an autologous biomaterial after an endodontic surgery: case reports. *JNTR Univ Health Sci* 2016;5:49-54.
[CROSSREF](#)
25. Nair PN, Sjögren U, Figdor D, Sundqvist G. Persistent periapical radiolucencies of root-filled human teeth, failed endodontic treatments, and periapical scars. *Oral Surg Oral Med Oral Pathol Oral Radiol Endod* 1999;87:617-627.
[PUBMED](#) | [CROSSREF](#)
26. Shah N, Logani A, Bhaskar U, Aggarwal V. Efficacy of revascularization to induce apexification/apexogenesis in infected, nonvital, immature teeth: a pilot clinical study. *J Endod* 2008;34:919-925.
[PUBMED](#) | [CROSSREF](#)
27. Torabinejad M, Nosrat A, Verma P, Udochukwu O. Regenerative endodontic treatment or mineral trioxide aggregate apical plug in teeth with necrotic pulps and open apices: a systematic review and meta-analysis. *J Endod* 2017;43:1806-1820.
[PUBMED](#) | [CROSSREF](#)
28. Almutairi W, Yassen GH, Aminoshariae A, Williams KA, Mickel A. Regenerative endodontics: a systematic analysis of the failed cases. *J Endod* 2019;45:567-577.
[PUBMED](#) | [CROSSREF](#)
29. Bose R, Nummikoski P, Hargreaves K. A retrospective evaluation of radiographic outcomes in immature teeth with necrotic root canal systems treated with regenerative endodontic procedures. *J Endod* 2009;35:1343-1349.
[PUBMED](#) | [CROSSREF](#)
30. Lee JY, Kersten DD, Mines P, Beltran TA. Regenerative endodontic procedures among endodontists: a web-based survey. *J Endod* 2018;44:250-255.
[PUBMED](#) | [CROSSREF](#)
31. Sonoyama W, Liu Y, Yamaza T, Tuan RS, Wang S, Shi S, Huang GT. Characterization of the apical papilla and its residing stem cells from human immature permanent teeth: a pilot study. *J Endod* 2008;34:166-171.
[PUBMED](#) | [CROSSREF](#)
32. Laureys WG, Cuvelier CA, Dermaut LR, De Pauw GA. The critical apical diameter to obtain regeneration of the pulp tissue after tooth transplantation, replantation, or regenerative endodontic treatment. *J Endod* 2013;39:759-763.
[PUBMED](#) | [CROSSREF](#)

33. Chueh LH, Ho YC, Kuo TC, Lai WH, Chen YH, Chiang CP. Regenerative endodontic treatment for necrotic immature permanent teeth. *J Endod* 2009;35:160-164.
[PUBMED](#) | [CROSSREF](#)
34. Ding RY, Cheung GS, Chen J, Yin XZ, Wang QQ, Zhang CF. Pulp revascularization of immature teeth with apical periodontitis: a clinical study. *J Endod* 2009;35:745-749.
[PUBMED](#) | [CROSSREF](#)
35. da Silva LA, Nelson-Filho P, da Silva RA, Flores DS, Heilborn C, Johnson JD, Cohenca N. Revascularization and periapical repair after endodontic treatment using apical negative pressure irrigation versus conventional irrigation plus triantibiotic intracanal dressing in dogs' teeth with apical periodontitis. *Oral Surg Oral Med Oral Pathol Oral Radiol Endod* 2010;109:779-787.
[PUBMED](#) | [CROSSREF](#)
36. Wang X, Thibodeau B, Trope M, Lin LM, Huang GT. Histologic characterization of regenerated tissues in canal space after the revitalization/revascularization procedure of immature dog teeth with apical periodontitis. *J Endod* 2010;36:56-63.
[PUBMED](#) | [CROSSREF](#)
37. Yamauchi N, Yamauchi S, Nagaoka H, Duggan D, Zhong S, Lee SM, Teixeira FB, Yamauchi M. Tissue engineering strategies for immature teeth with apical periodontitis. *J Endod* 2011;37:390-397.
[PUBMED](#) | [CROSSREF](#)
38. Nosrat A, Homayounfar N, Oloomi K. Drawbacks and unfavorable outcomes of regenerative endodontic treatments of necrotic immature teeth: a literature review and report of a case. *J Endod* 2012;38:1428-1434.
[PUBMED](#) | [CROSSREF](#)
39. Shimizu E, Ricucci D, Albert J, Alobaid AS, Gibbs JL, Huang GT, Lin LM. Clinical, radiographic, and histological observation of a human immature permanent tooth with chronic apical abscess after revitalization treatment. *J Endod* 2013;39:1078-1083.
[PUBMED](#) | [CROSSREF](#)
40. Alenazy M, Al-Nazhan S, Mosadomi H. Histologic, radiographic, and micro-computed tomography evaluation of experimentally enlarged root apices in dog teeth with apical periodontitis after regenerative treatment. *Curr Ther Res Clin Exp* 2020;94:100620.
[PUBMED](#) | [CROSSREF](#)
41. Marciano MA, Costa RM, Camilleri J, Mondelli RF, Guimarães BM, Duarte MA. Assessment of color stability of white mineral trioxide aggregate angelus and bismuth oxide in contact with tooth structure. *J Endod* 2014;40:1235-1240.
[PUBMED](#) | [CROSSREF](#)
42. Petrino JA, Boda KK, Shambarger S, Bowles WR, McClanahan SB. Challenges in regenerative endodontics: a case series. *J Endod* 2010;36:536-541.
[PUBMED](#) | [CROSSREF](#)
43. Ruparel NB, Teixeira FB, Ferraz CC, Diogenes A. Direct effect of intracanal medicaments on survival of stem cells of the apical papilla. *J Endod* 2012;38:1372-1375.
[PUBMED](#) | [CROSSREF](#)
44. Banchs F, Trope M. Revascularization of immature permanent teeth with apical periodontitis: new treatment protocol? *J Endod* 2004;30:196-200.
[PUBMED](#) | [CROSSREF](#)
45. Al-Tammami MF, Al-Nazhan SA. Retreatment of failed regenerative endodontic of orthodontically treated immature permanent maxillary central incisor: a case report. *Restor Dent Endod* 2017;42:65-71.
[PUBMED](#) | [CROSSREF](#)