



Pediatric oncologic endosurgery

Yoon Jung Boo, MD, PhD^{a,b}, Jan Goedecke, MD^a, Oliver J. Muensterer, MD, PhD^{a*}

Abstract

Despite increasing popularity of minimal-invasive techniques in the pediatric population, their use in diagnosis and management of pediatric malignancy is still debated. Moreover, there is limited evidence to clarify this controversy due to low incidence of each individual type of pediatric tumor, huge diversity of the disease entity, heterogeneity of surgical technique, and lack of well-designed studies on pediatric oncologic minimal-invasive surgery. However, a rapid development of medical instruments and technologies accelerated the current trend toward less invasive surgery, including oncologic endosurgery. The aim of this article is to review current literatures about the application of the minimal-invasive approach for pediatric tumors and to give an overview of the current status, indications, individual techniques, and future perspectives.

Keywords: Endosurgery, Laparoscopy, Thoracoscopy, Children, Solid tumors

Introduction

Holcomb et al^[1] first introduced minimal-invasive surgery (MIS) for pediatric tumors in 1995 as an alternative to the open approach. The initial indications were tumor biopsy, assessment of resectability, staging, and evaluation of metastasis. Over the following 2 decades, MIS emerged as an alternative for most of these indications in adults^[2]. In children, however, there has been slow corresponding acceptance.

In 1996, the Pediatric Oncology Group received funding from the National Cancer Institute to conduct prospective randomized controlled studies to evaluate the roll of MIS in children with cancer. Unfortunately, these studies were closed prematurely in 1998. Using the accrued data, Ehrlich et al^[3] evaluated the factors that led to study failure, and postulated the following main reasons: (1) inadequate communication between oncologists and surgeons, (2) lack of surgical expertise with endoscopic procedures, and (3) preconceived surgeon bias toward each surgical approach.

Unfortunately, even after undergoing this symbolic trial and error, no randomized controlled trials or controlled clinical trials evaluating endoscopic surgery in the treatment of solid tumors in children have been conducted since^[4]. The main obstacles remain the limited number of patients regarding each tumor type, as well

as the substantial heterogeneity in tumor biology. Another technical aspect is the relatively small working space of pediatric patients compared with adults, which therefore limits oncologic MIS to pediatric surgeons with advanced endosurgical skills.

Still, the acceptance of MIS for pediatric solid tumors seems to be increasing^[5]. Although most published studies are case reports, case series, cohort-control, or small case-control trials, it seems that pediatric cancer patients may benefit from certain advantages of MIS in terms of faster recovery, less pain, better cosmetic result, and earlier adjuvant treatment^[6].

Early reports suggested several potential limitations of pediatric oncologic MIS, such as tumor recurrence, trocar site metastasis, inadequate resection, tumor growth, and dissemination after CO₂ insufflation^[7]. Another concern was the difficulty to adhere to oncologic principle in pediatric endoscopic surgery due to loss of tactile sensation, possible tumor spillage, and difficulty of safe specimen removal specimens through small incisions^[8]. Auxiliary techniques such as computed tomography (CT)-guided wire marking techniques may overcome these issues^[9].

This article includes an overview of the status, indications, individual techniques, and a future prospective of endoscopic surgery for pediatric solid tumors based on the review of currently published literature.

Sponsorships or competing interests that may be relevant to content are disclosed at the end of this article.

^aDepartment of Pediatric Surgery, University Medicine of the Johannes Gutenberg University Mainz, Mainz, Germany and ^bDepartment of Pediatric Surgery, Korea University College of Medicine, Seoul, Korea

*Corresponding author. Address: Department of Pediatric Surgery, University Medicine of the Johannes Gutenberg University Mainz, Langenbeckstr. 1, 55131 Mainz, FR Germany. Tel.: +49 6131 17 3865; fax: +49 6131 17 6523. E-mail address: oliver.muensterer@unimedizin-mainz.de (O.J. Muensterer).

Copyright © 2017 The Authors. Published by Wolters Kluwer Health, Inc. on behalf of IJS Publishing Group Ltd. This is an open access article distributed under the Creative Commons Attribution-NoDerivatives License 4.0, which allows for redistribution, commercial and non-commercial, as long as it is passed along unchanged and in whole, with credit to the author.

International Journal of Surgery Oncology (2017) 2:e30

Received 28 April 2017; Accepted 29 April 2017

Published online 20 June 2017

<http://dx.doi.org/10.1097/IJ9.000000000000030>

Current status of pediatric oncologic endosurgery

Biopsy and staging

Most tumors in children require biopsy before initiating multimodal management. The ability of endoscopy to visualize almost the entire abdominal and thoracic cavity is one of the most powerful advantages of this technique. It not only enables tissue confirmation, but also supplies information about the size, location, and anatomy of the tumor. The diagnostic accuracy of MIS has been reported ranging from 85% up to 100%. Cribbs et al^[10] summarized several large series of laparoscopic procedures in children with abdominal masses, resulting in a 99% positive yield. For thoracoscopy, the success rate was 98%, with a combined conversion rate of only 12%.

MIS can be also used as an adjunctive tool to CT, magnetic resonance imaging, ultrasound, or positron emission tomography scanning to evaluate the extent of disease. Despite significant

improvements in tumor imaging, there is frequently a discrepancy between preoperative and intraoperative staging^[5]. Endosurgery allows direct visualization of the tumor, exact evaluation of invasion into adjacent organs, as well as a thorough inspection of the peritoneal or pleural surface for implants. In adults, laparoscopy has actually been shown to avoid unnecessary laparotomy in up to 67% of patients^[11]. During staging, metastatic deposits not detected by previous radiologic evaluation can be identified, and targeted biopsy is possible. Metzelder et al^[5] reported a total of 41 laparoscopic and 35 thoracoscopic biopsy and staging procedures in children, yielding a combined diagnostic accuracy of 98%.

Tumor resection

Recently, pediatric endosurgery has been more commonly used for curative intentions. Laparoscopic adrenalectomy is the most common procedure, with a conversion rate of only 10%^[10]. The International Pediatric Endosurgery Group issued guidelines in 2010 for laparoscopic adrenalectomy, based on level III evidence, and confirmed feasibility without an absolute contraindication^[12].

Laparoscopic nephrectomy has been reported for Wilms tumor after chemotherapy^[13]. The authors reported that 8 tumors were completely removed, including appropriate lymph node sampling, without significant complications. In addition, endosurgical resection of thoracic neuroblastoma^[14], primary liver cancers^[15], and ovarian tumors^[16] all have been reported in children.

Some authors attempted pediatric MIS in complex disease states such as the resection of neuroblastomas with vascular encasement^[11,13,17]. Retroperitoneoscopy has been used for lymph node sampling, diagnostic biopsy, and complete resection of the tumor in recent series as well^[18].

Metastasis

After a primary resection and chemotherapy, imaging techniques frequently provide only limited information on tumor recurrence or metastasis. MIS is an option for the determination and characterization of metastatic lesions, and may help define a treatment plan. This approach is particularly suitable for pulmonary lesions. In fact, technical advances in imaging have led to an increased detection of small lung nodules of uncertain histologic nature. The development of localization techniques has enabled the resection of even small lung nodules by thoracoscopy^[19], decreasing the need for a potentially morbid, open thoracotomy. Localizing techniques include placing a CT-guided wire into the lesion, or tattooing the lesions on the pulmonary surface using the patient's own blood or methylene blue^[20].

A particular clinical challenge is the resection of pulmonary osteosarcoma metastases, as these are characteristically firm and detectable by direct palpation. Thoracoscopic instruments diminish tactile feedback, so that thoracoscopy cannot be currently recommended for the search and resection of pulmonary osteosarcoma metastasis^[21].

Other supportive treatment and complications

Pediatric endosurgery can be performed for tumor complications, including cholecystectomy for cholecystitis, splenectomy for splenic involvement, oophorectomy for metastasis, Nissen fundoplication for gastroesophageal reflux, enterolysis for adhesive bowel obstruction, and feeding tube placement for tumor-associated cachexia^[22].

Insertion of peritoneal catheters for intra-abdominal administration of cytoreductive agents have also been reported laparoscopically^[10]. When the commonly used central veins are thrombosed or have been ligated, central venous catheters can be placed by MIS directly into the right atrium or via hepatic veins into the inferior vena cava^[21].

Infectious complications are common in children receiving intense multimodal therapy. MIS can be used to identify their source by obtaining samples of fluid or tissue^[22]. Endosurgical procedures also have been used to treat complications due to leukemic infiltration of organs, and intussusception from intraluminal bowel malignancies. Laparoscopy has also been used to create enteroenterostomies to treat chronic obstruction due to infiltrative malignancy.

Abdominal approach

Neuroblastoma and neurogenic tumors

Neuroblastoma (Fig. 1) is the most common abdominal solid tumor in children, arising from the adrenal gland in 40%^[23]. Iwakana et al^[24] suggested that earlier time to postoperative feeding can be accomplished after laparoscopic resection. Leclair et al^[17] published a multicenter study of 45 cases of abdominal neuroblastoma. The median diameter of the tumors was 37 mm. Four procedures were converted to open surgery, and 2 major complications occurred. A recent retrospective study of 79 patients showed that laparoscopic resection of adrenal neuroblastoma can be performed with equivalent risks compared with open surgery^[25]. The authors suggested selection criteria for laparoscopic tumor resection, including size smaller than 5 cm, and absence of vascular encasement. These studies show feasibility and good oncologic outcome of MIS in selected small, encapsulated low/intermediate risk tumors, while the roll of endosurgical procedures for complicated tumors has yet to be defined^[26].

Ganglioneuroma is a benign form of peripheral neurogenic tumor, often diagnosed incidentally in children. It may show invasiveness, leading to a high incidence of postoperative complications^[27,28]. However, if it is well-capsulated, tumors can generally be resected endosurgically without complications^[23].

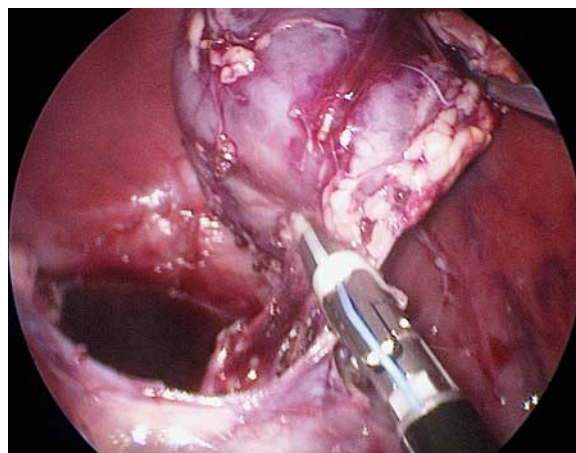


Figure 1. Endoscopic view of laparoscopic resection of neuroblastoma in the left adrenal gland. In this depiction, the tumor has been circumferentially mobilized and the adrenal vein is being ligated using a bipolar sealing device.

Pheochromocytoma

In children, 40% of cases of pheochromocytoma are associated with genetic mutations^[29]. In pediatric patients, there is an increased risk of bilaterality and recurrence^[30]. Complete surgical resection is the most important prognostic factor, and minimal-invasive procedure have been successfully utilized^[31]. In patients with bilateral disease, laparoscopic partial adrenalectomy can be performed with good success^[32]. Nau et al^[33] reported that laparoscopic pheochromocytoma resection showed similar outcomes compared with other adrenal entities, despite higher conversion rate. As in open surgery, careful intraoperative hemodynamic monitoring is mandatory. Also, the vein should always be ligated before any major manipulation because of the dangers of systemic catecholamine release.

Adrenocortical tumors (ACTs)

ACTs are rare in children, and generally have poor prognosis. Complete excision is the cornerstone of management because chemotherapy and radiotherapy are ineffective^[29]. As these tumors are usually large and their capsules are friable, rupture and spillage frequently occurs. Few pediatric cases operated by endosurgery for small tumors (< 55 mm) have been reported^[34]. However, because of the overall aggressive nature, and the fact that upfront complete (R0) resection is the only chance of survival, the authors generally recommend against using MIS for preoperatively identified ACTs.

Nephroblastoma

Nephroblastoma is the most common genitourinary malignancy of children. It is also an example of successful multimodal treatment, with an overall cure rate of over 90%^[35]. Despite good data, some controversies remain, including contralateral kidney exploration, indications for partial nephrectomy, and exclusive surgical treatment for some patients with low-risk diseases^[36]. As there is clear evidence that tumor spill during surgery increases the risk of local recurrence^[37], laparoscopic resection of large nephroblastomas is considered challenging. To date, there is insufficient evidence to make general recommendations on MIS for nephroblastoma^[38]. Endosurgical nephrectomy may offer a shorter length of stay, decreased use of narcotics, and lower intraoperative blood loss^[39]. However, large tumors are associated with a higher risk of intraoperative spillage^[40]. Conversely, in the European studies, preoperative chemotherapy is administered in all patients, followed by operative resection^[41]. Neoadjuvant chemotherapy usually leads to relevant tumor shrinkage, possibly decreasing the risk of tumor rupture^[13], facilitating an MIS approach in some cases^[8]. Large tumors may be difficult to handle, and carry a higher risk of tumor rupture^[42]. The tumor should therefore always be placed in a retrieval bag. Morcellation is not recommended due to the risk of tumor rupture and rendering an accurate pathologic analysis impossible^[43].

Hepatic tumors

MIS for hepatic tumors in children is currently considered experimental. Several series reported nonanatomic liver resection using endosurgical techniques in tumors such as fibrous nodular hyperplasia^[44], mesenchymal hamartoma^[45], and hemangioblastoma. In small and selective locations (anterolateral segments) of hepatoblastoma, endosurgical resection has been reported in few patients^[46].

Ovarian tumors

Ovarian tumors lend themselves to endosurgical resection^[47]. Laparoscopic resection of cystic ovarian neoplasms has been widely reported, most commonly in teratoma^[16]. Mature teratomas are particularly suited for this approach (Fig. 2), but potential malignancy makes it more controversial^[48]. Some authors recommend laparotomy for tumors larger than 7.5 cm because complete tumor resection is the key factor for good prognosis^[42]. However, MIS has been effectively used for staging and inspection of the peritoneal cavity and liver surface. Laparoscopic oophorosalingectomy is certainly an option for malignant tumors confined to the ovary (Fig. 3).

Sacroccygeal teratoma

Sacroccygeal tumors in neonates most commonly present as large external tumors, but some are partially or entirely intrapelvic (Altman classification). For all types, the authors recommend a combined laparoscopic abdominal and subsequent open perineal approach. Laparoscopic ligation of the median sacral artery (Fig. 4) before perineal resection proactively decreases the risk of life-threatening bleeding^[49]. The authors have acquired extensive favorable experience with this hybrid technique.

Thoracic indications

Thoracic neurogenic tumors

Thoracoscopic resection of neuroblastoma, ganglioneuroblastoma, and ganglioneuromas has evolved over time, with a considerable decrease in complication rates^[50]. Compared with conventional open surgery, thoracoscopic neuroblastoma resection is associated with shorter length of stay, lower blood loss, and lower chest tube requirement^[51]. Postoperative pain seems to be improved, as does the potential risk of tumor dissemination^[52]. A shorter recovery time after MIS may allow for earlier commencement of adjunctive therapy^[53].

Germ cell tumors

Approximately 4% of all germ cell tumors are located within the chest^[54]. Complete surgical resection is the most important factor for long-term survival. Frequently, these tumors infiltrate the surrounding tissues. Therefore, one should be cautious to use thoracoscopy when planning complete surgical resection.

Others

Besides the entities discussed, the mediastinum is a common location for intrathoracic masses in children. Primary pulmonary malignancies are less frequent than metastatic lesions. Surgical removal of lung metastasis improves survival in osteosarcoma and nephroblastoma, although it is less defined for other entities^[55]. In cases where the therapeutic goal is not the complete removal of all lung lesions (evaluation of dignity of incidentally diagnosed nodules, for example), the endosurgical approach is preferred^[56].

Technical tips and tricks

The first suggestion for successful pediatric oncologic MIS is optimal exposure. Trocars should be carefully placed to allow adequate visualization and ergonomic handling. Transabdominal stay sutures to retract surrounding tissue and organs can enhance exposure. Finally, the patient should be firmly secured to the table

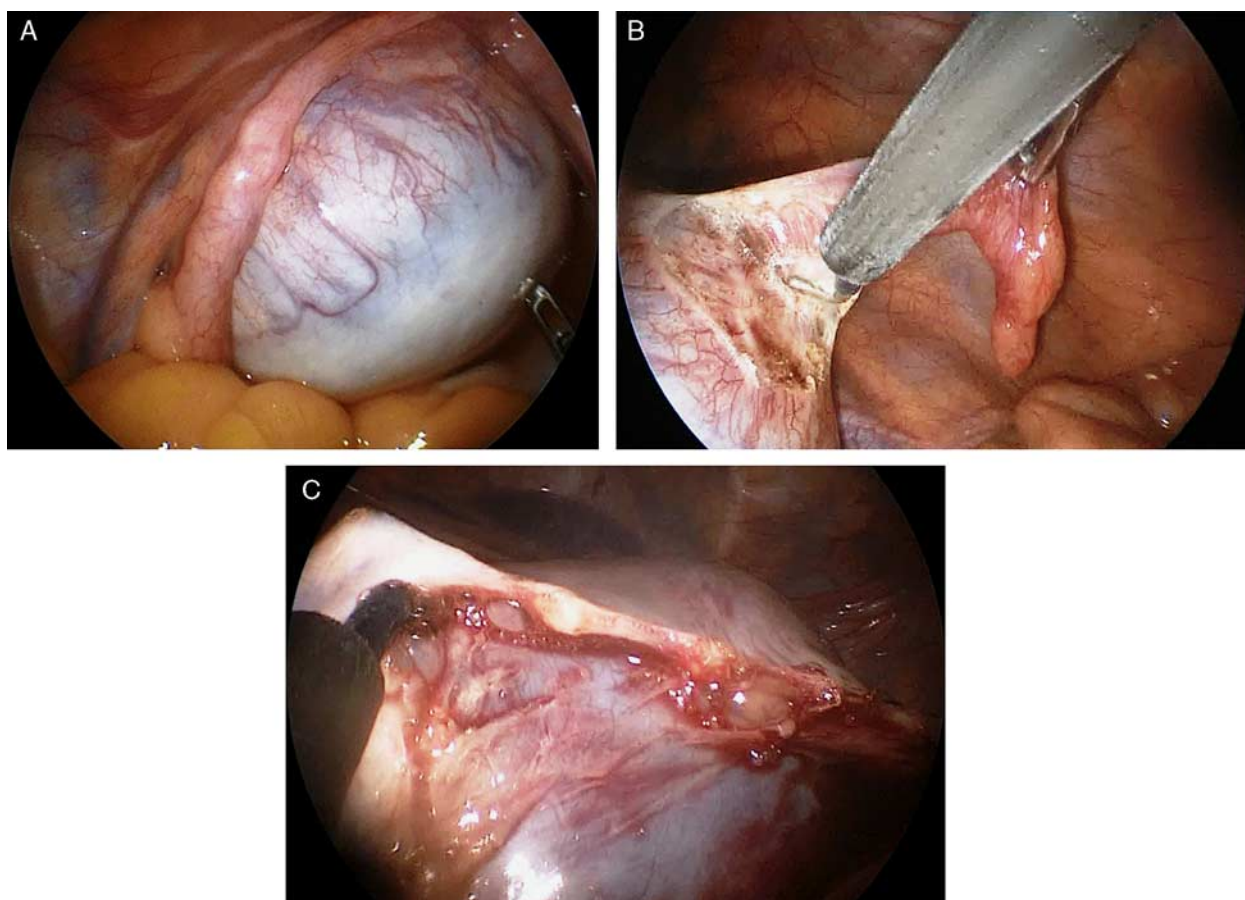


Figure 2. When mature features are clearly visible on preoperative imaging, an ovary-sparing resection of an ovarian teratoma (A) can be performed. The tube is preserved and the capsule is carefully opened (B). A plane can usually be developed between the teratoma (below the electrocautery hook) and healthy ovarian tissue, above (C).

so that the table can be shifted for gravity to aid in organ retraction.

Single-lung ventilation should be considered in older, relatively healthy patients when complex thoracoscopic interventions are planned. Single-lung ventilation can be achieved by using special double-lumen endotracheal tubes, by selective mainstem bronchus intubation, or by using a bronchial blocker in the ipsilateral side.

While we generally try to use the lowest pressures and flows possible during laparoscopy or thoracoscopy, temporarily increasing the pressure in the abdomen or thorax to gain working space during particularly critical phases can be beneficial.

Tumors should always be extracted in a tear-resistant endoscopic retrieval bag, and the corresponding incision must be made large enough to easily accommodate the tumor. Excessive manipulation of the specimen may break the bag and lead to inadvertent tumor spillage.

Although some authors claim that tumor size does not play a major role in choosing an endosurgical approach, large tumors are usually difficult to handle. We, therefore, advocate for careful case selection depending on surgical experience. In this context, Duarte et al^[13] suggested that MIS may be considered if the tumor's dimensions are $\leq 10\%$ of the child's height.

Finally, if in doubt, conversion to a small thorotomy or laparotomy to introduce a finger for haptic feedback can be helpful.

Future prospective

Single-incision surgery

Single-incision pediatric endosurgery (Fig. 5) has been validated for many general pediatric procedures, but rarely for tumors^[57,58]. Significant challenges include higher cost, a steep learning curve, lack of triangulation, and close instrument proximity, which is even more pronounced in smaller children^[59]. Most series using single-incision surgery include mixed oncologic and nononcologic cases. Single-incision endosurgery has been reported for unilateral benign adrenal tumors^[60], metanephric adenoma^[58], granulosa cell tumors^[61], mature teratoma, and cystadenoma^[57]. An advantage of single-incision pediatric endosurgery is a relatively large (15 to 20 mm) incision through which the tumor can be removed easier than through standard laparoscopic 3-, 5-, or 10-mm port incisions.

Robotic surgery

Robotic surgery is well established in adults with prostatic, renal, and rectal cancers. Currently there are some limitations in adopting this technique in children. There are few case series reported for robotic-assisted tumor resection in pediatric solid tumors. Robotic surgery has been reported in the resection of pediatric brain tumors^[62], as well as mediastinal and abdominopelvic masses^[63]. Mediastinal tumors have been proposed as the ideal

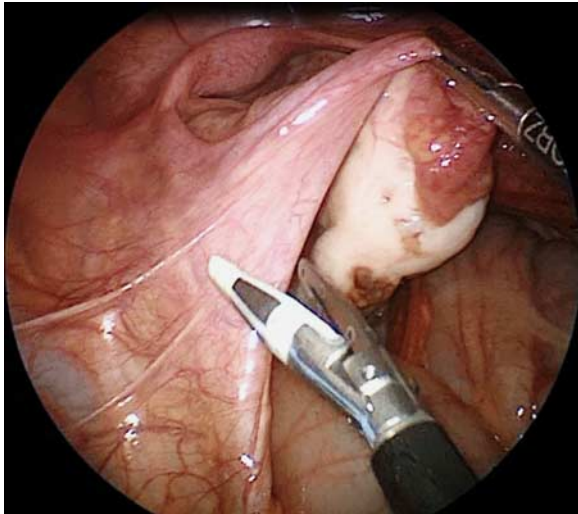


Figure 3. The surgeon is preparing for oophorosalingectomy of a germ cell tumor using the endoscopic bipolar sealing device.

indication of robotic surgery^[63]. Before robotic surgery can be universally adopted in the treatment of pediatric neoplasia, further miniaturization of the instruments is necessary, and benefits should first be documented for benign disease in clinical studies.

Navigation and in situ diagnosis

Endoscopic navigation is an intriguing tool to improve identification of tumors or metastases. Preoperative identification of the target lesion with image-guided needle localization has been reported as described above for the lung. However, this requires a preoperative intervention, which may not be tolerated as well by children.

Recently, fluorescence laparoscopy has been introduced as a tool for the in vivo diagnosis and photodynamic therapy of childhood rhabdomyosarcoma^[64]. This technique entails intraoperative intravenous injection of a fluorescent substance that lights up during laparoscopy using illumination at a particular wave length. In select cases, this may enable the more precise identification of

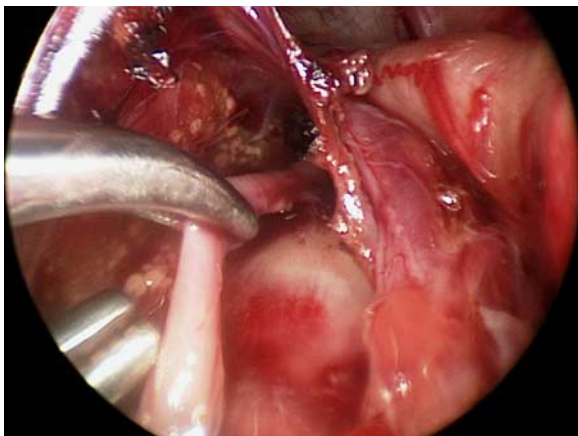


Figure 4. Endoscopic view of ligation of middle sacral artery in a neonate with sacrococcygeal teratoma.

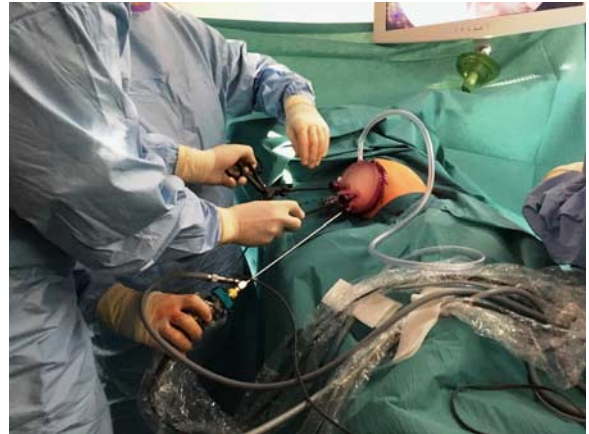

Figure 5. View of single-incision surgery performing left adrenalectomy for neuroblastoma.

the tumor margins based on the fluorescence, and may facilitate complete resection of the tumor.

Hayashi et al^[65] proposed a surgical navigation system based on CT-derived patient anatomy superimposed on the laparoscopic view in real time during surgery in adults. This surgical navigation system is based on virtual laparoscopy. In the future, it may overcome some limitations of MIS.

Multiphoton microscopy is a real time technique that allows imaging of tissue without time-consuming tissue labeling or staining^[66]. It can visualize malignant cells in vivo through the tumors' capsule (Fig. 6). Therefore, it has a certain potential for future intraoperative diagnosis by providing immediate feedback to the surgeon on resection margins and anatomic-pathologic features. The authors are currently evaluating the use of multiphoton microscopy in the management of pediatric solid tumors.

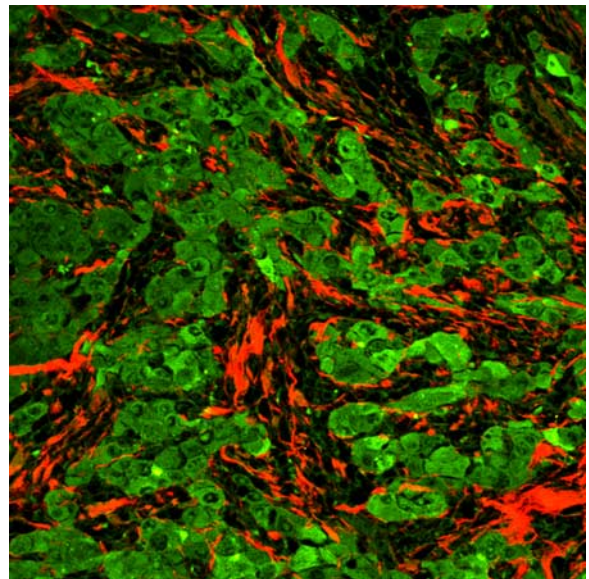


Figure 6. Images of multiphoton microscopy for hepatocellular carcinoma through the tumor capsule. Collagen fibers are visible in red (second harmonic generation), cellular components in green (autofluorescence).

Conclusions

Currently, no clear evidence exists to universally support pediatric oncologic endosurgery in all cases. However, with more emerging studies and more robust data, minimal-invasive techniques have a definitive potential to replace some of the standard open procedures in the future. Minimal-invasive oncologic surgery seems to be associated with faster recovery times, less pain, better cosmesis, and earlier commencement of adjunctive therapies. Therefore, families and practitioners often prefer minimal-invasive to open surgery whenever feasible. The treatment of cancer is a complex, multimodal endeavor, in which many aspects come into play. Endosurgical procedures for pediatric oncology should be applied under the premise of careful patient selection, thoughtful decision making, and strictly respecting universal oncologic principles.

Conflict of interest statement

The authors declare that they have no financial conflict of interest with regard to the content of this report.

References

- Holcomb GW III, Tomita SS, Haase GM, *et al.* Minimally invasive surgery in children with cancer. *Cancer* 1995;76:121–8.
- Spurbeck WW, Davidoff AM, Lobe TE, *et al.* Minimally invasive surgery in pediatric cancer patients. *Ann Surg Oncol* 2004;11:340–3.
- Ehrlich PF, Newman KD, Haase GM, *et al.* Lessons learned from a failed multi-institutional randomized controlled study. *J Pediatr Surg* 2002;37:431–6.
- van Dalen EC, de Lijster MS, Leijssen LG, *et al.* Minimally invasive surgery versus open surgery for the treatment of solid abdominal and thoracic neoplasms in children. *Cochrane Database Syst Rev* 2015;1:Cd008403.
- Metzelder ML, Kuebler JF, Shimotakahara A, *et al.* Role of diagnostic and ablative minimally invasive surgery for pediatric malignancies. *Cancer* 2007;109:2343–8.
- Malkan AD, Loh AH, Sandoval JA. Minimally invasive surgery in the management of abdominal tumors in children. *J Pediatr Surg* 2014;49:1171–6.
- Iwanaka T, Arya G, Ziegler MM. Mechanism and prevention of port-site tumor recurrence after laparoscopy in a murine model. *J Pediatr Surg* 1998;33:457–61.
- Fuchs J, Schafbuch L, Ebinger M, *et al.* Minimally invasive surgery for pediatric tumors—current state of the art. *Front Pediatr* 2014;2:48.
- Partrick DA, Bensard DD, Teitelbaum DH, *et al.* Successful thoracoscopic lung biopsy in children utilizing preoperative CT-guided localization. *J Pediatr Surg* 2002;37:970–3; discussion 970–3.
- Cribbs RK, Wulkan ML, Heiss KF, *et al.* Minimally invasive surgery and childhood cancer. *Surg Oncol* 2007;16:221–8.
- Rosoff JS, Raman JD, Del Pizzo JJ. Laparoscopic adrenalectomy for large adrenal masses. *Curr Urol Rep* 2008;9:73–9.
- International Pediatric Endosurgery Group. IPEG guidelines for the surgical treatment of adrenal masses in children. *J Laparoendosc Adv Surg Tech A* 2010;20:vii–ix.
- Duarte RJ, Dénes FT, Cristofani LM, *et al.* Laparoscopic nephrectomy for Wilms' tumor. *Expert Rev Anticancer Ther* 2009;9:753–61.
- Malek MM, Mollen KP, Kane TD, *et al.* Thoracic neuroblastoma: a retrospective review of our institutional experience with comparison of the thoracoscopic and open approaches to resection. *J Pediatr Surg* 2010;45:1622–6.
- Malek MM, Shah SR, Atri P, *et al.* Review of outcomes of primary liver cancers in children: our institutional experience with resection and transplantation. *Surgery* 2010;148:778–82; discussion 782–4.
- Ammor A, Kisra M, Oulahyane R, *et al.* Ovarian tumours in children: a review of 18 cases. *Afr J Paediatr Surg* 2012;9:231–6.
- Leclair MD, de Lagausie P, Becmeur F, *et al.* Laparoscopic resection of abdominal neuroblastoma. *Ann Surg Oncol* 2008;15:117–24.
- Theilen TM, Paran TS, Rutigliano D, *et al.* Experience with retroperitoneoscopy in pediatric surgical oncology. *Surg Endosc* 2011;25:2748–55.
- Federici S, Ratta A, Mordenti M, *et al.* Successful thoracoscopic resection of pulmonary metastasis less than 1 cm in size utilizing preoperative CT-guided wire localization. *J Laparoendosc Adv Surg Tech A* 2009;19(suppl 1):S171–3.
- Martin AE, Chen JY, Muratore CS, *et al.* Dual localization technique for thoracoscopic resection of lung lesions in children. *J Laparoendosc Adv Surg Tech A* 2009;19(suppl 1):S161–4.
- Fernandez-Pineda I, Daw NC, McCarville B, *et al.* Patients with osteosarcoma with a single pulmonary nodule on computed tomography: a single-institution experience. *J Pediatr Surg* 2012;47:1250–4.
- Dillon PW. Challenge of supportive surgical care in pediatric oncology. *Semin Surg Oncol* 1999;16:193–9.
- Peccelon M, Audry G, Irtan S. Minimally invasive surgery in childhood cancer: a challenging future. *Eur J Pediatr Surg* 2014;24:443–9.
- Iwanaka T, Arai M, Ito M, *et al.* Surgical treatment for abdominal neuroblastoma in the laparoscopic era. *Surg Endosc* 2001;15:751–4.
- Kelleher CM, Smithson L, Nguyen LL, *et al.* Clinical outcomes in children with adrenal neuroblastoma undergoing open versus laparoscopic adrenalectomy. *J Pediatr Surg* 2013;48:1727–32.
- Brisse HJ, McCarville MB, Granata C, *et al.* Guidelines for imaging and staging of neuroblastic tumors: consensus report from the International Neuroblastoma Risk Group Project. *Radiology* 2011;261:243–57.
- Retrosi G, Bishay M, Kiely EM, *et al.* Morbidity after ganglioneuroma excision: is surgery necessary? *Eur J Pediatr Surg* 2011;21:33–7.
- De Bernardi B, Gambini C, Haupt R, *et al.* Retrospective study of childhood ganglioneuroma. *J Clin Oncol* 2008;26:1710–6.
- Heloury Y, Muthucumar M, Panabokke G, *et al.* Minimally invasive adrenalectomy in children. *J Pediatr Surg* 2012;47:415–21.
- Fallon SC, Feig D, Lopez ME, *et al.* The utility of cortical-sparing adrenalectomy in pheochromocytomas associated with genetic syndromes. *J Pediatr Surg* 2013;48:1422–5.
- Miller KA, Albanese C, Harrison M, *et al.* Experience with laparoscopic adrenalectomy in pediatric patients. *J Pediatr Surg* 2002;37:979–82; discussion 979–982.
- Cheng SP, Saunders BD, Gauger PG, *et al.* Laparoscopic partial adrenalectomy for bilateral pheochromocytomas. *Ann Surg Oncol* 2008;15:2506–8.
- Nau P, Demyttenaere S, Muscarella P, *et al.* Pheochromocytoma does not increase risk in laparoscopic adrenalectomy. *Surg Endosc* 2010;24:2760–4.
- Gelas T, Frappaz D, Berlier P, *et al.* Mini-invasive surgery for adrenocortical carcinoma in children: is it safe? *Pediatr Hematol Oncol* 2013;30:288–90.
- Sonn G, Shortliffe LM. Management of Wilms tumor: current standard of care. *Nat Clin Pract Urol* 2008;5:551–60.
- Pritchard-Jones K. Controversies and advances in the management of Wilms' tumour. *Arch Dis Child* 2002;87:241–4.
- Green DM, Breslow NE, D'Angio GJ, *et al.* Outcome of patients with Stage II/favorable histology Wilms tumor with and without local tumor spill: a report from the National Wilms Tumor Study Group. *Pediatr Blood Cancer* 2014;61:134–9.
- Varlet F, Stephan JL, Guye E, *et al.* Laparoscopic radical nephrectomy for unilateral renal cancer in children. *Surg Laparosc Endosc Percutan Tech* 2009;19:148–52.
- Duarte RJ, Cristofani LM, Dénes FT, *et al.* Wilms tumor: a retrospective study of 32 patients using videolaparoscopic and open approaches. *Urology* 2014;84:191–5.
- Hamilton TE, Shamberger RC. Wilms tumor: recent advances in clinical care and biology. *Semin Pediatr Surg* 2012;21:15–20.
- Ko EY, Ritchey ML. Current management of Wilms' tumor in children. *J Pediatr Urol* 2009;5:56–65.
- Fuchs J. The role of minimally invasive surgery in pediatric solid tumors. *Pediatr Surg Int* 2015;31:213–8.
- Castilho LN, Fugita OE, Mitre AI, *et al.* Port site tumor recurrences of renal cell carcinoma after videolaparoscopic radical nephrectomy. *J Urol* 2001;165:519.
- Yeung CK, Chowdhary SK, Chan KW, *et al.* Atypical laparoscopic resection of a liver tumor in a 4-year-old girl. *J Laparoendosc Adv Surg Tech A* 2006;16:325–7.
- Dutta S, Nehra D, Woo R, *et al.* Laparoscopic resection of a benign liver tumor in a child. *J Pediatr Surg* 2007;42:1141–5.
- Kim T, Kim DY, Cho MJ, *et al.* Use of laparoscopic surgical resection for pediatric malignant solid tumors: a case series. *Surg Endosc* 2011;25:1484–8.

- [47] Williams RS, Littell RD, Mendenhall NP. Laparoscopic oophoropexy and ovarian function in the treatment of Hodgkin disease. *Cancer* 1999;86:2138–42.
- [48] Grabowski A, Korlacki W, Pasierbek M. Laparoscopy in elective and emergency management of ovarian pathology in children and adolescents. *Wideochir Inne Tech Maloinwazyjne* 2014;9:164–9.
- [49] Bax NM, van der Zee DC. The laparoscopic approach to sacrococcygeal teratomas. *Surg Endosc* 2004;18:128–30.
- [50] Fraga JC, Aydogdu B, Aufieri R, *et al.* Surgical treatment for pediatric mediastinal neurogenic tumors. *Ann Thorac Surg* 2010;90:413–8.
- [51] Fraga JC, Rothenberg S, Kiely E, *et al.* Video-assisted thoracic surgery resection for pediatric mediastinal neurogenic tumors. *J Pediatr Surg* 2012;47:1349–53.
- [52] Ponsky TA, Rothenberg SS, Tsao K, *et al.* Thoracoscopy in children: is a chest tube necessary? *J Laparoendosc Adv Surg Tech A* 2009;19(suppl 1): S23–5.
- [53] Smith TJ, Rothenberg SS, Brooks M, *et al.* Thoracoscopic surgery in childhood cancer. *J Pediatr Hematol Oncol* 2002;24:429–35.
- [54] Schneider DT, Calaminus G, Reinhard H, *et al.* Primary mediastinal germ cell tumors in children and adolescents: results of the German cooperative protocols MAKEI 83/86, 89, and 96. *J Clin Oncol* 2000;18:832–9.
- [55] Fuchs J, Seitz G, Handgretinger R, *et al.* Surgical treatment of lung metastases in patients with embryonal pediatric solid tumors: an update. *Semin Pediatr Surg* 2012;21:79–87.
- [56] Castagnetti M, Delarue A, Gentet JC. Optimizing the surgical management of lung nodules in children with osteosarcoma: thoracoscopy for biopsies, thoracotomy for resections. *Surg Endosc* 2004;18:1668–71.
- [57] Pontarelli EM, Emami C, Nguyen NX, *et al.* Single-incision laparoscopic resection of ovarian masses in children: a preliminary report. *Pediatr Surg Int* 2013;29:715–8.
- [58] Jeon HG, Kim DS, Jeoung HB, *et al.* Pediatric laparoendoscopic single-site partial nephrectomy: initial report. *Urology* 2010;76:138–41.
- [59] Malkan AD, Loh AH, Fernandez-Pineda I, *et al.* The role of thoracoscopic surgery in pediatric oncology. *J Laparoendosc Adv Surg Tech A* 2014;24:819–26.
- [60] Zhang X, Shi TP, Li HZ, *et al.* Laparo-endoscopic single site anatomical retroperitoneoscopic adrenalectomy using conventional instruments: initial experience and short-term outcome. *J Urol* 2011;185:401–6.
- [61] Lacher M, Kuebler JF, Yannam GR, *et al.* Single-incision pediatric endosurgery for ovarian pathology. *J Laparoendosc Adv Surg Tech A* 2013;23:291–6.
- [62] Drake JM, Joy M, Goldenberg A, *et al.* Computer- and robot-assisted resection of thalamic astrocytomas in children. *Neurosurgery* 1991;29:27–33.
- [63] Meehan JJ, Sandler AD. Robotic resection of mediastinal masses in children. *J Laparoendosc Adv Surg Tech A* 2008;18:114–9.
- [64] Urla C, Armeanu-Ebinger S, Fuchs J, *et al.* Successful in vivo tumor visualization using fluorescence laparoscopy in a mouse model of disseminated alveolar rhabdomyosarcoma. *Surg Endosc* 2015;29:1105–4.
- [65] Hayashi Y, Misawa K, Oda M, *et al.* Clinical application of a surgical navigation system based on virtual laparoscopy in laparoscopic gastrectomy for gastric cancer. *Int J Comput Assist Radiol Surg* 2016;11: 827–36.
- [66] Yan J, Zhuo S, Chen G, *et al.* Real-time optical diagnosis for surgical margin in low rectal cancer using multiphoton microscopy. *Surg Endosc* 2014;28:36–41.