

Hantavirus Cardiopulmonary Syndrome Due to Imported Andes Hantavirus Infection in Switzerland: A Multidisciplinary Challenge, Two Cases and a Literature Review

Andrea B. Kuenzli,¹ Jonas Marschall,¹ Joerg C. Schefold,¹ Margaret Schafer,¹ Oliver B. Engler,² Rahel Ackermann-Gäumann,² David C. Reineke,¹ Franziska Suter-Riniker,³ and Cornelia Staehelin¹

¹Bern University Hospital and University of Bern, ²Spiez Laboratory, Federal Office for Civil Protection, and ³Institute for Infectious Diseases, University of Bern, Switzerland

Two travellers returning from South America were diagnosed with Andes hantavirus infection, the only member of the *Hantaviridae* family known to be transmitted from person to person. We describe the clinical course and therapeutic and infection control measures. While both patients showed high viral load (VL) and shedding over several months, 1 patient recovered within 1 week from severe respiratory illness that required noninvasive ventilation, whereas the second patient developed severe hantavirus cardiopulmonary syndrome that required extracorporeal membrane oxygenation for 27 days. The clinical course in the latter patient was complicated by severe disseminated intravascular coagulopathy with diffuse hemorrhage that necessitated mass transfusions, as well as by multiple organ failure, including the need for renal replacement therapy. Results of VL in blood, respiratory secretions, and semen for the first 9 months of follow-up are reported. To our knowledge, these are the first cases of Andes hantavirus infection detected in Europe.

Keywords. Andes hantavirus; hantavirus cardiopulmonary syndrome; hemorrhagic fever; American hantavirus; ECMO.

CASE REPORTS

Patient 1

A previously healthy 55-year-old man presented to our emergency department (ED) in early December 2016 with fever, chills, fatigue, and headaches. Together with his wife, he had trekked from Ecuador to Chile from September 2016 to November 2016. Activities also included camping and taking mud baths. Patient 1 first developed fever upon return to Switzerland, 7 days before seeking medical care. At presentation, hypotension (90/55 mm Hg), tachycardia (120 bpm), and fever (39°C) were noted. Blood tests revealed moderately elevated inflammatory markers (leucocytes, 7.3 G/L with 35% bands; C-reactive protein, 68 mg/L) and thrombocytopenia (48 G/L). Chest radiography showed mild perihilar pulmonary infiltrates. Malaria, dengue, human immunodeficiency virus

infection, and common viral respiratory pathogens were ruled out. During the first 24 hours of admission, the patient developed marked prostration and respiratory distress that required noninvasive mechanical ventilation for 4 days. A computed tomography (CT) scan of the chest confirmed bilateral pulmonary infiltrates with pleural effusions. Based on the travel history, hantavirus infection was suspected by the infectious disease and tropical medicine consult service and later confirmed by reverse transcription polymerase chain reaction (RT-PCR) as well as by positive immunoglobulin (Ig) M and IgG serology to be Andes hantavirus (ANDV). Given the pronounced weakness of the patient, he was transferred to a rehabilitation facility on day 8. Full recovery was achieved after another month.

Patient 2

The first patient's previously healthy 54-year-old wife presented to our ED with unspecific symptoms 18 days after her husband's admission. As she was in good clinical condition and vital signs were within normal range, the patient was discharged with the diagnosis of bronchitis. Serology and serum RT-PCR for ANDV had been negative 5 days earlier, taken after her husband's diagnosis was established, to check for past asymptomatic infection or for potential viral replication in the incubation period. However, 21 days after her husband's admission (day 1 for patient 2), she complained of extreme fatigue, myalgia, headache, and shortness of breath. Upon presentation, she

Received 18 December 2017; editorial decision 12 May 2018; accepted 21 May 2018; published online May 22, 2018.

Correspondence: C. Staehelin, Department of Infectious Diseases, Bern University Hospital, 3010 Bern, Switzerland (cornelia.staehelin@insel.ch).

Clinical Infectious Diseases® 2018;67(11):1788–95

© The Author(s) 2018. Published by Oxford University Press for the Infectious Diseases Society of America. This is an Open Access article distributed under the terms of the Creative Commons Attribution-NonCommercial-NoDerivs licence (<http://creativecommons.org/licenses/by-nc-nd/4.0/>), which permits non-commercial reproduction and distribution of the work, in any medium, provided the original work is not altered or transformed in any way, and that the work is properly cited. For commercial re-use, please contact journals.permissions@oup.com DOI: 10.1093/cid/ciy443

was febrile (38.6°C) with normal blood pressure, heart rate, and oxygen saturation at ambient air. Laboratory results (Table 1) revealed leukopenia (1.88 G/L) and thrombocytopenia (98 G/L). Malaria and common causes of respiratory infections were excluded. Admitted for suspected ANDV infection, she deteriorated rapidly, requiring intubation and mechanical ventilation for acute respiratory failure on day 2. Only a few hours later, the patient fulfilled fast entry criteria for extracorporeal membrane oxygenation (ECMO) due to severe acute cardiopulmonary failure (PaO₂/FiO₂ ratio, 31), and peripheral veno-arterial ECMO was installed (venous cannula in right femoral vein; arterial cannula in left femoral artery). On the same day, she also developed life-threatening diffuse hemorrhage with advanced coagulopathy and profound thrombocytopenia (nadir, 15 G/L on day 4), suggesting disseminated intravascular coagulation. During the next 3 days, she required mass transfusions of blood products: 62 packed red blood cell units, 24 thrombocyte concentrates, and 53 units of fresh frozen plasma, and over 4 weeks a total of 102, 42, and 67 units, respectively (Figure 1). Hypoperfusion of the left leg due to the ECMO access made sternotomy for central ECMO cannulation necessary. Severe reperfusion injury and compartment syndrome of the left leg resulted in several vascular interventions and, ultimately, in through-knee amputation on day 9. Moreover, compartment syndrome due to capillary leak necessitated multiple fasciotomies of the right leg and amputation of 3 toes. Five emergency interventions were required due to diffuse bleeding from the

different ECMO insertion sites (mediastinum and groin) as well as from the left pulmonary lobe. Hemodiafiltration was started on day 4 for anuric renal failure. We administered ribavirin for 13 days from day 3 onward and added corticosteroid therapy for pronounced capillary leak syndrome. The patient also received broad-spectrum antibiotics as empiric treatment due to severe sepsis and worsening respiratory failure. Later, in view of possible candidemia, anidulafungin was supplemented.

Cardiac function stabilized over the subsequent 2 weeks, whereas respiratory function remained compromised, with a chest CT showing carnification of both basal lung fields and left pleural effusion (Figure 2). Culture of purulent pleural effusions on day 12 revealed *Aspergillus fumigatus*, and anidulafungin was replaced with voriconazole. Ventilator-associated pneumonia with *Pseudomonas aeruginosa* with increasingly resistant strains made combination antibiotic therapy necessary. ECMO was switched from venoarterial to venovenous cannulation on day 9. Because of intrathoracic compartment syndrome, closure of the thorax was only possible on day 15. In week 6, sternum infection with *P. aeruginosa* required several revisions and secondary closure with a rectus abdominis muscle flap. The patient was decannulated from ECMO on day 29. At 9 months after diagnosis, she still required positive pressure ventilation support all night and periodically during the day. Renal replacement therapy was discontinued after 46 days. Due to further complications, the patient remained in acute care for 6 months before transfer to a rehabilitation center.

Table 1. Laboratory Results of Patient 2 From Day 3 (First Ambulatory Visit to Emergency Department) to Day 7 (One Week After Admission)

| Laboratory Value | Reference Range | Day 3 | Day 1 | Day 2 | Day 3 | Day 4 | Day 5 | Day 6 | Day 7 |
|---|--------------------|-------|-------|-------|-------|-------|-------|-------|-------|
| Creatinine | (45–84 mmol/L) | 64 | 66 | 64 | 66 | 162 | 128 | NA | NA |
| Estimated glomerular filtration rate according to Chronic Kidney Disease Epidemiology Collaboration | (>59 mL/min) | >90 | >90 | >90 | >90 | 31 | 41 | NA | NA |
| Urea | (3.5–7.2 mmol/L) | 3.7 | NA | 2.4 | 3.8 | 9.4 | 10.8 | NA | NA |
| C-reactive protein | (<5 mg/L) | <3 | 7 | 53 | 72 | 50 | 68 | NA | NA |
| Procalcitonin | (<0.1 µg/L) | NA | NA | NA | NA | 45.8 | NA | NA | NA |
| Aspartate aminotransferase | (<35 U/L) | NA | 24 | 158 | 151 | 1514 | 479 | NA | NA |
| Alanine aminotransferase | (<35 U/L) | NA | 19 | 157 | 107 | 975 | 142 | NA | NA |
| Lactate | (0.63–2.44 mmol/L) | NA | 0.8 | NA | 10.5 | 10.8 | 9.7 | 3.3 | 1.8 |
| pH (arterial) | (7.35–7.45) | NA | NA | NA | 7.15 | 7.16 | 7.3 | 7.43 | 7.45 |
| Creatinine kinase | (>170 U/L) | 55 | NA | NA | 102 | 213 | 9235 | NA | NA |
| Leukocytes | (3.0–10.5 G/L) | 3.15 | 2.02 | 2.37 | 19.1 | 7.19 | 8.27 | 7.44 | 7.3 |
| Hemoglobin | (121–154 g/L) | 145 | 131 | 128 | 93 | 69 | 98 | 75 | 86 |
| Hematocrit | (0.36–0.44 L/L) | 0.42 | 0.38 | 0.37 | 0.28 | 0.19 | 0.28 | 0.21 | 0.25 |
| Platelets | (150–450 G/L) | 182 | 98 | 57 | 20 | 15 | 32 | 49 | 23 |
| Neutrophils | (1.6–7.4 G/L) | NA | 1.48 | 1.72 | NA | 4.63 | 4.26 | 4.72 | 5.8 |
| Lymphocytes | (1.1–3.5 G/L) | NA | 0.39 | 0.38 | NA | 1.11 | 1.08 | 0.1 | 0.73 |
| INR | <1 | <1 | 1.06 | 1.1 | 1.46 | 1.7 | 1.22 | 1.15 | 1.07 |
| Activated partial thromboplastin time | (25.0–36.0 sec) | NA | 42.1 | 45.2 | 79.9 | 86.8 | 63.8 | 54 | 42 |
| Thrombin time | (15.5–19.4 sec) | NA | 15.8 | 16.8 | 50.5 | 23.2 | 24.1 | 32.4 | NA |
| Fibrinogen Clauss | (1.8–4.2 g/L) | NA | 2.7 | 2.35 | 1.18 | 1.1 | 2.13 | 1.85 | 1.94 |
| D-dimer | (<500 µg/ml) | 182 | NA | NA | NA | NA | 1744 | NA | 2480 |

Laboratory values are only given for the first week of treatment, as thereafter the values are mainly influenced by renal replacement therapy (starting on day 4) and mass transfusions of blood and coagulation products (starting on day 5).

Abbreviations: INR, International Normalized Ratio; NA, not available.

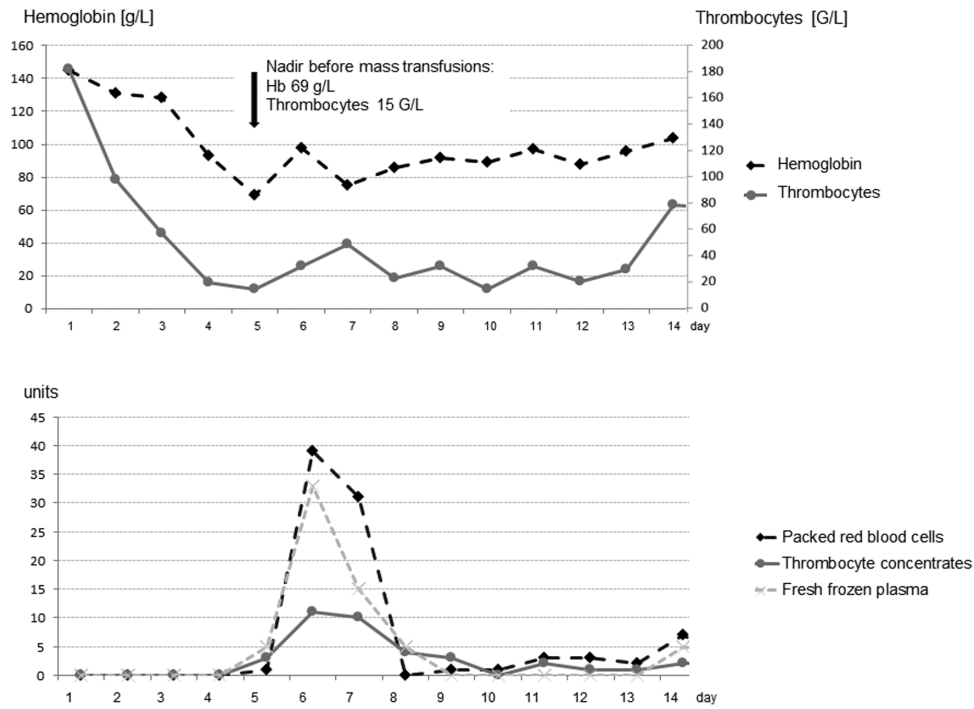


Figure 1. Evolution of hemoglobin and thrombocyte values and corresponding transfusion needs for patient 2. Abbreviation: Hb, hemoglobin.

Infection Prevention and Control Measures

As soon as ANDV infection was suspected in patient 1, he was placed under contact and droplet precautions. These measures were stopped after the patient’s respiratory symptoms subsided. Being this patient’s only close contact, the wife was

advised to seek medical attention in case of symptoms. The ED was informed of the need for contact and droplet precautions to prevent secondary cases. These precautions were started the second time the wife presented to the ED (day 1). Upon transfer to the intensive care unit, infection control measures were

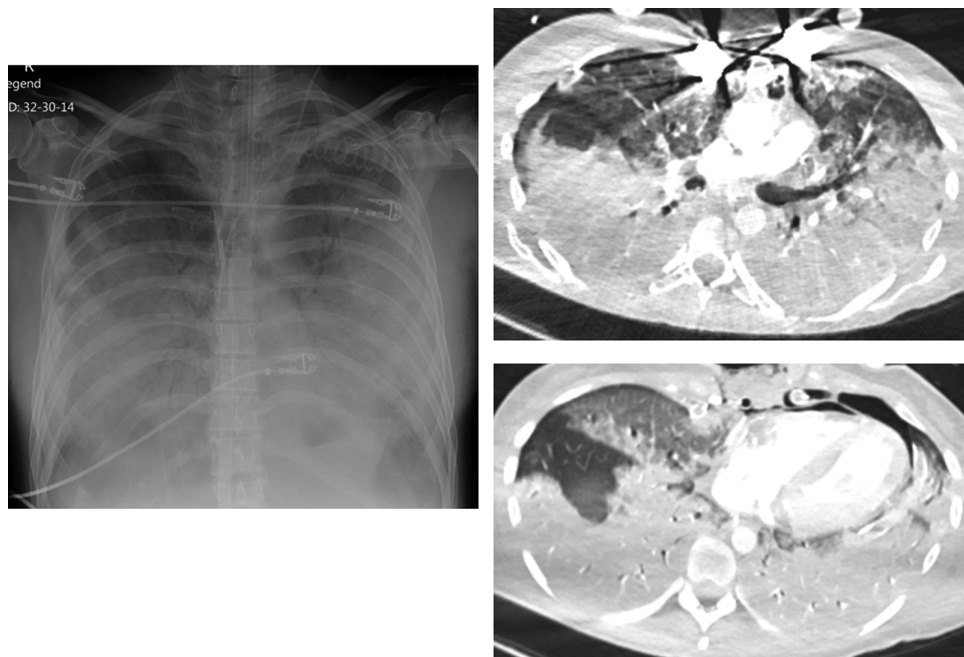

Figure 2. Chest radiography, day 3, and chest computed tomography scan with contrast enhancement, day 11, of patient 2.

escalated to contact and airborne precautions in a negative pressure room with anteroom. Daily ward rounds were performed by the infection prevention and control (IPC) team to ensure these measures were implemented correctly.

Local health authorities were informed of both cases, as required by Swiss law. The couple's travel company was also notified, and a proMED message [1] was released.

A survey of all personnel exposed to these 2 patients before installation of isolation precautions found 35 contacts for each case. No unprotected exposure during an aerosol-creating procedure was identified. One cardiac surgeon received a blood-tinged splash of rinsing liquid close to his eye on day 4. Serological follow-up was proposed, which he declined. He did not develop any symptoms suggestive of ANDV infection nor did any other healthcare worker involved.

Processing of blood samples was modified in order to prevent any exposure to aerosolized body fluids. Bedside tests were used wherever possible. Transport of blood samples within the hospital and to the external laboratory was executed by porters; for road transport, tubes were placed in a safety container as required by law. Any blood analysis that required opening tubes after centrifugation was performed in a safety cubicle. Type and screen testing can only be done with open tubes in our facility; hence, this analysis was omitted after risk evaluation from day 5 onward.

Waste and facility management are discussed in the [Supplementary Materials](#). IPC measures were discontinued when follow-up RT-PCR tests indicated decreasing viral loads (VLs) after 10 weeks. Multiresistant *P. aeruginosa* infection required continued contact precaution measures.

Virology

Molecular confirmation of ANDV was obtained by pan-Hantavirus RT-PCR [2] and subsequent sequencing of the amplicon for both patients. Phylogenetic analysis showed the strongest similarities with the ANDV isolate AH-1. Homology was later confirmed by complete genome analysis (manuscript in preparation). We monitored VL by an in-house quantitative real-time (qRT)-PCR method in EDTA whole blood and serum samples, respiratory specimens, and urine for up to 9 months, as shown in [Figure 3](#). Detailed information on the qRT-PCR and serology can be found in the [Supplementary Materials](#).

Discussion of the 2 Patients

Our 2 patients illustrate 3 major points: the clinical course of ANDV does not correlate with VL [3] but seems to be determined by host immunology [4]; IPC represents a substantial challenge in hemorrhagic fevers with potential human-to-human transmission; and ANDV appears to be yet another virus with prolonged viremia and shedding from sanctuary compartments such as semen.

While the clinical course in patient 1 was of moderate severity, patient 2, despite lower viremia, experienced severe hantavirus

cardiopulmonary syndrome (HCPS). We assume her severe lung damage to be multifactorial, including host immunology, viral pathology, hemorrhage, sepsis, and ventilation damage. Lung biopsy was not performed. The prolonged cardiorespiratory failure led us to suspect bacterial and later fungal superinfection. In retrospect, administration of broad-spectrum antibiotics in the initial phase would not have been necessary and favored appearance of multiresistant *P. aeruginosa*. Our second patient was treated with ribavirin in view of encouraging results in an animal model [5], despite concerns about side effects and lack of effectiveness.

The prolonged detection of viral RNA in different body compartments (respiratory secretions, whole blood, and semen) was unexpected. While whole blood samples were last positive on day 74 in patient 2 and on day 151 in patient 1, monitoring of semen in patient 1 was still ongoing at the time this manuscript was submitted. Despite this prolonged replication in various compartments, to our knowledge, clinical relapses have not been described and did not occur in our patients either.

The incubation periods for our patients were 5 to 34 days and 25 to 54 days. The interval between presentations of the 2 patients was 20 days, coinciding with the reported median for cases of person-to-person transmission. Our couple reported having sex only with condoms, leaving "deep kissing" as a possible route of transmission [6]. However, exposure to a common source is more frequent, and the incubation period for patient 2 is also compatible with such a scenario.

THE PATIENTS PUT IN CONTEXT—LITERATURE REVIEW

ANDV, a New World species of the genus *Orthohantavirus*, family *Hantaviridae*, belongs to the order of *Bunyavirales* [7]. It was first isolated in 1995 and is mainly found in Argentina and Chile, where seroprevalences vary from 0.5% to 6% [8]. HCPS was first described in 1993 in a patient with Sin Nombre virus infection in the United States [9, 10]. About 4000 HCPS cases have since been reported in South America [11]. In 2016, a local outbreak of ANDV caused 7 fatal cases in the region of Araucania, Chile [12]. Our patients had travelled that region during the last 3 weeks of their journey. Infection with ANDV has not been previously reported in Europe.

Transmission from its host, the long-tailed pygmy rice rat (*Oligoryzomys longicaudatus*), occurs through inhalation of dried excreta or direct contact [13]. To date, ANDV is the only hantavirus known to be transmitted from person to person, a characteristic first described in 1995 [14]. The exact route of transmission remains unclear. About one third of the cases occur in clusters, with a median of 19.5 days between symptom onset in index and secondary cases (range, 4–30 days) [6].

ANDV has been detected in peripheral blood cells up to 15 days before (median, 11 days) and 35 days after symptom onset [6]. Viable ANDV was also found in urine of patients

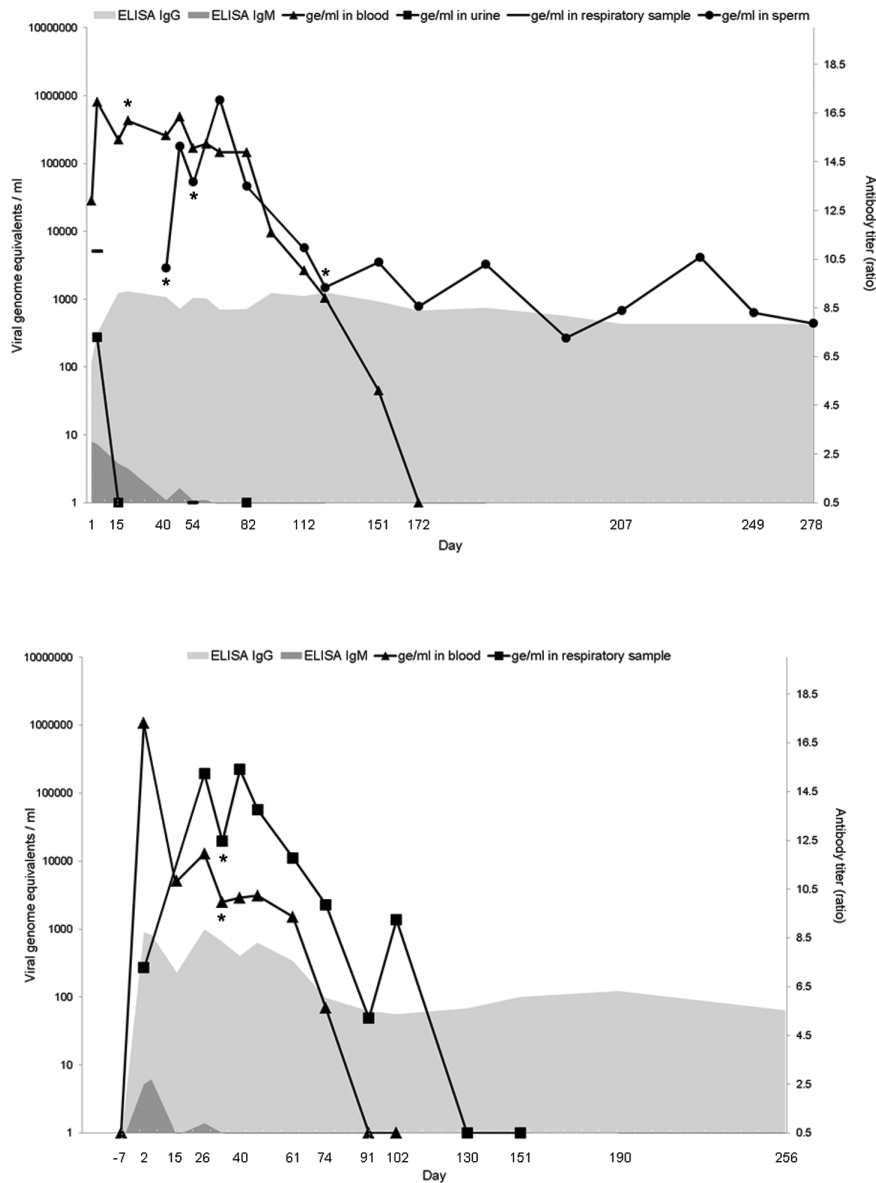


Figure 3. Course of Andes hantavirus RNA and anti-Andes hantavirus immunoglobulin (Ig) G/IgM antibodies for patient 1 (A) and patient 2 (B). RNA levels were assessed using in-house quantitative real-time polymerase chain reaction (qRT-PCR); measurements where a pronounced qRT-PCR inhibition was observed are marked with an asterisk (*). Serological parameters were assessed qualitatively by IgM/IgG immunoblot assay (IBA) (Euroline Hantavirus profile global, Euroimmun) and semiquantitatively by enzyme-linked immunosorbent assay (ELISA; Hantavirus Profile global, Euroimmun) by determining test-sample-to-calibrator ratio with a ratio of ≥ 1.1 rated positive (borderline ratio ≥ 0.8 to < 1.1); for IgG, a ratio of 8 corresponds to 260 RU/mL, a ratio of 5 to 160 RU/mL, and a ratio of 0.8 to 16 RU/mL. Comment on patient 1: viral load on day 1 was from a serum sample, and from day 4 onward from EDTA blood. On day 3, high Andes hantavirus (ANDV) viral load (8.07×10^5 GE/mL) in whole blood contrasted with a substantially lower load in serum (2.82×10^4 GE/ml) from the same day. Comment on patient 2: She tested negative for ANDV by RT-PCR in serum and for specific antibodies 1 week before onset of symptoms. Two days after admission, a high virus load was found in whole blood (1.07×10^6 GE/mL) and Hantavirus-specific IgM (ratio 2.5) and IgG antibodies (ratio 8.73) were detected by ELISA and IBA.

with HCPS [15]; furthermore, viral RNA was shown in gingival crevicular fluid and in saliva [16]. In a 4-week serological follow-up of 476 household contacts of 76 HCPS patients, the major risk factor for acquiring ANDV was being a sex partner, with 17.6% infected vs 1.2% of other household contacts (relative risk [RR], 14.9; 95% confidence interval [CI], 5.2–43.5), as was deep kissing (RR, 17.1; 95% CI, 4.7–62.5) and sharing the same bed (RR, 12.5; 95% CI, 4.0–38.5) [6]. In

another study, patients with fatal outcome were more likely to have caused secondary cases (41% vs 4%; $P = .005$) [17].

Reports of 2 ANDV outbreaks [18, 19] provide strong epidemiologic evidence for the virus's potential for nosocomial transmission, one involving 18 individuals, 5 of whom were physicians, with suspected transmission chains of up to 4 patients [18]. However, common exposure to rodent excreta might have been involved in some of the links. In contrast,

seroprevalences of healthcare workers exposed to respiratory secretions and blood of HCPS patients were not higher than in their community but lower than in household contacts [20–22]. This was noted despite poor compliance with IPC practices in some of the involved hospitals.

Clinical manifestations of ANDV infection range from unspecific febrile illness to its most severe form, HCPS. After an incubation period of 2 to 3 weeks (range, 7 to 39 days) [23], patients present with nonspecific prodromal symptoms over 2 to 8 days. Typically, respiratory symptoms and infiltrates on chest X-ray are absent in the beginning. Blood count may reveal thrombocytopenia, hemoconcentration, leucocytosis with left shift, and atypical lymphocytes [13, 24]. The cardiopulmonary phase begins abruptly, with cough, dyspnea, and precipitous hemodynamic instability due to cardiogenic shock and pulmonary edema. Capillary leak leads to hypovolemia, which may further impair cardiac and renal function. Hemorrhagic complications may occur [13], although severe disseminated intravascular coagulation is uncommon. In this phase, the disease can rapidly progress to multiorgan failure, and death may occur within 24 hours [25]. Disease pathology, which is characterized by microvascular leakage, is mainly attributed to host immune response, illustrated by the fact that infection of endothelial cells does not lead to cytopathology [26, 27]. Viral load does not appear to predict the severity of clinical presentation [3]. The cardiopulmonary phase usually lasts up to 7 days and is followed by a diuretic phase with resolution of the pulmonary edema. Convalescence may require several months.

Mortality in patients with HCPS due to ANDV is 20% to 40% [8, 28]. In survivors, antibody titers remain elevated for several years [29]. Reinfections have not been described to date [8].

Diagnosis is confirmed by RT-PCR from whole blood or by serology, either with presence of specific IgM antibodies or an at least 4-fold increase in IgG titers [30]. In early stages of the disease, RT-PCR, with a sensitivity of 100% and a specificity of 94% [31], is preferred over serology, which is typically negative in the prodromal phase. IgM can persist for up to 1 month. Whole blood yields higher levels of viral RNA than serum samples. A study found that ANDV RNA was still detected in leucocytes of 12 of 14 patients 84 days after presentation, while the ANDV RNA detected in plasma samples decreased rapidly over the first 7 days [32].

To date, there is no specific treatment or a vaccine against ANDV. Organ supportive therapy is the mainstay of treatment. Patients should be transferred to a tertiary intensive care unit immediately upon suspicion of ANDV infection, as ECMO support might be required [8]. ECMO is ideally placed before hemodynamic instability and major coagulopathy develop, according to a study comparing outcomes of 51 patients with Sin Nombre virus infection [33].

Ribavirin was shown to reduce mortality in patients with Old World hantavirus infection causing renal syndrome [34]. An in

vitro study in ANDV-infected human endothelial cells demonstrated that ribavirin is highly effective in preventing viral replication but not efficient in completely suppressing the overwhelming cytokine production [35]. However, a metaanalysis [36] of 2 clinical studies, limited by their small case numbers, concluded that there was no treatment benefit in New World hantavirus infections.

Treatment with corticosteroids showed no significant effect on mortality [28, 32]. A recently published nonrandomized trial on 29 ANDV cases showed a trend toward reduced mortality in patients treated with plasma from HCPS survivors collected at least 6 months after their recovery [37].

Literature on IPC measures for ANDV is sparse. This poses a substantial challenge to clinical management. The Ministry of Health of Argentina [8] suggests standard hygiene and droplet precautions as well as treating the patient in a single room. During aerosol-generating procedures, however, healthcare workers are advised to wear high-efficiency respirator masks and ocular protection. We opted for a conservative approach in view of the nosocomial transmissions described in the literature and the severe course of patient 2. IPC measures were initially reiterated to the multiple involved teams on a daily basis. Risk perception varied among involved personnel and corresponded to different levels of anxiety, but this did not lead to refusal to care for the patient.

According to the Centers for Disease Control and Prevention [38], handling of human samples with ANDV infection requires biosafety level (BSL) 2, whereas treating cell cultures and infected rodents' tissues requires BSL 3 precautions.

As an enveloped virus, ANDV should be vulnerable to common disinfectants. Direct evidence for ANDV is lacking, so we based our decisions on studies of Old World hantaviruses, which showed inactivation by commonly used disinfectants [39, 40].

CONCLUSIONS

The report of these first 2 ANDV patients in Switzerland illustrates the variable clinical course of the disease and highlights the multiple levels of awareness and decision-making required in the recognition and management of unexpected, highly pathogenic, and potentially nosocomially transmissible agents. Treatment of returning sick travellers requires not only ruling out common febrile diseases but also awareness of the current epidemiology in the regions visited. The triad of inexplicable severe exhaustion, fever, and thrombocytopenia in an appropriate epidemiological context should alert clinicians to the possibility of a viral hemorrhagic fever. In ANDV infection, initial clinical findings are unspecific and rarely provide clues as to which patient will develop HCPS. Therefore, a low threshold for clinical suspicion of the entity and rapid transfer to a tertiary care center with ECMO and transfusion facilities are key to improving prognosis in severe HCPS.

The lack of clear knowledge on the exact transmission mode and the duration of infectivity posed substantial challenges for our IPC team. These uncertainties are reflected in IPC measures that consist of contact and different aspects of respiratory precautions, which does not fit any standard IPC approach. In retrospect, excluding laboratory procedures for the sole reason that they involved open tubes was overly cautious and might have unduly hampered clinical management of the patient. For the hospital as a whole, the management of these 2 patients has greatly improved overall knowledge and awareness of managing critically ill patients with uncommon infections that require enhanced precaution measures.

SUPPLEMENTARY DATA

Supplementary materials are available at *Clinical Infectious Diseases*. Consisting of data provided by the author to benefit the reader, the posted materials are not copyedited and are the sole responsibility of the author, so questions or comments should be addressed to the author.

Notes

Acknowledgments. We thank our colleagues and the heads of Infectious Diseases and the Institute for Infectious Diseases, Elia Lo Priore, Hansjakob Furrer, and Stephen Leib, for their encouraging support during the intensive phase of these patients' illness. We thank the heads of hematology and biochemistry laboratories of Bern University Hospital, Behrouz Mansouri and Martin Fiedler, for making diagnostics possible in an often hectic and loaded setting. We are deeply indebted to the Centers for Disease Control and Prevention (Viral Special Pathogens Branch) and World Health Organization (Pandemic and Epidemic Diseases), Barbara Knust and Daniel Bausch, for essential support and information on Andes hantavirus and primary infection prevention measures. The first confirmation of Andes hantavirus came from Bernhard Nocht Institute, Hamburg, Germany (Jonas Schmidt-Chanasit), for which we are very grateful. Finally, we are grateful for the generous and efficient collaboration and support for virological and serological assays from Spiez Laboratory, Switzerland (Marc Strasser, Denise Siegrist, Johanna Signer, and Christian Beuret).

Potential conflicts of interest. All authors: No reported conflicts of interest. All authors have submitted the ICMJE Form for Disclosure of Potential Conflicts of Interest. Conflicts that the editors consider relevant to the content of the manuscript have been disclosed.

References

1. ProMED-mail. Available at: <https://www.promedmail.org/>. Accessed 20 January 2017.
2. Klempa B, Fichet-Calvet E, Lecompte E, et al. Hantavirus in African wood mouse, Guinea. *Emerg Infect Dis* 2006; 12:838–40.
3. Bellomo CM, Pires-Marczeski FC, Padula PJ. Viral load of patients with hantavirus pulmonary syndrome in Argentina. *J Med Virol* 2015; 87:1823–30.
4. Ferrer CP, Vial CPA, Ferrés GM, et al. Genetic susceptibility to Andes hantavirus: association between severity of disease and HLA alleles in Chilean patients. *Rev Chil Infectol* 2007; 24:351–9.
5. Safronetz D, Haddock E, Feldmann F, Ebihara H, Feldmann H. In vitro and in vivo activity of ribavirin against Andes virus infection. *PLoS One* 2011; 6:e23560.
6. Ferrer M, Vial P, Marco C, et al; Andes Virus Household Contacts Study Group. Prospective evaluation of household contacts of persons with hantavirus cardiopulmonary syndrome in Chile. *J Infect Dis* 2007; 195:1563–71.
7. Adams MJ, Lefkowitz EJ, King AM, et al. Ratification vote on taxonomic proposals to the International Committee on Taxonomy of Viruses (2016). *Arch Virol* 2016; 161:2921–49.
8. Enfermedades infecciosas: hantavirus, Guía para el equipo de salud. Available at: <http://www.msal.gob.ar/images/stories/bes/graficos/000000065cnt-2016-guia-medica-hantavirus.pdf>. Accessed 1 February 2017.
9. Nichol ST, Spiropoulou CF, Morzunov S, et al. Genetic identification of a hantavirus associated with an outbreak of acute respiratory illness. *Science* 1993; 262:914–7.
10. Khan AS, Khabbaz RF, Armstrong LR, et al. Hantavirus pulmonary syndrome: the first 100 US cases. *J Infect Dis* 1996; 173:1297–303.
11. Figueiredo LT, Souza WM, Ferrés M, Enria DA. Hantaviruses and cardiopulmonary syndrome in South America. *Virus Res* 2014; 187:43–54.
12. Fue confirmado el séptimo caso de hantavirus de este año en la Araucanía. Available at: <http://www.araucañiacuenta.cl/fue-confirmado-el-septimo-caso-de-hantavirus-de-este-año-en-la-araucanía/>. Accessed 27 January 2017.
13. Castillo C, Nicklas C, Mardones J, Ossa G. Andes hantavirus as possible cause of disease in travellers to South America. *Travel Med Infect Dis* 2007; 5:30–4.
14. Enria D, Padula P, Segura EL, et al. Hantavirus pulmonary syndrome in Argentina. Possibility of person to person transmission. *Medicina (B Aires)* 1996; 56:709–11.
15. Godoy P, Marsac D, Stefas E, et al. Andes virus antigens are shed in urine of patients with acute hantavirus cardiopulmonary syndrome. *J Virol* 2009; 83:5046–55.
16. Ferrer M, Vial P, Marco C, et al. Presence of Andes virus genome in gingival crevicular fluid during acute hantavirus infection. IDSA 48th Annual Meeting, Vancouver, 2010.
17. Lázaro ME, Cantoni GE, Calanni LM, et al. Clusters of hantavirus infection, southern Argentina. *Emerg Infect Dis* 2007; 13:104–10.
18. Wells RM, Sosa Estani S, Yadon ZE, et al. An unusual hantavirus outbreak in southern Argentina: person-to-person transmission? Hantavirus Pulmonary Syndrome Study Group for Patagonia. *Emerg Infect Dis* 1997; 3:171–4.
19. Martínez-Valdebenito C, Calvo M, Vial C, et al. Person-to-person household and nosocomial transmission of Andes hantavirus, southern Chile, 2011. *Emerg Infect Dis* 2014; 20:1629–36.
20. Chaparro J, Vega J, Terry W, et al. Assessment of person-to-person transmission of hantavirus pulmonary syndrome in a Chilean hospital setting. *J Hosp Infect* 1998; 40:281–5.
21. Castillo C, Mardones J, Villagra E. Prevalence of anti-hantavirus antibodies in health care personnel in direct contact with patients with hantavirus pulmonary syndrome in Temuco, Chile 1997 to 1999. *Revista medica de Chile* 2000; 128:735–9.
22. Castillo C, Villagra E, Sanhueza L, Ferrer M, Mardones J, Mertz GJ. Prevalence of antibodies to hantavirus among family and health care worker contacts of persons with hantavirus cardiopulmonary syndrome: lack of evidence for nosocomial transmission of Andes virus to health care workers in Chile. *Am J Trop Med Hyg* 2004; 70:302–4.
23. Vial PA, Valdivieso F, Mertz G, et al. Incubation period of hantavirus cardiopulmonary syndrome. *Emerg Infect Dis* 2006; 12:1271–3.
24. Castillo C, Naranjo J, Sepúlveda A, Ossa G, Levy H. Hantavirus pulmonary syndrome due to Andes virus in Temuco, Chile: clinical experience with 16 adults. *Chest* 2001; 120:548–54.
25. Manigold T, Vial P. Human hantavirus infections: epidemiology, clinical features, pathogenesis and immunology. *Swiss Med Wkly* 2014; 144:w13937.
26. Borges AA, Donadi EA, Campos GM, et al. Polymorphisms in human leukocyte antigens, human platelet antigens, and cytokine genes in hantavirus cardiopulmonary syndrome patients from Ribeirão Preto, Brazil. *J Med Virol* 2014; 86:1962–70.
27. Terajima M, Hayasaka D, Maeda K, Ennis FA. Immunopathogenesis of hantavirus pulmonary syndrome and hemorrhagic fever with renal syndrome: do CD8+ T cells trigger capillary leakage in viral hemorrhagic fevers? *Immunol Lett* 2007; 113:117–20.
28. Riquelme R, Rioseco ML, Bastidas L, et al. Hantavirus pulmonary syndrome, southern Chile, 1995–2012. *Emerg Infect Dis* 2015; 21:562–8.
29. Manigold T, Mori A, Graumann R, et al. Highly differentiated, resting gn-specific memory CD8+ T cells persist years after infection by Andes hantavirus. *PLoS Pathog* 2010; 6:e1000779.
30. PAHO/WHO Epidemiological Alerts: 17 October 2013: Hantavirus Pulmonary Syndrome—Situation in the Americas. Available at: http://www.paho.org/hq/index.php?option=com_docman&task=doc_view&gid=23387&Itemid=270&lang=en. Accessed 6 January 2017.
31. Vial C, Martínez-Valdebenito C, Rios S, et al. Molecular method for the detection of Andes hantavirus infection: validation for clinical diagnostics. *Diagn Microbiol Infect Dis* 2016; 84:36–9.
32. Vial PA, Valdivieso F, Ferrer M, et al; Hantavirus Study Group in Chile. High-dose intravenous methylprednisolone for hantavirus cardiopulmonary syndrome in Chile: a double-blind, randomized controlled clinical trial. *Clin Infect Dis* 2013; 57:943–51.
33. Wernly JA, Dietl CA, Taber CE, et al. Extracorporeal membrane oxygenation support improves survival of patients with hantavirus cardiopulmonary syndrome refractory to medical treatment. *Eur J Cardiothorac Surg* 2011; 40:1334–40.
34. Huggins JW, Hsiang CM, Cosgriff TM, et al. Prospective, double-blind, concurrent, placebo-controlled clinical trial of intravenous ribavirin therapy of hemorrhagic fever with renal syndrome. *J Infect Dis* 1991; 164:1119–27.

35. Khaiboullina SF, Rizvanov AA, Lombardi VC, et al. Andes-virus-induced cytokine storm is partially suppressed by ribavirin. *Antivir Ther* **2013**; 18:575–84.
36. Moreli ML, Marques-Silva AC, Pimentel VA, da Costa VG. Effectiveness of the ribavirin in treatment of hantavirus infections in the Americas and Eurasia: a meta-analysis. *Virusdisease* **2014**; 25:385–9.
37. Vial PA, Valdivieso F, Calvo M, et al; Hantavirus Study Group in Chile. A non-randomized multicentre trial of human immune plasma for treatment of hantavirus cardiopulmonary syndrome caused by Andes virus. *Antivir Ther* **2015**; 20:377–86.
38. *Biosafety in Microbiological and Biomedical Laboratories*, 5th Edition. Available at: <https://www.cdc.gov/biosafety/publications/bmbl5/bmbl.pdf>. Accessed 29 January 2017.
39. Maes P, Li S, Verbeeck J, Keyaerts E, Clement J, Van Ranst M. Evaluation of the efficacy of disinfectants against Puumala hantavirus by real-time RT-PCR. *J Virol Methods* **2007**; 141:111–5.
40. Kraus AA, Priemer C, Heider H, Kruger DH, Ulrich R. Inactivation of Hantaan virus-containing samples for subsequent investigations outside biosafety level 3 facilities. *Intervirology* **2005**; 48:255–61.