



Management of Early Glottic Cancer Treated by CO₂ Laser According to Surgical-Margin Status: A Systematic Review of the Literature

Barbara Verro¹  Giuseppe Greco¹  Enzo Chianetta¹  Carmelo Saraniti¹ 

¹Department of Biomedicine, Neuroscience and Advanced Diagnostics, ENT Clinic, University of Palermo, Palermo, Italy

Int Arch Otorhinolaryngol 2021;25(2):e301–e308.

Address for correspondence Carmelo Saraniti, MD, PhD, Dipartimento di Biomedicina, Neuroscienze e Diagnostica Avanzata, Clinica Otorinolaringoiatrica, Università degli Studi di Palermo, Via del Vespro, 129, Palermo, 90127, Italy (e-mail: carmelo.saraniti@unipa.it).

Abstract

Introduction Transoral laser microsurgery (TLM) is the treatment of choice for Tis-T2 squamous cell glottic carcinomas due to its advantages compared with open surgery and radiotherapy. However, the CO₂ laser beam causes changes and damage on the specimens, making the histological assessment of resection margins, the gold standard for confirming radical tumor resection, sometimes difficult.

Objective To assess the different ways to manage patients depending on the status of the histopathological margin according to recent studies to detect the most commonly shared therapeutic strategy.

Data Synthesis We analyzed the literature available on the PubMed and Web of Science databases, including only articles published since 2005, using specific keywords to retrieve articles whose titles and abstracts were read and analyzed independently by two authors to detect relevant studies. Therefore, we focused on disease-free survival, overall survival, local control, laryngeal preservation, and disease-specific survival. Thus, 17 studies were included in the present review; they were grouped according to the status of the histological margin, and we analyzed the different management policies described in them. This analysis showed that there is not a shared strategy, though in most studies the authors performed a second-look surgery in the cases of positive margins and a close follow-up in cases of negative ones. The main disagreement is regarding the management of close or non-valuable resection margins, since some authors performed a second-look surgery, and others, a close follow-up.

Conclusions Definitely, the most shared policy is the second-look surgery in case of positive surgical margins, and a close follow-up in case of close or non-valuable resection margins.

Keywords

- ▶ glottic cancer
- ▶ squamous cell carcinoma
- ▶ laser surgery
- ▶ surgical margin
- ▶ second-look surgery

Introduction

Transoral laser microsurgery (TLM) was first used for the treatment of early glottic cancer in 1972, as described by Strong and Jako.¹ To date, TLM is the treatment of choice for

Tis-T2 squamous cell glottic carcinomas. Indeed, this surgical procedure has many advantages compared with open surgery and radiotherapy (RT), such as: lower morbidity, shorter hospitalization, lower costs, and better organ preservation, with a lower impact on voice quality and swallowing,

received
April 21, 2020
accepted
May 10, 2020
published online
September 24, 2020

DOI <https://doi.org/10.1055/s-0040-1713922>.
ISSN 1809-9777.

© 2020. Fundação Otorrinolaringologia. All rights reserved.
This is an open access article published by Thieme under the terms of the Creative Commons Attribution-NonDerivative-NonCommercial-License, permitting copying and reproduction so long as the original work is given appropriate credit. Contents may not be used for commercial purposes, or adapted, remixed, transformed or built upon. (<https://creativecommons.org/licenses/by-nc-nd/4.0/>)
Thieme Revinter Publicações Ltda., Rua do Matoso 170, Rio de Janeiro, RJ, CEP 20270-135, Brazil

Key Points

- To date, TLM is the treatment of choice for Tis-T2 squamous cell glottic carcinomas.
- The CO₂ laser beam could impair the histological assessment of the resection margins, which is the gold standard to confirm radical tumor resection.
- Second-look TLM is the most performed strategy in case of positive surgical margins.
- Close follow-up is the most shared policy in case of close or non-valuable resection margins.
- In cases of negative resection margins, follow-up represents the best approach.

ensuring a radical excision of the lesion.^{2,3} Nevertheless, to date, the main critical questions involve the histological evaluation of the surgical resection margins and the management of the patients according to the status of the margins.^{4,5} In fact, some authors suggest a “wait and see” policy,^{6,7} while others propose a second-look microlaryngoscopy^{8,9} or RT when the resection margins are positive and/or close and/or unclear. The surgical margin is considered positive if the tumor is on the specimen’s edge, and close if there is a close distance between the tumor and the margin itself that is not adequate to consider the excision completely safe. The main disagreement in the literature is regarding the margin-to-tumor distance. Indeed, some authors suggest 2 mm as a safe distance,^{7,10} while others consider 0.5 mm,^{6,11–13} and most suggest 1 mm.^{8,14–16} Moreover, the surgical margin is defined as non-valuable if laser artifacts such as carbonization make the assessment of the specimen’s edge difficult. The resection margin is assessed as negative by a pathologist if it is free of tumor, with a proper tumor-to-margin distance, which differs from study to study.

The aim of the present review was to analyze the different ways to manage patients depending on the status of the histopathological margin according to recent studies to try to detect the most commonly shared therapeutic strategy. Therefore, we focused on disease-free survival (DFS), overall survival (OS), local control (LC), laryngeal preservation (LP), and disease-specific survival (DSS).

Review of the Literature

Search Methodology

We analyzed the literature available on the PubMed and Web of Science databases, including only articles published since 2005. The search strategy consisted of reading titles and abstracts independently by two authors (CS and BV) to detect relevant articles that would be studied in their entirety. We also searched for articles listed in the references of the pertinent studies. For the research, we used the following keywords: *transoral laser microsurgery* or *transoral laser cordectomy* or *CO₂ laser* and *early glottic cancer* or *glottic cancer* and/or *second-look* and/or *margin status* or *surgical margins*. The inclusion criteria were early glottic cancer (Tis, T1, T2); TLM as the first therapeutic approach for glottic lesion; management according to the status of the surgical margin; absence of nodal and distant metastases (NOM0); patients without previous RT or surgery for laryngeal cancer; reporting of at least two of the following: DFS, OS, LC, LP, DSS; and mean or median follow-up period of at

least 40 months. Studies were excluded if: they were reviews or editorials or opinions or case reports with fewer than twenty patients; articles published in languages other than English; studies that also included primary supraglottic or subglottic cancer; the patients who had a glottic lesion were first treated with CT and/or RT or endoscopic microsurgery.

Study Selection

►Fig. 1 shows the method of selection of the articles. In total, 17 studies were included in the present review, and their characteristics are shown in ►Table 1 and ►Table 2.

Management of Positive Surgical Margin

In cases of positive resection margin, a second-look surgery was the most followed approach.^{8,17,18} Other authors, such as Hendriksma et al,¹⁴ Hartl et al,⁷ and Lee HS,¹¹ suggest a second-look TLM or close follow-up according to the surgeon’s evaluation during surgery or in cases of suspicion of relapse during the follow-up.

On the other hand, Fiz et al¹⁹ usually followed a different policy according to the number and depth of the positive margins: they prefer the close follow-up only if a superficial margin is positive, and the second-look procedure, open surgery or RT strategies if more than one superficial margin or the deep margins are positive. By using this strategy, Fiz et al achieved a 5-year DFS in 77.2%, DSS in 98.3%, and LP in 96.2% of their sample. The same protocol was followed by Galli et al²⁰ and Lucioni et al.²¹

Moreover, in another study, Lucioni et al¹⁵ suggested performing the second-look surgery or RT in case of positive deep surgical margins, and close follow-up for positive superficial margins, achieving a 3-year DFS in 84.7%, a 3-year DSS in 97.8% and a 5-year OS in 91.4% of their sample.

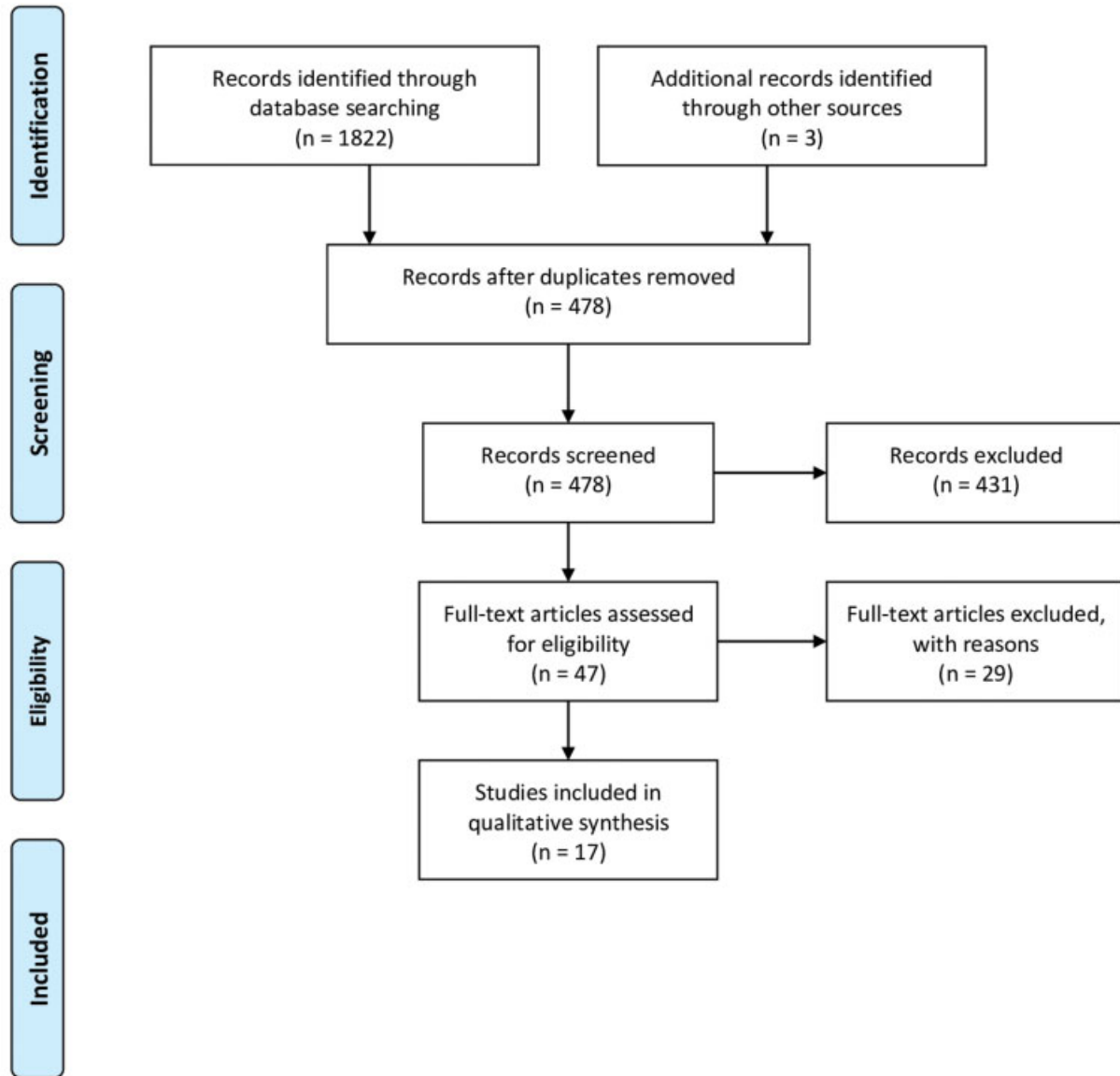
On the contrary, Ansarin et al¹⁶ perform a second look with TLM only if a resection margin is positive, and RT if there is more than 1 positive margin, achieving a 5-year OS in 90.01%, LP in 97.1%, and a 8-year DFS in 88.2% of their sample.

However, other authors^{6,10,12,13,22} always perform a close follow-up. Thus, in 2015, Hoffmann et al¹² achieved a 5-year OS in 79.2%, DSS in 91.5%, DFS in 61.7%, LP in 93.4%, and LC in 74.4% of their sample. In their case series, Charbonnier et al¹⁰ had similar findings, with a 5-year OS in 88%, DFS in 73%, and LC in 79% of their sample.

Preuss et al²³ performed second- and third-look TLMs in all patients regardless of the status of the resection margin, with a 5-year OS in 100%, and a 5-year DFS in 96.3% of their sample.



PRISMA 2009 Flow Diagram



From: Moher D, Liberati A, Tetzlaff J, Altman DG, The PRISMA Group (2009). Preferred Reporting Items for Systematic Reviews and Meta-Analyses: The PRISMA Statement. PLoS Med 6(7): e1000097. doi:10.1371/journal.pmed1000097

For more information, visit www.prisma-statement.org.

Fig. 1 Preferred Reporting Items for Systematic Reviews and Meta-Analyses (PRISMA) 2009 flow diagram of the selection process of studies in the current literature.

Table 1 Overall characteristics of the studies included

Authors	Number of patients	pT treated	Follow-up	OS	DSS	DFS	LP	LC
Hartl et al ⁷ (2007)	79	Tis-T1	56 months (mean)	/	97.3% (5 years)	89% (5 years)	97.5% (5 years)	95% (5 years)
Michel et al ¹⁷ (2011)	64	T1a	40 months (mean)	97% (5 years)	/	94% (5 years)	/	/
Hendriksma et al ¹⁴ (2018)	84	Tis-T1-T2	53 months (median)	98.6% (5 years)	78% (5 years)	/	100% (5 years)	78.6% (5 years)
Charbonnier et al ¹⁰ (2016)	110	T1-T2	43 months (mean)	88% (5 years)	/	73% (5 years)	/	79% (5 years)
Hoffmann et al ¹² (2015)	96	Tis-T1-T2	44.3 months (mean)	79.2% (5 years)	91.5% (5 years)	61.7% (5 years)	93.4% (5 years)	74.4% (5 years)
Osuch-Wójcikiewicz E et al ⁸ (2019)	102	T1-T2	48 months (median)	100% (5 years)	/	77.3% (5 years)	100% (5 years)	/
Ansarin et al ¹⁶ (2009)	318	Tis-T1-T2	58 months (median)	90.01% (5 years)	/	88.2% (8 years)	97.1% (5 years)	/
Hoffmann C et al ⁶ (2016)	201	Tis-T1-T2	50.82 months (mean)	84.6% (5 years)	96.2% (5 years)	70.6% (5 years)	96.8% (5 years)	86.7% (5 years)
del Mundo DA et al ¹³ (2019)	55	Tis-T1-T2	47 months (mean)	96% (5 years)	/	100% (5 years)	/	91% (5 years)
Estomba et al ¹⁸ (2016)	58	T1-T2	43.1 months (mean)	89.7% (3 years)	98.3% (3 years)	/	98.3% (3 years)	96.5% (3 years)
Fiz et al ¹⁹ (2017)	634	Tis-T1-T2	60 months (median)	/	98.3% (5 years)	77.2% (5 years)	96.2% (5 years)	/
Lucioni et al ¹⁵ (2012)	281	T1-T2	51 months (median)	91.4% (5 years)	97.8% (3 years)	84.7% (3 years)	/	/
Preuss et al ²³ (2009)	181	T1-T2	59 months (mean)	100% (5 years)	/	96.3% (5 years)	/	/
Gallet et al ²² (2017)	93	Tis-T1-T2	75.6 months (median)	/	96.8%	/	96.8% (5 years)	96.8% (5 years)
Galli et al ²⁰ (2016)	72	T1-T2	57.4 months (mean)	/	98.6% (5 years)	84.7% (5 years)	97.2% (5 years)	/
Lee et al ¹¹ (2013)	118	T1-T2	69.36 months (mean)	92.2% (5 years)	99% (5 years)	87.9% (5 years)	96.2% (5 years)	94.2% (5 years)
Lucioni et al ²¹ (2011)	177	T1-T2	49.1 months (mean)	90.8% (2 years)	98.8% (2 years)	/	97.6% (2 years)	94.3 (2 years)

Abbreviations: DFS, disease-free survival; DSS, disease-specific survival; LC, local control; LP, laryngeal preservation; OS, overall survival; pT, tumor stage.

Table 2 Features of management of early glottic cancer in included studies

Authors	Margin-to-tumor distance	Positive margins	Close or non-valuable margins	Negative margins	Suspicion on follow-up	Timing second look from first surgery	en bloc versus piecemeal excision	laser setting (watt, spot size)
Hartl et al ⁷ (2007)	2 mm	close follow-up (++) or second look (+) according to surgeon's impressions	close follow-up (++) or second look (+) according to surgeon's impressions	follow-up	/	< 1 month	en bloc	/
Michel et al ¹⁷ (2011)	/	second look (biopsies)	/	follow-up	/	10 weeks	/	7-12 weeks
Hendriksma et al ¹⁴ (2018)	/	close follow up (++) or second look (+) according to surgeon's impressions (biopsies)	close follow up (++) according to surgeon's impressions	follow-up	/	/	piecemeal	/
Charbonnier et al ¹⁰ (2016)	2 mm	close follow-up	/	follow-up	/	/		5-10 weeks; 0.25 mm
Hoffmann et al ¹² (2015)	0.5 mm	close follow-up		follow-up	second look	/	/	/
Osuch-Wójcikiewicz E et al ⁸ (2019)	1 mm	second look	second look	follow-up	/	3-4 weeks	/	/
Ansarin et al ¹⁶ (2009)	1 mm	if 1 margin: second look if > 1 margins: radiotherapy	second look	follow-up	/	/	en bloc	0.8-4.7 weeks; 0.15 mm
Hoffmann et al ⁶ (2016)	0.5 mm	follow-up	follow-up	follow-up	/	/	/	/
del Mundo et al ¹³ (2019)	/	close follow-up with narrow-band imaging	/	follow-up	second look	/	/	/
Estomba et al ¹⁸ (2016)	/	second look	follow-up (second look only if high endoscopic suspicion)	follow-up	/	/	en bloc	4-8 weeks
Fiz et al ¹⁹ (2017)	1 mm	- 1 superficial margin: close follow-up - > 1 superficial margins: second look, open surgery or RT - deep margin: second look, open surgery or RT	close follow-up	follow-up	/	/	en bloc and piecemeal	/
Lucioni et al ¹⁵ (2012)	1 mm	- superficial margin: close follow-up - deep margin: second look or RT	close follow-up	follow-up	/	/	en bloc	0.27 mm
Preuss et al ²³ (2009)	/	second look (biopsy)			/	8-10 weeks (first second look 16-20 weeks (second second look)	en bloc	/
Gallet et al ²² (2017)	3 mm	follow-up			second look	3 months	/	/
Galli A et al ²⁰ (2016)	1 mm	- 1 superficial margin: close follow-up - deep margin: second look (revision)	follow-up	follow-up	/	/	en bloc and piecemeal	/
Lee et al ¹¹ (2013)	0.5 mm	close follow-up (++) or second look (+) according to surgeon's impressions	/	follow up	/	/	en bloc and piecemeal	1-2 w
Lucioni et al ²¹ (2011)	1 mm	- 1 superficial margin: close follow-up - > 1 superficial margins: second look (revision) - deep margin: second look (revision)	follow-up	follow-up	/	/	en bloc and piecemeal	/

Management of Close or Non-valuable Surgical Margins

Regarding close or non-valuable resection margins, in the literature the most followed strategy was the close follow-up.^{6,11,12,15,18,19} However, Hendriksma et al¹⁴ and Hartl et al⁷ decided the most proper strategy between close follow-up and second-look surgery on a case-by-case basis. According to these authors, a surgeon's intraoperative evaluation is just as important as the histological assessment. Moreover, Hartl et al⁷ argue that in cases of disagreement between the surgeon and the pathologist (regarding positive or non-valuable margins), they usually performed a second-look TLM. In the literature, on the contrary, other authors recommend the second-look approach as a general rule if the margins are close or non-valuable.^{8,15,23}

Some studies did not examine this kind of surgical-margin status, assessing only positive and negative ones.^{10,12,13}

Management of Negative Surgical Margins

In the literature, there is no disagreement concerning the most proper approach in cases of negative resection margins. Thus, all authors suggest the follow-up. Only Preuss et al²³ performed at least two second-look microlaryngoscopies in cases of negative surgical margins.

Discussion

Summary of the Main Results

The present systematic review analyzed the different ways to manage patients previously treated with TLM depending on the histopathological status of the margin according to recent studies to try to detect the most commonly shared therapeutic strategy. The analysis showed that there is not a shared strategy, though most authors performed a second-look surgery in cases of positive margins, and follow-up in cases of negative ones. Regarding the management of close or non-valuable resection margins, there is a disagreement, since some authors performed a second-look, and others, close follow-up.

Challenges in the Histological Assessment of Resection Margins

The CO₂ laser beam causes changes and damage on the specimens, making the histological assessment of the resection margins, which is the gold standard to confirm radical tumor resection, sometimes difficult. In particular, laser-induced changes and damages could be due to the laser setting (spot size and power beam), which is adjusted by the surgeon, and the TLM experience of the surgeon themselves. Moreover, other issues that could impair margin assessment are small size and/or shrinking of the specimen during the histological preparation, carbonization, and difficulty in freezing sections.^{4,11,14,24–28} In particular, in the case of small specimens, making frozen sections or correctly orienting them is usually not possible, especially if the lesion is excised with the piece-meal technique. Indeed, in the literature, most authors^{7,15,16,18,23} report they prefer the en-bloc technique to ensure an adequate histopathological assessment. Some authors^{11,19–21} report using the en-bloc or piece-meal technique depending on the location of the

tumor, the depth of the infiltration, the laryngeal exposure, and the size of the tumor. In particular, Lee et al¹¹ argued that the en-bloc resection is recommended for small superficial tumors, while the piece-meal resection enables the assessment of the depth of the infiltration, especially in cases of extensive tumors. Only Hendriksma et al¹⁴ routinely prefer the multi-bloc technique. Their standard approach consists of resection of the tumor in two pieces and another five biopsies around the tumor bed.

Furthermore, the CO₂ laser induces an area of carbonization of 0.3 mm around the section line, which should be considered in the evaluation of margin status.²⁶ Indeed, since this carbonization makes it difficult to differentiate between positive and unclear resection margins, some authors^{11,14} decided to group these two different margins together, and recommend the same treatment approach, which is second-look or close follow-up according to the surgeon's evaluation. Preuss et al²³ routinely performed at least two second looks in all patients regardless of the status of the surgical margin due to charring artifacts that would not enable tumor detection in resection margins.

In their study, Buchanan et al²⁹ pointed out that the CO₂ laser induces a thermal cytologic damage that could result in misinterpretation or difficult assessment of margin status. In particular, they report that the CO₂ laser at a higher power causes less tissue damage thanks to the greater speed of the beam and, consequently, reduced contact between it and the cell. Furthermore, a small size of the laser beam spot (0.25 mm) ensures greater accuracy in the surgery and reduces tissue carbonization. However, in the literature, the CO₂ laser setting differed from study to study.^{10,11,15–18} Charbonnier et al¹⁰ performed TLM with a laser beam power between 5 W and 10 W, and a beam spot of 0.25 mm, while Ansarin et al¹⁶ preferred between 0.8 W and 4.7 W of laser power, and a spot size of 0.15 mm. Charbonnier et al¹⁰ treated 110 patients with 30 cases of positive resection margins; during the follow-up, 23 patients had recurrence, and among these, only 10 cases had positive margins, supporting the findings of Buchanan et al.²⁹ Meanwhile, Lee et al¹¹ performed TLM with a power setting of 1 W to 2 W in 118 patients with 65 cases of negative margins and 43 cases of positive margins: only 14 patients had recurrence during the follow-up, suggesting that the low laser power setting did not impair the correct histopathological assessment of the resection margins.

Photocoagulation of the Surgical Bed

Laser photocoagulation (LPC) of the surgical bed can be considered an effective technique to destroy any tumor remnant, thus reducing the risk of recurrence.^{10,15,18} Lucioni et al¹⁵ vaporized tissue around resection margins with the following laser setting: circular spot shape, spot size of 1.6 mm, and beam power of 16 W. They achieved a low local recurrence rate in cases of non-valuable, close and positive superficial margins. However, they also demonstrated that LPC is not able to destroy tumor cells in cases of positive deep margins. Furthermore, LPC does not impair voice quality, and so it can be routinely performed.

Margin-to-tumor Distance

Another main issue regarding TLM in glottic cancer concerns the margin-to-tumor distance. In the literature, this parameter differs from study to study. In particular, most authors^{8,15,16,19–21} establish 1 mm as a safe distance, while some^{6,11,12} suggest 0.5 mm, and a few^{7,10} report 2 mm. Moreover, the laser beam has a different effect on carcinoma and on healthy tissue that could help detect the tumor borderline. As a result, as aforementioned, the experience of the surgeon with the laser is very important for a radical tumor excision.

Management Policies According to the Status of the Resection Margins

Difficult histopathological assessment of resection margins, as well as disagreement over the margin-to-tumor distance result in different management policies in cases of positive, close and negative resection margins. Indeed, in cases of positive and close resection margins, some adopt a “wait and see” strategy with endoscopic follow-up, while others suggest a second-look TLM. In particular, in cases of positive margins, the literature reports that second-look TLM is the most accepted practice, with some differences from author to author. Some, such as Fiz et al,¹⁹ Galli et al,²⁰ and Lucioni et al,²¹ perform close follow-up in cases of just one positive superficial margin, and the second-look procedure in cases of more than one positive superficial margin or deep margins. Doing so, Fiz et al¹⁹ achieved a 5-year DFS in 77.2%, DSS in 98.3%, and LP in 96.2% of their sample. Other authors, such as Charbonnier et al¹⁰ and Hoffmann et al,¹² prefer a close follow-up approach in cases of positive margins, regardless of the depth of the infiltration and the number of positive margins. Thus, Hoffmann achieved a 5-year DFS, DSS, LP, OS and LC in 61.7%, 91.5%, 93.4%, 79.2%, and 74.4% of their sample respectively.¹² By comparing the results of these different strategies regarding the 5-year DFS, DSS and LP, the performance of the second-look surgery has better results than the close follow-up in cases of positive resection margins, ensuring a lower risk of recurrence and of invasive surgery, which can impair organ preservation. Preuss et al²³ suggest performing second- and third-look TLM in all patients regardless of the status of the resection margins, with a 5-year DFS in 96.3%, and a 5-year OS in 100% of their sample. Indeed, in their study, they found an increased incidence of residual tumor with two successive second-look TLMs, which enabled them to achieve complete resection of the tumor and early detection of recurrence, as demonstrated by a 5-year DFS in 96.3% of their sample, compared with a 5-year DFS in 73% and 61.7% in the studies by Charbonnier¹⁰ and Hoffmann¹² respectively.

Regarding close or non-valuable margins, close follow-up represents the most widely accepted approach.^{6,11,12,15,17,19} However, some surgeons perform follow-up or second-look TLM in a case-by-case basis.^{7,14} Actually, they have stated the importance of the surgeon's intraoperative evaluation over the histopathological assessment. Thus, in cases of a histological evaluation of positive or close resection margins, the surgeon

performs a second-look surgery or follow-up according to his/her evaluation of the radicalness of the of surgery.

Moreover, in 2014, after reviewing the then current literature, the European Laryngological Society (ELS) issued some evidence-based recommendations; in particular, it established that second-look TLM is mandatory in cases of positive margins, and recommended if the margins are close or non-valuable.³⁰

In cases of negative surgical margins, all authors suggest follow-up, except Preuss et al,²³ as aforementioned. However, several studies^{7,13,19,22} have reported the possibility of local recurrence even in cases of negative resection margins. Based on this point of view, follow-up, preferably with narrow-band imaging (NBI), is important to detect early recurrence.^{13,18} In fact, NBI is an endoscopic system that enables a better evaluation of the microvascular pattern in cases of preneoplastic and neoplastic lesions of the mucosa that cannot be examined with white-light endoscopy.³¹ So, NBI enables the detection of the early recurrence of the tumor and its superficial extension, but cannot evaluate the depth of the infiltration.

Timing of Second-Look TLM

In order to perform the early detection of recurrence or a residual tumor, rather than close follow-up, Preuss et al²³ prefer performing second-look TLM routinely. Moreover, they argue the importance of a short interval between the first and second TLMs. In fact, according to their protocol, the patients undergo two second-look procedures, at 8 and 16 weeks after the first surgery, regardless of the status of the resection margins, since they often found tumor remnants only after the second look. However, in the literature, there is discordance regarding the timing of the second-look TLM. Some authors^{7,8} recommend performing the second surgery ~ 3 to 4 weeks after the first TLM, while Gallet et al²² recommend it 3 months after. The latter argue that this period is adequate to detect any residual tumors and to avoid overtreatment at the same time, because, based on their experience, they found that recurrence usually occurs several months after surgery. The laser effects in terms of thermal damage and carbonization on treated tissue should also be considered and, therefore, the second-look surgery should be performed a few months after the first surgery, which is a sufficiently long time to ensure tissue healing and, thus, a radical tumor resection. However, in the literature, the timing of the second look is not usually reported, likely because the majority of clinicians do not consider it decisive for the outcome of the final surgery, which is complete tumor resection. The ELS does not make any recommendations regarding this, but it states that the timing of the second-look procedure is still controversial, and that it ranges from 1 to 8 months after the first surgery.³⁰

Final Comments

The objective of the present review was to detect a common policy in the treatment and follow-up of early glottic cancer after the first TLM surgery. We analyzed the different strategies

present in literature: second-look TLM or follow-up according to the different statuses of the resection margins. In particular, in the literature, the most accepted strategy is second-look TLM in case of positive surgical margins, and close follow-up in case of close or non-valuable ones. Furthermore, regarding negative resection margins, most authors suggest follow-up.

However, due to several issues that impact on the choice of policy, further studies, specially about laser-induced changes on resection margins, would be needed to establish a shared guideline.

Conflict of Interests

The authors have no conflict of interests to declare.

References

- Strong MS, Jako GJ. Laser surgery in the larynx. Early clinical experience with continuous CO₂ laser. *Ann Otol Rhinol Laryngol* 1972;81(06):791–798
- Grant DG, Salassa JR, Hinni ML, Pearson BW, Hayden RE, Perry WC. Transoral laser microsurgery for untreated glottic carcinoma. *Otolaryngol Head Neck Surg* 2007;137(03):482–486
- Preuss SF, Cramer K, Klussmann JP, Eckel HE, Guntinas-Lichius O. Transoral laser surgery for laryngeal cancer: outcome, complications and prognostic factors in 275 patients. *Eur J Surg Oncol* 2009;35(03):235–240
- Sigston E, de Mones E, Babin E, et al. Early-stage glottic cancer: oncological results and margins in laser cordectomy. *Arch Otolaryngol Head Neck Surg* 2006;132(02):147–152
- Fakhry N, Vergez S, Babin E, et al. Management of surgical margins after endoscopic laser surgery for early glottic cancers: a multicentric evaluation in French-speaking European countries. *Eur Arch Otorhinolaryngol* 2015;272(06):1465–1469
- Hoffmann C, Hans S, Sadoughi B, Brasnu D. Identifying outcome predictors of transoral laser cordectomy for early glottic cancer. *Head Neck* 2016;38(Suppl 1):E406–E411
- Hartl DM, de Monès E, Hans S, Janot F, Brasnu D. Treatment of early-stage glottic cancer by transoral laser resection. *Ann Otol Rhinol Laryngol* 2007;116(11):832–836
- Osuch-Wójcikiewicz E, Rzepakowska A, Sobol M, Bruzgielewicz A, Niemczyk K. *Oncological Outcomes of CO₂ Laser Cordectomies for Glottic Squamous Cell Carcinoma With Respect to Anterior Commissure Involvement and Margin Status*. Wiley Periodicals, 2019: 1–8
- Peretti G, Piazza C, Bolzoni A, et al. Analysis of recurrences in 322 Tis, T1, or T2 glottic carcinomas treated by carbon dioxide laser. *Ann Otol Rhinol Laryngol* 2004;113(11):853–858
- Charbonnier Q, Thisse AS, Slegheem L, et al. Oncologic outcomes of patients with positive margins after laser cordectomy for T1 and T2 glottic squamous cell carcinoma. *Head Neck* 2016;38(12):1804–1809
- Lee HS, Chun BG, Kim SW, et al. Transoral laser microsurgery for early glottic cancer as one-stage single-modality therapy. *Laryngoscope* 2013;123(11):2670–2674
- Hoffmann C, Hans S, Sadoughi B, Brasnu D. Identifying outcome predictors of transoral laser cordectomy for early glottic cancer. *Laryngoscope* 2015;•••:1–6
- del Mundo DAA, Morimoto K, Masuda K, et al. Oncological and functional outcomes of transoral CO₂ laser cordectomy for early glottic cancer. *Auris Nasas Larynx* 2019
- Hendriksma M, Montagne MW, Langeveld TPM, Veselic M, van Benthem PPG, Sjögren EV. Evaluation of surgical margin status in patients with early glottic cancer (Tis-T2) treated with transoral CO₂ laser microsurgery, on local control. *Eur Arch Otorhinolaryngol* 2018;275(09):2333–2340
- Lucioni M, Bertolin A, D'Ascanio L, Rizzotto G. Margin photocoagulation in laser surgery for early glottic cancer: impact on disease local control. *Otolaryngol Head Neck Surg* 2012;146(04):600–605
- Ansarin M, Santoro L, Cattaneo A, et al. Laser surgery for early glottic cancer: impact of margin status on local control and organ preservation. *Arch Otolaryngol Head Neck Surg* 2009;135(04):385–390
- Michel J, Fakhry N, Duflo S, et al. Prognostic value of the status of resection margins after endoscopic laser cordectomy for T1a glottic carcinoma. *Eur Ann Otorhinolaryngol Head Neck Dis* 2011;128(06):297–300
- Estomba CMC, Reinoso FAB, Velasquez AO, et al. Transoral CO₂ laser microsurgery outcomes for early glottic carcinomas T1–T2. *Int Arch Otorhinolaryngol* 2016;20(03):212–217
- Fiz I, Mazzola F, Fiz F, et al. Impact of Close and Positive Margins in Transoral Laser Microsurgery for Tis-T2 Glottic Cancer. *Front Oncol* 2017;7:245
- Galli A, Giordano L, Sarandria D, Di Santo D, Bussi M. Oncological and complication assessment of CO₂ laser-assisted endoscopic surgery for T1–T2 glottic tumours: clinical experience. *Acta Otorhinolaryngol Ital* 2016;36(03):167–173
- Lucioni M, Marioni G, Bertolin A, Giacomelli L, Rizzotto G. Glottic laser surgery: outcomes according to 2007 ELS classification. *Eur Arch Otorhinolaryngol* 2011;268(12):1771–1778
- Gallet P, Rumeau C, Nguyen DT, Teixeira PA, Baumann C, Toussaint B. “Watchful observation” follow-up scheme after endoscopic CO₂ laser treatment for small glottic carcinomas: A retrospective study of 93 cases. *Clin Otolaryngol* 2017;42(06):1193–1199
- Preuss SF, Cramer K, Drebber U, Klussmann JP, Eckel HE, Guntinas-Lichius O. Second-look microlaryngoscopy to detect residual carcinoma in patients after laser surgery for T1 and T2 laryngeal cancer. *Acta Otolaryngol* 2009;129(08):881–885
- Saraniti C, Speciale R, Gallina S, Salvago P. Prognostic role of resection margin in open oncologic laryngeal surgery: survival analysis of a cohort of 139 patients affected by squamous cell carcinoma. *Rev Bras Otorrinolaringol (Engl Ed)* 2019;85(05):603–610
- Peretti G, Nicolai P, Redaelli De Zinis LO, et al. Endoscopic CO₂ laser excision for Tis, T1, and T2 glottic carcinomas: cure rate and prognostic factors. *Otolaryngol Head Neck Surg* 2000;123(1 Pt 1):124–131
- Brøndbo K, Fridrich K, Boysen M. Laser surgery of T1a glottic carcinomas; significance of resection margins. *Eur Arch Otorhinolaryngol* 2007;264(06):627–630
- Dispenza F, Saraniti C, Mathur N, Dispenza C. Modified frontolateral laryngectomy in treatment of glottic T1(a-b) cancer with anterior commissure involvement. *Auris Nasas Larynx* 2010;37(04):469–473
- Shenoy AM, Prashanth V, Shivakumar T, et al. The utility of second look microlaryngoscopy after trans oral laser resection of laryngeal cancer. *Indian J Otolaryngol Head Neck Surg* 2012;64(02):137–141
- Buchanan MA, Coleman HG, Daley J, et al. Relationship between CO₂ laser-induced artifact and glottic cancer surgical margins at variable power doses. *Head Neck* 2016;38(Suppl 1):E712–E716
- Simo R, Bradley P, Chevalier D, et al. European Laryngological Society: ELS recommendations for the follow-up of patients treated for laryngeal cancer. *Eur Arch Otorhinolaryngol* 2014;271(09):2469–2479
- Campo F, D'Aguzzo V, Greco A, Ralli M, de Vincentiis M. The prognostic value of adding Narrow-Band Imaging in transoral laser microsurgery for early glottic cancer: a review. *Lasers Surg Med* 2019;•••:1–6