



## Review

# A case of hyperpigmentation induced by hydroxychloroquine and quinacrine in a patient with systemic lupus erythematosus and review of the literature

Daniel Kwak<sup>a</sup>, Pearl E. Grimes MD<sup>b,\*</sup><sup>a</sup> Vitiligo & Pigmentation Institute of Southern California, Los Angeles, CA, United States<sup>b</sup> Vitiligo & Pigmentation Institute of Southern California, Division of Dermatology, David Geffen School of Medicine, University of California, Los Angeles, CA, United States

## ARTICLE INFO

## Article history:

Received 12 July 2019

Received in revised form 20 May 2020

Accepted 24 June 2020

## Keywords:

Hydroxychloroquine

Hyperpigmentation

Systemic lupus erythematosus

Staining pattern

## ABSTRACT

Hydroxychloroquine (HQ) and quinacrine are widely used antimalarials for systemic lupus erythematosus (SLE) and other autoimmune diseases. We report a case of antimalarial-induced hyperpigmentation in a 57-year old African-American woman. The patient had a long-standing history of SLE that was treated with HQ and quinacrine in varying doses for 16 years. The disease improved considerably and entered remission; however, the patient subsequently developed severe, disseminated hyperpigmentation on her face, trunk, upper and lower extremities. A malar facial biopsy revealed numerous perivascular and scattered interstitial, heavily pigment laden dark brown to black macrophages. The Fontana Masson staining was positive for melanin, and Perl's stain for iron was negative. This staining pattern, to our knowledge, has only been reported once before in the literature. Our patient represents a rare case of severe recalcitrant hyperpigmentation induced by combination HQ and quinacrine therapy for SLE.

© 2020 Published by Elsevier Inc. on behalf of Women's Dermatologic Society. This is an open access article under the CC BY-NC-ND license (<http://creativecommons.org/licenses/by-nc-nd/4.0/>).

## Contents

Introduction.....	268
Case report .....	269
Discussion .....	269
Conclusion .....	271
Conflict of Interest .....	271
Funding .....	271
Study Approval .....	271
References .....	271

## Introduction

Antimalarial drugs have been widely used since 1953 for the treatment of systemic lupus erythematosus (SLE) after publication of the seminal work by Shee (1953), who reported the beneficial effects of chloroquine for lupus and rheumatoid arthritis (RA) in U.S. soldiers. Hydroxychloroquine (HQ) is the most frequently prescribed treatment for SLE and cutaneous lupus erythematosus. A common side effect of antimalarial agents is cutaneous hyperpig-

mentation and most cases are caused by chloroquine or HQ (Bahloul et al., 2017; Skare et al., 2018). A detailed review of antimalarial-induced hyperpigmentation in SLE reported on patients treated with HQ. We identified only 10 cases of hyperpigmentation induced by a combination therapy of HQ and quinacrine (Bahloul et al., 2017; Cho et al., 2012; Coulombe and Boccarda, 2017; Gallo et al., 2009; Jallouli et al., 2013; Mir et al., 2013; Mittal and Werth 2017; Morrison et al., 2009; Puri et al., 2008; Rood et al., 2008; Sawalha, 2015; Skare et al., 2011; Tuffanelli et al., 1963). Typically, patients with antimalarial-induced hyperpigmentation have blue-grey macules that gradually progress in

\* Corresponding author.

E-mail address: [pegrimes@pearlgrimesmd.com](mailto:pegrimes@pearlgrimesmd.com) (P.E. Grimes).

severity (Mir et al., 2013). Special staining of the skin often reveals higher concentrations of melanin and iron in the dermis.

We describe a rare case of a patient with disseminated severe hyperpigmentation secondary to the combination therapy of HQ and quinacrine for SLE. Our patient's biopsy was positive for melanin staining but negative for iron staining, which has rarely been reported. We review the literature for antimalarial-induced hyperpigmentation in patients with SLE.

### Case report

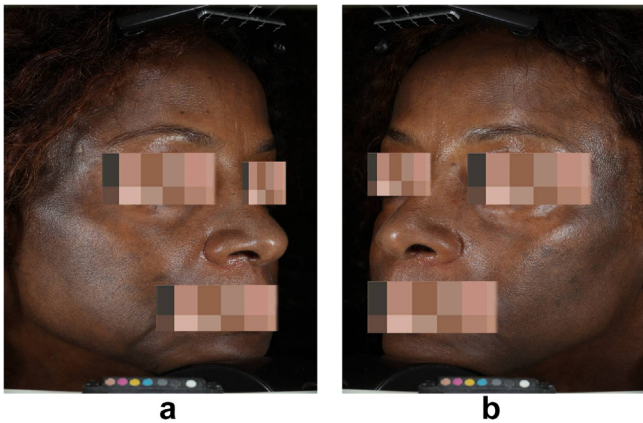The patient is a 57-year-old African-American woman who presented to the Vitiligo and Pigmentation Institute with a history of hyperpigmentation of the face, trunk, and extremities. The skin discoloration had progressed during the 5 years preceding her evaluation at our institute. She had been treated for SLE with varying doses of HQ, from 200 to 400 mg daily, and quinacrine for 16 years. At the time of evaluation, her SLE was in remission. Her medical history was unremarkable. Her initial SLE-related signs and symptoms included photosensitivity, alopecia, oral ulcers,

and arthralgias. She denied any history of bruising and had no risk factors for bruising, including any significance use of topical corticosteroids.

Cutaneous examination revealed severe disseminated areas of dusky, gray-black hyperpigmentation affecting the face, trunk, and upper and lower extremities in a patchy distribution (Figs. 1–3). Laboratory studies included a complete blood count with a differential, comprehensive metabolic panel, sedimentation rate panel, C-reactive protein, C3 and C4 complement levels, and a lupus panel. The results were unremarkable except for a low complement C4 of 24 mg/dL and a positive result for antinuclear antibodies.

Punch biopsies were taken from an involved hyperpigmented, lateral malar facial lesion and normal skin for comparison. The hyperpigmented patch revealed a flattened epidermis, scattered ectatic blood vessels, focal mild papillary dermal fibrosis, and numerous perivascular and scattered interstitial dark brown-black, heavily pigmented dermal macrophages (Fig. 3). The pigment stain tested positive for melanin with Fontana Masson and negative with the Perl's stain for iron (Figs. 4 and 5).

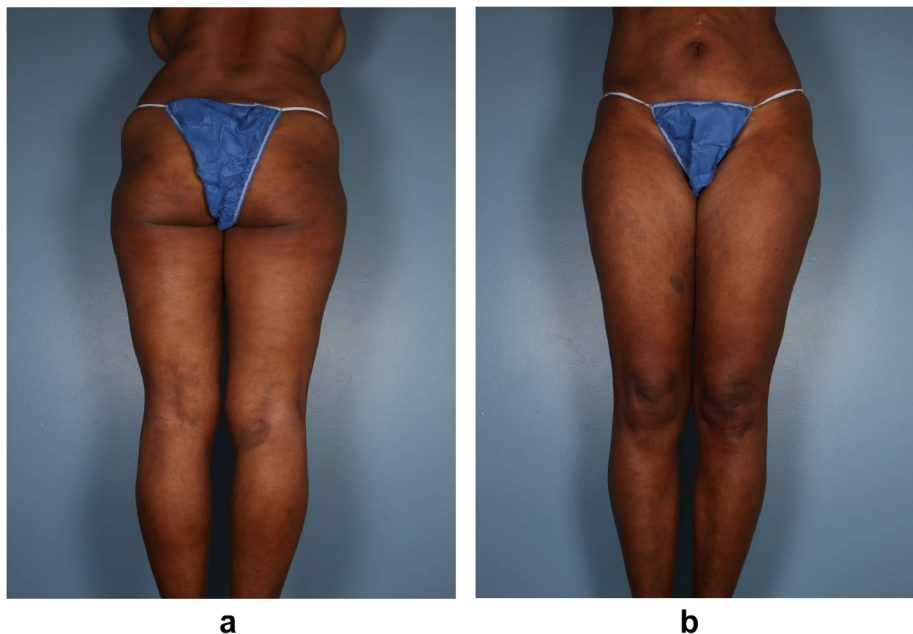
After her initial consultation, quinacrine was discontinued and HQ was tapered to 200 mg twice weekly. There was minimal improvement in the areas of hyperpigmentation of the face, trunk, and extremities during the next 3 years of follow-up. Overall, the hyperpigmented facial lesions were recalcitrant to topical lighteners, corticosteroids, and superficial peels.



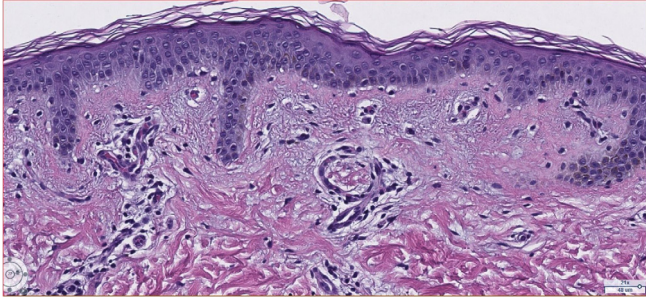
**Fig. 1.** Hyperpigmentation of (A) the face and (B) the right and left lateral facial regions. Severe areas of gray-black hyperpigmentation.

### Discussion

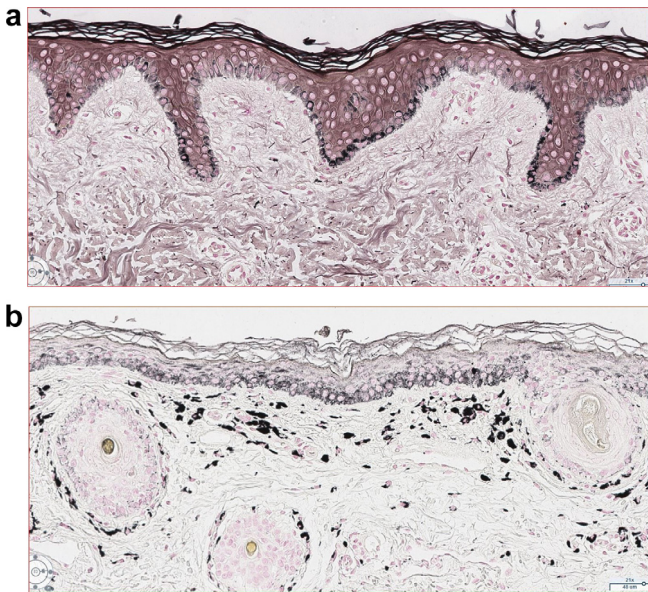
Antimalarials, including HQ and quinacrine, were previously utilized to treat malaria and are widely used today for autoimmune diseases such as RA, SLE, and discoid lupus erythematosus due to their immunosuppressive and anti-inflammatory actions (Bahloul et al., 2017). Despite their substantial efficacy, they are complicated by side effects, including localized and generalized hyperpigmentation. Cutaneous hyperpigmentation occurs in approximately 10% to 25% of patients on antimalarials (Puri et al., 2008). The incidence of chloroquine-induced hyperpigmentation is distinctly



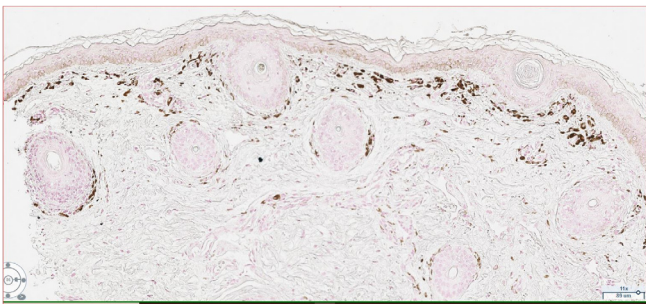
**Fig. 2.** Violaceous gray-black hyperpigmented patches of (A) the trunk and extremities and (B) anterior and posterior lower trunk and extremities.



**Fig. 3.** Hematoxylin and eosin stain: Some flattening of the epidermis, ectatic blood vessels, mild papillary dermal fibrosis, and scattered perivascular heavily pigmented macrophages.



**Fig. 4.** (A) Fontana-Masson stain (uninvolved facial skin): Unremarkable with a few pigment-laden macrophages in the papillary dermis. (B) Fontana-Masson stain (involved facial skin): Increased pigment deposition in the dermis. Numerous perivascular and scattered interstitial, heavily dark brown-black pigmented macrophages.



**Fig. 5.** Perl's Stain: Hyperpigmented patch. Dense pigmentation; however, negative stain for iron.

more common at 35%; only 13% is HQ-induced (Mir et al., 2013; Skare et al., 2011).

Tuffanelli et al. (1963) studied 25 patients with hyperpigmentation caused by antimalarial therapy. The study reported that 16 patients were on a mixture of antimalarials. However, the authors did not specify which combination of antimalarials was used

(Tuffanelli et al., 1963). A recent study by Mittal and Werth (2017) reported only 10 patients whose antimalarial-induced dyschromia was caused by a combination of quinacrine and HQ therapy. Our paper represents another rare case report of HQ- and quinacrine-induced hyperpigmentation in a patient with SLE. A more complete tabulation of studies on antimalarial-induced hyperpigmentation is shown in Table 1.

HQ's mechanism of action is mediated via the suppression of the activation of toll-like receptors on the surface of endosomes, thereby blocking innate and adaptive immune responses, including the reduction of interferon alpha levels (Shippey et al., 2018). A spectrum of cutaneous side effects has been reported with antimalarials, including xerosis, allergic reactions, pruritis, headaches, gastrointestinal changes, and even hair loss. Skin hyperpigmentation is common. Skare et al. (2011) retrospectively assessed the prevalence of cutaneous side effects of antimalarials in 209 patients. Of the group of antimalarial therapy users, 127 had SLE and 82 had RA. Hyperpigmentation was reported in slightly over 30% of patients and was detected mostly in the upper limbs and face. Mucousal hyperpigmentation was found in the cheeks (70%) and hard palate (20%) and was diffused in 10% of cases. Bahloul et al. (2017) reported a cross-sectional study of 41 cases of HQ-induced hyperpigmentation in systemic diseases. Of the group, 29% had HQ-induced skin pigmentation. All patients with HQ-induced pigmentation had SLE. Additionally, patients with dark Fitzpatrick skin phototype represented 83% of all cases.

Quinacrine, the first antimalarial to be widely used, is still commonly used today, especially in patients who are intolerant or unresponsive to HQ. Parallel to our case, most patients often use a combination of both HQ and quinacrine. The Office of New Drugs suggests 100 mg of quinacrine daily, although this dosage may vary depending on the patient (Mittal and Werth, 2017). The dosage ranges mostly from 50 to 100 mg. Quinacrine follows a similar mechanism to HQ, but whereas HQ induces gray and black hyperpigmented lesions, quinacrine often results in yellowish discolorations (Shippey et al., 2018).

A spectrum of changes has been reported in the biopsies of the hyperpigmented lesions. Higher melanin and iron concentrations are often reported (Bahloul et al., 2017; Cho et al., 2012; Jallouli et al., 2013; Rood et al., 2008; Sawalha, 2015). Histological studies suggest that the cutaneous hyperpigmentation is caused by the high content of melanin and iron within the lesions. Most cases of HQ-related hyperpigmentation occurred in patients with darker Fitzpatrick skin types. These darker skin types are known to have a higher content of epidermal melanin (Bahloul et al., 2017; Gallo et al., 2009). The correlation of HQ-induced hyperpigmentation in darker skin types suggest that HQ is capable of binding to melanin, similar to chloroquine (Mir et al., 2013; Morrison et al., 2009).

Our case had a positive Fontana Masson stain for melanin and a negative Perl's stain for iron. This pattern of staining for HQ, to our knowledge, has only been reported one other time (Puri et al., 2008). Other cases of HQ-induced hyperpigmentation have reported the presence of both melanin and hemosiderin, which is the body's iron storage complex (Rood et al., 2008; Tuffanelli et al., 1963). The positive stain for melanin confirms that HQ can bind to melanin. In contrast, the negative staining for iron indicates that higher iron levels, or the presence of hemosiderin deposits, may not be a primary cause of hyperpigmentation.

Oral anticoagulants, along with oral antiplatelets, are also considered to have strong associations with antimalarial-induced hyperpigmentation (Bahloul et al., 2017; Coulombe and Boccara, 2017; Shippey et al., 2018). In a study by Bahloul et al. (2017), out of 41 patients who had HQ-induced hyperpigmentation, the percentage of patients who also consumed anticoagulants and/or antiplatelet agents was 58.33% versus 24.1% of patients who did not take these agents. The probability of having skin discoloration due

**Table 1**

Review of the literature: Antimalarial-induced hyperpigmentation and staining patterns in patients with SLE.

Study	Past diagnosis	Antimalarial taken	Hyperpigmentation? (Y = yes; N = no)	Hemosiderin	Melanin
Bahloul et al., 2017	12 SLE	HQ (all 12)	Y for all	Not shown	Not shown
Cho et al., 2012	RA	HQ	Y	NS	Present
Coulombe and Boccara, 2017	SLE	HQ	Y	Present	Present
Gallo et al., 2009	1 RA 1 Sjogren's syndrome	CQ (both)	Y for both	NS	NS
Jallouli et al., 2013	24 SLE	HQ	Y for all	NS	NS
Mir et al., 2013	SLE	HQ	Y	NS	NS
Mittal and Werth, 2017	Cutaneous lupus erythematosus (number NS) Dermatomyositis (number NS)	312 HQ + quinacrine 85 CQ + quinacrine	10 Y, N for rest	NS	NS
Morrison et al., 2009	Subacute cutaneous lupus erythematosus	HQ	Y	NS	NS
Puri et al., 2008	1 Arthritis-predominant connective tissue disease 1 SLE/RA	HQ (both)	Y for both	Negative in both	Present in both
Rood et al., 2008	RA	HQ	Y	Present	Present
Sawalha, 2015	RA	HQ	Y	NS	NS
Skare, 2011	127 SLE 82 RA	194 CQ 15 HQ	159 Y, N for rest	NS	NS
Tuffanelli et al., 1963	17 SLE 6 DLE 2 RA	7 CQ 1 quinacrine 1 HQ 16 multiple antimalarial	Y for all	Present in all	Present in all

CQ, chloroquine; DLE, discoid lupus erythematosus; HQ, hydroxychloroquine; NS, not shown; RA, rheumatoid arthritis; SLE, systemic lupus erythematosus.

to HQ with a history of taking anticoagulant or antiplatelet agents was also significantly higher ( $p = .03$ ). The low  $p$ -value suggests a strong correlation between HQ-induced hyperpigmentation and anticoagulant/antiplatelet use. Our patient did not ratify this trend because she had no history of anticoagulant or antiplatelet therapy.

Along with pigment changes, prolonged use of HQ may increase the risk of retinopathy. As the duration of use increases, so does the risk for irreversible vision loss (Coulombe and Boccara, 2017; de Melo Filho et al., 2012; Shippey et al., 2018). Consequently, it is important for patients to be checked after prolonged use of HQ. Our patient did not have any vision loss.

## Conclusion

We report a rare case of severe disseminated hyperpigmentation caused by the combination of HQ and quinacrine therapy in a patient with SLE. We are unaware of other cases of such severe disseminated hyperpigmentation induced by this regimen as reported in our case. In addition, our patient had no history of ecchymoses or anticoagulant therapy. Our case also presents a rare staining pattern, with a positive stain for melanin and a negative stain for iron. To our knowledge, this is the second time that this pattern has ever been reported. Our results support the ongoing argument that HQ can bind to melanin. Additionally, the negative Perl's stain underscores that iron may not be a primary factor for this drug-induced hyperpigmentation.

## Conflict of Interest

None.

## Funding

NA.

## Study Approval

The author(s) confirm that any aspect of the work covered in this manuscript that has involved human patients has been conducted with the ethical approval of all relevant bodies.

## References

- Bahloul E, Jallouli M, Garbaa S, Marzouk S, Masmoud A, Turki H, et al. Hydroxychloroquine-induced hyperpigmentation in systemic diseases: prevalence, clinical features and risk factors: a cross-sectional study of 41 cases. *Lupus* 2017;26(12):1304–8.
- Cho EB, Kim BC, Park EJ, Kwon IH, Cho HJ, Kim KH, et al. Hydroxychloroquine-induced hyperpigmentation. *J Dermatol* 2012;39:859–60.
- Coulombe J, Boccara O. Hydroxychloroquine-related skin discoloration. *CMAJ* 2017;189(5):E212.
- de Melo Filho MR, da Silva CAD, da Rocha DM, de Oliveira Pires MB, Pêgo SP, de Freitas EM. Palate hyperpigmentation caused by prolonged use of the antimalarial chloroquine. *Head Neck Pathol* 2012;6:48.
- Gallo CB, Luiz AC, Ferrazzo KL, Migliari DA, Sugaya NN. Drug-induced pigmentation of hard palate and skin due to chronic chloroquine therapy: report of two cases. *Clin Exp Dermatol* 2009;34(7):e266–7.
- Jallouli M, Francès C, Piette J, Huong du LT, Moguelet P, Factor C, et al. Hydroxychloroquine-induced pigmentation in patients with systemic lupus erythematosus: a case-control study. *JAMA Dermatol* 2013;149(8):935–40.
- Mir A, Boyd KP, Meehan SA, McLellan B. Hydroxychloroquine-induced hyperpigmentation. *Dermatol Online J* 2013;19:12.
- Mittal L, Werth VP. The quinacrine experience in a population of cutaneous lupus erythematosus and dermatomyositis patients. *J Am Acad Dermatol* 2017;77(2):374–7.
- Morrison LK, Nordlund JJ, Heffernan MP. Persistent cutaneous hyperpigmentation due to hydroxychloroquinone one year after therapy discontinuation. *Dermatol Online J* 2009;15(12).
- Puri PK, Lountzis NI, Tyler W, Ferringer T. Hydroxychloroquine-induced hyperpigmentation: the staining pattern. *J Cutan Pathol* 2008;35:1134–7.
- Rood MJ, Vermeer MH, Huizinga TWJ. Hyperpigmentation of the skin due to hydroxychloroquine. *Scand J Rheumatol* 2008;37(2):158.
- Sawalha AH. Hydroxychloroquine-induced hyperpigmentation of the skin. *J Rheumatol* 2015;42(1):135–6.
- Shee JC. Lupus erythematosus treated with chloroquine. *Lancet* 1953;265(6778):201–2.
- Shippey EA, Wagler VD, Collamer AN. Hydroxychloroquine: an old drug with new relevance. *Cleve Clin J Med* 2018;85(6):459–67.
- Skare T, Ribeiro CF, Souza FHM, Haendchen L, Jordão JM. Antimalarial cutaneous side effects: a study in 209 users. *Cutan Ocul Toxicol* 2011;30(1):45–9.
- Tuffanelli D, Abraham RK, Dubois EI. Pigmentation from antimalarial therapy: its possible relationship to the ocular lesions. *Arch Dermatol* 1963;88(4):419–26.