

Diffuse Hepatic Hemangiomas without Extrahepatic Involvement in an Adult Patient

Eun Hui Kim, MD
Soo Youn Park, MD
Yon Kwon Ihn, MD
Seong Su Hwang, MD

We report an extremely rare case of a diffuse hepatic hemangiomas without extrahepatic involvement in an adult. The imaging findings of this tumor were similar to those of a hepatic hemangioma and included contrast enhancement with a centripetal filling pattern of the entire hepatic tumor on the delayed phase of a dynamic CT and inhomogeneous diffuse uptake of the entire tumor on blood-pool images obtained five hours later on a ^{99m}Tc-labeled red blood cell scan. Despite its rarity, diffuse hepatic hemangiomas can be suggested in adult patients with diffusely involved hepatic tumors showing the radiological findings of a hepatic hemangioma.

Index terms:

Hemangioma, cavernous
Liver Neoplasms

DOI:10.3348/kjr.2008.9.6.559

Korean J Radiol 2008;9: 559-562

Received April 4, 2008; accepted after revision June 4, 2008.

All authors: Department of Radiology, St. Vincent's Hospital, College of Medicine, The Catholic University of Korea, Gyeonggi-do 442-023, Korea

Address reprint requests to:

Seong Su Hwang, MD, Department of Radiology, St. Vincent's Hospital, College of Medicine, The Catholic University of Korea, 93-1 Chi-dong, Paldal-gu, Suwon, Gyeonggi-do 442-023, Korea.
Tel. (8231) 249-7486
Fax. (8231) 247-5713
e-mail: sshwang7@catholic.ac.kr

Diffuse hepatic hemangiomas usually occurs in neonates with an abdominal mass and unidentified congestive heart failure. Further, diffuse hepatic hemangiomas is characterized by hemangiomas of the skin and involvement of at least two visceral organs (1). However, an adult case of hepatic hemangiomas, especially in its isolated form, is extremely rare. To the best of our knowledge, no cases which are similar to our patient, and includes the involvement of the entire liver were described in the literature. We report a case of a pathologically proven diffuse hepatic hemangiomas without an extrahepatic lesion in an adult. Our diagnosis was confirmed by an ultrasound-guided biopsy.

CASE REPORT

A 33-year-old woman was admitted to our hospital with a two-month history of abdominal distension and edema. The patient had no prior history of drug usage, including oral contraceptives, and no relevant family medical history. Upon admission, the patient underwent a physical examination, which revealed diffuse hepatomegaly, pitting edema in both legs, however no abnormal cardiac murmur. The laboratory findings indicated abnormalities including a hemoglobin level of 7.5 g/dL, a platelet count of 18,000/mm³, as well as a slightly elevated serum alanine aminotransferase (50 U/I) and aspartate aminotransferase (56 U/I). Moreover, the hepatitis B virus antigen was negative, and the titer of the hepatitis B virus antibody and alpha-fetoprotein were normal. The clinical and radiological evaluation showed no evidence of Rendu-Osler-Weber disease or hemangiomas in the extrahepatic region.

An ultrasonography revealed a diffuse heterogeneous echogenic infiltrative mass containing numerous and various-sized hypoechoic nodules involving the entire liver (Fig. 1A). A Doppler ultrasonography revealed no remarkable tumor vascularities except for the underlying hepatic parenchymal vascular flow (Fig. 1B). A hepatic dynamic CT was performed and demonstrated the multifocal enhancing hepatic

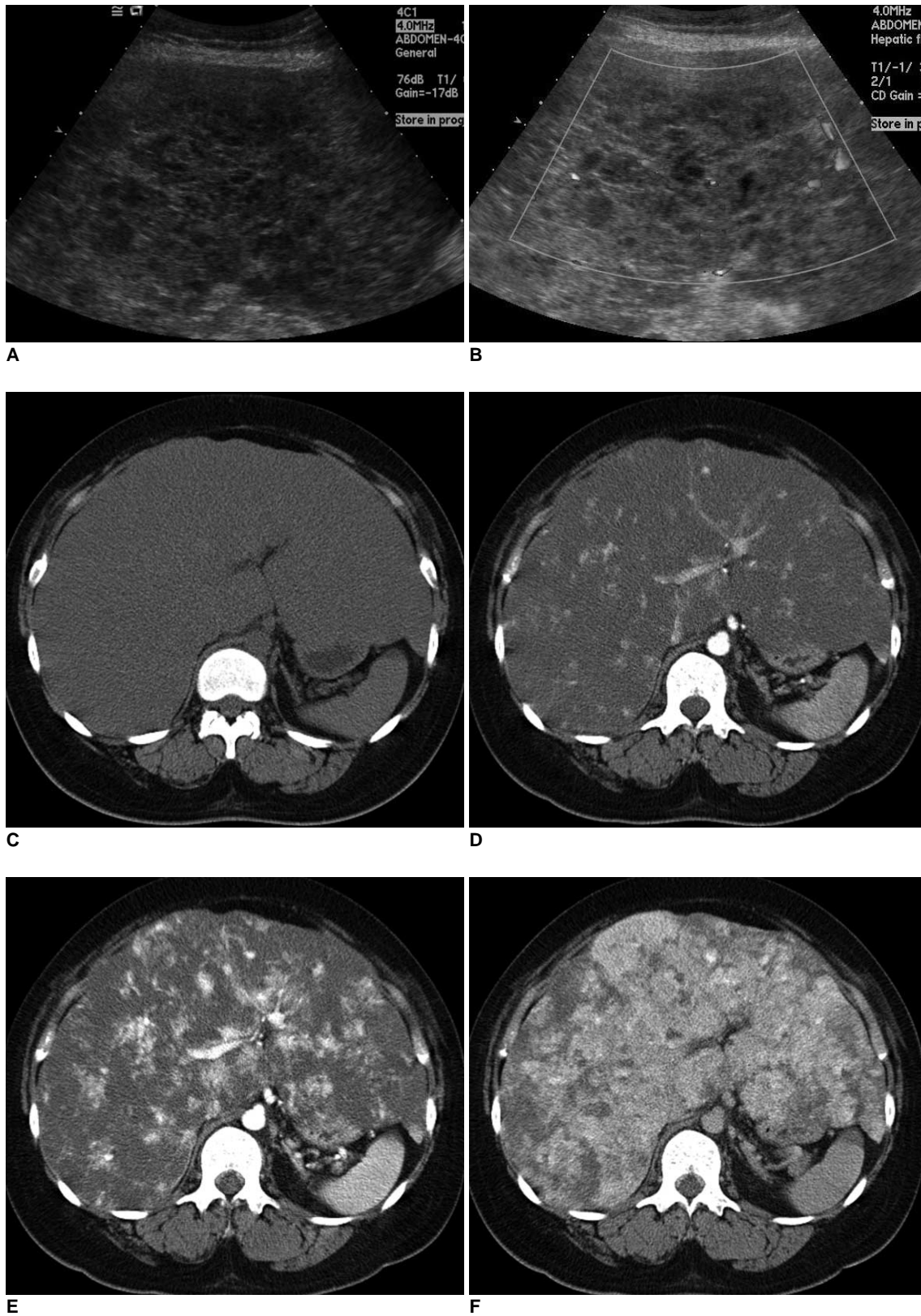


Fig. 1. Diffuse hepatic hemangiomatosis in 33-year-old woman.
A. Ultrasonography indicates heterogeneous infiltrative hepatic tumor containing various-sized hypoechoic nodules.
B. No remarkable tumor vascularity is observed, except for hepatic parenchymal vessels.
C-F. Dynamic CT demonstrates early nodular contrast enhancement on arterial (**D**) and gradual centripetal pattern of contrast enhancement in diffuse infiltrating hepatic mass on portal (**E**) and delayed (**F**) phases. Neither intratumoral calcifications nor area of normal-appearing intervening hepatic parenchymal vessels are visible.

Diffuse Hepatic Hemangiomas without Extrahepatic Involvement

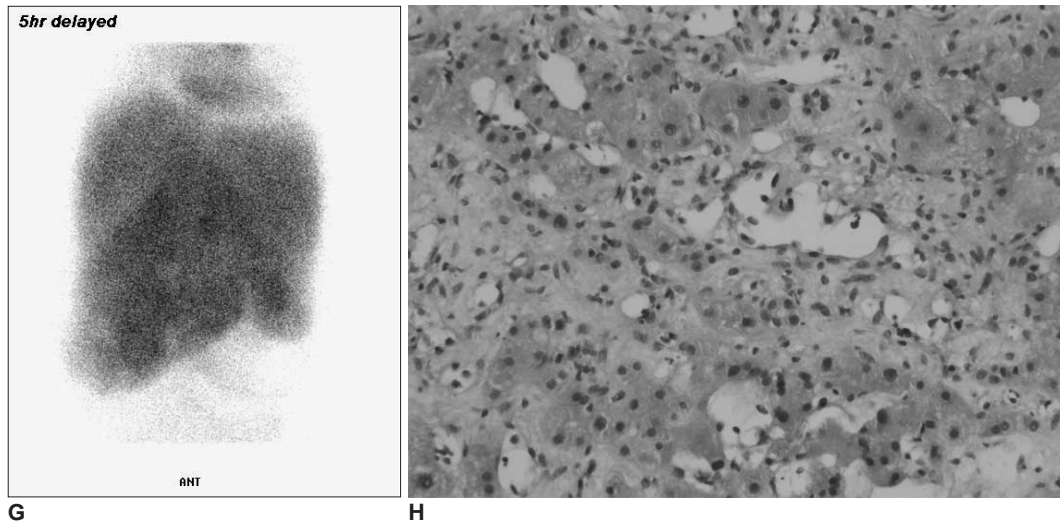


Fig. 1. Diffuse hepatic hemangiomas in 33-year-old woman.

G. ^{99m}Tc -labeled red blood cell scan reveals heterogeneous uptake of radiopharmaceuticals throughout hepatic mass, involving whole liver on blood pool images. Diffuse tumor uptake is still noted on delayed scan obtained five hours later.

H. Histological findings reveal endothelial cell proliferation and dilated blood channels (Hematoxylin & Eosin staining, $\times 200$).

nodules on both the arterial and portal phases, as well as an increased area of contrast enhancement with a centripetal filling pattern of nearly the entire hepatic tumor on a delayed phase CT (Fig. 1C–F). In addition, areas of capsular retraction were also noted. However, there was no remarkable tumor calcification or intervening normal hepatic parenchyma in either of the hepatic lobes. No intraabdominal metastasis or lymphadenopathy was observed. Subsequently, a ^{99m}Tc -labeled red blood cell scan was performed and the blood pool images were taken at five hours after inhomogeneous diffuse activity in the entire hepatic mass (Fig. 1G). However, no extrahepatic mass with abnormally increased radioactivity was observed on this ^{99m}Tc -labeled red blood cell scan. Our differential diagnoses included a diffuse hemangiomas, epithelioid hemangioendothelioma, and angiosarcoma. To rule out a hepatic angiosarcoma, an ultrasound-guided automated gun biopsy, using an 18-gauge core needle was performed in the right hepatic lobe. Before the biopsy, the patient's platelet count was $170,000/\text{mm}^3$ after infusion of fresh frozen plasma. No complications, including intrahepatic or intraperitoneal hemorrhage, were encountered following the biopsy. The patient's histology revealed prominent cavernous vascular proliferation and fibrosis without angiosarcomatous components (Fig. 1H). Further, the patient showed no hemangiomas in other regions of the body, including the skin. Hence, a final diagnosis of isolated diffuse hepatic hemangiomas was established. The patient continued to complain about continuous abdominal distension, which rapidly progressed to the deterioration of hepatic function. Ten days following

admission, the patient expired due to hepatic failure.

DISCUSSION

A hemangioma is the most common benign tumor affecting the liver. It occurs in all age groups, although hepatic hemangiomas occur predominantly in infants and may cause life threatening conditions (1). However, diffuse hepatic hemangiomas in adults is very rarely encountered and more so when observed without any other organ involvement (2–4). Although several cases of long-term adult survival of diffuse neonatal hemangiomas have been reported (5, 6), the etiology and natural history of diffuse hepatic hemangiomas remains unclear.

The histological characteristics of hemangiomas includes the presence of large vascular channels in both the normal-appearing hepatic parenchyma and the cavernous tumor region (2). The histological findings of our ultrasound-guided biopsy specimen revealed prominently increased vascular proliferation and fibrosis with no sarcomatous change on staining (Fig. 1H), as well as vascular endothelial cells showing positive staining on immunochemical stains, which included Masson's trichrome stain and the Gomori reticulin stain.

As no reliable clinical or radiological findings have been reported for the differential diagnosis of hepatic hemangiomas from rare primary vascular hepatic tumors such as hepatic hemangioendothelioma or angiosarcoma, the diagnosis relies solely on the histological findings (7). Also, because it is so rare, only a few reports document the imaging findings of diffuse hepatic hemangiomas.

However, these imaging findings are similar to those of other common hepatic hemangiomas, including variable echoic lesions on the ultrasound, vascular pooling of contrast material within the tumor on angiography, a centripetal enhancement pattern on dynamic enhancement studies, and bright tumor signal intensities on T2-weighted MR images (2, 3, 8). In our patient, the ultrasonography findings included a heterogeneous echoic infiltrative hepatic mass containing numerous hypoechoic nodules. Compared to the histological findings, the heterogeneous infiltrative echotexture may be caused by hemangiomas and parenchymal fibrosis. Our case showed a delayed centripetal contrast-enhancement pattern of the tumor on a dynamic CT and diffuse uptake on vascular pooling images from a ^{99m}Tc -labeled red blood cell scan. Because our case revealed imaging findings similar to hepatic hemangiomas, epithelioid hemangioendotheliomas, and angiosarcomas, diffuse hepatic hemangiomas should be considered in the differential diagnoses (7, 9).

Patients with diffuse hemangiomas showed symptoms of abdominal pain and a palpable abdominal mass. The natural history and underlying etiology of diffuse hepatic hemangiomas is uncertain. Although previous reports have cited the role of steroid medications in the development of hepatic cavernous hemangiomas (10) and the administration of metoclopramide medications in a patient with diffuse hepatic hemangiomas (8), no history of steroid or estrogen use was documented in the reported cases of diffuse hepatic hemangiomas, including our patient. The prognosis of diffuse hepatic hemangiomas without extrahepatic involvement is still unclear because it occurs so rarely and has variable clinical courses in affected patients. In the literature, various prognoses have been reported for diffuse hepatic hemangiomas without extrahepatic lesion in adults (2, 3, 8, 11). In our patient, hepatic function rapidly deteriorated following admission. The cause of the hepatic failure and the patient's death remains unclear. The possibility exists that a minimal amount of the remaining normal

hepatic parenchyma with extensive hepatic hemangiomas involving the entire liver may have caused hepatic failure and subsequent patient death. More cases of diffuse hepatic hemangiomas are needed to establish their natural course and prognosis.

Despite its rarity, we concluded that the diagnosis of diffuse hepatic hemangiomas in adults can be suggested in patients with a diffusely involved hepatic tumor showing radiologic findings of hepatic hemangioma.

References

1. Lopriore E, Markhorst DG. Diffuse neonatal haemangiomas: new views on diagnostic criteria and prognosis. *Acta Paediatr* 1999;88:93-97
2. Lehmann FS, Beglinger C, Schnabel K, Terracciano L. Progressive development of diffuse liver hemangiomas. *J Hepatol* 1999;30:951-954
3. Moon WS, Yu HC, Lee JM, Kang MJ. Diffuse hepatic hemangiomas in an adult. *J Korean Med Sci* 2000;15:471-474
4. Langner C, Thonhofer R, Hegenbarth K, Trauner M. Diffuse hemangiomas of the liver and spleen in an adult. *Pathologe* 2001;22:424-428
5. Latifi HR, Siegel MJ. Diffuse neonatal hemangiomas: CT findings in an adult. *J Comput Assist Tomogr* 1992;16:971-973
6. Ohnishi S, Miyagishima T, Nakagawa M, Kamata T, Kishimoto A, Choi GH, et al. Diffuse neonatal hemangiomas without cutaneous lesions in an adult—a case report. *Angiology* 2002;53:235-237
7. Bishop PR, Nowicki MJ, Parker PH. Radiological case of the month. Hepatic hemangiomas. *Arch Pediatr Adolesc Med* 2000;154:743-744
8. Feurle GE. Arteriovenous shunting and cholestasis in hepatic hemangiomas associated with metoclopramide. *Gastroenterology* 1990;99:258-262
9. Buetow PC, Buck JL, Ros PR, Goodman ZD. Malignant vascular tumors of the liver: radiologic-pathologic correlation. *Radiographics* 1994;14:153-166
10. Conter RL, Longmire WP Jr. Recurrent hepatic hemangiomas. Possible association with estrogen therapy. *Ann Surg* 1988;207:115-119
11. Frangides C, Kounis NG, Papadaki PJ, Goudevenos J, Zabras GM. Diffuse hepatic hemangiomas in the elderly. *Br J Clin Pract* 1995;49:215-216