




ELSEVIER

Contents lists available at ScienceDirect

Urology Case Reports

journal homepage: www.elsevier.com/locate/eucr

Trauma and reconstruction

Phalloplasty and urethroplasty in adult with disorder of sex developments

Kuncoro Adi^a, Safendra Siregar^a, Rani Septrina^b, Zola Wijayanti^{a,*}^a Urology Department, Hasan Sadikin Hospital, University of Padjadjaran Bandung, Indonesia^b Plastic Surgery Department, Hasan Sadikin Hospital, University of Padjadjaran Bandung, Indonesia

ARTICLE INFO

Keywords:

Phalloplasty
Urethroplasty
Radial fore arm free flap
Sex reassignment

ABSTRACT

This case report presents our experience on the first phalloplasty and urethroplasty in adult with Development Sex Disorder (DSD) in Indonesia. A 25 years old male with DSD 46 XY planned undergo phalloplasty and urethroplasty with radial forearm free flap (RFFF). Eight months later, there was fistulas repairment due to urethrocutaneous fistulas. Cartilage insertion also was done to make a semi-rigid neophallus. At last, there was no new fistula or stricture developed. Qmax and Qmean were 33,8 ml/s and 14,0ml/s. RFFF only causes minimal complication. The neophallus and neourethra also function properly.

Introduction

Disorder of sex developments are defined as congenital conditions associated with atypical development of chromosomal, gonadal, or anatomical sex. Conflict in psychosexual development is the most common problem found in DSD, so that etiology of DSD should be confirmed and a management should be planned.

Phalloplasty is one of sexual reassignment management. Neophallus is constructed from a flap. The most frequent technique is radial forearm free flap (RFFF). It is considered as the gold-standard technique for penile reconstruction, because of the thin pliable forearm skin, reliable vascularization pattern and easy re-sensibilization.¹ Due to its complicated process, it takes several stages of surgery. Urethroplasty also should be perform to make patient able to voiding while standing. The aim of surgery is to make ambiguous external genitalia compatible with assigned gender, preventing urinary obstruction or infections, preserving sexual and reproductive potentials, and maximizing anatomy to enhance sexual function.¹

In this article, we aimed to report our experience on the first phalloplasty and urethroplasty in adult with disorder of sex development in Indonesia.

Case presentation

Mr. F, 25 years old, he diagnosed as developmental sex disorder 46XY. He planned to undergo phalloplasty to make a neophallus. To be able to voiding while normal standing, radial forearm free flap (RFFF) technique was used (Fig. 1). The plan was making tube within tube flap. An incision was made in left groin to made a “tunnel” for flap

revascularization. The “inner tube” was intended as new urethra. Anastomotic urethroplasty was done to communicate urethra and neourethra. This was a joined surgery between Urology department and Plastic Surgery department.

Eight months after first surgery, urethrocutaneous fistulas developed (Fig. 2). Patient underwent surgery to urethroscopy and fistulas repairment. Fistula found in 1cm distal from urethra-neourethra junction (5mm in diameter) and 3cm distal from urethra-neourethra junction (1mm in diameter). Second stage reconstruction also done by plastic surgery department. A cartilage graft from rib inserted in neophallus. It had to be done which in addition to permanently keeping the phallus in a semi-rigid state (Fig. 3).

To evaluate any complication after fistulas repair, urethrocystoscopy was done in the next month. During urethrocystoscopy, it found that there was no new fistula developed. Bladder and prostate were also normal. A test with uroflowmeter was taken to check urine flow. Volume for urine flow was 367ml. It flow time was 26,3 seconds. Qmax and Qmean were 33,8 ml/s and 14 ml/s. The total time was 38,3 seconds.

Discussion

Phalloplasty is a challenging and a mysterious operation that has several indications. In phalloplasty, we construct neophallus with other structure. It is indicated for patient gender reassignment, post penile amputation, micropenis, epispadias, and hypospadias. There are some main goals that has to be achieved after phalloplasty, which was competent neo-urethra to allow for voiding while standing. There should be a good innervation showed by the return of both tactile

* Corresponding author. Jl. Setra Murni Tengah 4 No. 36B, Sukarasa, Sukasari, Bandung, Indonesia.

E-mail address: zola.wijayanti@gmail.com (Z. Wijayanti).

<https://doi.org/10.1016/j.eucr.2019.100930>

Received 19 April 2019; Accepted 29 May 2019

Available online 31 May 2019

2214-4420/© 2019 The Authors. Published by Elsevier Inc. This is an open access article under the CC BY-NC-ND license

(<http://creativecommons.org/licenses/by-nc-nd/4.0/>).

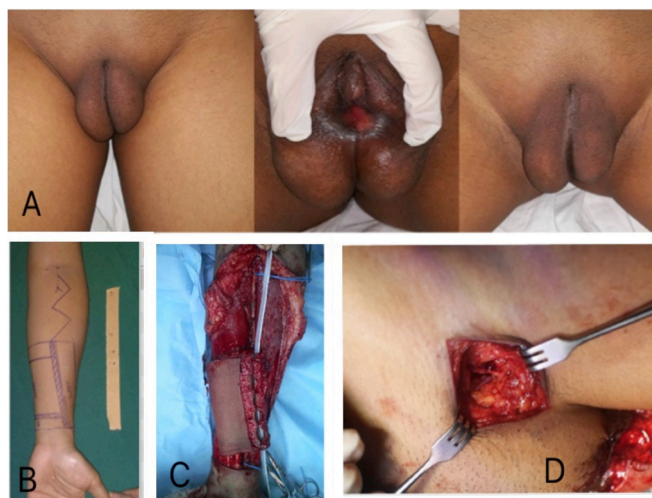


Fig. 1. A. A 25 years old patient with Disorder of Sex Developments (DSD) 46XY. Patient has scrotum but only small size of penis; B. Patient's forearm had been marked to made radial forearm free flap (RFFF); C. Radial Forearm Free Flap; D. Incision in inguinal area for "Tunnel" of innervation and vascularization.

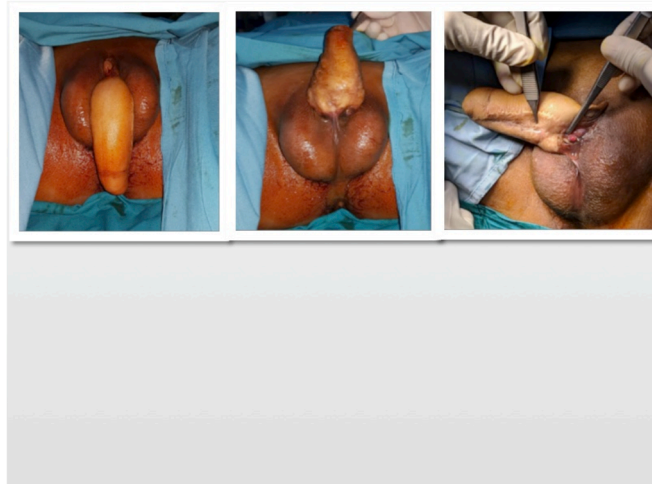

Fig. 2. Urethrocutaneous fistula was developed in ventral area.

erogenous sensibility, and aesthetically acceptable to the patient.²

Over years, many different techniques have been used to reconstruct the penis in order to achieve those goals above. Random pattern flaps, pedicled flaps, free flaps would be used for phalloplasty operations.² There are so many complications may affect after phalloplasty. It such as flap failure, urethral stricture, urethral fistula, and stiffener-related complication. Nowadays, flap failure is uncommon. But total flap loss may arise as result of neglected urethral fistulae, infection, or thrombosis of pedicle. The radial forearm, lateral arm and the Latissimus dorsi flap have the highest reported rates of survival among the most commonly performed free flaps.³

Urethral complications are common after phalloplasty and may prevent the patient from standing micturition. Urethral stricture and urethral fistula are examples of urethral complications. The overall urethral complication rate for radial forearm free flap phalloplasty was 31.5%. It was better than anterolateral thigh pedicled flap phalloplasty, 32,8%.⁴ Urethra fistula in RFFF phalloplasty has reported rates ranging from 22 to 68%.³ Stricture locations include the meatus, phallic urethra, anastomosis (most common), fixed part and multiple sites. Fistulas are more common where the urethral anastomosis is located more proximally.⁴ Persistently high rates of urethral fistulas and strictures are related to multiple factors. Firstly, the urethral segment of the flap may be lying away from the pedicle thus being relatively less vascularized. Secondly, the length of the urethral segment may be limited due to the overall dimensions of the flap and thus may be inadequate for tension free urethral anastomosis. Lastly, as most of these flaps are from the hair-bearing parts of body, hair growth within the urethra soon causes obstruction to the urinary flow with its resultant complications.⁴ In our patient, those two fistulas developed in area of native urethra-neourethra junction. There was no sign of infection found before fistula developed.

Complication post insertion the stiffener also common. Stiffener is needed to maintain its consistency in semi-rigid state. There are sorts of stiffener that can be chose, autologous (rib cartilage) or prosthesis. Nearly, 30% of neophalluses inserted with implants have implant related complications, mostly in the form of infection or device failure, leading to high implant removal rates.⁵ An autologous stiffener also may cause infection, resorption, fracture, and even extrusion. In our patient, there is no any stiffener related complication. Patient can even erect normally.

As mentioned before, one of goal of phalloplasty and urethroplasty is able to voiding normally while standing. Normally for 16–50 years old male Qmax is 22.5 ± 9.2 ml/s. Then, normal range for Qmean is

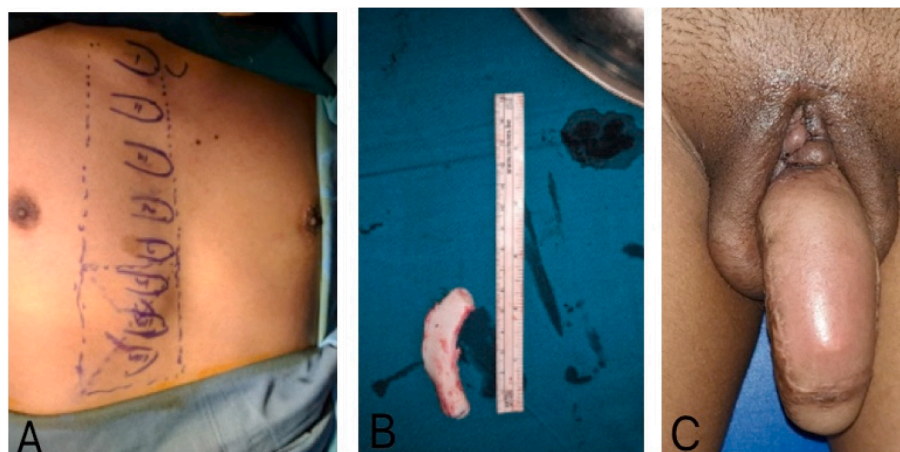


Fig. 3. A. Patient's chest was marked to mark cartilage from rib; B. Cartilage from rib was taken and inserted to penile shaft for made a semi-rigid state C. Semi rigid phallus.

13.05 ± 6.12 ml/s. Our patient underwent uroflowmetry for voiding evaluation. Results showed volume 367ml, flow time 26,3 seconds, Qmax 33,8 ml/s, Qmean 14 ml/s, and total time 38,3 seconds. It showed good results.

Conclusion

Phalloplasty and urethroplasty may become a solution for patients with Disorder of Sex Developments (DSD). Many techniques have arisen, one of them with RFFF. As seen in our patient, this technique only causes minimal complication. The neophallus and neourethra also function properly. It can erect and void normally.

Source of support

None.

References

1. Godbole, Koyle, Wilcox. *Pediatric Urology: Surgical Complications and Management*. Wiley; 2015.
2. Sarikaya S, Ralph DJ. Mystery and realities of phalloplasty: a systematic review. *Turk J Urol*. 2017 Sep;43(3):229–236.
3. Doomaert M, Hoebeke P, Ceulemans P, T'Sjoen G, Monstrey S. Penile reconstruction with the radial forearm flap: an update. *Handchir Mikrochir Plast Chir*. 2011 Aug;43(4):208–214.
4. Ascha M, Massie JP, Morrison SD, Crane CN, Chen ML. Outcomes of single stage phalloplasty by pedicled anterolateral thigh flap versus radial forearm free flap in gender confirming surgery. *J Urol*. 2018 Jan;199(1):206–214.
5. Garaffa, Christopher. *Ralph. Phallic Reconstruction Following Penile Cancer Surgery. Textbook of Penile Cancer*. Springer; 2016:279–293.