

Exceptional Case

Influenza virus vaccination and kidney graft rejection: causality or coincidence

Anne Sophie Lind Fischer¹, Bjarne Kuno Møller², Søren Krag³ and Bente Jespersen¹

¹Department of Nephrology, Aarhus University Hospital, Skejby, Århus N DK-8200, Denmark, ²Department of Clinical Immunology, Aarhus University Hospital, Skejby, Aarhus N DK-8200, Denmark and ³Department of Pathology, Aarhus University Hospital, Aarhus N DK-8200, Denmark

Correspondence to: Anne Sophie Lind Fischer; E-mail: aslf@dadlnet.dk

Abstract

Influenza can cause significant morbidity and mortality in renal transplant recipients especially with a high rate of lower respiratory disease. Annual influenza vaccination is therefore recommended to renal transplant recipients.

We report the first three cases of acute kidney injury in renal transplant recipients following influenza vaccination that all led to graft loss. They all had different native diseases and were all vaccinated in the same season of 2009–10. The time span from vaccination to decline of kidney function is shorter than the time to diagnosis since the three patients only had blood tests every 3 months or when symptoms became severe.

These reports do not justify a change of current recommendations regarding influenza vaccination in renal transplant recipients, but they support the continued attention and registration of vaccinations to monitor side effects.

Keywords: acute kidney injury; influenza vaccination; kidney graft rejection; renal transplant recipient

Introduction

Influenza virus can cause significant morbidity and mortality in renal transplant recipients, particularly due to lower respiratory disease. Annual influenza vaccination is therefore recommended for solid organ transplant recipients [1] as for patients with other chronic illness [2]. The vaccine has been shown to be safe and is generally well tolerated in both adults and paediatric recipients [3]. Side effects such as local reactions, fever and fatigue are well known. However, cases of rhabdomyolysis [4, 5], nephrotic syndrome [6] and neurologic complications [7–10] have also been reported. Only a single case report describes adverse effects in a renal transplant recipient. This patient developed Henoch–Schönlein purpura with glomerular involvement following influenza vaccination [11].

Non-specific activation of the immune system might be of significance, and we therefore report the first three cases of acute kidney injury (AKI) in renal transplant recipients after influenza vaccination that all led to graft loss.

Case 1

A 43-year-old Caucasian female was evaluated for AKI in January 2010, 58 days after annual seasonal influenza vaccination. She had received a second living-related

donor renal transplant in 2000 (HLA-A, B, DR mismatch 1-2-0) and afterwards had stable kidney function with plasma creatinine at 129 µmol/L and urine albumin 0.418 g/L (14 August 2009). Her native renal disease was extra-capillary glomerulonephritis. Her past medical history was comprised of hypertension, arthritis urica and an undefined connective tissue disease. She received immunosuppressive therapy with prednisolone 2.5 mg once daily, mycophenolate mofetil 250 mg twice daily and tacrolimus 2 mg once daily.

Symptoms started right after the vaccination, and at admission, she complained of flu-like symptoms, shortness of breath, swelling of her face and lower limbs, joint pain in her right ankle and was found to have an elevated plasma creatinine of 227 µmol/L. Urine protein was 1.58 g/L. Ultrasound showed no urinary obstruction, and there were no signs of infection. Renal biopsy revealed signs of both acute and chronic humoral rejection with peritubular capillaritis and positive C4d staining as well as signs of transplant glomerulopathy (Figure 1). Flow cytometric crossmatching was positive. She was treated with intravenous (IV) high-dose methylprednisolone 500 mg daily for 3 days, 7 days of plasmapheresis, IV immunoglobulin and two courses of 750 mg rituximab, but neither had effect on graft function.

Plasma creatinine increased over the next 2 weeks to 249 µmol/L, and the immunosuppressive treatment was intensified with a higher dose of mycophenolate mofetil. From September 2011, haemodialysis was prescribed.

Case 2

A 60-year-old Caucasian female received her annual influenza vaccination in November 2009, and 53 days later, in January 2010, she was hospitalized for evaluation of acute renal graft failure.

In September 2008, she received a living-related donor renal transplant (HLA-A, B, DR mismatch 1-2-1) and afterwards had stable kidney function with a plasma creatinine level of 90 $\mu\text{mol/L}$ and without detectable albuminuria (20 October 2009). Her native renal disease was unknown. Her hypertension was treated with a calcium channel blocker, and she had a pacemaker due to sinus node dysfunction. She received immunosuppressive treatment with prednisolone 5 mg once daily, mycophenolate mofetil 500 mg twice daily and tacrolimus 3 mg once daily.

At admission, she complained of nausea and swelling of the face and lower limbs, which started after the vaccination. Plasma creatinine was elevated to 250 $\mu\text{mol/L}$. Urine dip stick showed no red blood cells, but 24-h urine collection revealed microalbuminuria of 100 mg (23 January 2010). Medical investigation included polyomavirus, ANCA (MPO and PR3), anti-GBM, ANA, anti-DNA, C3, C4, Ig-screening and CMV antigenemia—all of which were within normal limits.

Ultrasound of the graft did not reveal urinary obstruction, and there were no signs of infection. Renal biopsy showed acute cellular rejection (type IA according to the Banff classification) with severe interstitial oedema, interstitial inflammation (i2) and focal moderate tubulitis (t2). There were no signs of humoral rejection, and C4d staining was negative. Flow cytometric crossmatch was negative.

Treatment with methylprednisolone 500 mg daily was initiated. Despite 4 days of treatment, plasma creatinine

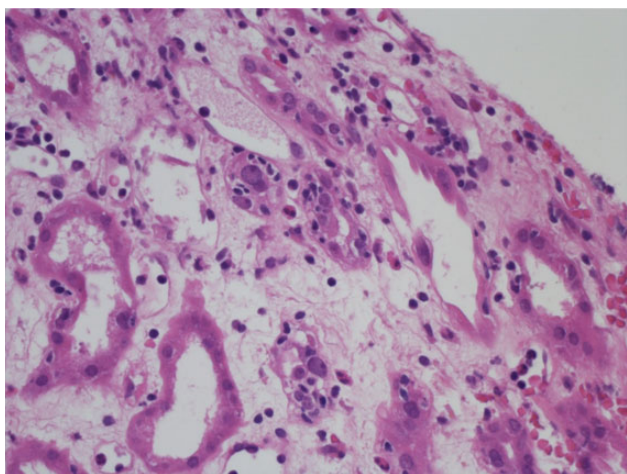


Fig. 1. Kidney biopsy of Case 2.

was still 422 $\mu\text{mol/L}$. Chronic dialysis was initiated in November 2010.

Case 3

A 43-year-old Caucasian male presented to our department in January 2010, 34 days after he received the annual influenza vaccination.

His native renal disease was IgA nephropathy diagnosed in 2002. After 1 year on continuous ambulatory peritoneal dialysis (CAPD), the patient received a living-related donor renal transplant (HLA-A, B, DR mismatch 2-2-1) in 2003 and afterwards had a plasma creatinine level of 126 $\mu\text{mol/L}$ and no detectable albuminuria (2 February 2009). His past medical history comprised of hypertension, which was treated with calcium channel blocker, and no angiotensin-converting enzyme inhibitor due to previous angioedema. Due to cholelithiasis, cholecystectomy had been performed.

He received immunosuppressive treatment with tacrolimus 1 mg daily.

The patient had not been well since the vaccination, and on admission, he presented with complaints of flu-like symptoms, fatigue, weight loss of 3 kg, and back and stomach pain, which had all emerged 2 weeks after vaccination. Antibiotics prescribed by his general practitioner to treat presumed pneumonia had no effect on his clinical condition.

Laboratory findings showed slightly elevated levels of creatinine (132 $\mu\text{mol/L}$), white blood count ($15 \times 10^9/\text{L}$), C-reactive protein (48 mg/L), alkaline phosphatase (150 U/L) and normal levels of bilirubin and amylase.

The patient was discharged in February 2010 as abdominal pain had disappeared. He was followed in the outpatient clinic. Proteinuria was noted at discharge and increased to 5 g/L by November 2010. Over the same period, plasma creatinine increased to 162 $\mu\text{mol/L}$ (8 November 2010). The patient was therefore readmitted.

Biopsy of the graft exhibited a mesangial proliferative glomerulonephritis with a single small extracapillary proliferation and was positive for IgA by immunofluorescence. Electron microscopy confirmed dominant mesangial immune deposits. Interstitial fibrosis was observed. These findings were consistent with relapse of IgA nephropathy.

After further progression, peritoneal dialysis was initiated in January 2013.

Discussion

These were the first reported cases of AKI in renal transplant recipients following influenza vaccination that all led to graft loss. Although we cannot exclude that the onset

Table 1. Comparison of the three cases

	Case 1	Case 2	Case 3
Time from vaccination until hospitalization (days)	58	53	34
Kidney biopsy	Acute and chronic humoral rejection, C4d positive	Acute cellular rejection (Banff-type IA), C4d negative	Recurrent IgA nephropathy, C4d negative
Urine protein prior to vaccination (g/L)	0.418	Undetectable	Undetectable
Urine protein after vaccination (g/L)	0.732 (5 months after admission)	0.2 (2 months after)	4.98 (3½ months after)

of AKI is a coincidence, we would like to point out these three cases with striking association to the vaccinations (Table 1). All patients were vaccinated in the same winter

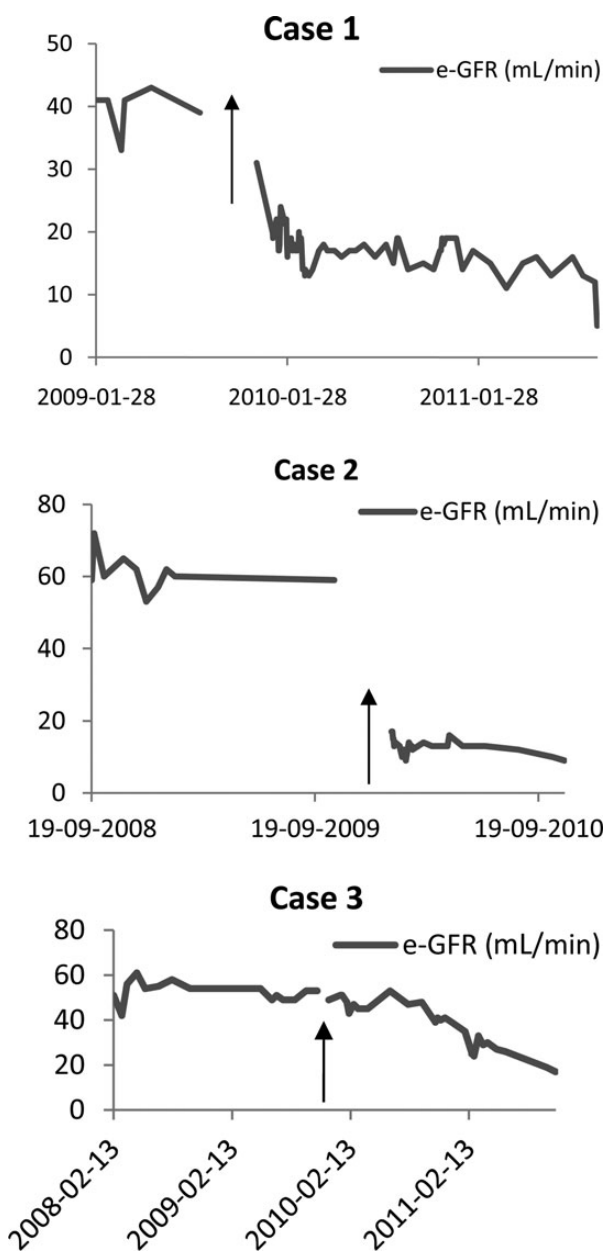


Fig. 2. The three figures show estimated glomerular filtration rate (e-GFR) for the cases over time. The graphs end when dialysis was initiated. The arrow indicates the time of vaccination. e-GFR is estimated using the MDRD study equation [16].

season of 2009–10. They were all diagnosed with different native renal diseases, but the symptoms of renal failure developed after the vaccination, which led to admission 1–2 months after the vaccinations. There were no signs of infection or urinary obstruction in any of the cases. One could suspect that an activation of the immune system led to late rejections and/or relapse of the native renal disease and thus to graft loss. The time span from vaccination to decline of kidney function in our study was shorter than the time to diagnosis since the three patients only had blood tests every 3 months or when symptoms became severe (Figure 2).

The single-antigen beads assay used for detection of the donor-specific anti-DQ7 has a very high sensitivity but a correspondingly lower clinical specificity, and donor-specific antibodies undetectable in flow cytometric cross-matching are usually regarded as less important in clinical risk assessment. Cellular rejection has been evidenced by histological examinations of the kidney, and the absence of C4d deposits might reflect that the anti-DQ7 antibody is not C'-activating. In Case 2, we speculate that the formation of the antibody might either be part of a general immune response involving cellular anti-donor alloreactivity or be eliciting antibody-dependent cellular cytotoxicity, thereby contributing to graft loss.

The use of adjuvants in vaccines is a double-edged sword. The rapid and effective immunization yielding protection from infection by the adaptive immune response is usually mediated by a primary and non-specific activation of the innate immune system. The lack of specificity of adjuvants is constructive in the production of vaccines, since the same adjuvant may be used for several therapeutic vaccines. However, this non-specificity simultaneously increases the likelihood of adverse immune reactions [12]. Immunosuppression in transplanted patients has to outweigh the risk of rejection with risks of infection/cancer, and the delicate balance is likely to be affected by activation of inflammatory pathways of the innate immune system by adjuvants. Since the alloantigens of the graft are available for immune recognition at the time of adjuvant administration, it is likely that effective vaccination may lead to anti-graft responses also (Table 2).

The adjuvant in the 2009 H1N1 vaccine was the oil-based AS03 and enhanced the immune response to inactivated influenza vaccine, thereby reducing the amount of antigen needed per dose [13]. AS03 had been administered successfully to a very large number of healthy individuals, but the applicability in a setting of immunosuppressed, organ-transplanted patients was less well described, though feasibility had been documented [14]. Non-specific immune activation by the vaccine adjuvant (AS03) in the presence of transplanted alloantigens might lower the threshold for alloimmunization and lead to formation of donor-specific antibodies [15].

Table 2. Comparison of grafts and antibodies after vaccination

	Case 1	Case 2	Case 3
HLA mismatch (A-B-DR)	1-2-0	1-2-1	2-2-1
HLA mismatches	A24(9);B7,51(5);C*07,15; DQB1*03:01	A24(9);B60(40),B62(15); DRB1*04; DQB1*03:01	A2,28; B60(40),B62(15); Cw3; DRB1*04; DQB1*03:02
Donor-specific Abs post-Tx, post-vac	Anti-A24,B7,B51	Anti-DQ7	Anti-DR53,DQ8
Flow crossmatch post-Tx, post-vac	Positive	Negative	Not determined

Responses to the AS03-adjuvanted pandemic influenza vaccine in solid organ transplant recipients have previously been described [1]. A total of 96 renal transplant recipients received two doses of the AS03-adjuvanted split A/09/H1N1 influenza vaccine at a 3–4-week interval. Overall graft function did not change. A transient increase of plasma creatinine was experienced by 14% of the kidney recipients. Only one patient showed signs of graft dysfunction and was successfully treated with steroids for acute rejection 8 days after the first dose of the vaccine. After two immunizations, 83.3% of the patients reached seroprotective titres. Our patients only received one vaccination as the routine in Denmark.

On the basis of our observations, we find no need to change current recommendation of influenza vaccination to renal transplant recipients, but our study supports the continued attention and registration of vaccinations and possible side effects.

References

1. Siegrist CA, Ambrosioni J, Bel M et al. Responses of solid organ transplant recipients to the AS03-adjuvanted pandemic influenza vaccine. *Antivir Ther* 2012; 17: 893–903
2. Duchini A, Goss JA, Karpen S et al. Vaccinations for adult solid-organ transplant recipients: current recommendations and protocols. *Clin Microbiol Rev* 2003; 16: 357–364
3. Kumar D, Blumberg EA, Danziger-Isakov L et al. Influenza vaccination in the organ transplant recipient: review and summary recommendations. *Am J Transplant* 2011; 11: 2020–2030
4. Shah SV, Reddy K. Rhabdomyolysis with acute renal failure triggered by the seasonal flu vaccination in a patient taking simvastatin. *BMJ Case Rep* 2010; 2010: doi: 10.1136/bcr.11.2009.2485
5. Raman KS, Chandrasekar T, Reeve RS et al. Influenza vaccine-induced rhabdomyolysis leading to acute renal transplant dysfunction. *Nephrol Dial Transplant* 2006; 21: 530–531
6. Fernandes P, Jorge S, Lopes JA. Relapse of nephrotic syndrome following the use of 2009 pandemic influenza A (H1N1) vaccine. *Am J Kidney Dis* 2010; 56: 185–186
7. Crawford CM, Grazko MB, Raymond WR IV et al. Retrobulbar optic neuritis and live attenuated influenza vaccine. *J Pediatr Ophthalmol Strabismus* 2013; 50: 61
8. Gable KL, Afshari Z, Sufit RL et al. Distal acquired demyelinating symmetric neuropathy after vaccination. *J Clin Neuromuscul Dis* 2013; 14: 117–122
9. Rubinov A, Beiran I, Krasnitz I et al. Bilateral optic neuritis after inactivated influenza vaccination. *Isr Med Assoc J* 2012; 14: 705–707
10. Shaikh MF, Baqai TJ, Tahir H. Acute brachial neuritis following influenza vaccination. *BMJ Case Rep* 2012; 2012: doi: 10.1136/bcr-2012-007673
11. McNally A, McGregor D, Searle M et al. Henoch-Schönlein purpura in a renal transplant recipient with prior IgA nephropathy following influenza vaccination. *Clin Kidney J* 2013; 6: 313
12. Petrovsky N. Vaccine adjuvant safety: the elephant in the room. *Expert Rev Vaccines* 2013; 12: 715–717
13. Jackson LA, Chen WH, Stapleton JT et al. Immunogenicity and safety of varying dosages of a monovalent 2009 H1N1 influenza vaccine given with and without AS03 adjuvant system in healthy adults and older persons. *J Infect Dis* 2012; 206: 811–820
14. Manuel O, Pascual M, Hoschler K et al. Humoral response to the influenza A H1N1/09 monovalent AS03-adjuvanted vaccine in immunocompromised patients. *Clin Infect Dis* 2011; 52: 248
15. Katerinis I, Hadaya K, Duquesnoy R et al. De Novo anti-HLA antibody after pandemic H1N1 and seasonal influenza immunization in kidney transplant recipients. *Am J Transplant* 2011; 11: 1727
16. Matsushita K, Mahmoodi BK, Woodward M et al. Comparison of risk prediction using the CKD-EPI equation and the MDRD study equation for estimated glomerular filtration rate. *JAMA* 2012; 307: 1941–1951

Received for publication: 12.8.14; Accepted in revised form: 9.4.15