

Robotic Adrenalectomy: A 10-Year Clinical Experience at a Tertiary Medical Center

Andrew Francis, MD, Logan Mellert, DO, Neel Parekh, MD, Mark Pozsgay, DO, Adrian Dan, MD

ABSTRACT

Background and Objective: Laparoscopic adrenalectomy is now the preferred approach for most adrenal tumors. As minimally invasive surgery departments gain familiarity with the robotic platform, the safety profiles and efficacy of robotic adrenalectomy has been an area of continued discussion. The objective of this study is to outline our experience with transitioning to the robotic platform and determining the effectiveness and safety of transperitoneal robotic adrenalectomy.

Methods: We performed a single-center, retrospective review of 37 patients who underwent transperitoneal robotic adrenalectomy between August 1, 2010 and August 31, 2020. Outcomes included patient morbidity, hospital length of stay, operative time, estimated blood loss, gland volume, pathology, and postoperative complications.

Results: Sixty-five percent of the total robotic adrenalectomies were of the left adrenal gland. The average operating room time was 213 minutes. The average gland volume was 71 cm³, estimated blood loss was 74 mL and length of stay was 1.4 days. There were no significant differences in outcomes between the right and left total robotic adrenalectomies. Approximately one-third of our cohort had an adrenal cortical adenoma, while only one patient had adrenal cortical carcinoma. Four patients experienced postoperative complications that resulted in unplanned hospital readmissions and there was one mortality.

Conclusions: Although the standard of care for most adrenal tumors is laparoscopic resection, our 10-year

experience has shown that robotic adrenalectomy is highly effective and can be a valuable tool in the community and academic setting.

Key Words: Robotic surgery, Adrenalectomy, Adrenal gland neoplasm.

INTRODUCTION

Over the past two decades, adrenal surgery has progressively evolved alongside advances in surgical technology. As such, there has been a transition from open surgery as the mainstay of surgical management to minimally invasive approaches. Laparoscopic adrenalectomy is now considered the preferred surgical approach for most adrenal pathologies. It is safe and effective when compared to open adrenalectomy.^{1,2} However, like the adoption of the robotic platform across other surgical specialties, there has been a shift to robotic adrenalectomies given its inherent advantages including high-definition three-dimensional visual systems, enhanced degree of flexibility with the capability of 360-degree rotation and improved depth perception, dexterity, and ergonomics. Consequently, robotic surgery may be invaluable as the resection of the adrenal gland requires careful dissection along major vessels and organs as well as fine dissection in limited spaces such as the retroperitoneum.³ The safety profile and feasibility of robotic adrenalectomy has been elucidated in multiple series. Compared to conventional laparoscopic surgery, this technique is associated with decreased blood loss, reduced patient morbidity, and shorter hospital stay.⁴⁻⁷ Over the past decade, minimally invasive surgery (MIS) departments have gained experience and familiarity with the robotic platform and expanded its utilization into adrenal surgery. Therefore, this study aims to determine the effectiveness and safety profile of transperitoneal robotic adrenalectomy in our MIS practice.

METHODOLOGY

1. Study Design

This is a quality improvement study of 37 patients who underwent transperitoneal robotic adrenalectomy (TRA)

Department of General Surgery, Summa Health - Akron City Hospital, Akron, OH. (Dr Francis, Mellert, Pozsgay, and Dan)

Department of Urology, Glickman Urologic and Kidney Institute, Cleveland Clinic Foundation, Cleveland, OH. (Dr. Parekh)

Disclosure: none.

Funding sources: none.

Conflict of interests: none.

Informed consent: Dr. Adrian Dan declares that written informed consent was obtained from the patient/s for publication of this study/report and any accompanying images.

Address correspondence to: Dr. Adrian Dan, 95 Arch Street, Suite 240, Akron, OH, USA, 44304, Telephone: (330)-761-9930, E-mail: dana@summahealth.org.

DOI: 10.4293/JSLs.2021.00083

© 2022 by SLS, Society of Laparoscopic & Robotic Surgeons. Published by the Society of Laparoscopic & Robotic Surgeons.

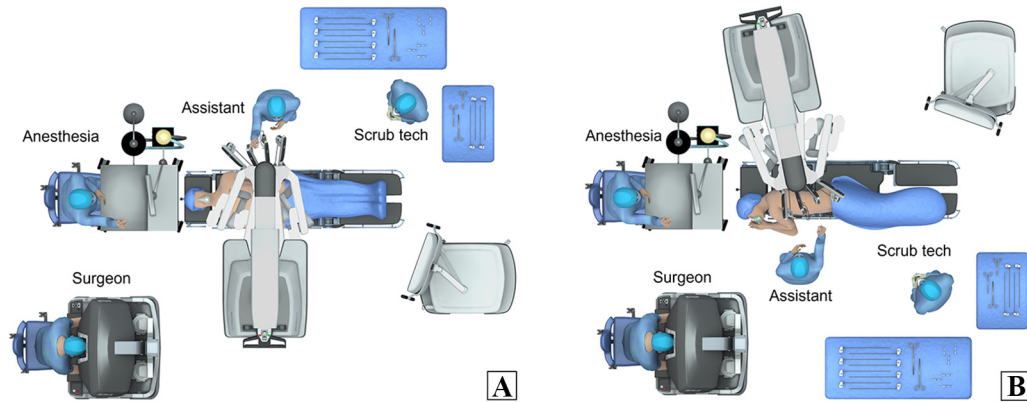


Figure 1. Robotic docking and patient positioning for right (A) and left (B) Transperitoneal Robotic Adrenalectomy.

between August 1, 2010 and August 31, 2020 at a university affiliated, community-based, tertiary care hospital. Robotic adrenalectomy was performed utilizing the DaVinci Si™ and Robotic Xi Surgical System (Intuitive Surgical Sàrl, Aubonne, Switzerland). Indications for TRA included advanced/functional adenomas and concern for malignancy. Data was queried from our electronic medical records (EPIC, Epic Systems Corporation, Verona, Wisconsin) and data compilation was performed by trained, unblinded reviewers in accordance with retrospective review guidelines.⁸ All operations were performed by a single surgeon.

2. Pre-operative Assessment

Indications for TRA included hormone-producing neoplasms of any size (hyperaldosteronism, pheochromocytoma, primary adrenal hypercortisolism, adrenal hypersecretion of estrogens/androgens) and hormone inactive lesions that were greater than or equal to 4 cm. To ensure we selected patients with a low likelihood of malignancy, we excluded patients who displayed locoregional invasion on computed tomography or magnetic resonance

imaging. Perioperative planning included a multidisciplinary team from Surgery, Endocrinology, and Anesthesiology. Pre-operative management of patients with pheochromocytoma was in accordance with The Endocrine Society's *Clinical Practice Guidelines*.⁹

3. Operative Technique

3.1 Robot-Assisted Left Transperitoneal Adrenalectomy

Patients were placed in the right lateral decubitus position and the operating table was flexed to optimize exposure of the left retroperitoneum. The patient was secured to the surgical table and a shoulder roll was placed. All pressure points were padded with foam to avoid injury. The robot was docked (Figure 1a) and four trocars were placed (Figure 2a). Following entry, the lateral attachments of the spleen were mobilized from the anterior abdominal wall. The peritoneum was then incised allowing access to the retroperitoneum and a medial rotation of the spleen and pancreas was achieved to the level of the falciform ligament. The splenic vein was identified and preserved. In our

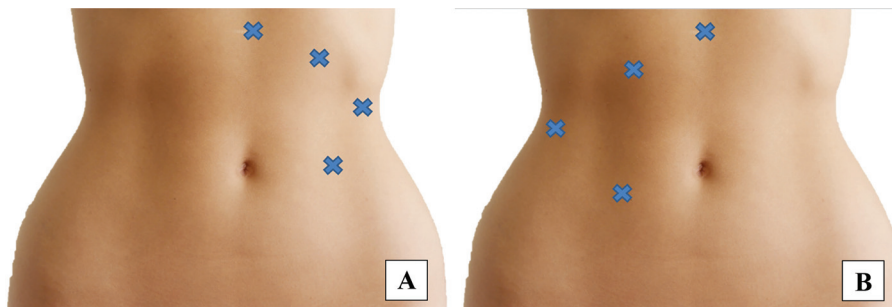


Figure 2. Trocar placement in right (A) and left (B) Transperitoneal Robotic Adrenalectomy.

practice, we exposed the left crus of the diaphragm and the greater curvature of the stomach as we believe it improves visualization. The left renal vein was then identified within the hilum of the kidney followed by the identification of Gerota's fascia. The perinephric fat was dissected revealing the left adrenal gland and accessory adrenal veins. These are carefully dissected, clipped, and divided. The remainder of the gland was dissected free from the kidney (posteriorly and inferiorly), the aorta (medially) and the diaphragmatic attachments near the left crus (Figures 3a, 3b). The gland was placed in a laparoscopic specimen bag and removed. Following completion of the procedure, hemostasis was confirmed, the robot was undocked, trocars removed, and port sites closed.

3.2 Robot-Assisted Right Transperitoneal Adrenalectomy

The patient was placed in the supine position with a roll to bump the right upper abdomen. The robot was docked (Figure 1b) and trocars were placed (Figure 2b). A liver retractor was used to elevate the liver and expose the upper abdominal peritoneum cephalad to the hepatic flexure. This was incised, providing access to the retroperitoneum. Gerota's fascia was reflected medially and the right kidney and adrenal were exposed. The medial

aspect of the gland was first dissected free, defining the cephalad plane between the gland and inferior vena cava. The right adrenal vein was skeletonized, clipped, and divided. The remaining attachments were dissected using a combination of ultrasonic shears and electrocautery, detaching the gland from the kidney (inferior posterior) and the liver and diaphragm (superior). During this dissection, the hepatic veins and vena cava were identified and protected to avoid unintentional injury. The gland was then placed in a laparoscopic specimen bag and removed. Following completion of the procedure, hemostasis was confirmed, the robot was undocked, trocars removed, and port sites closed.

4. Data Collection

Demographic data such as sex, body mass index (BMI), Charleston comorbidity index (CCI), and presence of previous abdominal surgery were collected. Outcomes included mortality, operative time (time from incision to completion of closure), estimated blood loss (EBL), length of stay (LOS), gland volume, gland pathology, and Clavien-Dindo classification¹⁰ of postoperative complications within 30 days of the procedure.

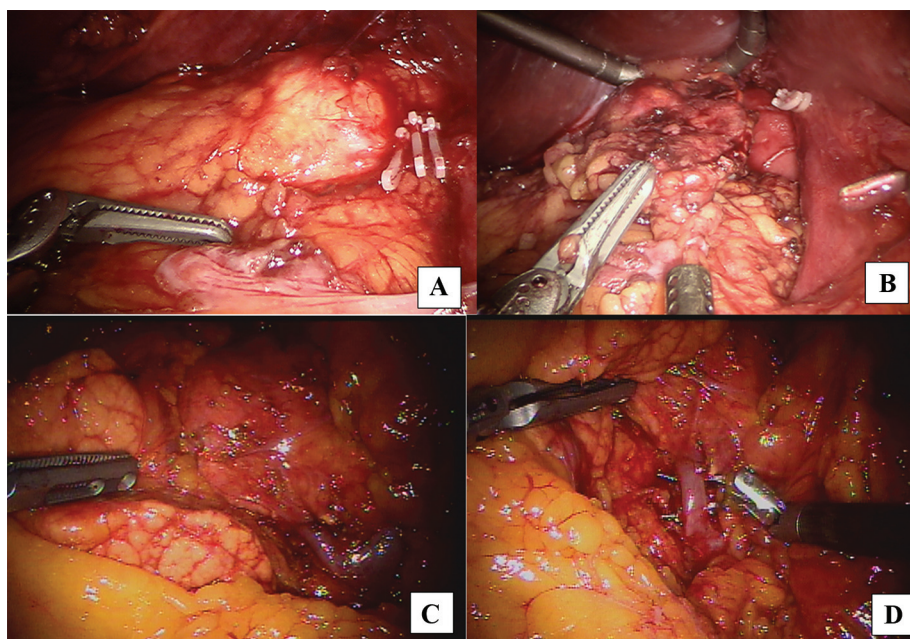


Figure 3. Intraoperative images of the right (A,B) and left (C,D) Transperitoneal Robotic Adrenalectomy. A) The right adrenal gland after exposure and clipping of the adrenal vein that is followed by dissection of the right adrenal gland (B). C) The exposed left adrenal gland followed by the isolation of the left adrenal vein (D).

Table 1.

Baseline Demographic Data of Patients Who Underwent Transperitoneal Robotic Adrenalectomy

| Description | |
|-----------------------------------|-----------|
| Sample size, n | 37 |
| Sex, n (%) | |
| Male | 14 (38) |
| Female | 23 (62) |
| Age in years, mean ± SD | 55.4 ± 12 |
| BMI, mean ± SD | 31 ± 7 |
| CCI, mean ± SD | 3.8 ± 1.7 |
| Previous abdominal surgery, n (%) | 28 (76) |

SD, standard deviation; BMI, body mass index; CCI, Charleston Comorbidity Index.

5. Statistical Analysis

Collected data were expressed as either sum (n) and percentage (%) or mean and standard deviation (SD). Statistical comparisons were made with a two-sample, two-tailed T-test using Microsoft Excel data analysis software (Microsoft Corp, Redmond, WA). A *p*-value of < 0.05 was considered statistically significant.

RESULTS

In our cohort of 37 patients, 62% were female, the average age was 55 years old with a CCI of 3.7 and BMI 31. Further demographic information is shown in **Table 1**. Over 75% of the patients had prior abdominal surgery. Sixty-five percent of the adrenalectomies were of the left adrenal gland. No bilateral adrenalectomies were performed. The average operating room time for all TRAs was 213 minutes. The average gland volume, EBL, and LOS were, 71 cm³, 74 mL, and 1.4 days, respectively. There were no significant differences

in operating time, gland volume, EBL, or LOS between the right and left TRA groups (**Table 2**). One-third of our cohort had adrenal cortical adenomas, nine were biologically active, and only one patient had an adrenal cortical carcinoma (**Table 3**). All margins were pathologically negative. There were no blood transfusions in our cohort. None of the procedures were converted to a laparoscopic or open approach. Four patients (11%) experienced postoperative complications, three of which resulted in unplanned hospital readmission. One patient presented with a Clavien-Dindo II complication of a type 1 non-ST elevation myocardial infarction 22 days from the index operation. She recovered well and was discharged in stable condition. The second patient was readmitted one day after discharge for management of hypocortisolism and a urinary tract infection (Clavien-Dindo II complication). He was treated and discharged home five days later in good condition. The third patient was readmitted 11 days after his index procedure with a wound hematoma (Clavien-Dindo II complication) that was managed nonoperatively. He was discharged from the hospital the following day. The single mortality in the study was a patient who suffered a postoperative ST elevation myocardial infarction (STEMI) requiring urgent cardiac intervention with subsequent arrest (Clavien-Dindo V complication).

DISCUSSION

Since its description by Gagner et al. in 1992,¹¹ laparoscopic adrenalectomy has become the standard of care for the management of both functional and nonfunctional neoplasms of the adrenal gland. When first introduced, minimally invasive adrenal surgery of large tumors was associated with inferior outcomes due to prolonged operative times, increased blood loss, tumor spillage, and capsular rupture. These procedures were also associated with high conversion rates.¹² As surgeon familiarity with this technique improved, so did the outcomes and the

Table 2.

Intraoperative Data of Right and Left Transperitoneal Robotic Adrenalectomies and Final Pathology

| Description | Total | Right TRA | Left TRA | <i>P</i> -Value |
|---|-----------|-----------|-----------|-----------------|
| Sample size, n (%) | | 13 (35) | 24 (65) | |
| Mean Operative Time (min), mean ± SD | 213 ± 87 | 205 ± 106 | 216 ± 77 | 0.72 |
| Mean Size of Resected gland (cm ³), mean ± SD | 71 ± 63 | 58 ± 64 | 77 ± 64 | 0.40 |
| Mean Estimated Blood Loss (mL), mean ± SD | 74 ± 83 | 80 ± 84 | 69 ± 83 | 0.95 |
| Mean Length of Stay (days), mean ± SD | 1.4 ± 0.7 | 1.3 ± 8.5 | 1.3 ± 0.6 | 0.71 |

TRA, transperitoneal robotic adrenalectomy; SD, standard deviation.

Table 3.
Final Pathology of Retrieved Specimens

| Description | n (%) |
|----------------------------------|---------|
| Adrenal cortical adenoma | 12 (32) |
| Pheochromocytoma | 5 (14) |
| Benign adrenal cortical neoplasm | 5 (14) |
| Cortical hyperplasia | 4 (11) |
| Vascular adrenal cyst | 3 (8) |
| Adrenal cyst | 3 (8) |
| Myolipoma | 2 (5) |
| Adrenal cortical carcinoma | 1 (3) |
| Other* | 2 (5) |

*Other includes: adrenal medullary hyperplasia, separate nodule of paraganglioma/extra-adrenal pheochromocytoma; invasive high-grade neuroendocrine tumor.

resectability of large tumors. Once a contraindication, a threshold larger than 6 cm has now become a matter of debate. Currently, relative contraindications to the minimally invasive adrenalectomy include adrenocortical cancer and malignant pheochromocytoma. Locoregional invasion is an absolute contraindication and mandates laparotomy.^{13,14} Following the development of minimally invasive retroperitoneal access by Garu et al. and Madsessi et al. in 1993, the posterior retroperitoneal approach has become an additional option that can be used in select patients.^{15,16} Although the level of evidence is weak, the American Society of Gastrointestinal and Endoscopic Surgery has provided the following recommendations in patient selection for posterior retroperitoneoscopic and lateral transabdominal adrenalectomy:

- A retroperitoneal approach may be preferred in a patient with previous abdominal surgical procedures as there are fewer complications and shortened operative times
- The retroperitoneal approach has the advantage of eliminating patient repositioning for patients undergoing bilateral adrenalectomies
- There is a preference to use the lateral transabdominal approach in patients that are morbidly obese patients (BMI > 35 kg/m²) or have large tumors (> 6 cm).

Despite the above recommendations, surgeons should use the technique most familiar to ensure the best patient outcomes.¹⁷

It has been well established that laparoscopic surgery is associated with shorter hospital LOS, less postoperative

pain, rapid postoperative recovery, and lower patient morbidity.¹⁸ Over the past two decades, there has been widespread use and adoption of the robotic platform as it ameliorates many limitations of laparoscopic surgery including inadequate tailoring of operative ergonomics, two-dimensional vision, loss of depth perception, rigid instruments, and only four degrees of freedom.³ Despite these advantages, the overall benefit of robotic adrenalectomy compared to conventional laparoscopic adrenalectomy remains highly debated. Here we will review the current literature on complications, operative times, and cost; as well as discuss our experience.

Postoperative morbidity and mortality are similar between the laparoscopic and robotic approaches. There are no differences in ileus, surgical site infection, wound infection, postoperative hematoma, urinary tract infection, adjacent organ injury, and hemorrhage.¹⁸ In our cohort, there were four postoperative complications (11%) including myocardial infarction, urinary tract infection, and hematoma that occurred within 30 days of the index procedure. We had one postoperative mortality due to STEMI. Upon further review, this patient had a CCI of 8 as well as a 7.3% risk of severe complication (average risk of 3.6%) and a 1.1% risk of death (average risk of 0.2%) based on the American College of Surgeons National Surgical Quality Improvement Program surgical risk calculator.¹⁹ Our data closely mirrors that of other small series. Branaud et al. followed a cohort of 100 patients who underwent robotic transperitoneal adrenalectomy. They had 10 (10%) postoperative complications (3 Clavien grade I and 7 Clavien grade II complications). In this series, one robotic approach required conversion to laparoscopy and another required conversion to open adrenalectomy.²⁰ Similarly, in a series of 30 patients undergoing unilateral transperitoneal adrenalectomy, D'Annibale et al. had 3 (10%) postoperative complications as well as 2 intraoperative complications (6.7%) with one conversion to open adrenalectomy (3.3%).⁵ Several reviews have reported rates of conversion from robotic adrenalectomy to laparoscopic and open adrenalectomy as high as 6% and 7%, respectively.^{7,18} Conversion rates during minimally invasive adrenalectomy are higher for tumors > 6 cm in size, as removal of these large tumors can be technically challenging. However, in a single-center review by Agcaoglu et al. comparing 62 patients undergoing robotic (n = 24) and laparoscopic (n = 38) adrenalectomy of tumors > 5 cm, the robotic approach was associated with significantly less conversion rates, less blood loss, and a shorter hospital stay despite similar tumor sizes between these groups.²¹

Much of the data regarding robotic adrenalectomy is from small cohort studies. Recently, there have been some

meta-analyses comparing robotic and conventional laparoscopic adrenalectomy. In 2019, Samreen et al. analyzed 1,006 patients (668 undergoing laparoscopic adrenalectomy and 338 undergoing robotic adrenalectomy) from the National Inpatient Sample (NIS) database. They did not find any significant difference in complications or conversions between the two groups but showed a significantly shorter LOS in patients undergoing robotic adrenalectomy.²² A 2017 meta-analysis of 27 studies comparing a total of 1,162 patients undergoing robotic (n = 747) and laparoscopic (n = 415) adrenalectomy showed no significant difference in intraoperative or postoperative complications, mortality, conversion rates or blood loss. Robotic adrenalectomy was associated with a significantly shorter length of stay as well as longer operative times. Further, there were only two recorded mortalities related to postoperative respiratory failure and another to arrhythmia.²³

When transitioning from conventional laparoscopic to robotic approaches, many authors observe that operative times decrease significantly between the first 20–50 cases, with the most significant differences occurring with junior surgeons.^{20,5,24} There are mixed results between large meta-analyses on the differences of operative times between laparoscopic and robotic approaches.^{23–25} Makey et al. observed that surgeon experience, first assistant training level, and tumor size are independent factors associated with mean operative times. As such, the length of time increased with the complexity of the operation.²⁶ There is significant heterogeneity in operative times based on surgical approach between laparoscopic (77–256 min), posterior retroperitoneoscopic (51–214 min), and open (85–180 min) procedures.²³ A recent review of 12 small cohort studies in patients undergoing robotic adrenalectomy showed operative times can vary widely (89–234 min).¹⁸ In our study, the average operative time for robotic adrenalectomy was 229 min, with no difference based on laterality. This time appears consistent with what has been found in the literature.¹⁸ Our operative time did not decrease with more operations, nor did the operative time increase with an increase in tumor size. Further, all operations were performed by a single surgeon with the assistance of a second surgeon or a fellow.

Cost data was not included in our case series; however, there are relevant cost considerations when utilizing the robotic platform. Whether there are increased costs associated with robotic adrenalectomy remains controversial. There are a myriad cohort studies that have shown an increased cost with the robotic approach more than 1.5 times when compared to conventional

laparoscopic surgery.²⁷ Additionally, a recent retrospective review of data from the NIS database showed a significantly higher total cost of robotic adrenalectomy compared to conventional laparoscopic adrenalectomy.²¹ However, Feng et al. recently showed that the relative cost for both procedures does not differ. The authors concluded that restricting the number of robotic instruments and energy devices may limit the cost of robotic surgery, which is a strategy that we have employed in our practice.²⁸

CONCLUSION

We have shown that robotic adrenalectomy is a highly effective, minimally invasive procedure at our university affiliated, community-based, tertiary hospital. The authors acknowledge that this 10-year experience may or may not be replicated as it represents a single surgeon at a single institution and thus lacks external validity. Minimally invasive adrenalectomy has been associated with decreased hospital LOS, decreased EBL, acceptable safety margin, and potentially decreased operative times. This study demonstrates that adrenal surgery can safely be converted from a laparoscopic to robotic approach. We anticipate improvement of outcomes as surgeons gain experience and the technology of the robotic platform advances. Future studies should focus on multicenter/surgeon experiences to provide better external validity for robotic adrenalectomy.

References:

1. Winter JM, Talamini MA, Stanfield CL, et al. Thirty robotic adrenalectomies. *Surg Endosc*. 2006;20(1):119–124.
2. Kumar R, Hemal A, Menon M. Robotic renal and adrenal surgery: present and future. *BJU Int*. 2005;96(3):244–249.
3. Yiannakopoulou E. Robotic assisted adrenalectomy: surgical techniques, feasibility, indications, oncological outcome and safety. *Int J Surg*. 2016;28:169–172.
4. Rosoff JS, Otto BJ, Del Pizzo JJ. The emerging role of robotics in adrenal surgery. *Curr Urol Rep*. 2010;11(1):38–43.
5. D'Annibale A, Lucandri G, Monsellato I, et al. Robotic adrenalectomy: technical aspects, early results and learning curve. *Int J Med Robot*. 2012;8(4):483–490.
6. Brunaud L, Germain A, Zarnegar R, Cuny T, Ayav A, Bresler L. Robot-assisted adrenalectomy. *Surg Laparosc Endosc Percutan Tech*. 2011;21(4):248–254.
7. Nomine-Criqui C, Demarquet L, Schweitzer ML, Klein M, Brunaud L, Bihain F. Robotic adrenalectomy: when and how? *Gland Surg*. 2020;9(Suppl 2):S166–S172.

8. Kaji AH, Schriger D, Green S. Looking through the retro-spectroscope: reducing bias in emergency medicine chart review studies. *Ann Emerg Med.* 2014;64(3):292–298.
9. Lenders JWM, Duh Q-Y, Eisenhofer G, et al. Pheochromocytoma and paraganglioma: an Endocrine Society Clinical Practice Guideline. *J Clin Endocrinol Metab.* 2014;99(6):1915–1942.
10. Clavien PA, Barkun J, de Oliveira ML, et al. The Clavien-Dindo classification of surgical complications: five-year experience. *Ann Surg.* 2009;250(2):187–196.
11. Gagner M, Lacroix A, Bolte E. Laparoscopic adrenalectomy in Cushing's syndrome and pheochromocytoma. *N Engl J Med.* 1992;327(14):1033.
12. Prager G, Heinz-Peer G, Passler C, Kaczirek K, Scheuba C, Niederle B. Applicability of laparoscopic adrenalectomy in a prospective study in 150 consecutive patients. *Arch Surg.* 2004;139(1):46.
13. Lombardi CP, Raffaelli M, De Crea C, et al. Open versus endoscopic adrenalectomy in the treatment of localized (stage I/II) adrenocortical carcinoma: results of a multi-institutional Italian survey. *Surgery.* 2012;152(6):1158–1164.
14. Lombardi CP, Raffaelli M, Boniardi M, et al. Adrenocortical carcinoma: effect of hospital volume on patient outcome. *Langenbecks Arch Surg.* 2012;397(2):201–207.
15. Gaur DD, Agarwal DL, Purohit KC. Retroperitoneal laparoscopic nephrectomy: initial case report. *J Urol.* 1993;149(1):103–105.
16. Mandressi A, Buizza C, Antonelli D, Belloni M, Chsena S, et al. Retro-extraperitoneal laparoscopic approach to excise retroperitoneal organs: kidney and adrenal gland. *Min Invas Ther.* 1993;2(5):213–220.
17. Stefanidis D, Goldfarb M, Kercher KW, et al. SAGES Guidelines for minimally invasive treatment of adrenal pathology. *Surg Endosc.* 2013;27(11):3960–3980.
18. Makay O, Erol V, Ozdemir M. Robotic adrenalectomy. *Gland Surg.* 2019;8(Suppl 1):S10–S16.
19. Bilimoria KY, Liu Y, Paruch JL, et al. Development and evaluation of the universal ACS NSQIP surgical risk calculator: a decision aid and informed consent tool for patients and surgeons. *J AM Coll Surg.* 2013;217(5):833–842.
20. Brunaud L, Ayav A, Zarnegar R, et al. Prospective evaluation of 100 robotic-assisted unilateral adrenalectomies. *Surgery.* 2008;144(6):995–1001.
21. Agcaoglu O, Aliyev S, Karabulut K, et al. Robotic versus laparoscopic posterior retroperitoneal adrenalectomy. *Arch Surg.* 2012;147(3):272–275.
22. Samreen S, Fluck M, Hunsinger M, et al. Laparoscopic versus robotic adrenalectomy: a review of the national inpatient sample. *J Robot Surg.* 2019;13(1):69–75.
23. Economopoulos KP, Mylonas KS, Stamou AA, et al. Laparoscopic versus robotic adrenalectomy: a comprehensive meta-analysis. *Int J Surg.* 2017;38:95–104.
24. Pineda-Solís K, Medina-Franco H, Heslin MJ. Robotic versus laparoscopic adrenalectomy: a comparative study in a high-volume center. *Surg Endosc.* 2013;27(2):599–602.
25. Heger P, Probst P, Hüttner FJ, et al. Evaluation of open and minimally invasive adrenalectomy: a systematic review and network meta-analysis. *World J Surg.* 2017;41(11):2746–2757.
26. Makay O, Uguz A, Simsir I, et al. Robot-assisted laparoscopic bilateral adrenalectomy: a case report. *UCD.* 2013;28(4):225–228.
27. Bodner J, Augustin F, Wykypiel H, et al. The da Vinci robotic system for general surgical applications: a critical interim appraisal. *Swiss Med Wkly.* 2005;135:674–678.
28. Feng Z, Feng MP, Feng DP, et al. A cost-conscious approach to robotic adrenalectomy. *J Robot Surg.* 2018;12(4):607–611.