

Case report

Open Access

Primary gastric tuberculosis – report of 5 cases

Deepak N Amarpurkar*¹, Nikhil D Patel¹ and Anjali D Amarpurkar²

Address: ¹Departments of Gastroenterology and Hepatology Bombay Hospital and Medical Research Centre, India and ²Department of Pathology BYL Nair Ch Hospital, TN Medical college, Mumbai, India

Email: Deepak N Amarpurkar* - deepakn@bom3.vsnl.net.in; Nikhil D Patel - niyopatel@vsnl.net; Anjali D Amarpurkar - anjali_1963@hotmail.com

* Corresponding author

Published: 18 April 2003

Received: 11 November 2002

BMC Gastroenterology 2003, **3**:6

Accepted: 18 April 2003

This article is available from: <http://www.biomedcentral.com/1471-230X/3/6>

© 2003 Amarpurkar et al; licensee BioMed Central Ltd. This is an Open Access article: verbatim copying and redistribution of this article are permitted in all media for any purpose, provided this notice is preserved along with the article's original URL.

Abstract

Background: Gastric tuberculosis is rare, and usually associated with pulmonary tuberculosis or an immunodeficient state. Here, we report five cases of gastric tuberculosis in immunocompetent patients without evidence of pulmonary involvement.

Case presentation: Three patients presented with gastric outlet obstruction that required surgery to relieve the obstruction as well as to confirm the diagnosis. The remaining two had involvement of gastroesophageal junction. All of them responded well to standard antitubercular treatment.

Conclusion: Though gastric tuberculosis is rare, it should be considered a possibility when patients present with gastric outlet obstruction or with endoscopic evidence of diffuse chronic inflammatory activity, particularly in areas endemic for tuberculosis.

Background

Tuberculosis of stomach whether primary or secondary infection is not common. [1,2] It is usually associated with pulmonary tuberculosis or with immunodeficiency state. [3] Clinically it resembles peptic ulcer disease or malignancy. [4] we report 5 cases of gastric tuberculosis in immunocompetent patients without evidence of pulmonary involvement.

Case presentation

Case 1

A 32 years female presented with epigastric pain, nausea and occasional vomiting for 5 months. She noticed significant weight loss in 2 months. There was no past or family history of tuberculosis. Physical examination did not reveal any abnormality. Patient was non-diabetic. X ray chest, complete blood count, liver and renal function tests were normal. Her HIV status was negative. Upper GI en-

doscopy was suggestive of ulcerated mass at the antrum with a nonnegotiable gastric outlet obstruction. Endoscopic mucosal biopsy did not reveal malignancy or granuloma. CT scan of abdomen suggested thick antrum with dilated stomach, without any lymph node enlargement or ascites. In view of gastric outlet obstruction without specific histological diagnosis patient was subjected to exploratory laparotomy. Intraoperatively multiple necrotising lymph nodes were seen forming a mass around the antrum. Gastrojejunostomy was done. Biopsy from the lymph node mass showed caseating granuloma with presence of epithelioid cells, Langhan's giant cells and acid-fast bacilli on Zeil Nelson staining. Patient was put on antituberculous treatment (ATT) regimen consisting of (HREZ) 2(HR) 7 that is Isoniazide 5 mg / kg, Rifampicin 10 mg/kg, Ethambutol 15 mg/kg and Pyrizinamide 25 mg/kg body weight for initial 2 months followed by Isoniazide and Rifampicin in same dose for another 7

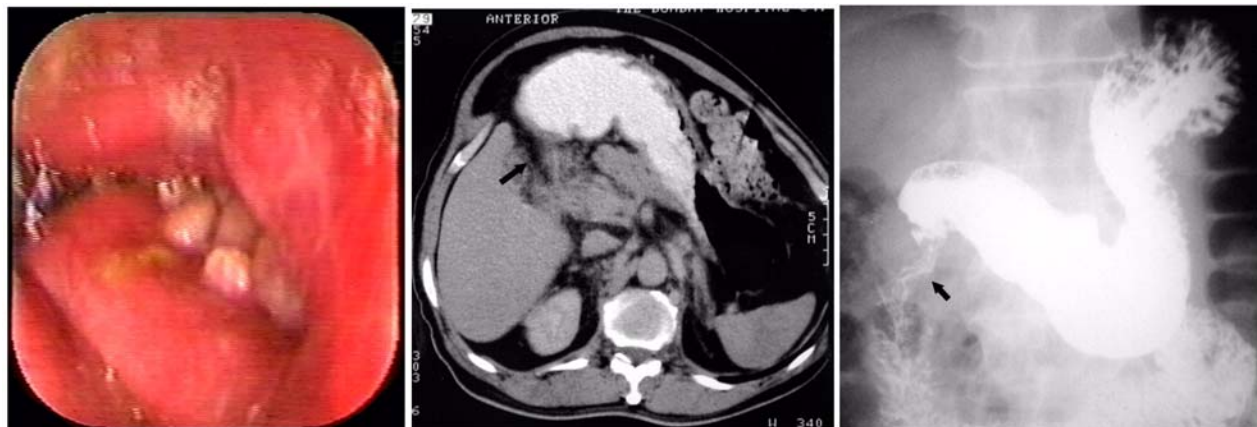


Figure 1
Endoscopy, CT abdomen and barium study are suggestive of gastric outlet obstruction. (Case 2).

months. While on treatment, she gained 6 kgs weight and became symptom free. Repeat upper GI endoscopy after 4 months of treatment was suggestive of deformed but negotiable antrum, nodular duodenum with well functioning gastrojejunal (GJ) stoma. At one yr, upper GI endoscopy was normal with presence of normal GJ stoma.

Case 2

A 53 years old male presented with epigastric pain, anorexia and nausea for 3 months. He lost 10 kgs of weight in few months. There was no past or family history of tuberculosis. Patient was non-diabetic. Clinical examination was within normal limits. X ray chest, complete hemogram, liver and renal function tests were normal. HIV testing was negative. Upper GI endoscopy was suggestive of deformed and narrowed antrum, with gastric outlet obstruction. (Fig 1) Duodenum was also deformed. Abdominal CT scan revealed presence of multiple lymph nodes in para aortic, celiac, pancreatic and retroperitoneal regions. Barium meal studies were suggestive of deformed and spastic duodenum. Exploratory laparotomy was planned to relieve gastric outlet obstruction due to matted lymph-nodes, which were causing extrinsic compression and obstruction of pylorus. Gastrojejunostomy was performed. Histopathology of the lymph node revealed caseating granuloma. He was put on ATT regimen of (HERZ) 2(HR) 7 during which, he gained weight of 12 kgs and became symptom free. Upper GI endoscopy at 6 months was normal with presence of GJ stoma.

Case 3

A 23 years female presented with epigastric pain, vomiting and loss of weight for last 6 months. Her upper GI endoscopy was suggestive of narrowed antrum and gastric outlet obstruction. She underwent laparotomy for relieving gastric outlet obstruction with gastrojejunostomy. Intraoperatively a lymph node mass was seen obstructing pyloroduodenal region which on histology was suggestive of caseating granuloma with presence of acid fast bacilli. Then she received ATT that is (HERZ) 2(HR) 7 for 1 year and was symptom free. Five years later, she presented again with splenomegaly and imaging studies were suggestive of portal hypertension with calcified portal cavernoma and splenomegaly. Liver was normal on imaging as well as on scintigraphy. Her hemogram, liver and renal function tests and chest X ray were normal. Viral and autoimmune markers were negative. She was a nondiabetic and negative for HIV serology. Upper GI endoscopy revealed esophageal and fundic varices and presence of gastrojejunal stoma. Portal vein thrombosis in this case was probably secondary to old tubercular lymphadenitis.

Case 4

A 32 years male presented with epigastric pain and occasional vomiting for 1 year. He did not show any response to repeated antisecretory medications. There was no past or family history of tuberculosis. Clinical examination was normal. X ray chest, liver and renal function tests were normal. Patient was non-diabetic and seronegative for HIV. Upper GI endoscopy was suggestive of nodular ulcerative lesion at gastro esophageal junction, occluding almost half of the lumen. Endoscopic biopsy revealed

caseating epitheloid granuloma with Langhan's giant cells. CT scan abdomen was suggestive of enhancing nodular lesion in celiac and para aortic regions, probably lymph nodes with asymmetrical thickening of wall at gastro esophageal junction. Patient was put on ATT regimen of (HERZ) 2(HR) 7 and became symptom free. Repeat upper GI endoscopy at one year was normal.

Case 5

A 30 years male presented with epigastric pain and dysphagia of five months duration. Upper GI endoscopy was suggestive of a mass at gastro esophageal junction with possibility of leiomyoma. There was no response to antisecretory medications. Patient did not give any past or family history for tuberculosis. Clinical examination was normal. X ray chest, hemogram, liver and renal function tests were normal. Abdominal CT scan revealed heterogeneously enhancing lesion at gastro esophageal junction. Repeat upper GI endoscopy was suggestive of an ulcer at gastro esophageal junction and evidence of gastritis. Endoscopic biopsy showed multiple caseating granulomas suggestive of tuberculosis. He was put on ATT regimen of (HERZ) 2(HR) 7 and became symptom free.

Discussion

Commonest site for intra-abdominal tuberculosis is ileocecal region.[5] Involvement of stomach is considered to be rare. Usually gastric tuberculosis is secondary to pulmonary tuberculosis. [3] Primary and isolated gastric tuberculosis without evidence of lesions elsewhere is uncommon. [1] The reason for relative rarity is attributed to bactericidal property of gastric acid, scarcity of lymphoid tissue in gastric wall and intact gastric mucosa of the stomach. The possible routes of infection include direct infection of the mucosa, hematogenous spread or extension from neighbouring tuberculous lesion. [4] Commonly these patients mimic peptic ulcer disease or malignancy but at times clinical presentation may be misleading. Okoro EO and Komolafe OF [6] reported two patients of gastric tuberculosis with unusual presentations. One of their patients was elderly man suspected to have abdominal malignancy but subsequently found to be extensive, complicated gastric tuberculosis coexisting with chronic peptic ulcer disease. The second patient was female who developed gastro-bronchial fistula due to tuberculosis, which was evident radiologically. A report by Chetri K [7] et al has shown a case of gastric tuberculosis presenting as non-healing gastric ulcer. Out of 5, three of our cases presented with gastric outlet obstruction, which is the most common presentation of gastric tuberculosis. [8] These 3 patients had to undergo subsequently laparotomy for relieving obstruction and tissue diagnosis. One of these 3 showed features of portal hypertension with splenomegaly, which was due to old tuberculous lymphadenitis causing portal vein thrombosis. Wig JD [9] et

al reported a case of isolated gastric tuberculosis presenting as massive hematemesis. This patient was found to have benign gastric ulcer along the lesser curvature. The diagnosis of tuberculosis was done on histopathological examination showing caseating epitheloid cell granulomas. It is well known fact that probably due to lack of accurate clinical diagnosis, most patients end up with surgical intervention and the diagnosis of gastric tuberculosis is made after surgery. Remaining 2 patients presented with dysphagia and a mass lesion at gastroesophageal junction. Tuberculous lesions of the stomach are usually located on lesser curvature of the antrum and often involve the duodenum but the finding of a tuberculous ulcer at the gastroesophageal junction is uncommon. [10] The diagnosis of tuberculosis requires demonstration of caseating epitheloid granuloma or presence of acid-fast bacilli in tissue. When granulomas are non-caseating, small and discrete, the differential diagnosis on histology includes Crohn's disease, sarcoidosis, syphilis, mycotic lesions and exposure to beryllium, silicates or reserpine.[4,11] Petroianni A et al have reported a case of abdominal tuberculosis mimicking Crohn's disease in an immigrant girl from Peru. In all of our 5 cases, granulomas were composed of caseation necrosis and epitheloid cells. We were able to demonstrate AFB bacilli in all of them. Other possibilities of granulomatous lesions were ruled out clinically keeping in mind high incidence of tuberculosis in India. The clinical response to ATT and repeat endoscopic examination also supported the diagnosis.

Conclusion

Though gastric tuberculosis is rare, patients presenting with gastric outlet obstruction or with endoscopic evidence of diffuse chronic inflammatory activity, the possibility of gastric tuberculosis should be kept in mind especially in areas endemic for tuberculosis.

Acknowledgement

"Written consent was obtained from the patients for publication of the patient's details."

References

1. Subei I, Attar B, Schmitt G and Levendoglu H **Primary gastric tuberculosis: A case report and literature review** *Am J Gastroenterol* 1987, **82**:769-772
2. Misra RC, Agrawal SK, Prakash P, Saha MM and Gupta PS **Gastric tuberculosis** *Endoscopy* 1984, **14**:235-237
3. Brody JM, Miller DK, Zeman RK, Klappenbach RS, Jaffe MH, Clark LR, Benjamin SB and Choyke PL **Gastric tuberculosis: A manifestations of acquired immunodeficiency syndrome** *Radiology* 1986, **159**:347-348
4. Gupta B, Mathew S and Bhalla S **Pyloric obstruction due to gastric tuberculosis: An endoscopic diagnosis** *Postgrad Med J* 1990, **66**:62-65
5. Abrams JS and Holden WD **Tuberculosis of gastrointestinal tract** *Arch Surg* 1964, **89**:282-293
6. Okoro EO and Komolafe OF **Gastric tuberculosis: unusual presentations in two patients** *Clin Radiol* 1999, **54**:257-9

7. Chetri K, Prasad KK, Jain M and Choudhuri G **Gastric tuberculosis presenting as non-healing ulcer: case report** *Trop Gastroenterol* 2000, **21**:180-1
8. Tromba JL, Inglese R, Rieders B and Todaro R **Primary gastric tuberculosis presenting as pyloric outlet obstruction** *Am J Gastroenterol* 1991, **86**:1820-1822
9. Wig JD, Vaiphei K, Tashi M and Kochhar R **Isolated gastric tuberculosis presenting as massive hematemesis report of a case** *Surg Today* 2000, **30**:921-2
10. Palmer ED **Tuberculosis of the stomach and the stomach in tuberculosis** *Am Rev Tuberc* 1950, **61**:116-130
11. Petroianni A, Mugnaini L, Laurendi G, Giousue S, Schinina V, Bibbolino C and Bisetti A **Abdominal tuberculosis mimicking Crohn's disease: a difficult diagnosis. Report of a case** *Panminerva Med* 2002, **44**:155-8

Pre-publication history

The pre-publication history for this paper can be accessed here:

<http://www.biomedcentral.com/1471-230X/3/6/prepub>

Publish with **BioMed Central** and every scientist can read your work free of charge

"BioMed Central will be the most significant development for disseminating the results of biomedical research in our lifetime."

Sir Paul Nurse, Cancer Research UK

Your research papers will be:

- available free of charge to the entire biomedical community
- peer reviewed and published immediately upon acceptance
- cited in PubMed and archived on PubMed Central
- yours — you keep the copyright

Submit your manuscript here:
http://www.biomedcentral.com/info/publishing_adv.asp

