

# Intermittent Asymptomatic Fever in a Psoriasis Patient

This article was published in the following Dove Press journal:  
*International Journal of General Medicine*

Jiawen Zhang<sup>1,\*</sup>  
Hequn Huang<sup>2,\*</sup>  
XiXi Xiong<sup>1</sup>  
Yan Lu<sup>1</sup>   
Lorna Martin Kasyanjan Carrero<sup>1</sup>  
Bingrong Zhou<sup>1</sup>  
Yang Xu<sup>1</sup>

<sup>1</sup>Department of Dermatology, The First Affiliated Hospital of Nanjing Medical University, Nanjing, Jiangsu Province 210029, People's Republic of China;

<sup>2</sup>Department of Dermatology, No. 1 Hospital and Key Laboratory of Dermatology, Ministry of Education, Anhui Medical University, Hefei, Anhui Province 230032, People's Republic of China

\*These authors contributed equally to this work

**Abstract:** Acitretin, an active metabolite of etretinate, is the most widely used systemic retinoid in the treatment of psoriasis. Several side effects of acitretin have been reported such as teratogenicity, cheilitis, xerosis, dyslipidemia, and photosensitivity. Here, we reported a case of acitretin-induced intermittent asymptomatic fever in a 79-year-old male psoriasis patient. To the best of our knowledge, only one such case has been reported in the literature so far. We report our case to draw clinical attention that acitretin may cause drug fever, which might not be a rare phenomenon.

**Keywords:** acitretin, drug fever, psoriasis

## Introduction

Drug-induced fever is a febrile response after the administration of a drug without other underlying causes.<sup>1</sup> Drug-induced fever might have four kinds of heat type, presenting as continuous, remittent, intermittent, or hectic.<sup>2</sup> Body temperature during drug-induced fever is usually around 39°C–40°C.<sup>3</sup>

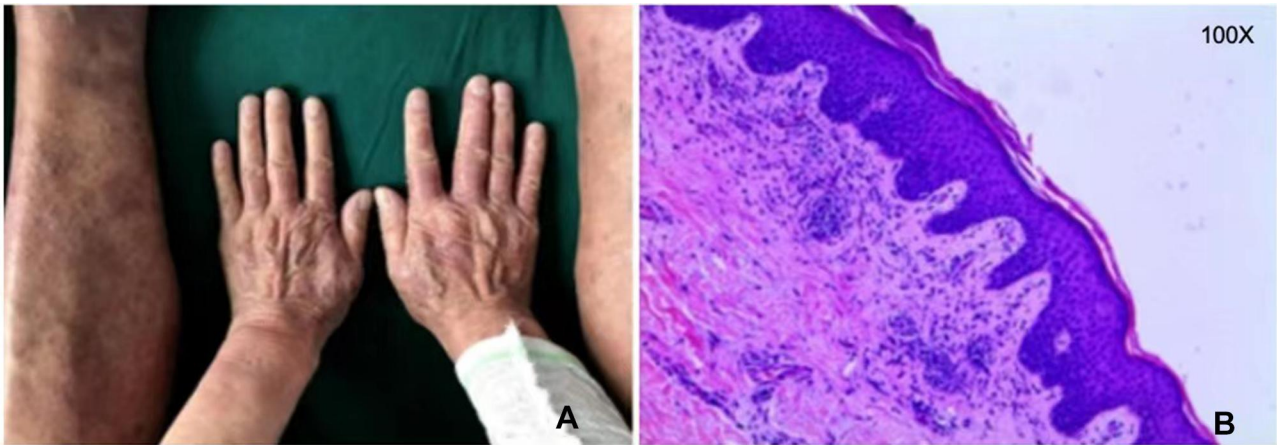
Acitretin, a metabolite of etretinate, has been used to treat psoriasis since the 1980s. Common side effects, which are generally dose-dependent, include cheilitis, desquamation, pruritus, alopecia, rhinitis, xerophthalmia, and xerosis. Hepatotoxicity, altered lipid profile, and pancreatitis are less common. Acitretin is limited by its teratogenicity and thus should be avoided during pregnancy.<sup>4</sup>

Up to now, only one case of acitretin-induced fever has been reported.<sup>2</sup> Here, we reported the second case ever of acitretin-induced fever.

## Case Report

A 79-year-old man was presented with aggregated, erythematous, scaly plaques that appeared on his trunk and extremities 3 days ago. The patient had a 10-year history of psoriasis vulgaris, and his clinicopathological manifestations were consistent with psoriasis (Figure 1). He had a 20-year history of chronic obstructive pulmonary disease (treated using salmeterol and tiotropium bromide once daily), a 10-year history of hypertension (treated using nifedipine besylate 5 mg once daily), and a 5-year history of type-2 diabetes mellitus (treated using glimepiride 2 mg and acarbose 50 mg thrice daily). He was allergic to penicillin, cephalosporins, and magnesium isoglycyrrhizinate. The next day (day 2), acitretin 20 mg was administered at noon. The medications for chronic obstructive pulmonary disease, hypertension, and diabetes that he had been taking for the past 6 months were continued.

Correspondence: Yang Xu  
Department of Dermatology, The First Affiliated Hospital of Nanjing Medical University, Nanjing, Jiangsu Province 210029, People's Republic of China  
Tel +86-13851856794  
Email yangxu@njmu.edu.cn



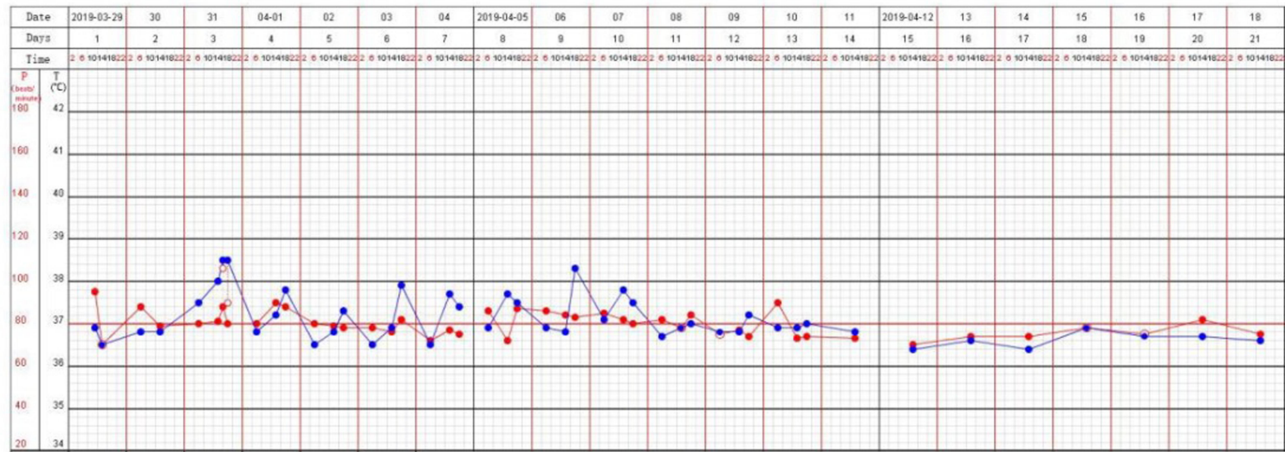
**Figure 1** Clinical and pathological manifestations in the patient. **(A)** Scaly erythema was seen on the trunk and extremities. **(B)** Focal hyperkeratosis with hypokeratosis was observed in the epidermis, along with Munro's microabscess. In the dermis, a sparse superficial perivascular infiltration of lymphocytes, mononuclear cells, neutrophils, and eosinophils was seen. Dilated, tortuous capillaries were found. Hematoxylin and eosin staining; magnification, 100 $\times$ .

At 18:00 on day 3, 36 h after the first acitretin dose, the patient was found to have a fever (temperature, 38.5°C). The fever persisted for 4 h and disappeared after physical cooling at about 22:00. On admission, the chest CT scan showed signs of pulmonary infection. So daily 0.5g azithromycin was given intravenously. The patient did not feel any discomfort during this time. Further screening for infection, including bacterial cultures from the throat, skin, urine, and blood, serum antibody tests for Epstein-Barr virus and cytomegalovirus, and Aspergillus tests, yielded no positive results. Laboratory examinations indicated there might be no pathogenic infection. Intermittent fever persisted for the next 7 days (Figure 2). During the treatment of Acitretin, the patient's skin manifestation is gradually getting better without any sign of aggravation.

Meanwhile, the patient's lips were dry which was alleviated by some moisturizer. On day 10, acitretin was discontinued, and pyrexia did not recur. The patient was administered methotrexate 7.5 mg/week and discharged after a marked therapeutic response. Follow-up at 1 and 3 months showed that the patient was well and afebrile.

**Discussion**

The key feature of this case is the sudden onset of fever after acitretin administration. The patient himself did not notice the fever. His heart rate was not elevated during pyrexia, and he was in a relatively good condition throughout. Although drug-induced fever is not listed as an adverse reaction in the package insert for acitretin, a sudden fever with a lack of self-discomfort and no



**Figure 2** Record of the body temperature (blue) and heart rate (red) of the patient. From day 3 to day 10 after his admission, the patient had an intermittent fever from 18:00 to 22:00 every day, during which time, there was no obvious fluctuation in the heart rate.

evidence of relative bradycardia after the initiation of a medication should raise a high suspicion of drug-induced fever.

Besides high body temperature, other manifestations of drug fever include unawareness of the fever by the patient himself and disappearance of relative bradycardia. Patients with drug-induced fever may not have fatigue, chills, and discomfort, and their heart rate does not increase to the extent expected for the given temperature elevation. At 38.5°C, the appropriate pulse response is up to 113 beats per minute. The most sensible treatment for drug-induced fever is drug discontinuation. Challenge tests might re-induce fever and are controversial. Early diagnosis of drug fever and timely withdrawal of medicine play an essential role in maintaining efficient medical care.

Acitretin-induced fever is rare, with only one reported case.<sup>2</sup> A 63-year-old man with psoriasis was administered acitretin 25 mg/day (0.3 mg/kg), and developed a sudden fever ~24 h later. The fever recurred every day thereafter (highest body temperature, 38.8°C), and subsided 24 h after acitretin discontinuation. Thus, the characteristics of acitretin-induced fever are as follows: (1) onset ~24 h after the first dose; (2) intermittent fever recurring every day (temperature < 39°C) and resolving spontaneously; (3) relative bradycardia and unawareness of the fever by the patient; and (4) complete resolution 1 day after acitretin withdrawal. Internal medical doctors and dermatologists should be aware of this side effect to avoid unnecessary screening.

Acitretin acts through retinoic acid receptors to decrease the expression of STAT1 and STAT3, and interfere with the JAK-STAT pathway. This may suppress keratinocyte proliferation and inhibit the expression of multiple cytokines.<sup>5</sup> The mechanism of acitretin-induced fever needs further study.

## Ethics Statement

The study was approved by the ethics committee of the First Affiliated Hospital of Nanjing Medical University. The patient also provided written informed consent for the case details and accompanying images to be published.

## Disclosure

The authors report no conflicts of interest for this work.

## References

1. Patel RA, Gallagher JC. Pharmacotherapy. *Drug Fever*. 2010;30(1):57–69.
2. Rob F, Fialová J, Brejchová M. Drug fever as an adverse effect of acitretin in complicated psoriasis patient. *Dermatol Ther*. 2015;28(6):366–368. doi:10.1111/dth.12263
3. Labbus K, Junkmann JK, Perka C, Trampuz A, Renz N. Antibiotic-induced fever in orthopaedic patients—a diagnostic challenge. *Int Orthop*. 2018;42(8):1775–1781.
4. Kaushik SB, Lebwohl MG. Dermatology, psoriasis: which therapy for which patient: focus on special populations and chronic infections. *J Am Acad Dermatol*. 2019;80(1):43–53.
5. Heath MS, Sahni DR, Curry ZA, Feldman SR. Pharmacokinetics of tazarotene and acitretin in psoriasis. *Expert Opin Drug Metab Toxicol*. 2018;14(9):919–927.

International Journal of General Medicine

### Publish your work in this journal

The International Journal of General Medicine is an international, peer-reviewed open-access journal that focuses on general and internal medicine, pathogenesis, epidemiology, diagnosis, monitoring and treatment protocols. The journal is characterized by the rapid reporting of reviews, original research and clinical studies

Submit your manuscript here: <https://www.dovepress.com/international-journal-of-general-medicine-journal>

Dovepress

across all disease areas. The manuscript management system is completely online and includes a very quick and fair peer-review system, which is all easy to use. Visit <http://www.dovepress.com/testimonials.php> to read real quotes from published authors.