

➤ **Case Report** ◀

Jetstream XC Device for Treatment of Long Viabahn Stents Occlusions in the Superficial Femoral Artery: A Report of Two Cases

Tae-Hoon Kim, MD, PhD,¹ Nelson Chavarria, MD,² Khagendra Dahal, MD,³
Michael Azrin, MD,¹ and Juyong Lee, MD, PhD¹

Repeated restenotic events are common in superficial femoral artery and as of late, Viabahn stent grafts have been FDA (U.S. Food & Drug Administration) approved. Viabahn have been particularly attractive given that they provided a physical barrier for the development of neointimal hyperplasia. This particular feature however, also underscores one of the main limitations of the therapy; providing a physical barrier of collateral circulation and predisposing to acute limb ischemia. Viabahn endograft thrombosis is characterized by stent edge stenosis and endograft thrombosis. Here we present 2 cases of Viabahn graft thrombosis successfully treated with the Jetstream atherectomy device, a rotational cutter with aspiration capacity.

Keywords: atherectomy, Jetstream device, Viabahn occlusion

Introduction

Treatment of superficial femoral artery (SFA) disease remains challenging, in part due to the unique nature of lesion morphologies created by the complex network of mechanical forces present in the muscular adductor canal. Long areas of stenosis and chronic total occlusions are common in the SFA, making a reliable, long-term treatment strategy difficult to obtain. Treatment of SFA in-stent restenosis (ISR) is complicated by the same factors that impact the development of intimal hyperplasia during

the initial primary procedure: stent type, lesion length, vessel area, active smoking, insulin-dependent diabetes, phenotypic gene expression, low blood flow, and plaque composition. Since its introduction, Viabahn endoprosthesis (W. L. Gore & Associates, Flagstaff, AZ, USA) for the treatment of SFA ISR has been particularly appealing, as it creates an endoluminal bypass that limits development of restenosis to the proximal and distal edges of the stent only.¹⁾ Given that thrombosis rates for Viabahn endografts can be high if oversized, monitoring for proximal or distal edge restenosis remains key component of follow-up treatment.²⁾ The development of slow flow can result in thrombosis of the entire endograft and in patients with an inadequate profunda femoris, the endograft can limit recruitment of distal collaterals and predispose to development of acute limb ischemia. In this report, we describe the utilization of the Jetstream XC atherectomy device, a rotational cutter with aspiration capacity, as part of an initial strategy that limits the use thrombolytic therapy exposure time, allows for treatment of the edge stenosis during the index procedure and potentially reduces the length of stay.

Case Reviews

Case 1

A 66-year-old male was admitted to our hospital with acute onset of life-style limiting claudication of the left leg (Rutherford classification 2a). He was an active smoker with a history of hypertension, hyperlipidemia and peripheral artery disease with multiple prior percutaneous endovascular interventions including placement of several nitinol self-expanding stents in the iliac arteries and 18 months prior, placement of 3 Viabahn endograft stents (one 100 mm×5 mm and two 150 mm×5 mm, W. L. Gore & Associates, Flagstaff, AZ, USA) in the left SFA for diffuse in-stent restenosis. Given the acute nature of his symptoms, he was urgently referred for angiography which confirmed a complete thrombotic occlusion of the Viabahn endografts extending from the ostium of the left

¹ UConn Health, University of Connecticut School of Medicine, Farmington, Connecticut, USA

² Montefiore Medical Center, Bronx, New York, USA

³ Division of Cardiovascular Medicine, Louisiana State University Health Science Center, Shreveport, Louisiana, USA

Received: March 26, 2017; Accepted: August 14, 2017
Corresponding author: Juyong Lee, MD, PhD. UConn Health, University of Connecticut School of Medicine, 263 Farmington Avenue, Farmington, Connecticut 06030, USA
Tel: +1-860-679-3343; +1-860-679-2058, Fax: +1-860-679-3346
E-mail: jlee@uchc.edu



SFA to the proximal portion of the left popliteal artery (Figs. 1A and 1B, arrowheads). A patent deep femoral artery provided bridging collaterals reconstituting the mid-segment of the left popliteal artery. We proceeded with an endovascular strategy using the Jetstream XC atherectomy device, a rotational cutter with aspiration capability. After positioning an Emboshield 0.014 NAV6 filter (Abbott Vascular, Santa Clara, CA, USA) in the distal left popliteal artery segment for embolic protection, we directly delivered the Jetstream XC device (2.1 mm/3.0 mm, Boston Scientific, Marlborough, MA, USA) and performed mechanical thrombectomy along the entire length of the occluded SFA and popliteal artery. The follow-up angiogram demonstrated effective removal of large amounts of thrombus, but no reflow was present distally where the filter was located. We then performed aspiration thrombectomy with a Pronto V3 extraction catheter (Vascular Solutions, Minneapolis, MN, USA; Fig. 1C, arrow) and administered intra-arterial vasodilator agents (a total 400 µg of nitroglycerin and 100 µg sodium nitroprusside), which effectively restored flow to the distal vessels. The Viabahn stent edges were then addressed with selective atherectomy using the Jetstream XC device, followed by balloon angioplasty (Powerflex 5.0×60 mm, Cordis Corp, Miami Lakes, FL, USA). The follow-up angiogram demonstrated no filling defects or residual areas of stenosis in

the SFA, popliteal arteries or the infra-popliteal vessels. Satisfied with the excellent angiographic result, the patient was discharged home less than 24 hours from the time of presentation with antiplatelet therapy. Subsequently, he was lost to follow-up and presented again 7 months later with acute thrombosis of the Viabahn endografts. Continued smoking and lack of adherence to antiplatelet therapy likely contributed to his presentation. He was subsequently referred for femoral-popliteal bypass surgery.

Case 2

An 85-year-old female was admitted to our hospital with acute onset of resting left foot pain (Rutherford classification 2b). She had a history of atrial fibrillation on Coumadin therapy, ischemic strokes and peripheral artery disease with multiple prior percutaneous endovascular interventions including placement of 2 Viabahn endograft stents in the left SFA for diffuse in-stent disease (5.0×100 mm and 5.0×150 mm, W. L. Gore & Associates, Flagstaff, AZ, USA). Given the acute nature of symptoms she was referred for urgent angiography which confirmed an acute thrombotic occlusion of the Viabahn endografts extending from the ostium of the left SFA to the proximal portion of the left popliteal artery (Fig. 2A). Upon confirming an international normalized ratio (INR) of 2.7 and having a multi-disciplinary team discussion, we proceeded with an

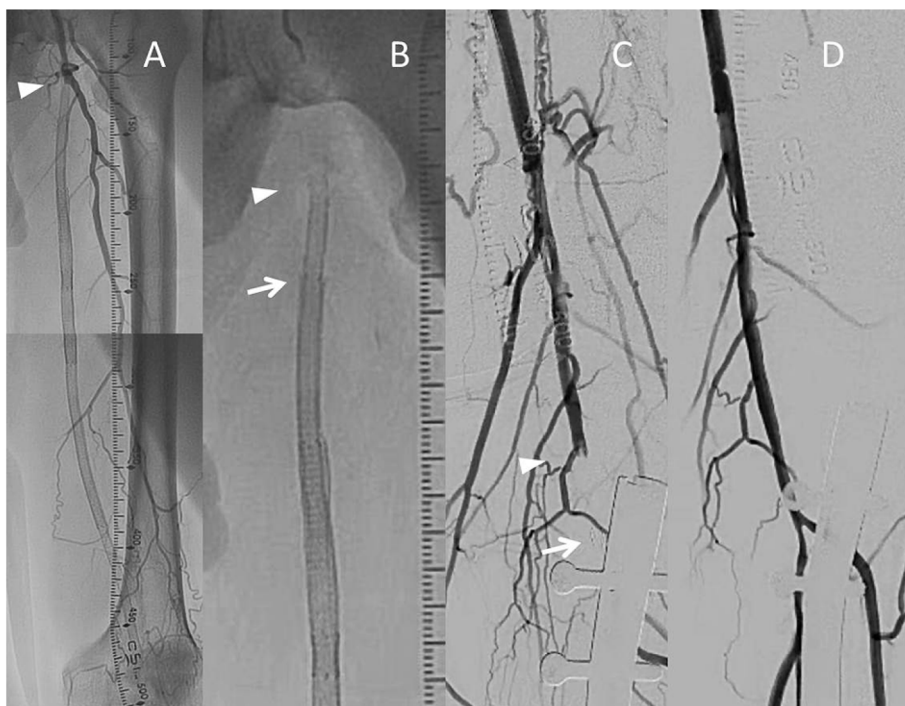

Fig. 1 Case 1 angiographic images. Angiography revealing total occlusion of three Viabahn endografts in the superficial femoral artery (A, B). Digital subtraction angiography revealing a filling defect in popliteal artery (arrowhead), above the filter (arrow) following utilization of the Jetstream XC device (C). Flow was effectively restored after filter removal and administration of intra-arterial vasodilators (D).

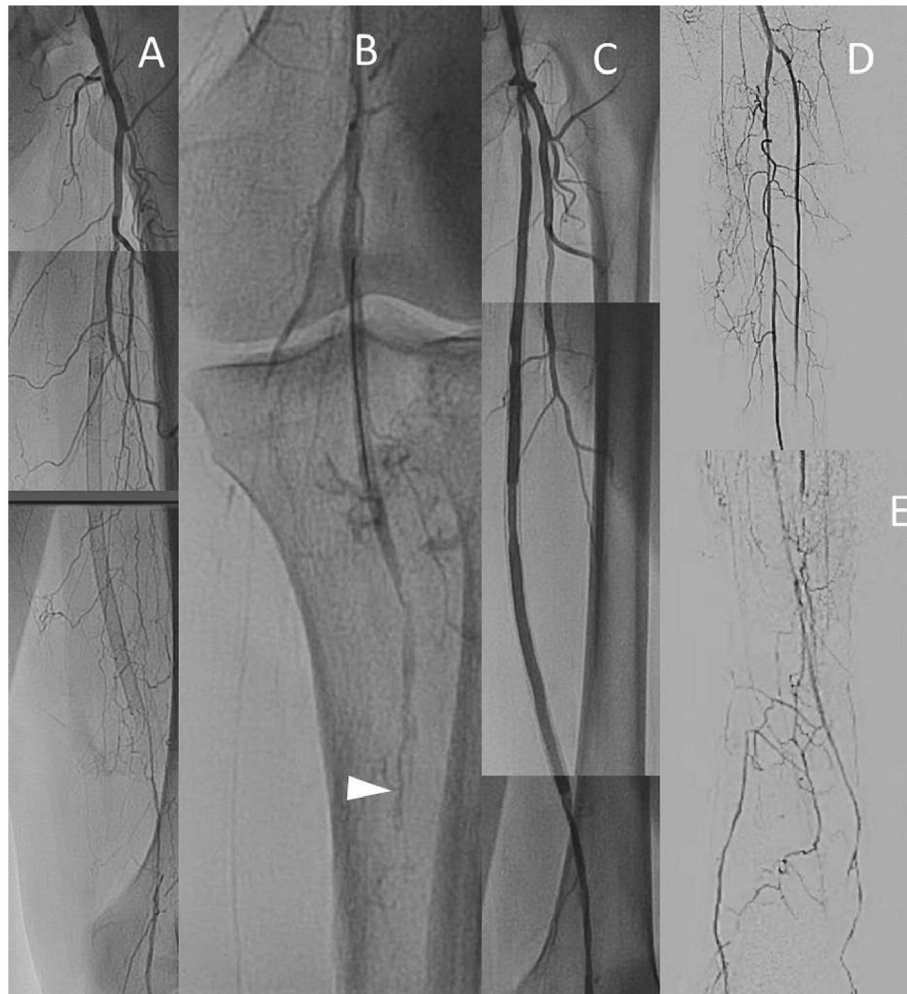


Fig. 2 Case 2 angiographic images. Angiography revealing total occlusion of three Viabahn endografts in the superficial femoral artery (**A**). Selective angiography revealing filling defects in the popliteal artery following Jetstream XC device utilization (**B**). Effective restoration of flow following mechanical thrombectomy of the distal filter, selective angioplasty of the popliteal and tibioperoneal arteries, and administration of intra-arterial vasodilators (**C–E**).

endovascular strategy that focused on limiting thrombolytic exposure. We positioned an Emboshield 0.014 NAV6 filter (Abbott Vascular, Santa Clara, CA, USA) in the distal left popliteal artery segment for embolic protection and delivered the Jetstream XC (2.1 mm/3.0 mm) device to the site of thrombosis (Boston Scientific, Marlborough, MA, USA). After performing mechanical aspiration thrombectomy of the occluded SFA and popliteal segments, follow-up angiography revealed no reflow distally in the popliteal segment with a filling defect just above the site of filter (**Fig. 2B**). Aspiration thrombectomy was performed with a Pronto V3 extraction catheter (Vascular Solutions, Minneapolis, MN, USA) followed by administration of intra-arterial vasodilator agents (200 μ g of nitroglycerin and 50 μ g sodium nitroprusside, as a bolus doses). After confirming improved flow to the distal vessels, atherectomy and drug coated balloon angioplasty of the Viabahn stent edges was performed (5.0 \times 40 mm, Bard Lutonix, New Hope, MN,

USA). The follow-up angiogram again demonstrated no reflow distally in the infrapopliteal vessels at which time the filter was removed, intra-arterial vasodilator agents were administered and selective balloon angioplasty of the tibio-peroneal and anterior tibial arteries was performed (2.0 \times 200 mm, SAVVY balloon catheter; Cordis Corp, Miami Lakes, FL, USA). The follow-up angiogram demonstrated brisk flow in the infrapopliteal vessels with no residual stenosis or filling defects in the SFA or popliteal arteries. The patient was discharged less than 24 hours from the time of presentation with Coumadin and antiplatelet therapy. Despite close monitoring during follow-up, she presented with acute thrombosis of the Viabahn endografts 7 months later. She was subsequently referred for femoral-popliteal bypass surgery.

Table 1 Indications, featured function and application details of Jetstream device

Total occlusion	Indication of Jetstream device			
	Thrombus	Calcified lesion	Soft plaque	Fibrous plaque
Featured function of the device				
Active aspiration	Front cutting	Atherectomy	Concentric lumen	Prevention of vessel rupture
Application of the device by the vessel diameter or lesion location				
Lesion location Vessel size	Device and diameter (Blade down/up)	Shaft length	Max guidewire diameter	Target RPM
Above the knee (Upper)	Jetstream XC (2.4 mm/3.4 mm)	120 cm	0.014"	70K
Above the knee (Lower/popliteal)	Jetstream XC (2.1 mm/3.0 mm)	135 cm	0.014"	70K
Below the knee	Jetstream SC 1.85 mm	145 cm	0.014"	73K
Below the knee	Jetstream SC 1.6 mm	145 cm	0.014"	73L

RPM: revolutions per minute

Discussion

In these cases, the Jetstream XC device was selected over alternative catheter directed thrombolytic strategies because it addressed two main factors pertinent to Viabahn endograft failure, namely edge stenosis and graft thrombosis.³⁾ Acute thrombosis is often preceded by edge stenosis or any significant inflow or outflow disease of the stent-graft. Recent histologic and intravascular ultrasound evidence has demonstrated that a large floating and fragile thrombus develops in the middle of the stent graft, flanked by more organized thrombus in the proximal and distal edges.⁴⁾ Traditionally, mechanical thrombectomy using Fogarty balloons either by the percutaneous or surgical method is a standard technique for acute thrombotic occlusion, however utilization of this technique for intimal hyperplasia or organized thrombus is difficult. The Jetstream XC device, with its ability to perform thrombectomy and atherectomy, would seem uniquely suited for this pathology (Table 1). By performing thrombectomy of the endograft, followed by atherectomy of the stent edges, rapid flow can be restored quickly. The conventional strategy of continuous intra-thrombus infusion of thrombolytic therapy through a catheter requires a longer period of time, as it typically requires monitoring in the intensive care unit followed by angiography 8–12 h later. It is here where the Jetstream XC device offers the advantage of being able to address these stent edges during the index procedure, obviating the need for a second follow-up angiogram.

The use of Viabahn stent-grafts in SFA disease has increased in recent years due to improved outcomes and patency rates observed in native vessel and restenotic disease. More recently however, there are growing concerns over the high rates of thrombosis (16–34%), which can often lead to acute limb ischemia and require urgent revascular-

ization.⁵⁾ Several trials have demonstrated that catheter-directed thrombolysis techniques are non-inferior to open surgical strategies with respect to acute limb salvage, and that catheter-directed thrombolysis in graft cases can be more effective than in native vessels.⁶⁾ However, the use of catheter-directed thrombolysis has also been associated with higher rates of distal embolization and bleeding. With the growing use of Viabahn stent-grafts for treatment of SFA restenotic disease, it remains unclear whether the strategies employed to revascularize the graft affect complication rates. In this respect, we describe the successful use of the Jetstream XC device for treatment of Viabahn stent graft thrombosis and propose that the dual capabilities of atherectomy and thrombectomy uniquely target the main determinants of this entity; edge restenosis and graft thrombosis. Furthermore, we propose that if the strategy is employed during the index procedure, it may reduce thrombolytic exposure time and potentially reduce length of stay. In the recently published study by Shammam et al., Jetstream atherectomy device used to treat femoropopliteal ISR revealed 9% distal embolization in a group having 25% of total occlusive disease.⁷⁾ Remarkably, in their report, 50% of patients had filters and debris were extracted from 81% of this group. Therefore, although it is not required, distal protection filter devices are recommended for FP ISR treatment or graft failure when using Jetstream device in long chronic occlusive lesions. A bolus intra-arterial injection of nitroglycerin or nitroprusside can also be helpful. These vasodilators will avoid spasm around the device and in the distal vessels. It is also helpful in avoiding dissection and/or mechanical obstruction of distal peripheral vasculature, which could lead to no reflow and acute limb ischemia. Many operators add vasodilators or heparin in the saline infusion bag during the atherectomy procedure, although there is no formal data or amount of medications used. In the earlier

data, Shammass et al. used 1 mg of nitroglycerin and 5 mg of verapamil in 1 liter saline flush bag.⁸⁾ While in our lab, we use Rotaglide as an optional lubricant in a 1 liter bag.

It is also important to recognize that the two illustrated cases developed repeat endograft failure within seven months of the index procedure with the Jetstream XC device. It seemed unlikely that re-occlusions were caused by Viabahn graft injury due to device-stent interaction. In a study of porcine stent/balloon injury model, there were no angiographic stent disruptions or stent strut discontinuity with intravascular ultrasound (IVUS) or high resolution radiography.⁹⁾ In rare cases, a graft or stent injury could be expected in the lesion with severe angulation. When a device encounters high resistance, device stall and wire entrapment would happen and can disrupt the atherectomy procedure.¹⁰⁾ However, our patients had a relatively straight course of the targeted vessel, we did not have any device-graft interaction. The etiologies for these recurrent presentations were likely multifactorial such as repetitive elongation between the foreign body and native vessel plus intimal hyperplasia. Additional studies are needed to confirm the safety and efficacy of the Jetstream XC device in Viabahn endograft failure. On the other hand, a change of strategy to bypass surgery would be required for the patients having recurrence of their disease.

Conclusion

In conclusion, the endovascular treatment of Viabahn stent-graft thrombosis should be approached methodically and with caution. The large thrombus burden conferred by these lesions can increase the risk for distal embolization during the index procedure and long term patency outcomes appear to vary across different treatment strategies. We propose that use of the Jetstream XC device with its dual atherectomy and thrombectomy capabilities, can effectively treat edge stenosis and graft thrombosis during the index procedure. Although the immediate benefits of reducing thrombolytic exposure time and length of stay remain attractive, additional studies are needed to determine long term patency outcomes.

Disclosure Statement

All authors have nothing to declare.

Author Contributions

Study conception: JL

Writing: TK, NC

Funding acquisition: none

Critical review and revision: all authors

Final approval of the article: all authors

Accountability for all aspects of the work: all authors

References

- 1) Geraghty PJ, Mewissen MW, Jaff MR, et al.; VIBRANT Investigators. Three-year results of the VIBRANT trial of VIABAHN endoprosthesis versus bare nitinol stent implantation for complex superficial femoral artery occlusive disease. *J Vasc Surg* 2013; **58**: 386-95.e4.
- 2) Saxon RR, Coffman JM, Gooding JM, et al. Long-term patency and clinical outcome of the Viabahn stent-graft for femoropopliteal artery obstructions. *J Vasc Interv Radiol* 2007; **18**: 1341-9; quiz, 1350.
- 3) Banerjee S, Sarode K, Mohammad A, et al. Femoropopliteal artery stent thrombosis: report from the excellence in peripheral artery disease registry. *Circ Cardiovasc Interv* 2016; **9**: e002730.
- 4) Winkler TA, Trerotola SO, Davidson DD, et al. Study of thrombus from thrombosed hemodialysis access grafts. *Radiology* 1995; **197**: 461-5.
- 5) Shackles C, Rundback JH, Herman K, et al. Above and below knee femoropopliteal VIABAHN®. *Catheter Cardiovasc Interv* 2015; **85**: 859-67.
- 6) Weaver FA, Comerota AJ, Youngblood M, et al. The STILE Investigators. Surgical revascularization versus thrombolysis for nonembolic lower extremity native artery occlusions: results of a prospective randomized trial. *J Vasc Surg* 1996; **24**: 513-21; discussion, 521-3.
- 7) Shammass NW, Shammass GA, Banerjee S, et al. JetStream rotational and aspiration atherectomy in treating in-stent restenosis of the femoropopliteal arteries: results of the JETSTREAM-ISR feasibility study. *J Endovasc Ther* 2016; **23**: 339-46.
- 8) Shammass NW. JETSTREAM atherectomy: a review of technique, tips, and tricks in treating the femoropopliteal lesions. *Int J Angiol* 2015; **24**: 81-6.
- 9) Shammass NW, Aasen N, Bailey L, et al. Two blades-up runs using the JetStream navitus atherectomy device achieve optimal tissue debulking of nonocclusive in-stent restenosis: observations from a porcine stent/balloon injury model. *J Endovasc Ther* 2015; **22**: 518-24.
- 10) Obon-Dent M and Hernandez-Vila E. Jetstream(R) atherectomy for subacutely or chronically occluded femoro-popliteal prosthetic bypass grafts: a report of three cases. *Catheter Cardiovasc Interv* 2013; **82**: E529-34.