

Case Report

An Intestinal Type Gastric Neuroendocrine Tumor: A Case Report

Mohammad Abu-Jeyyab^a Renata Kakish^b Malak Alkatib^a
Leen Alshwabkeh^a Rawan Bani Hamad^a Mary Almadani^a
Ma'wia Santarisi^c Mohammad Al-Jafari^a Abdulqadir J. Nashwan^d

^aSchool of Medicine, Mutah University, Al-Karak, Jordan; ^bSchool of Medicine, Hashemite University, Zarqa, Jordan; ^cDepartment of Surgery, Al-Basheer Hospital, Amman, Jordan; ^dHamad Medical Corporation, Doha, Qatar

Keywords

Neuroendocrine tumors · Carcinoma · Computed tomography · Neuroendocrine cells

Abstract

Neuroendocrine tumors (NETs) represent a diverse set of malignancies, originating from the neuroendocrine cells dispersed throughout the body. Their symptoms are associated with the secretion of bioactive peptides by tumor cells. Five-year survival rates depend on the disease stage: 93% for local, 74% for regional, and 19% for metastatic disease. This report describes a case involving a 64-year-old male patient, who was enduring high blood pressure and anemia. His symptomatology included frequent fainting and bloody vomiting without prior bleeding, coupled with persistent abdominal pain and weight loss. A complete blood count revealed microcytic anemia. His condition improved postoperatively after the transfusion of two units of packed red blood cells, normalizing all parameters. Further biochemistry and serology tests did not provide significant insights. However, an upper endoscopy unveiled a deep ulcer below the gastroesophageal junction with ulcer desquamation. A combination of clinical, laboratory, and radiographic data initially indicated a gastric carcinoma of the intestinal type, characterized by extensive extracellular mucin secretion. The surgical intervention led to the extraction of multiple tumors from lymph nodes, culminating in a postoperative diagnosis of a gastrointestinal (GI) mesenchymal tumor. NETs predominantly manifest in the GI tract, initiating primarily in the small intestine but can also originate in the stomach, appendix, colon, and other parts of the GI tract. Their development from neuroendocrine cells enables them to produce high concentrations of hormone-like substances such as neuropeptides and amines.

© 2023 The Author(s).
Published by S. Karger AG, Basel

Correspondence to:
Abdulqadir J. Nashwan, anashwan@hamad.qa

Introduction

Neuroendocrine tumors (NETs) are a heterogeneous group of tumors arising from widely distributed neuroendocrine cells throughout the body. The signs and symptoms of these tumors develop as a result of secreting bioactive peptides by the tumor cells [1, 2]. NET constitutes only 0.5% of all malignancies. The incidence is approaching 2/100,000. The two main primary sites are the GI tract (62–67%) and the lung (22–27%), other sites are the appendix and colon. Cases diagnosed with metastatic disease presented in 12–22% of cases. In the last decades, the percentage has been rising. This might be due to added awareness, enhanced diagnostic facilities, or a different criterion of which tumor should be considered as a NET. In most situations the cases are sporadic, but some cases are concomitant with the multiple endocrine neoplasia type I syndrome. The 5-year survival is determined by the stage: 93% in local disease, 74% in regional disease, and 19% in metastatic disease [3, 4]. The GI tract and pancreas are common primary sites for NETs. The predominant complaint by the patient is nonspecific symptoms for 1 year before the diagnosis. Presenting symptoms of gastroenteropancreatic NET are abdominal pain, bowel obstruction, diarrhea, flushing, and GI bleeding [5].

We report a case of a 64-year-old male patient diagnosed with gastric NET intestinal type as the primary disease, presented with metastasis to the hepatic artery lymph nodes and pancreas, the spleen was free of the tumor. The CARE Checklist has been completed by the authors for this case report, attached as online supplementary material (for all online suppl. material, see <https://doi.org/10.1159/000533761>).

Case Presentation

A 64-year-old male patient, who is a known case of hypertension and ischemic heart disease presented to the emergency department complaining of syncope preceded by hematemesis two times in 1 day prior to the presentation with no melena and no active bleeding. In addition to the mentioned history, the patient reported an association with chronic abdominal pain for 2 months and associated with significant weight loss. The patient was a regular smoker; moreover, he denied any family history of any kind of malignancies or endocrine diseases. The relevant clinical examination after resuscitation showed a soft lax abdomen with no scars' tenderness and masses, normal percussion, and normal bowel sound.

The patient had microcytic anemia with hemoglobin of 7.8 g/dL the normal range from 13.8 to 17.2 g/dL, mean corpuscular volume of 67.7 μm^3 normal range from 80 to 100 μm^3 , mean corpuscular hemoglobin of 22.5 pg the normal range from 26 to 33 pg, and mean corpuscular hemoglobin concentration of 33.2 g/dL the normal range 32–36 g/dL Table 1. Post-operation all laboratory results were corrected to normal ranges after he was given two units of packed red blood cells. Other biochemistry and serology tests were all normal.

Ultrasonography was also obtained which reported nonspecific findings – dilated stomach. After 2 days, upper endoscopy was performed showing an ugly deep ulcer below the gastroesophageal junction that was easy to bleed, multiple biopsies were taken. Abdominal computed tomography scanning with contrast was done to show the presence of a complex mass lesion seen in the tail of the pancreas measuring 6.8 × 6.5 cm with enhancing margins as shown in Figure 1.

Two weeks later, the stomach biopsy results were released showing an ulcerative slough and granulation tissue. The epithelium was showing moderate-high grade dysplasia. Up to this point, clinical, laboratory, and radiology findings were ultimately suggestive of a gastric neuroendocrine intestinal type tumor with abundant extracellular mucin secretion.

Table 1. Complete blood count (CBC) test results

	Result	Reference range
Hemoglobin, g/dL	7.8	13.8–17.2
Mean corpuscular volume, μm^3	67.7	80–100
Mean corpuscular hemoglobin, pg	22.5	26–33
Mean corpuscular hemoglobin concentration, g/dL	33.2	32–36

The patient was counseled for the management plan, all the treatment options were discussed clearly; however, he refused chemotherapy – imatinib. As a result, the surgeon decided to do partial gastrectomy, splenectomy, and distal pancreatectomy with multiple lymph node excisions to extract the tumors and the patient agreed. The postoperative biopsies confirmed the initial diagnosis; the postoperative diagnosis was GI stromal tumor. Postoperative recovery passed with surgical wound infection treated with a suitable vancomycin antibiotic.

Eight days postoperative the patient had a course of pulmonary embolism signs and symptoms such as fever tachycardia and tachypnea. The computed tomography angiogram showed multiple ground glass opacities with Atelectatic bands seen in the posterior aspect of both lower lobes, a small left-sided pleural effusion as shown in Figure 2. The case was managed according to the pulmonary medicine consultation. Figure 3 is shows the patient's case starting from the first presentation.

Discussion

Gastric cancer (GC) is the 5th most diagnosed cancer in the world and the 7th most prevalent [6]. The risk of developing gastric cancer from birth to age 74 is 1.87% in males and 0.79% in females worldwide. Males are more likely to be diagnosed with gastric cancer than females, in general. In addition to that, studies have shown that gastric cancer is 2.2 more in males in developed countries while the percentage in developing countries is 1.83 [7].

Stomach cancer is more common in developed than developing countries. The average incidence rate among high-middle human development index (HDI) nations is 20 per 100,000 for males, while the average rate among low-middle HDI nations is 6.6 per 100,000 [7], as we report a case of a male patient with gastric neuroendocrine cancer in Jordan.

NETs are tumors that arise from specialized cells that are called neuroendocrine cells, which have both the traits of nervous cells and endocrine cells that produce hormones. NET constitutes only 0.5% of all malignancies. The incidence is approaching 2/100,000. The two main primary sites are the GI tract (62–67%) and the lung (22–27%). Cases diagnosed with metastatic disease presented in 12–22% of cases [8]. NETs can occur anywhere in the body but more commonly originate in the endocrine pancreas, parathyroid, adrenal, pituitary glands, and calcitonin-producing cells of the thyroid (causing medullary thyroid carcinoma), and argentaffin cells of the gut (causing carcinoid tumors) [4]. So, we report a case of a 64-year-old male patient diagnosed with gastric NET intestinal type as the primary disease.

NETs are rare and can be broadly subdivided into those that produce excess hormones (functional NETs) and those that do not release hormones or do not release enough to cause symptoms (nonfunctional NETs). Most are malignant and metastasize commonly to the lymph nodes, and the liver or less commonly to bone, lung, brain, and other organs. Despite the widespread metastasis, these tumors are typically slow-growing and often present with no symptoms [9]. Our patient presented with metastasis to the hepatic artery lymph nodes and pancreas, the spleen was free of the tumor.

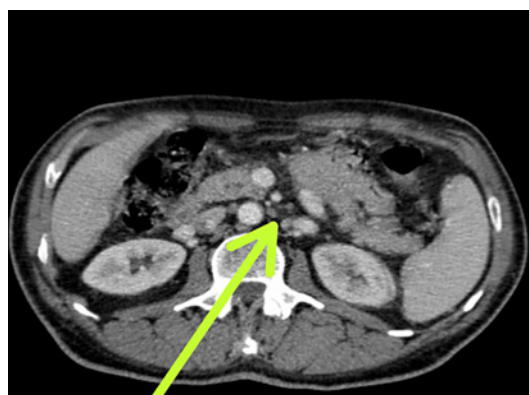

Fig. 1. Abdominal CT showing A Complex mass lesion in the tail of the pancreas.

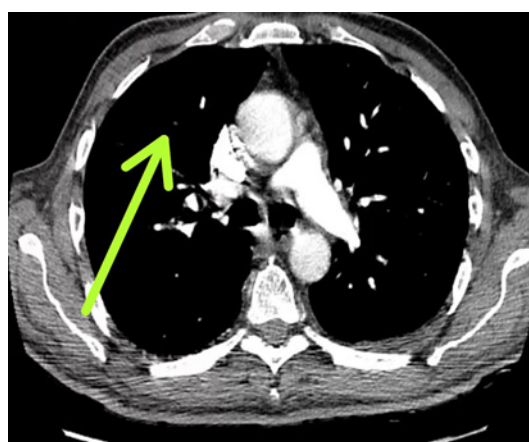


Fig. 2. Angiogram CT showing the evidence of pulmonary embolism.

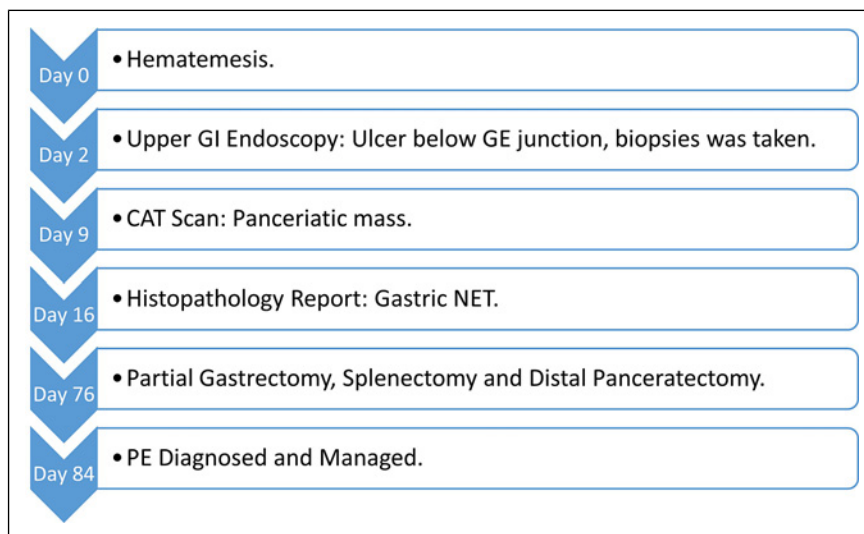


Fig. 3. A diagram showing the patient's case starting from the first presentation.

Gastric adenocarcinoma is classified into two major histological subtypes: intestinal and diffuse adenocarcinoma, according to Lauren's classification [10]. There are two gastric cancer subtypes based on their anatomic site: cardia (occurring in the 1 cm [about 0.39 in] proximal and 2 cm [about 0.79 in] distal area of the esophagogastric junction) and gastric

adenocarcinoma (CGA), such as our case. And non-cardia (distal: involving the distal and middle parts of the stomach) gastric adenocarcinoma (NCGA) [11].

Most cases of cardia gastric cancer are sporadic. However, lifestyle, H. Pylori infection, GERD, and multiple genetic, epigenetic, and environmental risk factors have been related to an increased risk of cardia gastric cancer [12].

In our case, the diagnosis was made by taking a biopsy of the stomach. Most of the previous cases of reported gastric cancer were diagnosed by gross specimens from surgeries. On the other hand, what differentiates our case is that gastric cancer was also associated with a complex mass lesion in the tail of the pancreas [13, 14].

The prognosis has been influenced by the anatomical site, disease stage, histology, age, sex, race, and geographic area. Also, because of the different classifications of NETs, prognostic factors remain a challenge. In previous studies, the survival rate for functional well-differentiated endocrine tumors of the GI tract was 52%, and 64% for nonfunctional. Nevertheless, the 5-year relative survival for the other sites was 30%. Furthermore, in previous studies, the 5-year survival according to the stage was 93% in local disease, 74% in regional disease, and 19% in metastatic disease, as in our case of a gastric NET that was metastasized to the hepatic artery lymph node and the pancreas [15–18].

Gastric NETs are usually treated by partial or total gastrectomy with local lymph node resection [19–21]. So, surgery is generally the way to treat all patients with operable well-differentiated metastases from NET regardless of the site of origin [22, 23]. As in our case, the patient was treated by partial gastrectomy, splenectomy, and distal pancreatectomy with multiple lymph node excisions. Although in another reported case of gastric neuroendocrine cancer, a splenectomy was also done [24]. Correspondingly, splenic metastasis is rare from (NETs) of the stomach. So, splenectomy in those cases is indicated for two reasons: first, in a case of metastasis of the spleen, and second, to prevent complications such as thrombosis of the splenic vein or a splenic rupture as has been done in our case to prevent those complications [25, 26].

Immunology and oncology fields were linked when the surgeon William Coley reported that an injection of killed bacteria into sites of sarcoma could lead to tumor shrinkage, in the late 19th century [27]. Efforts to improve treatment results beyond those obtained with surgery alone have included adjuvant and neoadjuvant approaches. Immunotherapy has determined unique long-term responses in several hematological and solid tumors. For instance, the use of immune checkpoint inhibitors may significantly increase the chance of achieving complete remissions in comparison with control treatments, as suggested by the MOUSEION-03 study [28]. The positive impact of such therapies on survival in cancer patients has become richer over time, although there is no agreement as to the best approach yet for patients with gastric cancer.

Cancer immunotherapies are affected by multiple factors, such as differences in anatomy, and gene expression levels on the sex chromosomes. Furthermore, the immune system is involved in the chronic oxidative and inflammatory stress conditions of aging, and sex-associated changes in immune response [29]. So, each case differs, and we still need more trials and studies for a clear guideline that we can follow.

The optimal way to integrate combined-modality therapy has not been definitively established yet and multiple factors play a role in choosing the treatment plan. The only approved targeted treatment for human epidermal growth factor receptor 2 (HER2)-positive gastric cancer for the past 10 years has been trastuzumab, a monoclonal antibody. Moreover, trastuzumab deruxtecan (T-Dxd) has been recently endorsed by the Food and Drug Administration (FDA) in the USA, adding to the available treatment options in this setting. Therapies targeting HER2 and programmed cell death 1 are also being investigated in combination with chemotherapy against gastric cancer, including margetuximab and ZW25, both being anti-HER2 antibodies [30].

GC patients with adequate performance status and organ function receiving combination chemotherapy have a median overall survival of approximately 1 year, compared with

approximately three to 4 months when treated with supportive care alone. Unfortunately, most gastric adenocarcinomas are indeed chromosomally unstable and have high levels of copy number changes, which correlate with immune exclusion [31].

In our case, we report the case of a 64-year-old male patient with a GI NET of the stomach and a complex mass lesion seen in the tail of the pancreas. Gastric NETs are generally treated with partial or total gastrectomy with local lymph node resection [23, 32]. So, the patient was treated with partial gastrectomy, splenectomy, and distal pancreatectomy with multiple lymph nodes excisions to extract the tumors. The postoperative biopsies confirmed the initial diagnosis of a GI stromal tumor; unfortunately, no immunohistochemistry was performed.

Conclusion

NETs are cancers that develop from the cells of the neuroendocrine system. These tumors might have several subtypes depending on the organ from which they arise. Our case involves one of the rarest forms of gastric NETs, the intestinal type, which originates in the stomach. This tumor was found not only in the stomach but also in various locations at the same time, which is unusual. It had also metastasized to the lymph nodes and is seldom impacted by this malignancy. As a result, our case demonstrated an uncommon and complex expression of an intestine-type gastric NET that necessitated a rigorous diagnosis and therapy.

Acknowledgments

This research was mentored and supervised by the Mutah Research and Audit Society (MRAS). The Qatar National Library funded the publication of this article.

Statement of Ethics

The article describes a case report. The Ethics Committee at Al-Basheer hospital waived ethical approval. Written informed consent was obtained from the patient for publication of this case report and any accompanying images.

Conflict of Interest Statement

The authors have no conflicts of interest to declare.

Funding Source

This study was not funded.

Author Contributions

M.A.-J., R.K., M.K., L.A., R.B.H., M.M., M.S., M.A., and A.J.N. have contributed to writing and reviewing the manuscript. All authors have read and approved the manuscript.

Data Availability Statement

All data generated or analyzed during this study are included in this article. Further inquiries can be directed to the corresponding author.

References

- 1 Clift AK, Kidd M, Bodei L, Toumpanakis C, Baum RP, Oberg K, et al. Neuroendocrine neoplasms of the small bowel and pancreas: a comprehensive review. *Neuroendocrinology*. 2020;110(6):444–76.
- 2 Raphael MJ, Chan DL, Law C, Singh S, Liu G. Principles of diagnosis and management of neuroendocrine tumours. *Can Med Assoc J*. 2017;189(10):E398–404.
- 3 Taal BG, Visser O. Epidemiology of neuroendocrine tumours. *Neuroendocrinology*. 2004;80(Suppl 1):3–7.
- 4 Volante M, Grillo F, Massa F, Maletta F, Mastracci L, Campora M, et al. Neuroendocrine neoplasms of the appendix, colon, and rectum: a comprehensive review from the Italian Association of Anatomic Pathology and Diagnostic Cytopathology (SIAPEC-IAP). *Pathologica*. 2021;113(1):19–27.
- 5 Andreasi V, Muffatti F, Guarneri G, Falconi M, Partelli S. Surgical principles in the management of pancreatic neuroendocrine neoplasms: an overview of current practice and future perspectives. *Curr Treat Options Oncol*. 2020;21(6):48.
- 6 Rawla P, Barsouk A. Epidemiology of gastric cancer: global trends, risk factors and prevention. *Prz Gastroenterol*. 2019;14(1):26–38.
- 7 Bray F, Ferlay J, Soerjomataram I, Siegel RL, Torre LA, Jemal A. Global cancer statistics 2018: GLOBOCAN estimates of incidence and mortality worldwide for 36 cancers in 185 countries. *CA Cancer J Clin*. 2018;68(6):394–424.
- 8 Clark OH, Benson AB 3rd, Berlin JD, Choti MA, Doherty GM, Engstrom PF, et al. NCCN clinical practice guidelines in oncology: neuroendocrine tumors. *J Natl Compr Canc Netw*. 2009;7(7):712–47.
- 9 Lauren P. The two histological main types of gastric carcinoma: diffuse and so-called intestinal-type carcinoma: an attempt at a histo-clinical classification. *Acta Pathol Microbiol Scand*. 1965;64(1):31–49.
- 10 Abdi E, Latifi-Navid S, Zahri S, Yazdanbod A, Pourfarzi F. Risk factors predisposing to cardia gastric adenocarcinoma: insights and new perspectives. *Cancer Med*. 2019;8(13):6114–26.
- 11 Okamoto T, Ogasahara K, Fujiki M, Takagi M, Ikeda H, Makino T, et al. Primary coexistent neuroendocrine carcinoma hepatoid adenocarcinoma and tubular adenocarcinoma of the stomach with focal trophoblastic differentiation in metastatic. *J Gastroenterol*. 2013;38(6):608–10.
- 12 Yasuda K, Fujiwara H, Nomura H, Sogo Y, Sakai K, Teramura K. A case of neuroendocrine cell carcinoma and poorly differentiated adenocarcinoma of the stomach in synchronous multiple cancer. *J Gastroenterological Surgery*. 2006;39(4):446–51.
- 13 Kim A, Kim SW, Song SK, Bae YK. Gastric adenocarcinoma with coexistent hepatoid adenocarcinoma and neuroendocrine carcinoma: a case report. *Korean J Pathol*. 2009;43(1):79–82.
- 14 Jung JH, Kim YC, Kim JH, Chung HS, Cheung DY, Kim JI, et al. A case of a gastric composite tumor with an adenocarcinoma and a large cell neuroendocrine carcinoma. *Korean Journal*. 2013;46(3):280–3.
- 15 Mróz A, Kiedrowski M, Malinowska M, Sopyło R. Collision tumour of the stomach-adenocarcinoma and neuroendocrine carcinoma: case report and review of the literature. *Pol J Pathol*. 2009;60(2):94–7.
- 16 Jang KY, Moon WS, Lee H, Kim CY, Park HS. Gastric collision tumor of large cell neuroendocrine carcinoma and adenocarcinoma—a case report. *Pathol Res Pract*. 2010;206(6):387–90.
- 17 Terada T, Maruo H. Simultaneous large cell neuroendocrine carcinoma and adenocarcinoma of the stomach. *World J Gastroenterol*. 2011;17(43):4831–4.
- 18 Miguchi MI, Iseki M, Shimatani K. Advanced gastric neuroendocrine carcinoma with an adenocarcinoma component. *Case Rep Gastroenterol*. 2012;6(1):52–7.
- 19 Nakayama Y, Higure A, Shibao K, Sato N, Matayoshi N, Yamaguchi K. Synchronous occurrence of early neuroendocrine carcinoma and tubular adenocarcinoma in the stomach. *Clin J Gastroenterol*. 2012;5(4):307–11.
- 20 Van Der Zwan JM, Trama A, Otter R, Larrañaga N, Tavilla A, Marcos-Gragera R, et al. Rare neuroendocrine tumours: results of the surveillance of rare cancers in Europe project. *Eur J Cancer*. 2013;49(11):2565–78.
- 21 Gilligan CJ, Lawton GP, Tang LH, West AB, Modlin IM. Gastric carcinoid tumors: the biology and therapy of an enigmatic and controversial lesion. *Am J Gastroenterol*. 1995;90(3):338–52.
- 22 Plöckinger U, Rindi G, Arnold R, Eriksson B, Krenning EP, de Herder WW, et al. European neuroendocrine tumour society. guidelines for the diagnosis and treatment of neuroendocrine gastrointestinal tumours. A consensus statement on behalf of the European Neuroendocrine Tumour Society (ENETS). *Neuroendocrinology*. 2004;80(6):394–424.
- 23 Delle Fave G, Kwেকেboom DJ, Van Cutsem E, Rindi G, Kos-Kudla B, Knigge U, et al. ENETS Consensus Guidelines for the management of patients with gastroduodenal neoplasms. *Neuroendocrinology*. 2012;95(2):74–87.

- 24 Pavel M, Baudin E, Couvelard A, Krenning E, Öberg K, Steinmüller T, et al. ENETS consensus guidelines for the management of patients with liver and other distant metastases from neuroendocrine neoplasms of foregut midgut hindgut and unknown primary. [Neuroendocrinology](#). 2012;95(2):157–76.
- 25 Kubota K, Okada A, Kuroda J, Yoshida M, Ohta K, Adachi M, et al. Neuroendocrine carcinoma of the stomach: a case study. [Case Rep Med](#). 2011;2011:948328.
- 26 Sninate S, Allioui S, Tbouda M, Razine S, Jerguigue H, Latib R, et al. Splenic metastasis from neuroendocrine tumor of the stomach: a case report. [Radiol Case](#). 2021;16(11):3438–41.
- 27 Coley WB, The treatment of malignant tumors by repeated inoculations of erysipelas: with a report of ten original cases. [Am J Med Sci](#). 1893;105(6):487.
- 28 Santoni M, Rizzo A, Kucharz J, Mollica V, Rosellini M, Marchetti A, et al. Complete remissions following immunotherapy or immuno-oncology combinations in cancer patients: the MOUSEION-03 meta-analysis. [Cancer Immunol Immunother](#). 2023 Jun;72(6):1365–79.
- 29 Santoni M, Rizzo A, Mollica V, Matrana MR, Rosellini M, Faloppi L, et al. The impact of gender on the efficacy of immune checkpoint inhibitors in cancer patients: the MOUSEION-01 study. [Crit Rev Oncol Hematol](#). 2022 Feb; 170:103596.
- 30 Ricci AD, Rizzo A, Rojas Llimpe FL, Di Fabio F, De Biase D, Rihawi K. Novel HER2-directed treatments in advanced gastric carcinoma: AnotHER paradigm shift? [Cancers](#). 2021 Apr 1;13(7):1664.
- 31 Ricci AD, Rizzo A, Brandi G. DNA damage response alterations in gastric cancer: knocking down a new wall. [Future Oncol](#). 2021 Mar;17(8):865–8.
- 32 Gilligan CJ, Lawton GP, Tang LH, West AB, Modlin IM. Gastric carcinoid tumors: the biology and therapy of an enigmatic and controversial lesion. [Am J Gastroenterol](#). 1995 Mar;90(3):338–52.