

Case Report

Simultaneous false aneurysm and arterio-venous fistula in the presence of a single wound

G.N. Ayane^{a,*}, M. Walsh^a, D. Prozesky^b, K. Kadimo^c

^a Department of Surgery, Faculty of Medicine, University of Botswana, Botswana

^b Department of Medical Education, Faculty of Medicine, University of Botswana, Botswana

^c Department of Library Services, University of Botswana, Botswana

ARTICLE INFO

Keywords:

False aneurysm
Arteriovenous fistula (AVF)
Computed tomography angiography (CTA)
Vascular surgery

ABSTRACT

We describe a patient in whom a stab wound to the right supraclavicular fossa led to a subclavian artery false aneurysm and an arterio-venous fistula (AVF) between the right subclavian artery and the right internal jugular vein. The diagnosis was made clinically and with computerised tomographic angiography (CTA). Open vascular repair was successful. We postulate that this presentation was the result of the knife being inserted then partly withdrawn and reinserted at a different angle. This pattern of injury has been reported previously following central venous line insertion, but rarely following a stab injury.

Case report

A 29 year old male sustained a stab wound, five years previously, to the right supraclavicular fossa, 2 cm above the clavicle and close to the lateral border of sternocleidomastoid. The patient had been asymptomatic until a single episode of loss of consciousness three weeks before presentation. The patient was assessed in a district hospital where ultrasound confirmed the presence of a false aneurysm. He was transferred to the referral hospital. On arrival the patient was clinically stable. Physical examination findings included a single 2 cm scar in the right supraclavicular fossa with an underlying mass which was 3 cm in diameter, smooth, non-tender, pulsatile, expansile and with a machinery murmur. CTA confirmed the diagnosis of a false aneurysm of the right subclavian artery and an AVF between the right subclavian artery and internal jugular vein (Fig. 1).

The patient underwent open surgical repair. The intra-operative findings were of a 1 cm defect in the superior surface of the second part of the subclavian artery, resulting in a false aneurysm of 2 cm by 3 cm passing superiorly and medially and connected with a 1 cm defect in the lateral surface of the right internal jugular vein in zone 2 of the neck to form the AVF. The internal jugular vein from the level of the aneurysm down was widely dilated and pulsatile.

The subclavian artery and internal jugular vein were controlled either side of their connections with the false aneurysm and the sac was opened. The defect in the subclavian was repaired with an autologous long saphenous vein patch to avoid narrowing the lumen and the defect in the internal jugular vein was directly sutured. The patient was discharged three days later with normal physiological parameters. Follow-up as an outpatient confirmed a successful outcome and he was discharged.

In this case a false aneurysm and an AV fistula resulted from a single penetrating wound with anatomically distant injuries to the right subclavian artery and internal jugular vein. The opening in the vein was perpendicular to and relatively distant from that in the

* Corresponding author.

E-mail addresses: Gezahen.ayane@mopipi.ub.bw (G.N. Ayane), Michael.walsh@mopipi.ub.bw (M. Walsh), prozeskyd@UB.AC.BW (D. Prozesky), Khutsafalo.kadimo@mopipi.ub.bw (K. Kadimo).

<https://doi.org/10.1016/j.tcr.2018.07.004>

Accepted 16 July 2018

Available online 19 July 2018

2352-6440/ © 2018 Published by Elsevier Ltd. This is an open access article under the CC BY-NC-ND license (<http://creativecommons.org/licenses/by-nc-nd/4.0/>).

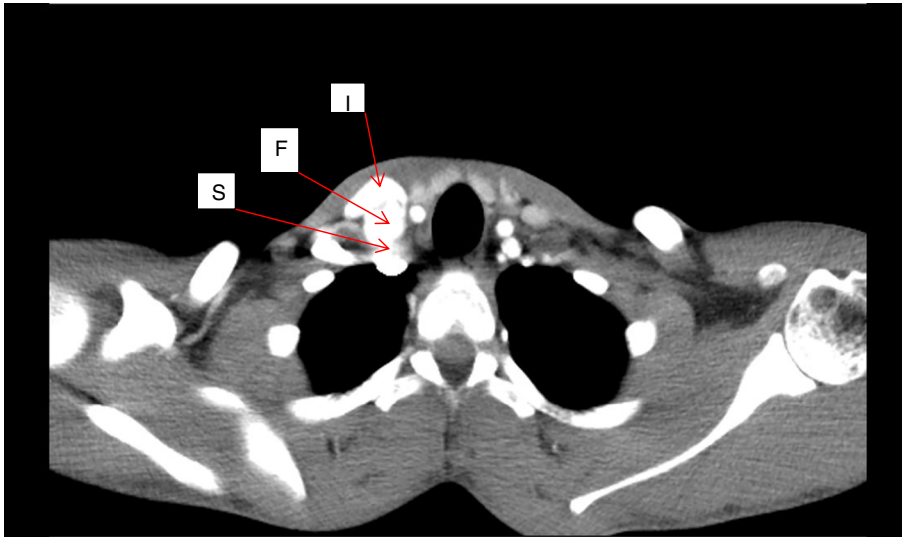


Fig. 1. CT angiogram in the arterial phase demonstrating the early filling and dilatation of the internal jugular vein(I), the sac of the false aneurysm (F) and the subclavian artery pushed posteriorly by the aneurysm sac(S).

artery. This raises the question of how a single skin entry wound could have caused the dual injuries. To explain this paradox we postulate that the sharp instrument was partly withdrawn during the attack and reinserted at a different angle. The initial vertical thrust would have caused the perforation of the subclavian artery, and a second, more medially directed, the perforation of the internal jugular vein. A false aneurysm involving the subclavian artery with an AVF to the internal jugular vein has been reported commonly following central venous line insertion. To our knowledge this pattern of injury following a single stab wound is very unusual.

Discussion

Traumatic AVF fistulae and false aneurysms have been known for centuries. In 1762 William Hunter described the pathophysiology associated with an AV fistula and the management of this problem has challenged many surgeons [1,2]. In addition to case reports from the 19th century there have been published series from wartime experience acquired from treating and diagnosing AVF and false aneurysms during World War II, Vietnam and Korean wars [1,3,4]. Combined false aneurysms and AV fistulae accounted for 7% of the casualties in Vietnam [2,4].

The standard treatment of quadruple ligation of AVF was introduced by surgeons such as Halsted and Holman at the beginning of the twentieth century [2,4,5]. Subsequent advances increased the feasibility of immediate repair of acute arterial injuries: experiences in treating war injuries, the development of new vascular surgery techniques, and non-invasive investigation. These advances decreased the prevalence of chronic post-traumatic AVF as well false aneurysms [6]. When AVF and false aneurysms have developed after vascular injury, restoration of arterial anatomical continuity is now the gold standard treatment [4,5,7].

When classifying aneurysms the first distinction to be drawn is between ‘true’ and ‘false’. True aneurysms involve all three layers of the arterial wall. False aneurysms are differentiated from true aneurysms by the presence of blood flow outside the normal layers of the arterial wall. The wall of the false aneurysm is therefore composed of compressed surrounding fibrotic tissue, not arterial wall [5,8,9]. Common causes of false aneurysm are post-invasive vascular manipulations (catheterization), vascular surgery (synthetic graft anastomosis), post-traumatic (from blunt or penetrating injury), infection (e.g. syphilitic, mycotic and HIV) [5,7] and intravenous drug abuse [5,7].

A number of classification schemes for AVF and AV shunts exist [10], based on: location (e.g. in the cranium), congenital or acquired, and the arterial blood flow rate [11]. In the present case the fistula must have been acquired and may well have allowed substantial shunting, as witness the episode of syncope. Traumatic AVF caused by penetrating trauma account for as many as 90% of cases. Blunt trauma is more rarely the cause and it is responsible for the remaining 10%. Gunshot wounds are the most frequent traumatic incidents, but stab wounds and iatrogenic lesions also account for traumatic AVF [1,2,4,5,7,11–15].

In the current case both pathologies appear to have been caused by a penetrating injury in the right supraclavicular fossa.

False aneurysms present as pulsatile, expansile swellings, and may be mistaken for abscesses particularly in view of their tendency to expand. Clinical examination of AVF shows a pathognomonic triad: palpable tumefaction, thrill above this change, and continuous systolic-diastolic murmur on auscultation [1,2,5,12,14,16]. In the current case the expansile, pulsatile mass indicated a false aneurysm; the machinery-like murmur alerted us to the possibility of a concurrent AV fistula. A further pointer was the reported episode of syncope, which may have been due to decreased blood flow in the carotid system.

The major complication of false aneurysms is spontaneous rupture. The risk of rupture is related to the size (3 or more cm),

presence of symptoms, a large hematoma, or continued growth [1,2,17]. The long-term presence of AV fistulae can lead to numerous systemic complications [1,4,12,15]. Increased blood flow through a wide AV fistula can lead to strain of the heart and consequent coronary insufficiency [1,2,4,11,15,17]. Fistulae affecting the extremities may lead to sign of venous hypertension, varicosities, pain and limb overgrowth [2,4,16,17]. In the present case none of these complications were present.

Diagnosis of traumatic AVF and false aneurysm is based on careful anamnesis, clinical examination and the application of non-invasive and invasive diagnostic methods. Accurate clinical anatomical delineation can be difficult and is often dependent on imaging. Arteriography was the main modality of examination until recently and may still play an important role in diagnosing AV fistulae and false aneurysms [5,9,14–16,18]. At the present time CTA, magnetic resonance imaging (MRI) and colour Doppler with spectral analysis play an important role in the diagnosis of these pathologies [4,5,9,14,15]. In this case the clinical examination pointed to a dual pathology which was confirmed by CTA, whereas the ultrasound only demonstrated the false aneurysm.

There are several options for the management of false aneurysms [1,2,5,7,11–13,15,17]. Surgical intervention was the gold standard for treatment previously and still has an important place. Open surgical ligation or repair may be performed with or without distal bypass, depending on whether the artery is expendable or lacks sufficient collaterals [1,2,4,5,12,13,16,17,19].

Brooks first described the use of endovascular techniques for treatment in 1930 [7]. Endovascular techniques include selective arterial embolization using a variety of agents [4,7], permanent balloon occlusion of the feeding vessel [12], ultrasound-guided thrombin injection into the aneurysm sac [1,4] and placing a covered stent-graft across the opening in the wall of the artery to prevent it from receiving blood flow, resulting in thrombosis of the false aneurysm [1,2,4,6,12–14,17,20]. The advantages of the endovascular approach are the less invasive remote access, less blood loss, shorter hospital stay and subsequent lower cost. These techniques require careful judgement in selecting the most appropriate method taking into account the position, size of the sac and arterial defect and the arterial run-off. The endovascular approaches have potential risks including false aneurysm formation at the site of arterial puncture, embolization and thrombosis.

Non-invasive techniques include ultrasound-guided compression [7] in which an ultrasound probe is used to identify the defect in the arterial wall leading to the false aneurysm sac. The probe is then pushed firmly against the patient's skin to compress the neck of the false aneurysm for 20 min, by which time the blood in the cavity of the aneurysm has clotted. This technique is limited to small, superficial, false aneurysms with necks of 5 mm diameter or less.

The main goal of any AVF or false aneurysm repair is the complete obliteration of the defect and restoration of normal blood flow. Traditionally treatment has been surgical; however more recently endovascular methods have been successfully used. In this particular case minimally invasive or endovascular procedures were not considered because of possible risks of embolization of coils or thrombin given the fistula and the possible risk of future stent fracture related to possible compression of the subclavian artery between the clavicle and first rib. Long term follow up would also be difficult. We therefore opted for a surgical approach.

Teaching points

1. False aneurysm and AVF can occur together.
2. An AVF can be formed between anatomically distant vessels following penetrating injuries.
Most commonly this is described following internal jugular central line insertion. Unusually this occurred following a single stab injury in the supraclavicular fossa.
3. A successful outcome for the management of a combined AVF and false aneurysm requires careful anatomical delineation of the affected vessels, using appropriately selected investigations and selecting a treatment modality which takes into account the anatomy of the involved vessels, fistula and false aneurysm and the patient's circumstances.

Conflict of interest

No conflict of interest.

References

- [1] N. Ili, M. Jovanovi, Z. Damjanovi, G. Stanojevi, Surgical Procedure in Isolated Traumatic Arteriovenous Fistula Between External Iliac Artery and Vein, 28 (2011), pp. 245–249.
- [2] T. Anbessa, A. Ababa, Traumatic arteriovenous fistulas and aneurysms at the Tikur Ambessa hospital, Addis Ababa, East Cent. Afr. J. Surg. 6 (1996) 1–4 [Internet]. Association of Surgeons of East Africa and College of Surgeons of East Central and Southern Africa. Available from: <http://www.bioline.org.br/request?js01002>.
- [3] R.W. Franz, Delayed treatment of a traumatic left subclavian artery pseudoaneurysm, Vasc. Endovasc. Surg. 42 (2008) 482–485 [Internet]. Available from: <http://ves.sagepub.com/content/42/5/482.short>.
- [4] C.G. Mulatti, B.A. Queiroz, S.E. Da Silva, S. Tjoumakaris (Ed.), Traumatic Arteriovenous Fistula, 40 InTech, 2013, pp. 506–510 Chirurg. [Internet]. Available from: <http://www.intechopen.com/books/arteriovenous-fistulas-diagnosis-and-management/traumatic-arteriovenous-fistula>.
- [5] J. Khoshnevis, M.R. Sobhiyeh, M.F. Zavareh, Deep femoral artery branch pseudoaneurysm after orthopedic procedure requiring surgical treatment: a case report, Trauma Mon. 17 (2012) 305–308.
- [6] R.M. Fairman, L. Nolte, S.A. Snyder, T.A. Chuter, R.K. Greenberg, S. Francisco, Factors predictive of early or late aneurysm sac size change following endovascular repair, J. Vasc. Surg. 43 (2006) 649–656.
- [7] J. Rennert, M. Seiz, C. Nimsky, A. Doerfler, Endovascular treatment of traumatic high flow dural arterio-venous fistula involving the middle meningeal artery and facial veins, Rontgenpraxis 56 (2008) 164–168 [Internet]. Available from: [http://www.embase.com/search/results?subaction=viewrecord{&}from=export{&}id=L351734510\\$&#http://dx.doi.org/10.1016/j.rontge.2006.10.002{&}\\$&# http://sfx.library.uu.nl/utrecht?sid=EMBASE{&}jissn=00357820{&}id=doi:10.1016/j.rontge.2006.10.002{&}\\$&#atitle=Endovaskuläre+Versorg](http://www.embase.com/search/results?subaction=viewrecord{&}from=export{&}id=L351734510$&#http://dx.doi.org/10.1016/j.rontge.2006.10.002{&}$&# http://sfx.library.uu.nl/utrecht?sid=EMBASE{&}jissn=00357820{&}id=doi:10.1016/j.rontge.2006.10.002{&}$&#atitle=Endovaskuläre+Versorg).
- [8] G.N. Kouvelos, N.K. Papas, E.M. Arnaoutoglou, G.S. Papadopoulos, M.I. Matsagkas, Endovascular repair of profunda femoral artery false aneurysms using

- covered stents, *Vascular* 19 (2011) 51–54 [Internet]. Available from: <http://www.ncbi.nlm.nih.gov/pubmed/21489928>.
- [9] L. Zhang, J.K. Yin, Y.Y. Duan, Y.F. Liu, X. Liu, Neck mass caused by spontaneous arteriovenous fistula of the superior thyroid artery to its homonymic accompanying vein by duplex ultrasonography, *EJVES Extra* 19 (2010) e51–e54 [Internet]. Elsevier Ltd. Available from: <http://linkinghub.elsevier.com/retrieve/pii/S1533316710000075>.
- [10] S.H. Fatimi, R. Deedar-Ali-Khawaja, S.K. Niazi, Z. Luqman, Late concomitant pseudoaneurysm and arteriovenous fistula of the subclavian artery: a developing country perspective, *Vasc. Endovasc. Surg.* 44 (2010) 503–505.
- [11] M. Chaudry, W.R. Flinn, K. Kim, D.G. Neschis, Traumatic arteriovenous fistula 52 years after injury, *J. Vasc. Surg.* 51 (2010) 1265–1267 [Internet]. Available from: <http://www.sciencedirect.com/science/article/pii/S0741521409024537>.
- [12] J.Y. Ahn, Y.S. Chung, B.H. Lee, S.W. Choi, O.J. Kim, Stent-graft placement in a traumatic internal carotid-internal jugular fistula and pseudoaneurysm, *J. Clin. Neurosci.* 11 (2004) 636–639.
- [13] F. Li, S. Zhu, Y. Liu, Y. Chen, L. Chi, G. Chen, et al., Traumatic arteriovenous fistula of the superficial temporal artery, *J. Clin. Neurosci.* 14 (2007) 595–600 [Internet]. Available from: <http://www.ncbi.nlm.nih.gov/pubmed/17379525>.
- [14] P.K. Ssenyonga, Feuvre D. Le, A. Taylor, D. Le Feuvre, A. Taylor, Head and neck neurovascular trauma: clinical and angiographic correlation, *Interv. Neuroradiol.* 21 (2015) 108–113 [Internet]. Available from: <http://www.ncbi.nlm.nih.gov/pubmed/25934784>.
- [15] K. Nagpal, K. Ahmed, R. Cuschieri, Diagnosis and management of acute traumatic arteriovenous fistula, *Int. J. Angiol.* 17 (2008) 214–216 [Internet]. Available from: <http://www.pubmedcentral.nih.gov/articlerender.fcgi?artid=2728918&tool=pmcentrez&rendertype=abstract>.
- [16] A. Megalopoulos, S. Siminas, G. Treloupoulos, Traumatic pseudoaneurysm of the popliteal artery after blunt trauma: case report and a review of the literature, *Vasc. Endovasc. Surg.* 40 (2007) 499–504 [Internet]. Available from: <http://ves.sagepub.com/cgi/doi/10.1177/1538574406290037>.
- [17] K. Konner, N.B. Daniel, E. Ritz, G. Editor, K. Konner, B. Nonnast-Daniel, et al., The arteriovenous fistula, *J. Am. Soc. Nephrol.* 14 (2003) 1669–1680 [Internet]. Available from: <http://www.jasn.org/cgi/doi/10.1097/01.ASN.0000069219.88168.39>.
- [18] S.M. Maher, H.M. Rabee, Mohammed S. Takrouri, M.M. Al-Salman, Traumatic arteriovenous fistula, *Ann. Thorac. Surg.* 63 (1997) 1792–1794.
- [19] S.Y. Chan, C.K. Chan, S.M. Hou, C.F. Ng, Mid-thigh arteriovenous graft in lower extremity vascular access construction for hemodialysis patients, *Hong Kong J. Nephrol.* 9 (2007) 86–88.
- [20] D.F. Toit, A.V. Lambrechts, H. Stark, B.L. Warren, S. Africa, D.F. du Toit, et al., Long-term results of stent graft treatment of subclavian artery injuries: management of choice for stable patients? *J. Vasc. Surg.* 47 (2008) 739–743.