

# An All-Arthroscopic Technique for Complex Posterolateral Corner Reconstruction



Jan Philipp Kolb, M.D., Jannik Frings, M.D., Matthias Krause, M.D., Maximilian Hartel, M.D., and Karl Heinz Frosch, M.D.

**Abstract:** Injuries to the posterolateral corner (PLC) often result in lateral, rotational, and dorsal instability, which need appropriate and differentiated treatment. Besides posterior cruciate ligament reconstruction for posterior instability, the technique according to LaPrade et al. efficiently stabilizes posterolateral rotational and lateral instability as described in Fanelli type B or C injuries. This technique has been exclusively used as an open procedure. In this article, we present an all-arthroscopic technique for the posterolateral stabilization procedure. To achieve this, 5 different arthroscopic portals are needed. The PLC is visualized by a trans-septal approach. Directly posterior to the popliteal tendon, arthroscopic preparation is started and the medial part of the fibular head is exposed. Two anatomic drill channels are placed in the lateral femoral condyle, with one tibial channel in the distal third of the sulcus popliteus and one channel in the fibular head. The popliteal tendon, popliteofibular ligament, and lateral collateral ligament are reconstructed with autologous hamstring tendons. The advantages of an all-arthroscopic anatomic PLC reconstruction are the protection of the soft tissues and the precise anatomic tunnel placement under direct visualization. The described procedure is a safe and anatomic method for posterolateral stabilization.

Injuries to the posterolateral corner (PLC) are frequently missed and are often not treated in an appropriate fashion.<sup>1-3</sup> As a result, chronic posterolateral rotational instability is noted in such cases.<sup>1</sup> Recently, the complex anatomy was analyzed and understood.<sup>4</sup> Lateral instability, rotational instability, and dorsal instability need to be separately diagnosed, as well as differentiated, and have to be appropriately treated. The PLC provides the primary stability against varus forces as well as against external rotation of the knee. These structures were also found to be important as secondary stabilizers to anterior and posterior tibial translation.<sup>5</sup>

The lateral collateral ligament (LCL) and the popliteal complex are the most important structures of the PLC.<sup>6,7</sup> The popliteal complex consists of the popliteal muscle-tendon unit and the arcuate complex, which includes the popliteofibular ligament (PFL), the fabellofibular ligament, and the popliteomeniscal fibers.<sup>7</sup>

The popliteal tendon and the PFL are the main static stabilizers of the PLC against external rotation.<sup>5,7,8</sup> They also stabilize against posterior translation.<sup>6,7</sup> The LCL mainly stabilizes against varus stress.

Apart from the popliteal bypass technique, which stabilizes mainly against external rotation, an LCL repair is necessary to stabilize lateral (varus) instability as seen in Fanelli type B or C injuries.<sup>7,9</sup> Both LaPrade et al.<sup>6</sup> and Arciero<sup>10</sup> described open surgical techniques for an anatomic posterolateral knee reconstruction,<sup>7,9</sup> with similar biomechanical results. Frings et al.<sup>11</sup> already described an all-arthroscopic technique according to Arciero. This article presents an all-arthroscopic technique for anatomic posterolateral knee reconstruction.<sup>4,12</sup>

## Indication

The described surgical technique should be used in PLC injuries with lateral, dorsal, and rotational instabilities. The technique efficiently stabilizes instabilities as described in Fanelli type B or C injuries.

From the Department of Trauma, Hand and Reconstructive Surgery, Universitätsklinikum Hamburg-Eppendorf, Hamburg, Germany.

The authors report the following potential conflicts of interest or sources of funding: J.P.K., J.F., M.K., M.H., and K.H.F. receive nonfinancial support from Universitätsklinikum Hamburg-Eppendorf. Full ICMJE author disclosure forms are available for this article online, as [supplementary material](#).

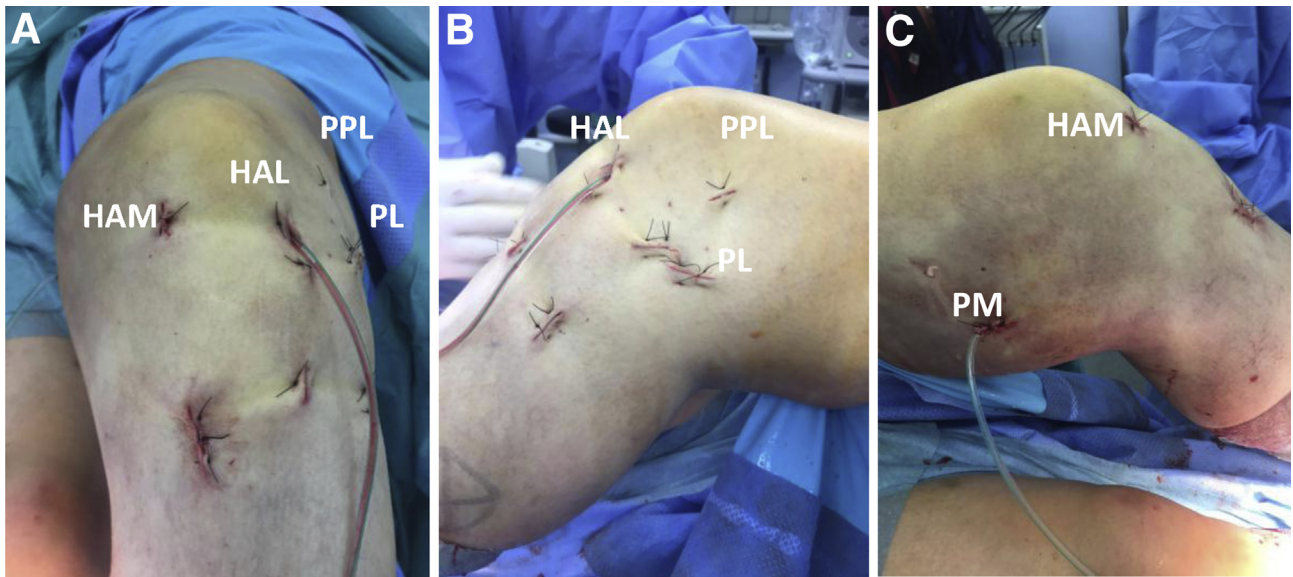
Received March 5, 2019; accepted May 6, 2019.

Address correspondence to Karl Heinz Frosch, Trauma, Hand and Reconstructive Surgery, Universitätsklinikum Hamburg-Eppendorf, Martinistraße 52, 20246 Hamburg, Germany. E-mail: [k.frosch@uke.de](mailto:k.frosch@uke.de)

© 2019 by the Arthroscopy Association of North America. Published by Elsevier. This is an open access article under the CC BY-NC-ND license (<http://creativecommons.org/licenses/by-nc-nd/4.0/>).

2212-6287/19289

<https://doi.org/10.1016/j.eats.2019.05.010>



**Fig 1.** Anterior (A), lateral (B), and medial (C) views of a left knee after surgery with the 5 needed arthroscopic portals: high anterolateral (HAL), high anteromedial (HAM), posteromedial (PM), posterolateral (PL), and parapatellar lateral (PPL).

### Patient Positioning

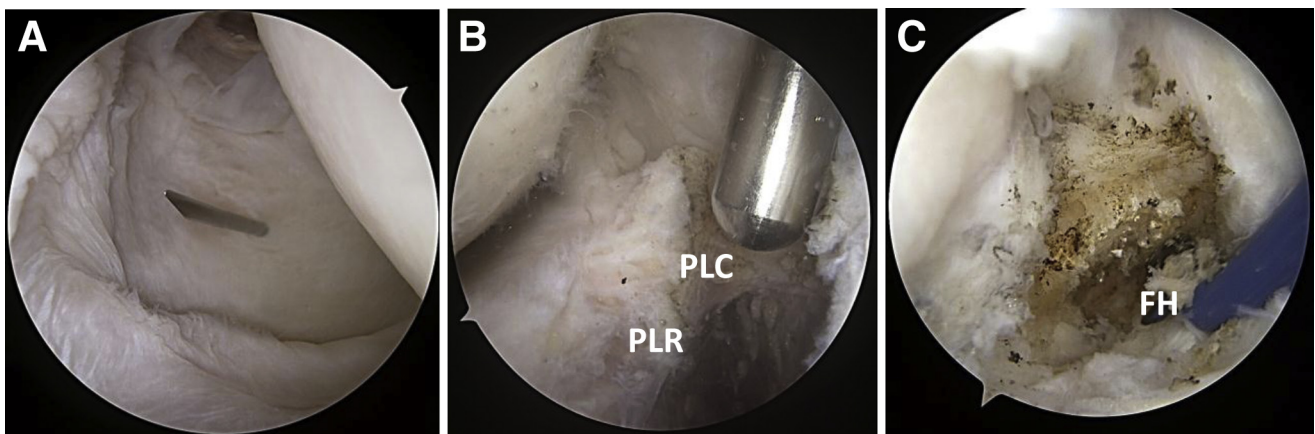
The patient is placed in the supine position. The leg is placed in a leg holder with a nonsterile tourniquet around the thigh and is prepared in a standard sterile fashion.

### Surgical Technique

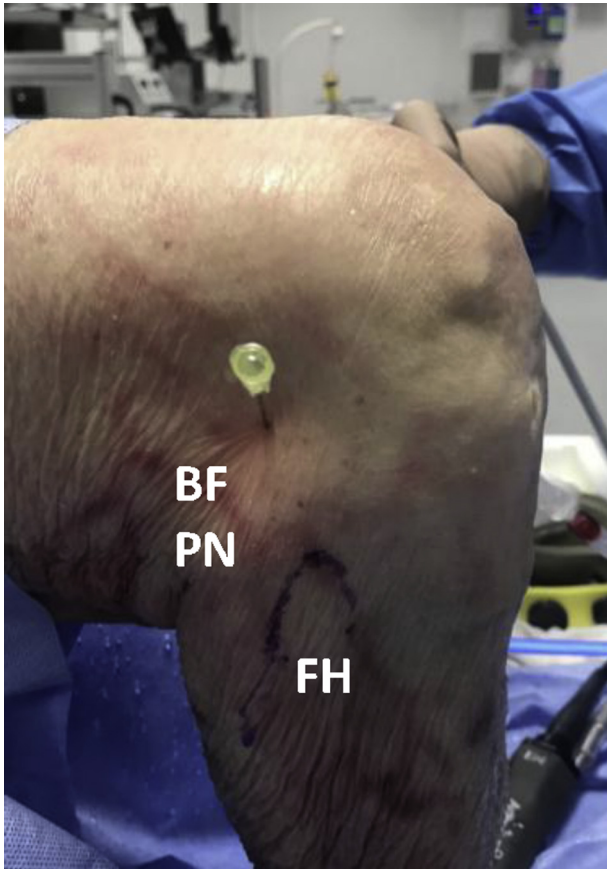To perform the surgical technique,<sup>4,8</sup> the posteromedial aspect of the fibular styloid with the PFL and the posterolateral aspect of the tibia, the tibial popliteal sulcus (located at the

musculotendinous junction of the popliteus), and the attachment site of the fibular collateral ligament on the lateral aspect of the fibula need to be identified.<sup>8</sup> To achieve this, 5 different arthroscopic portals are needed: high anterolateral, high anteromedial, posteromedial, (trans-septal) posterolateral, and parapatellar lateral (Fig 1, Video 1).

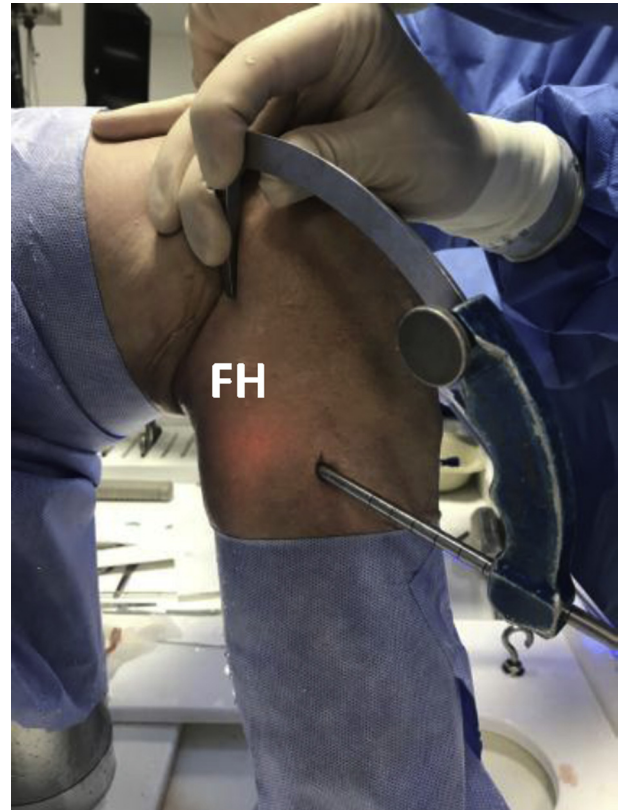First, the anterolateral and anteromedial portals are established. Second, the posteromedial portal is developed under arthroscopic control, and the dorsal septum is carefully dissected with a shaver (trans-septal



**Fig 2.** (A) The posteromedial portal is developed under arthroscopic visualization. The camera is inserted through the posteromedial portal. (B) After trans-septal preparation, the posterolateral recessus (PLR) is exposed through the posteromedial portal. After dissection of the posterolateral capsule (PLC) dorsal to the lateral meniscus and directly dorsal to the popliteal tendon, any further preparation should be performed with a radiofrequency device. (C) The fibular head (FH) can be directly exposed lateral and inferior to the popliteal tendon. The preparation should be close to the popliteal tendon to ensure no injury to any neurovascular structure.



**Fig 3.** Lateral view of right knee. A posterolateral portal is established anterior to the tendon of the biceps femoris (BF) to protect the peroneal nerve (PN). (FH, fibular head.)

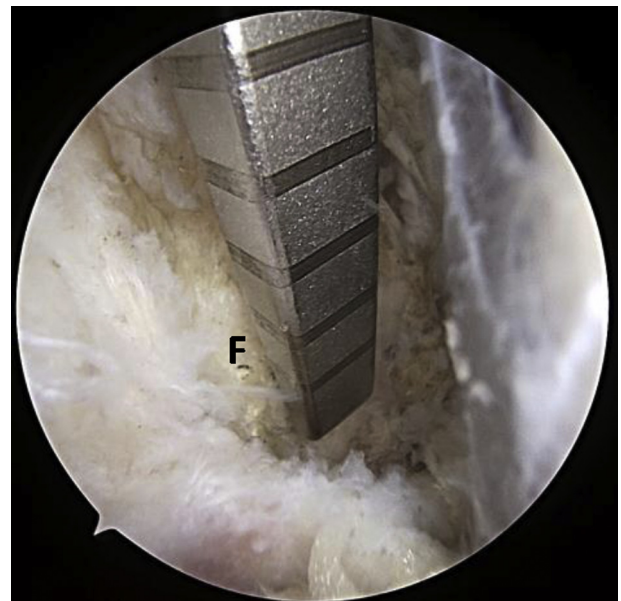


**Fig 4.** Lateral view of right knee. A cannulated posterior cruciate ligament femoral tunnel-aiming device (AR-1510F; Arthrex) is used to create the fibular tunnel. To achieve this, the aiming device is placed through the posterolateral portal on the dorsomedial side of the fibular head (FH).

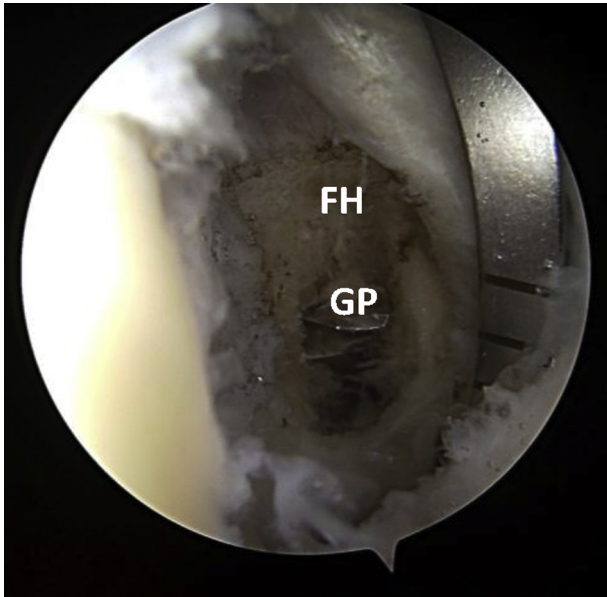
approach, Fig 2). Third, a posterolateral portal is established anterior to the tendon of the biceps femoris to protect the peroneal nerve (Fig 3). By use of a radiofrequency electrode or a shaver, capsular fibers dorsal to the popliteal tendon need to be dissected to expose the popliteal tendon (Fig 2B). The fibular head can be palpated and exposed distal and lateral to the popliteal tendon (Fig 2C).

A cannulated aiming device is used to create the fibular tunnel (AR-1510F; Arthrex, Naples, FL). The aiming device is placed through the posterolateral portal on the medial aspect of the fibular head to the attachment site of the PFL, and a guide pin is drilled through the fibular head from the attachment site of the fibular collateral ligament from anterolateral to posteromedial (Fig 4). Next, a 5- to 6-mm tunnel is reamed over this guide pin (Figs 5 and 6). Care has to be taken so that the drill channel is surrounded by bone tissue, not too close to the proximal tibiofibular joint and not too close to the proximal fibular tip, to prevent cutout of the graft.

The Tibial Popliteal Marking Hook (AR1510PT-1; Arthrex) is used as a drill guide for the tibial tunnel

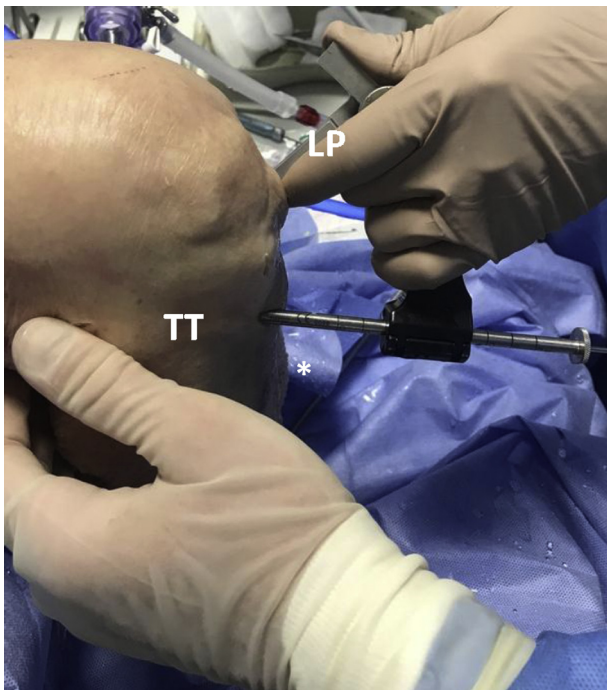

**Fig 5.** The aiming device is placed on the dorsomedial aspect of the fibula (F) close to the tibiofibular joint.



**Fig 6.** View through posteromedial portal on fibular head (FH). A guide pin (GP) is drilled through the FH from the attachment site of the fibular collateral ligament to the dorsomedial aspect of the FH.

for popliteal bypass reconstruction. The guide is placed through the anteromedial portal to the posterior popliteal sulcus at the level of the popliteal musculotendinous junction (about 10-12 mm distal

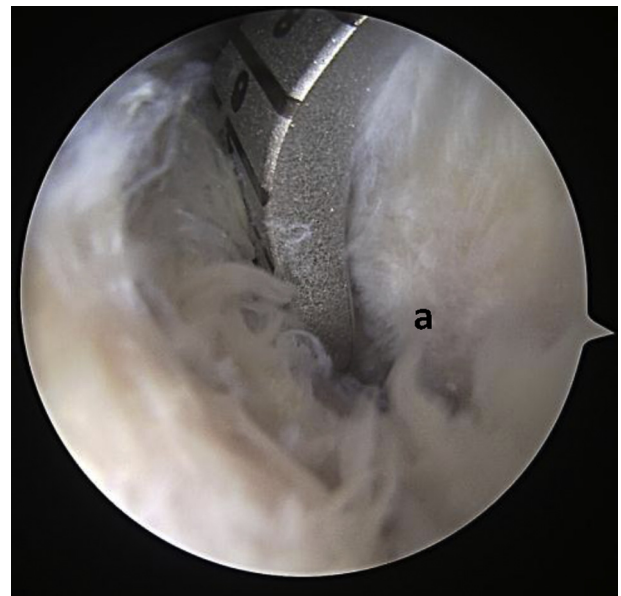


**Fig 7.** Medial view of knee. The Tibial Popliteal Marking Hook is used as a drill guide for the tibial tunnel (TT). The guide is placed through the anterior lateral portal (LP).

to the margin of the articular cartilage, Figs 7 and 8).<sup>13</sup> A guide pin is then advanced in an anteroposterior direction through the guide from an anterior start point between the tibial tuberosity and Gerdy tubercle to exit at the distal third of the popliteal sulcus. Then, a 7-mm tunnel is drilled over the guidewire.

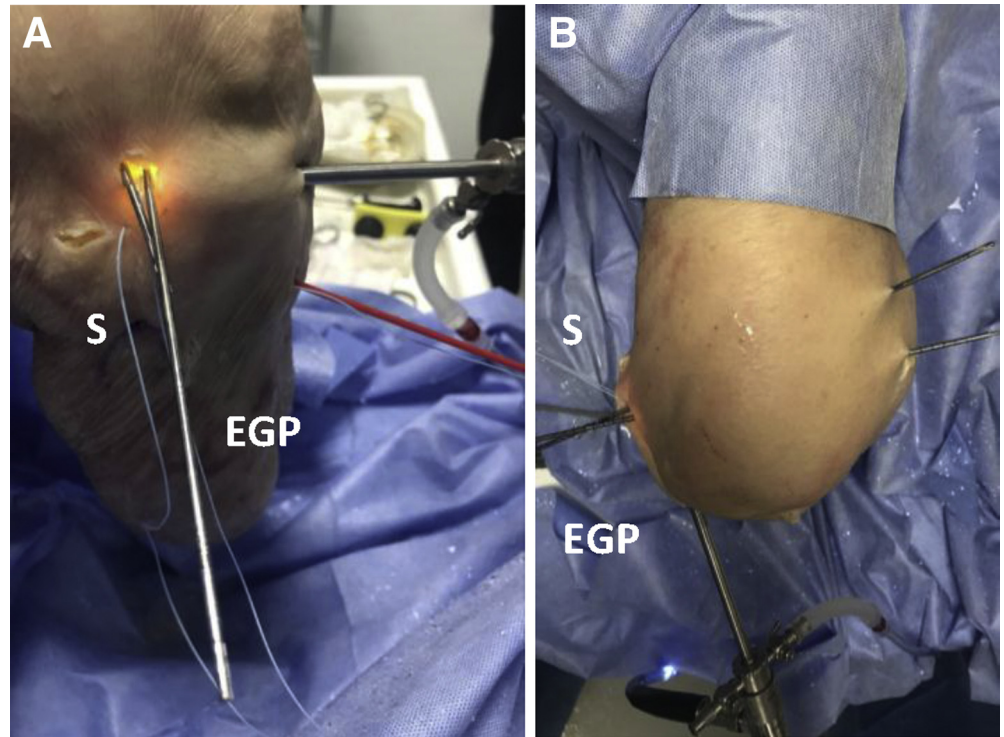
The arthroscope is advanced through the high anterolateral portal to the lateral femoral epicondyle, and a lateral parapatellar portal is established. Now, the femoral footprints of the LCL and popliteal tendon are exposed using a shaver, as previously described, through the lateral parapatellar portal.<sup>7</sup> At this point, sutures can be used to retract the soft tissue including the iliotibial band to improve visualization. Through a skin incision, 2 eyelet-tipped guide pins are drilled parallel into the center of the femoral footprint of the popliteal tendon and in the femoral footprint of the fibular collateral ligament. The center-to-center distance between the 2 footprints is at least 1.1 mm, as previously described.<sup>7</sup> The guide pins exit at the distal femur proximal-medial and anterior to the medial epicondyle and adductor tubercle (Figs 9 and 10). Graft tunnels 5 to 6 mm in diameter are then reamed over the guide pins. Care should be taken to respect any existent anterior cruciate ligament graft tunnels. The distance between tunnels should be at least 5 mm.<sup>8</sup>

For both tendon grafts, we recommend 1 semitendinosus tendon with a total length of at least 27 cm (2 tendon grafts are necessary: fibula, measuring at least



**Fig 8.** Inside view through dorsolateral portal. The aiming device is placed about 10 to 12 mm distal to the margin of the articular cartilage to the distal third of the sulcus popliteus at the level of the popliteal musculotendinous junction (a).

**Fig 9.** Through the lateral parapatellar portal, 2 eyelet-tipped guide pins (EGP) are drilled parallel into the femoral footprints of the popliteal tendon and of the fibular collateral ligament. Sutures (S) can be used to retract the soft tissue and the iliotibial band. (A) View from lateral. (B) View from anterior.



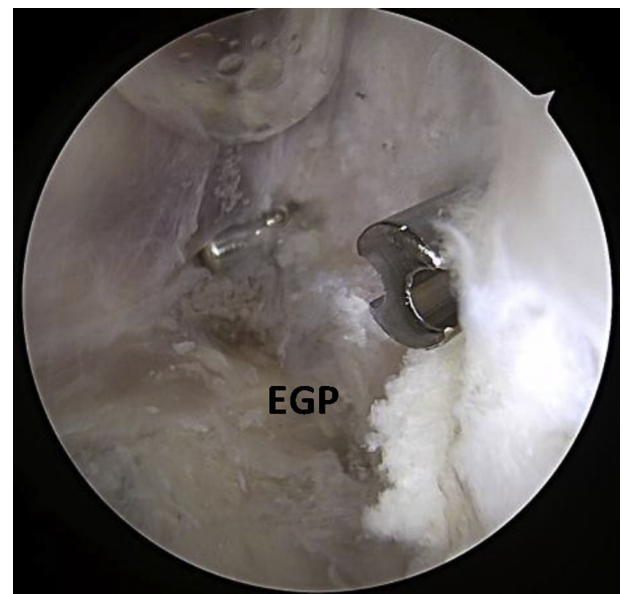16 cm, and popliteal bypass, measuring at least 11 cm). If needed, the grafts can be augmented with a Fiber-Tape (Arthrex).

The popliteal bypass graft is fixed on the femoral side with a bio-interference screw and passed distally along the anatomic path of the popliteal tendon through the popliteal hiatus to reach the posterolateral aspect of the lateral tibial plateau at the location of the anatomic site of the musculotendinous junction of the popliteus. The graft is then pulled through the tibial tunnel from posterior to anterior (Figs 11 and 12).

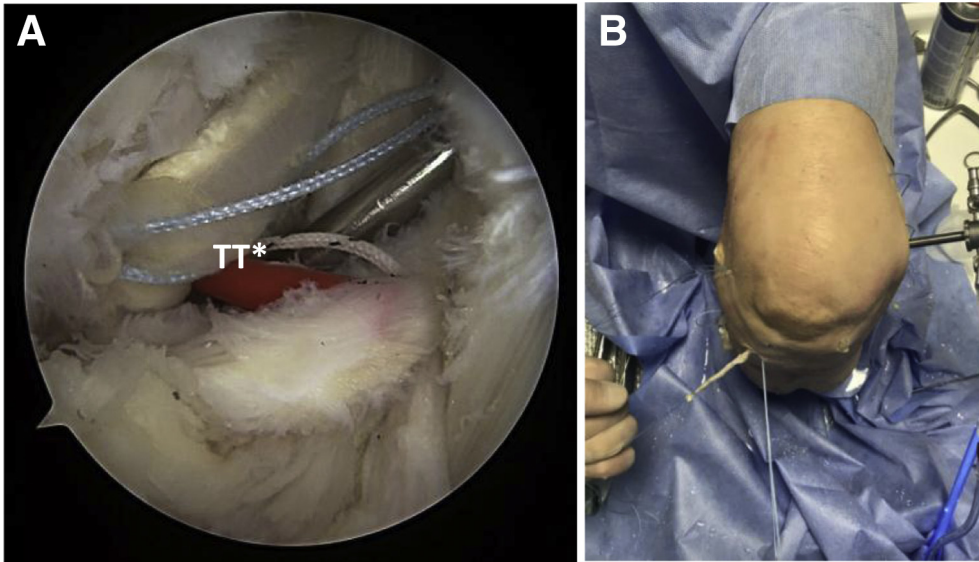
The second graft is used to reconstruct both the fibular collateral ligament and the PFL. After fixation of the second graft on the femoral side to reconstruct the LCL, the graft is then passed under the iliotibial band to the fibular head following the anatomic distal course of the fibular collateral ligament (Figs 13 and 14).

The graft is then passed through the fibular tunnel from anterolateral to posteromedial and pulled into the tibial tunnel from posterior to anterior. The LCL graft is fixed at first in the fibular tunnel at 20° of knee flexion with a 5-mm bio-interference screw. After tightening of the popliteal bypass graft, it is fixed at 70° of knee flexion in the tibial tunnel with a 7-mm cannulated bioabsorbable interference screw introduced from anteriorly.

If additional posterior cruciate ligament (PCL) reconstruction is necessary, we recommend the creation of drill channels of the PCL after drill channel placement on the lateral side. After all tendon grafts are



**Fig 10.** Inside view of distal femur. The eyelet-tipped guide pins (EGP) exit at the distal femur proximal and anterior to the medial epicondyle.



**Fig 11.** Arthroscopic view (right knee) from inside through posteromedial portal (A) and outside view (B). The popliteal bypass graft is fixed in the anatomic femoral drill channel and then pulled through the tibial tunnel (TT) from posterior to anterior. It exits just medial and slightly distal to the Gerdy tubercle.

in situ and fixed on the femoral side, we recommend starting fixation of the LCL on the fibular side, followed by the popliteal bypass on the tibial side and, finally, the PCL on the tibial side.

### Rehabilitation

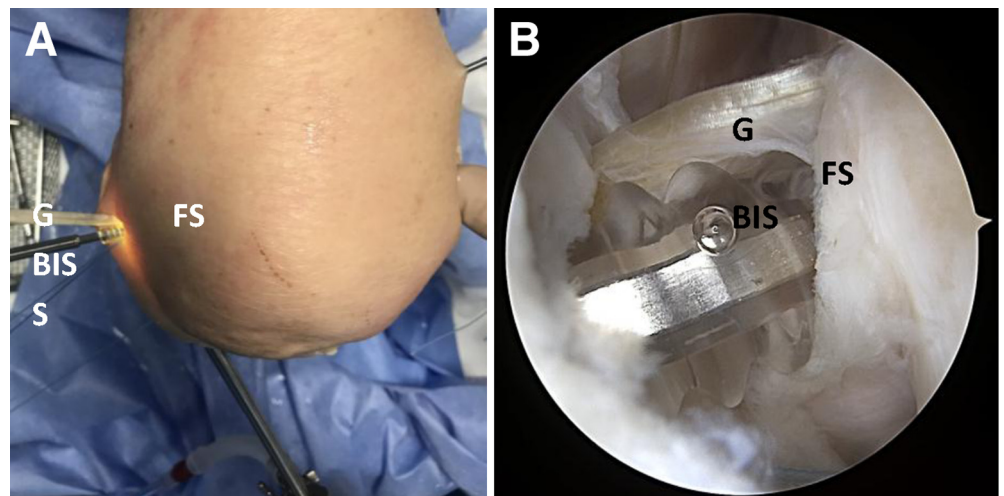
Passive knee motion up to 60° of flexion in the prone position against quadriceps force is started after the drains have been removed on day 2. Walking on crutches with partial weight bearing for 6 weeks and using a PCL brace (Jack PCL Brace; Albrecht, Bernau am Chiemsee, Germany) are recommended. The brace has a limitation in range of motion of 0° extension and 30° flexion for 2 weeks,

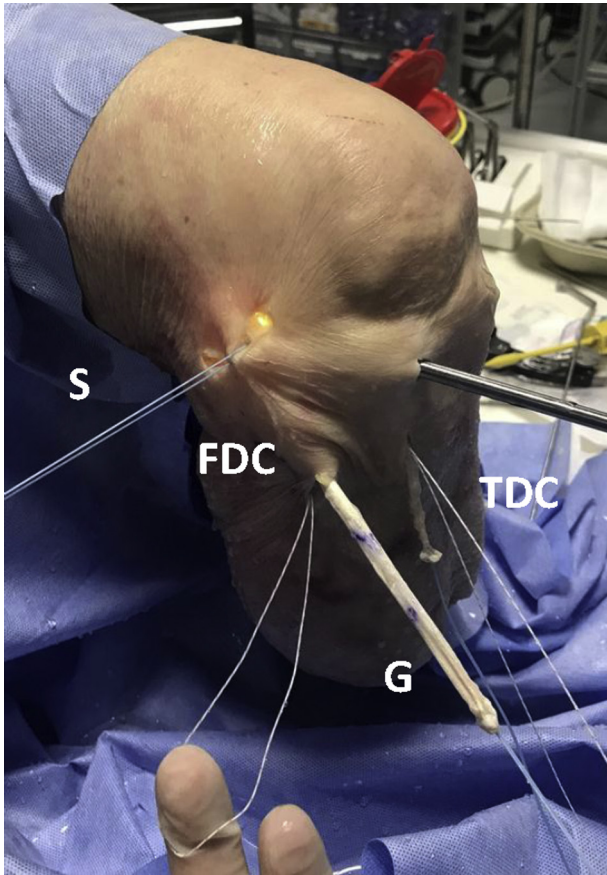
0° extension and 45° flexion for 2 weeks, and 0° extension and 60° flexion for 2 further weeks. Cycling is allowed after 8 weeks, jogging is allowed after 12 weeks, and stop-and-go sports such as soccer or tennis are allowed after 6 months according to return-to-play and return-to-competition tests.

### Discussion

In this article, we present an all-arthroscopic technique for anatomic PLC reconstruction for the first time. Numerous open fixation techniques have been described before.<sup>6,7,9,10</sup> In open fixation techniques, detailed exposure of the anatomic landmarks is necessary and is therefore naturally accompanied by

**Fig 12.** The graft (G) is fixed on the femoral side (FS) with a 6- or 7-mm cannulated bio-absorbable interference screw (BIS). Soft tissue is retracted with sutures (S). (A) Anterior view from outside. (B) Arthroscopic view on femoral side.

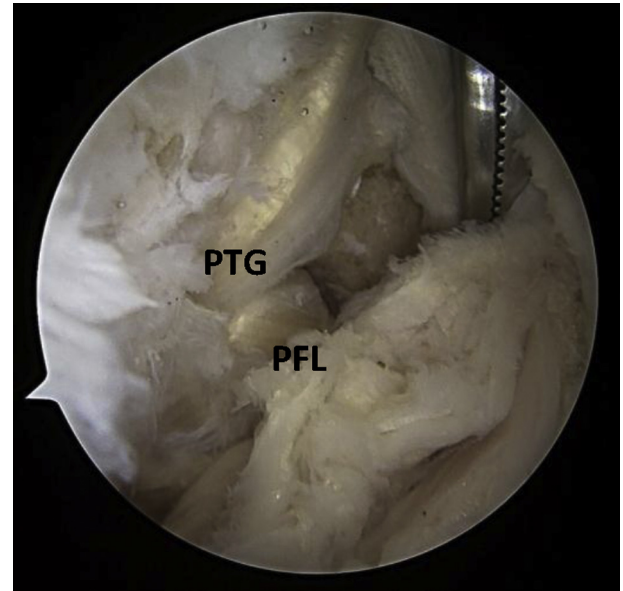




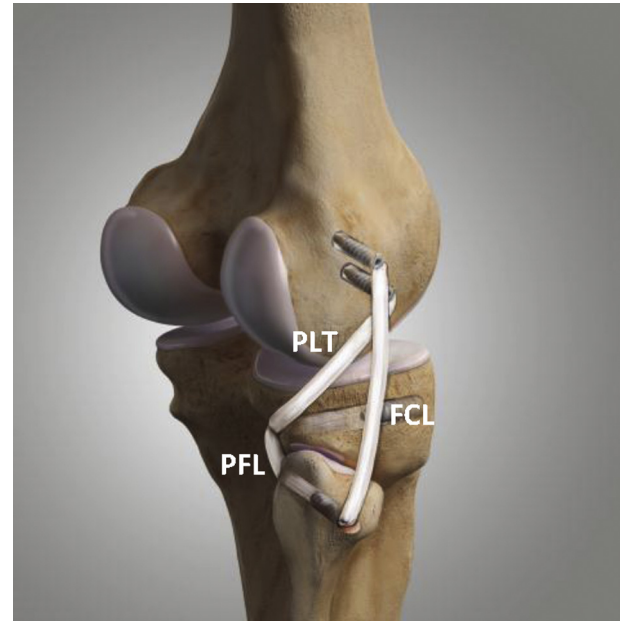
**Fig 13.** The second graft is used to reconstruct both the fibular collateral ligament and the popliteofibular ligament. From its anatomic fixation site at the femur, the graft (G) is passed under the iliotibial band, following the anatomic distal course of the fibular collateral ligament in the fibular drill channel (FDC) from anterior to posterior. The graft exits the fibular drill channel on the posterior side and enters the drill channel in the tibia (TDC) at the distal part of the sulcus popliteus from posterior. Sutures (S) are used to retract the soft tissue.

soft-tissue damage. The advantages of an all-arthroscopic anatomic posterolateral reconstruction are the protection of the soft tissues and the precise anatomic tunnel placement under direct visualization.<sup>11</sup> Direct visualization of the peroneal nerve is not necessary, which reduces the risk of peroneal nerve damage. Especially in revision cases, a second exposure of the nerve is not necessary, which lowers the risk of injury to the nerve.

Arthroscopic stabilization of the PLC is challenging and should therefore be carried out by a surgeon with advanced experience in arthroscopic procedures. As such, the described procedure is a safe and anatomic method for posterolateral stabilization (Fig 15). The clinical results have to be evaluated. Table 1 lists risks and limitations of the described technique, Table 2 shows pearls and pitfalls, and Table 3 presents advantages and disadvantages.



**Fig 14.** The popliteal bypass graft (PTG) is passed distally along the anatomic path of the popliteal tendon through the popliteal hiatus to reach the posterior-lateral aspect of the lateral tibial plateau at the location of the anatomic site of the musculotendinous junction of the popliteus. The popliteofibular ligament (PFL) is also reconstructed with a tendon graft.



**Fig 15.** Laprade technique with reconstruction of fibular collateral ligament (FCL), popliteofibular ligament (PFL), and popliteal bypass graft (PLT).

**Table 1.** Risks and Limitations of All-Arthroscopic Technique for Posterolateral Corner Reconstruction

Arthroscopic stabilization of the posterolateral corner is challenging and should therefore be carried out by a surgeon with advanced experience in arthroscopic procedures. The clinical results have to be evaluated.

**Table 2.** Pearls and Pitfalls of All-Arthroscopic Technique for Posterolateral Corner Reconstruction

## Pearls

- Because of the all-arthroscopic procedure, the soft tissue is protected.
- Anatomic tunnel placement under direct visualization is possible.
- Direct visualization of the peroneal nerve is not necessary, which reduces the risk of peroneal nerve damage.
- Especially in revision cases, a second exposure of the nerve is not necessary, which lowers the risk of injury to the nerve.
- The described procedure is a safe and anatomic method for posterolateral stabilization.

## Pitfalls

- Five arthroscopic portals are needed: high anterolateral, high anteromedial, posteromedial, posterolateral, and parapatellar lateral.
- After trans-septal preparation, the posterolateral recess is exposed through the posteromedial portal, which can be challenging.
- After dissection of the posterolateral capsule dorsal to the lateral meniscus and directly dorsal to the popliteal tendon, any further preparation should be performed with a radiofrequency device.
- The preparation should be close to the popliteal tendon to ensure no injury to any neurovascular structure.

**Table 3.** Advantages and Disadvantages of All-Arthroscopic Technique for Posterolateral Corner Reconstruction

## Advantages

- The soft tissue is protected owing to the arthroscopic technique.
- Tunnel placement can be performed under direct visualization.
- There is a reduced risk of peroneal nerve damage.
- The technique offers an anatomic method for posterolateral stabilization.
- Accompanying injuries (e.g., meniscal tears) can be addressed in the same setting.
- Additional posterolateral rotational and lateral instability is efficiently stabilized.

## Disadvantages

- Five arthroscopic portals are needed.
- The posterolateral recess has to be exposed to the posteromedial portal, which can be challenging.
- Even with a radiofrequency device, injury to any neurovascular structure is possible.
- The semitendinosus tendon has to be harvested.

## References

1. Fanelli GC, Giannotti BF, Edson CJ. Arthroscopically assisted combined posterior cruciate ligament/posterior lateral complex reconstruction. *Arthroscopy* 1996;12:521-530.
2. Sekiya JK, Whiddon DR, Zehms CT, Miller MD. A clinically relevant assessment of posterior cruciate ligament and posterolateral corner injuries. Evaluation of isolated and combined deficiency. *J Bone Joint Surg Am* 2008;90:1621-1627.
3. Hermanowicz K, Góralczyk A, Malinowski K, Jancewicz P. Arthroscopic posterolateral corner stabilization with popliteus tenodesis. *Arthrosc Tech* 2018;7:e669-e674.
4. LaPrade RF, Johansen S, Wentorf FA, Engebretsen L, Esterberg JL, Tso A. An analysis of an anatomical posterolateral knee reconstruction: An in vitro biomechanical study and development of a surgical technique. *Am J Sports Med* 2004;32:1405-1414.
5. Chahla J, Moatshe G, Dean CS, LaPrade RF. Posterolateral corner of the knee: Current concepts. *Arch Bone Jt Surg* 2016;4:97-103.
6. LaPrade RF, Griffith CJ, Coobs BR, Geeslin AG, Johansen S, Engebretsen L. Improving outcomes for posterolateral knee injuries. *J Orthop Res* 2014;32:485-491.
7. Frosch KH, Akoto R, Heitmann M, Enderle E, Giannakos A, Preiss A. Arthroscopic reconstruction of the popliteus complex: Accuracy and reproducibility of a new surgical technique [erratum published in *Knee Surg Sports Traumatol Arthrosc* 2016;24:3693]. *Knee Surg Sports Traumatol Arthrosc* 2015;23:3114-3120.
8. LaPrade RF, Ly TV, Wentorf FA, Engebretsen L. The posterolateral attachments of the knee: A qualitative and quantitative morphologic analysis of the fibular collateral ligament, popliteus tendon, popliteus tendon, popliteofibular ligament, and lateral gastrocnemius tendon. *Am J Sports Med* 2003;31:854-860.
9. Domnick C, Frosch KH, Raschke MJ, et al. Kinematics of different components of the posterolateral corner of the knee in the lateral collateral ligament-intact state: A human cadaveric study. *Arthroscopy* 2017;33:1821-1830.e1.
10. Arciero RA. Anatomic posterolateral corner knee reconstruction. *Arthroscopy* 2005;21:1147.
11. Frings J, Kolb JP, Drenck TC, et al. Anatomic reconstruction of the posterolateral corner: An all-arthroscopic technique. *Arthrosc Tech* 2019;8:153-161.
12. Stannard JP, Brown SL, Robinson JT, McGwin G Jr, Volgas DA. Reconstruction of the posterolateral corner of the knee. *Arthroscopy* 2005;21:1051-1059.
13. Krause M, Akoto R, Drenck TC, Frosch KH, Preiss A. Posterolateral rotatory knee instability-MRI evaluation of anatomic landmarks for tibial drill tunnel placement in open and arthroscopic popliteus tendon reconstruction [published online July 6, 2018]. *J Knee Surg*, <https://doi.org/10.1055/s-0038-1666832>.