

## Images in Infectious Diseases in Obstetrics and Gynecology

Section Editor: David E. Soper, M.D.

### Human Papillomavirus Infection and Cervical Dysplasia

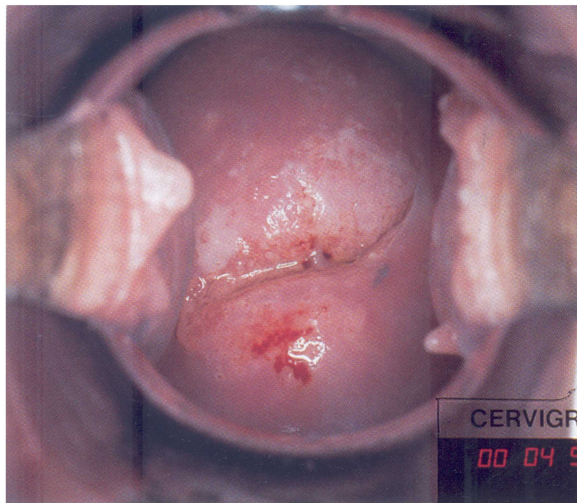
Sharon Bond

College of Nursing, Medical University of South Carolina,  
Charleston, SC

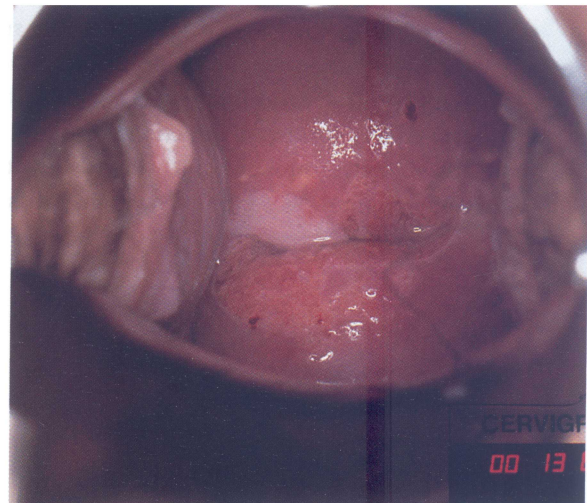
Human papillomavirus (HPV) infection is highly prevalent and a common cause of abnormal cytology, particularly among young, sexually active women. With hybrid capture system assay, HPV can be further classified into low-risk (6, 11, 42, 43, 44) and high-risk (16, 18, 31, 33, 35, 45, 51, 52, 56) DNA types. The majority of HPV infections are believed to regress spontaneously. How-

ever, the natural history of infection in a particular woman and factors associated with individual persistence and/or regression are unknown. Persistent infection, especially with a high-risk type, may place a woman at increased risk for progression to high-grade squamous intraepithelial lesions (HGSIL) and perhaps cervical cancer.

Shown here is a case of a 25-year-old woman with progressive cervical intraepithelial neoplasia (CIN) over 15 months. The initial Pap smear suggested a low-grade squamous intraepithelial lesion (LGSIL). A cervi-gram (A, 10 o'clock to 11:30 o'clock) was obtained and colposcopically directed biopsies confirmed CIN I. An HPV DNA test was positive for high-risk HPV types. Repeat evaluation 1 year later yielded cytologic, biopsy, and cervicographic evidence of HGSIL compatible with CIN III (B). She was treated with large loop excision of the transformation zone. © 1999 Wiley-Liss, Inc.



A



B

*Images in Infectious Diseases in Obstetrics and Gynecology* presents clinically important visual images that a practitioner in women's health might encounter. If you have a high-quality color or black-and-white photograph or slide representing such an image that you would like considered for publication, send it with a descriptive legend to David E. Soper, MD, Department of Obstetrics and Gynecology, Rush-Presbyterian-St. Luke's Medical Center, 1653 West Congress Parkway, Chicago, IL 60612-3833. *Images* is made possible through an educational grant from 3M Pharmaceuticals.

Images