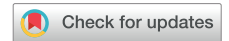

# Multimodality Imaging in the Evaluation of Ascending Aortic Pseudoaneurysms to Guide Complex Surgical Management



Kevin Li, MD, Chadi Ayoub, MD, Gosta Pettersson, MD, PhD, Leonardo Rodriguez, MD, and Anand R. Mehta, MBBS, *Cleveland, Ohio*

## INTRODUCTION

Ascending aortic pseudoaneurysm (AAP) is a rare but potentially fatal complication after aortic surgery. AAP can compress nearby structures; lead to hemorrhage, rupture, or thrombosis; or serve as a nidus for fistula formation. A pseudoaneurysm, also known as a false aneurysm or contained rupture, is defined as a contained collection of blood involving at least one layer of the vasculature, whereas a true aneurysm involves all three layers.<sup>1</sup> Despite advances in endovascular repair, conventional full sternotomy and open surgical intervention are required. The following case demonstrates the importance of multimodality imaging in planning a complex redo surgical approach for a patient with two AAPs.

## CASE PRESENTATION

A 60-year-old man with a background significant for heart failure with reduced left ventricular ejection fraction (30%) and chronic kidney disease stage III was initially diagnosed with *Aerococcus urinae* endocarditis of his native trileaflet aortic valve. This was associated with an aortic root abscess surrounding two thirds of the circumference involving the left and right coronary leaflets. The source was thought to be urosepsis. Surgical treatment with an aortic valve replacement with a bioprosthetic valve and root patch repair was performed. Two months later, he was diagnosed with severe paravalvular leak due to patch dehiscence and underwent reoperation with a Bentall procedure. The Bentall procedure (Figure 1) was originally described as an aortic root, valve, and ascending aorta replacement with a composite graft containing a mechanical prosthetic aortic valve and reattachment of the coronary arteries.<sup>2</sup> One year later, an aortic paravalvular leak, aortic pseudoaneurysm, and severe mitral regurgitation were detected, for which he underwent a repeat Bentall procedure and mitral valve replacement with a mechanical prosthesis.

Three years later, the patient was admitted for chest pain and shortness of breath at an outside hospital. Initial workup showed

ST-segment depressions on electrocardiography and pulmonary edema on chest radiography. Heart catheterization revealed patent coronary arteries and elevated right-sided pressures consistent with severe pulmonary hypertension. Transthoracic echocardiography (TTE) revealed an elevated mitral valve gradient of 10 to 12 mm Hg, which was attributed to a smaller prosthetic valve size (27-mm St. Jude bileaflet mechanical valve) and tachycardia. Moderate to severe aortic paraprosthesis regurgitation was also noted on TTE. Transesophageal echocardiography (TEE) discerned an echo-lucent space between the aortic root and the left atrial wall associated with moderate to severe aortic paravalvular regurgitation. On the basis of these findings, a percutaneous closure of the leak was attempted. Angiography showed a pseudoaneurysm that was compressing the aortic graft as well as the pulmonary artery during systole, resulting in equalization of aortic pressure to pulmonary artery pressure. The procedure was aborted, and the patient was transferred to our institution for further management of the aortic pseudoaneurysm.

TTE at our institution confirmed the paravalvular leak and a well-seated mitral mechanical prosthesis with normal leaflet mobility. The proximal posterior pseudoaneurysm was seen with diastolic flow noted around the posterior aspect of the aortic prosthesis (Video 1). A second pseudoaneurysm along the posterior aspect of the ascending aortic conduit and a left coronary button leak were also noted (Video 2). Acoustic shadowing from the mechanical valves on TTE limited the assessment of the posterior pseudoaneurysm. Preoperative TEE confirmed the presence of the aortic pseudoaneurysm of the intervalvular fibrosa and the distal anastomotic site (Videos 3-5) as well as the leak around the left coronary button suture line during diastole (Video 6). Systolic collapse of the ascending aortic graft was noted with expansion of the posterior pseudoaneurysm of the intervalvular fibrosa (Video 7). During diastole, the pseudoaneurysm emptied back into the left ventricle, simulating paravalvular regurgitation. The mechanical valve in the composite Valsalva graft was functioning normally.

Computed tomography (CT) with contrast was obtained for surgical planning. The images revealed a proximal aortic 1.5 × 1.2 cm root pseudoaneurysm that communicated with the left ventricle posteriorly. A second 5.6 × 4.8 cm communicating pseudoaneurysm was noted at the distal aortic anastomosis, in close proximity to the sternum. The aortic and mitral valve mechanical prosthesis were well seated with normal leaflet mobility. CT also revealed the left brachiocephalic vein immediately behind the manubrium. The aortic pseudoaneurysm and right ventricle were closely approximated to the sternum. These findings led to the establishment of cardiopulmonary bypass (CPB) with peripheral cannulation and the use of an aortic endoballoon and percutaneous retrograde cardioplegia catheter to decompress and arrest the heart. This mitigated the risk for accidental injury to the pseudoaneurysm and the other adherent structures upon sternal reentry. To determine the landing zone and the accurate placement of the percutaneous endoballoon, the distance from the aortic

From the Department of Cardiothoracic Anesthesiology (K.L., A.R.M.), the Section of Cardiovascular Imaging, Heart and Vascular Institute (C.A., L.R.), and Department of Thoracic and Cardiovascular Surgery (G.P.), Cleveland Clinic, Cleveland, Ohio.

Keywords: Ascending aortic pseudoaneurysm, CorMatrix, Intervalvular fibrosa, Multimodal imaging

Conflicts of interest: The authors reported no actual or potential conflicts of interest relative to this document.

Supported by Cleveland Clinic Anesthesia Institute, Cleveland, OH, USA.

Copyright 2020 by the American Society of Echocardiography. Published by Elsevier Inc. This is an open access article under the CC BY-NC-ND license (<http://creativecommons.org/licenses/by-nc-nd/4.0/>).

2468-6441

<https://doi.org/10.1016/j.case.2020.06.003>

## VIDEO HIGHLIGHTS

**Video 1:** Preoperative TTE, parasternal long-axis view, with flow along the posterior aspect of the ascending aortic conduit.

**Video 2:** Preoperative TTE, parasternal short-axis view, demonstrating left coronary button leak.

**Video 3:** Intraoperative three-dimensional multiplanar reconstruction of the aortic root visualizing pseudoaneurysm of the mitral-aortic intervalvular fibrosa dehiscence.

**Video 4:** Intraoperative TEE, midesophageal aortic valve short-axis view with biplane and color flow Doppler, visualizing pseudoaneurysm of the mitral-aortic intervalvular fibrosa.

**Video 5:** Intraoperative TEE, midesophageal ascending aortic long-axis view, visualizing the two AAPs.

**Video 6:** Intraoperative TEE, midesophageal ascending aortic short-axis view, with diastolic leak noted near the left coronary button.

**Video 7:** Intraoperative TEE, midesophageal aortic valve short-axis view with biplane, visualizing systolic collapse of ascending aortic graft and the pulmonary artery vent.

**Video 8:** Aortic root angiogram with ascending aortic graft with leak around the left coronary button.

**Video 9:** Intraoperative TEE, midesophageal long-axis view, visualizing proximal migration of the partially inflated endoballoon into the skirt of the Valsalva graft during trial positioning.

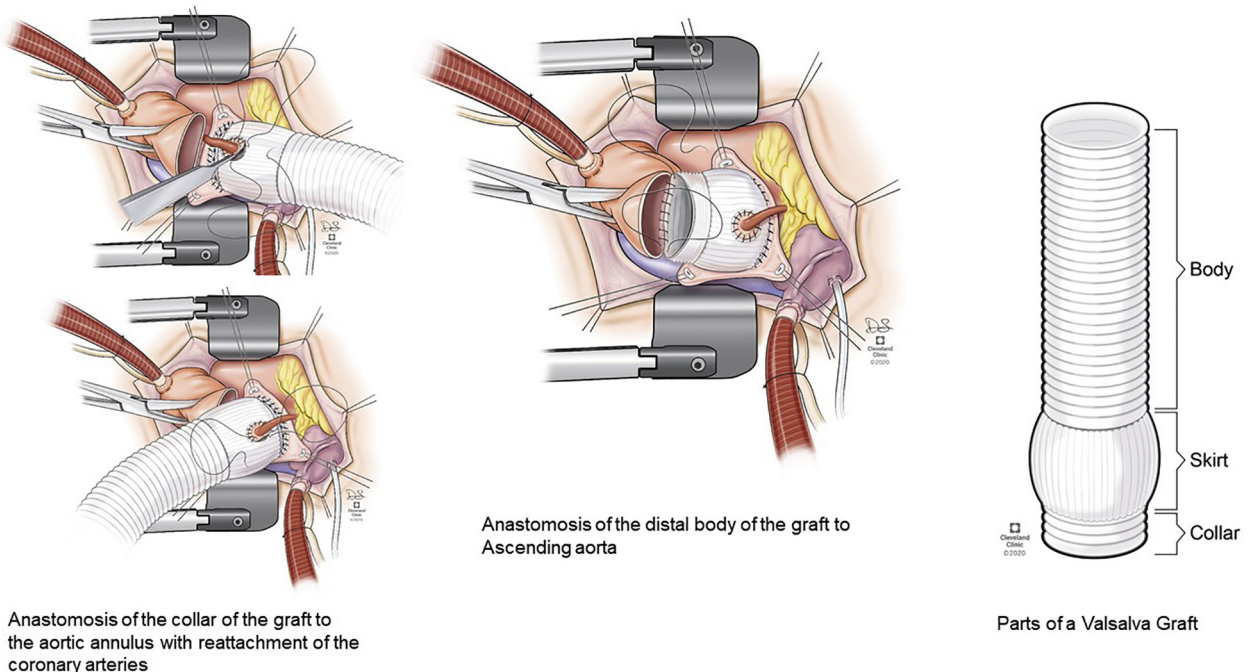
**Video 10:** Intraoperative TEE, midesophageal long-axis biplane view, visualizing endoballoon after inflation.

View the video content online at [www.cvcasejournal.com](http://www.cvcasejournal.com).

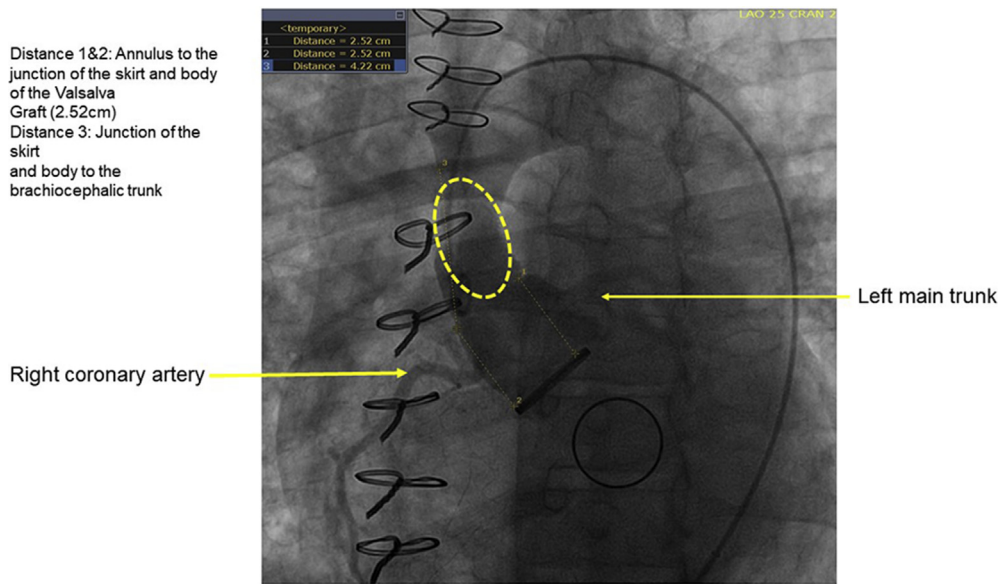
valve annulus to the junction of the skirt and the body of the graft (tubular aspect of the graft) and the distance from the junction of the skirt and the body of the graft to the brachiocephalic artery were measured on aortic root angiography (Video 8, Figure 2). The distances from the aortic annulus to the left and right coronary buttons were also measured on CT to prevent accidental coronary occlusion on balloon migration (Figure 3).

Intraoperative TEE confirmed the preoperative findings. After induction of general anesthesia, a coronary sinus catheter for retrograde cardioplegia delivery was inserted through the right internal jugular vein and positioned with transesophageal echocardiographic guidance. A pulmonary endovent was similarly introduced via the right internal jugular vein and positioned in the main pulmonary artery. Peripheral CPB was established with dual arterial cannulation, via the right axillary and right femoral artery. The venous cannula was inserted through the right femoral vein with the tip positioned in the right atrium with transesophageal echocardiographic guidance. The endoballoon was introduced through the right arterial groin cannula and, using TEE, positioned in the body of the ascending aortic graft at the previously defined "landing zone" on preoperative imaging.

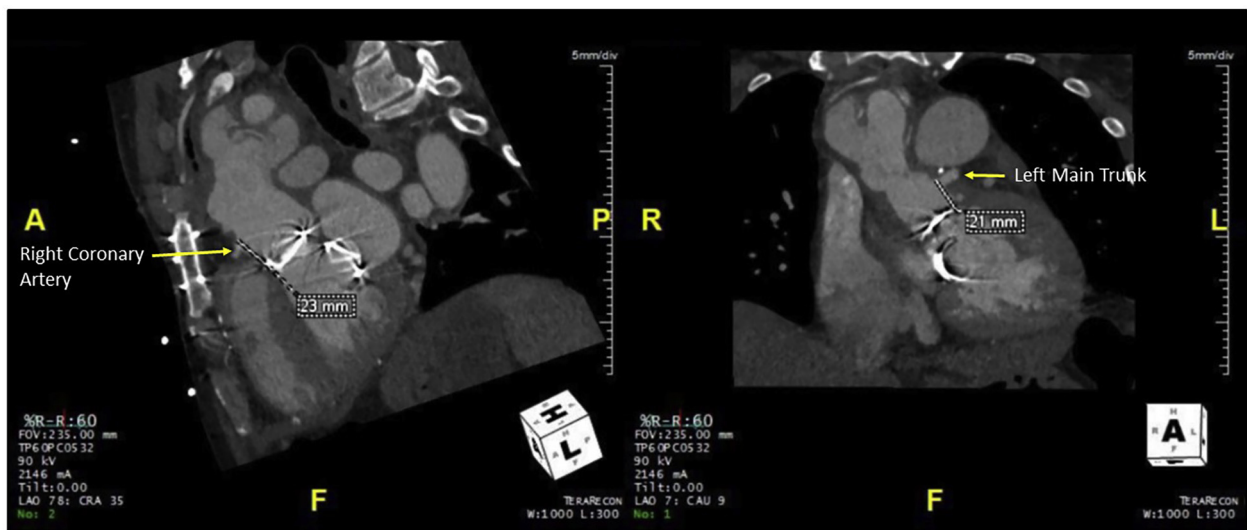A redo sternotomy was performed to the level of the sternomanubrial junction, up close to the pseudoaneurysm. The right atrium and diaphragmatic surface of the heart were dissected out before heparinization, cannulation, and initiation of CPB (Figure 4). The heart was decompressed and systemic cooling initiated and continued until the heart fibrillated. The heart was vented with the use of the pulmonary artery vent. The sternotomy was completed, and this resulted in an accidental entry into the pseudoaneurysm. The endoballoon was inflated and the heart arrested with retrograde cold-blood cardioplegia (Figure 5). Minimal flow into the pseudoaneurysm from the left coronary button and from the left ventricle was observed after balloon



**Figure 1** The Bentall procedure. Illustrations by Joseph Pangrace, BFA, CMI and David Schumick, BS, CMI. Reprinted with the permission of the Cleveland Clinic Center for Medical Art & Photography © 2020. All Rights Reserved.



**Figure 2** “Landing zone” for the endoballoon on aortic root angiography.



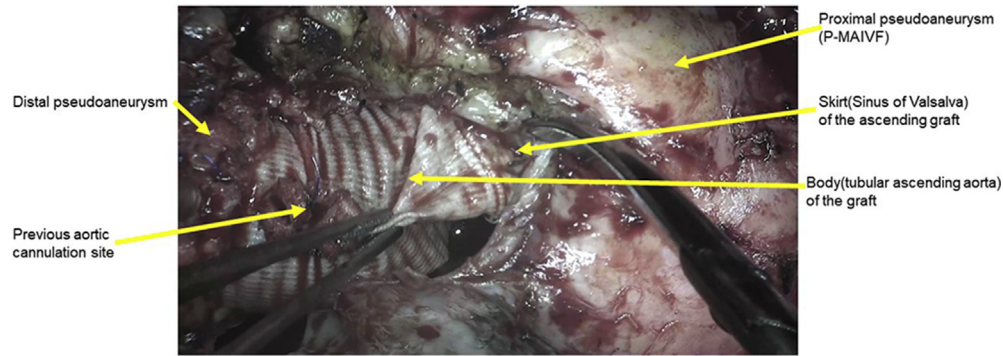
**Figure 3** Distance of the coronary buttons from the valve annulus on computed tomographic angiography.

inflation (Videos 9 and 10). The ascending graft and distal aorta were dissected out and mobilized. The endoballoon was deflated and withdrawn and a regular aortic clamp applied (Figure 6). Further dissection confirmed partial dehiscence of the left coronary button from the root graft and partial dehiscence of the composite graft valve posteriorly from the left ventricular outflow tract (LVOT). The composite graft was excised, and the LVOT was debrided. The patch (CorMatrix; CorMatrix Cardiovascular, Atlanta, GA) used to reconstruct the intervalvular fibrosa during the patient’s previous surgery had necrosed, explaining the posterior dehiscence of the composite valve. There were no signs of active infection. The aortic root and ascending aorta were re-replaced with a new composite graft including a 25-mm mechanical aortic valve. The patient was easily weaned from CPB, and his postoperative course was uneventful. He was extubated, transferred to

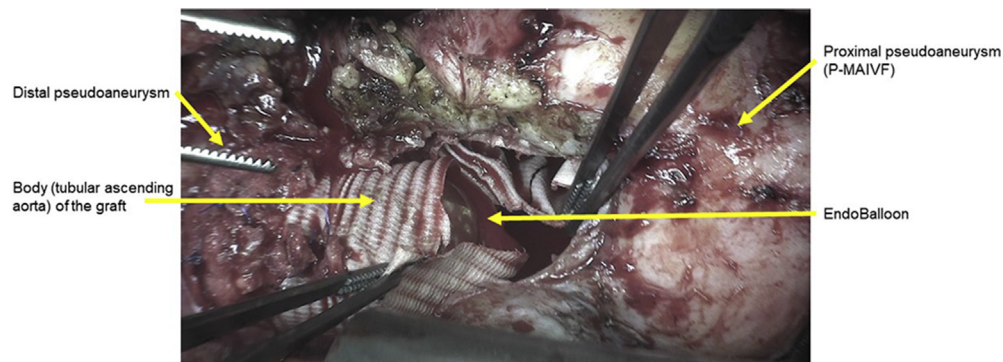
the regular nursing floor the next day, and discharged home on postoperative day 6.

## DISCUSSION

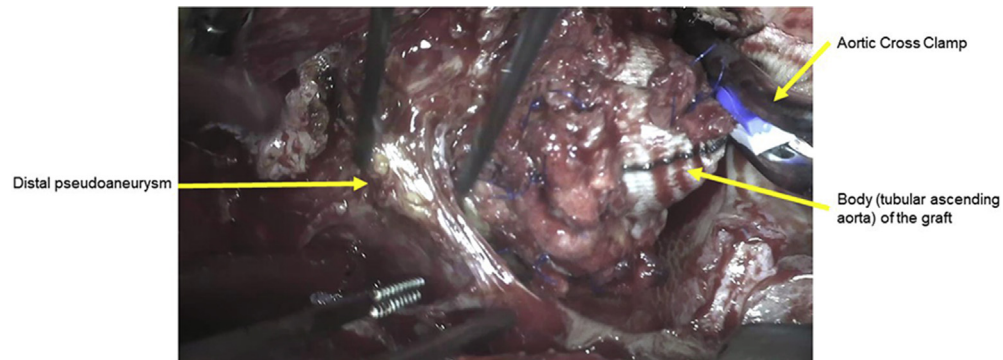
Periprosthetic pseudoaneurysm is a rare complication after a Bentall procedure that may be associated with the use of glue, infection, or connective tissue diseases such as Marfan syndrome.<sup>1,3-5</sup> In this particular case, the cause of the aortic valve dehiscence and the pseudoaneurysm was disintegration of the previous patch used to reconstruct the intervalvular fibrosa. Etiologies of pseudoaneurysm of the mitral-aortic intervalvular fibrosa are similar to aortic pseudoaneurysms, including endocarditis and aortic valve surgery because of its relatively avascular nature and susceptibility to damage.<sup>4,5</sup> Complications also include



**Figure 4** Surgical image of the two pseudoaneurysms of the Valsalva graft. *P-MAIVF*, Pseudoaneurysm of the mitral-aortic intervalvular fibrosa.



**Figure 5** Surgical image of the endoballoon within the Valsalva graft. *P-MAIVF*, Pseudoaneurysm of the mitral-aortic intervalvular fibrosa.



**Figure 6** Surgical image of the distal pseudoaneurysm.

compression of nearby structures, fistula formation, and rupture, which necessitate early recognition and evaluation with multimodality imaging and close monitoring.

TEE is useful as an initial mode of investigation but can miss pseudoaneurysm of the mitral-aortic intervalvular fibrosa in the presence of a prosthetic aortic valve, the presence of artifact, and its relative posterior position.<sup>4,5</sup> Off-axis imaging views may provide better visualization. In our case, dynamic systolic collapse of the aortic graft was noted. In a previous case report, the transthoracic echocardiographic findings of systolic collapse of the composite graft in a patient with a history of a Bentall procedure were used to help with early recognition of aortic

pseudoaneurysm.<sup>6</sup> Visualization of the mitral-aortic intervalvular fibrosa may be challenging with TTE because of acoustic shadowing in the far field. TEE may allow enhanced imaging, as the mitral-aortic intervalvular fibrosa will be visualized in the near field without acoustic shadowing from the prosthetic valve. Thus, TEE is often needed to confirm the diagnosis and better delineate the pathology. Typical findings include a pulsatile echo-free space that expands with blood flow into the pseudoaneurysm on color Doppler during systole and collapses during diastole with blood flow into the LVOT.<sup>4-6</sup>

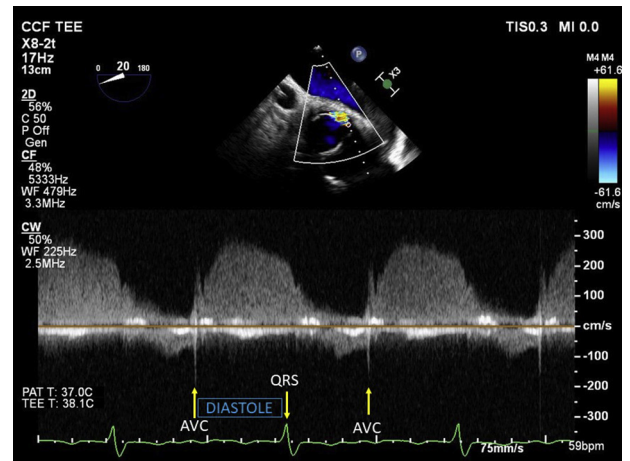
Multiple views on our transesophageal echocardiographic images showed systolic flow in the aortic pseudoaneurysm with concomitant

collapse of aortic graft and diastolic flow reversal from the pseudoaneurysm into the LVOT on color flow Doppler. A diastolic leak around the left coronary button was also noted on color flow Doppler with a diastolic peak velocity of close to 3 m/sec on continuous-wave Doppler (Figure 7). Of note, the dehiscence of the intervalvular fibrosa can be mistakenly reported as aortic insufficiency, with flow seen entering the LVOT during diastole. Typically, paravalvular regurgitation is due to dehiscence of the sewing ring from the adjacent aortic wall or, in this case, the graft. Separation of the valve sewing ring from the graft in a composite graft is extremely rare. Despite its rarity, if this were to occur, diastolic flow would be visualized between the graft and the valve on color flow Doppler. In the absence of a pseudoaneurysm, systolic collapse of the graft would not be seen, as the luminal pressure within the graft would exceed the extramural pressure surrounding the graft. A pseudoaneurysm in the presence of dehiscence of the composite graft from the mitral-aortic intervalvular fibrosa would expand in systole, with the potential to collapse the ascending graft if the pressure within the pseudoaneurysm exceeded the intraluminal pressure within the graft.

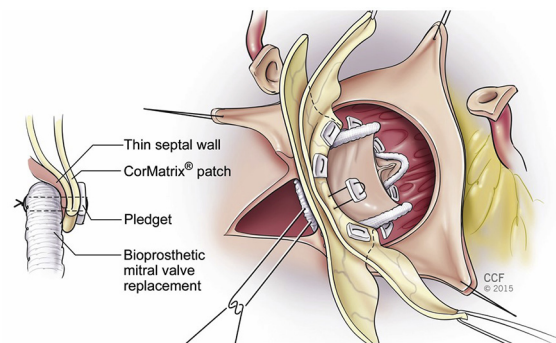
The use of multiple imaging modalities, such as TTE, TEE, CT, and cardiac catheterization, is critical in defining the anatomy and guiding the operative course for the surgical repair of AAPs.<sup>7,8</sup> Preoperative CT is considered vital in identifying the proximity of the aortic pseudoaneurysm and other cardiac structures to the inner table of the sternum.<sup>9</sup> The brachiocephalic vein and AAP were closely approximated to the sternum. Redo sternotomy with a high risk for injury to an aortic pseudoaneurysm results in catastrophic bleeding with instant systemic and cerebral hypoperfusion. Precise surgical planning on the basis of imaging, including establishment of peripheral CPB and the use of an endoballoon and percutaneous retrograde cardioplegia, is required to minimize this risk.<sup>10</sup> CT was used to define the distance of the origins of the coronary arteries from the aortic valve annulus to ascertain that they were not obstructed on endoballoon migration. These measurements were better defined on CT compared with TEE. Aortic root angiography was used to define a suitable landing zone for the endoballoon. Dual arterial, axillary, and femoral cannulation sites were used to prevent distal migration of the endoballoon.

CorMatrix patch dehiscence after reconstruction of the interventricular septum and heart base resulting in a large left ventricular-to-right atrial shunt (Gerbode shunt) has been reported (Figures 8 and 9).<sup>11</sup> The CorMatrix is a porcine small intestine submucosal extracellular matrix patch used to promote native remodeling and growth with reduced immunogenicity to avoid inflammation.<sup>12</sup> It has been widely used in adult and congenital cardiac procedures as well as vascular reconstructions. Despite its advantages in minimizing inflammation and promoting remodeling, complications such as patch degradation, pseudoaneurysm, and rupture associated with chronic inflammatory changes have been reported.<sup>11-13</sup>

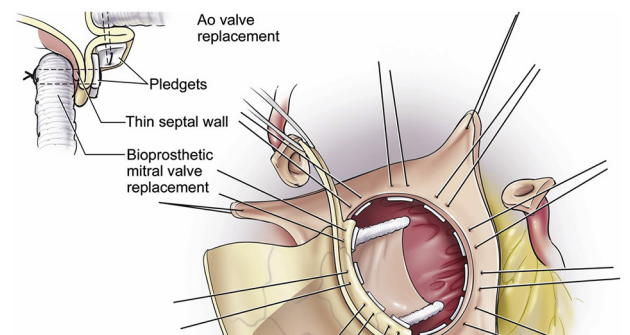
The most common sites of aortic pseudoaneurysm are at the proximal and distal aortic suture line, proximal composite valve graft suture line, and coronary ostium.<sup>1,2</sup> The course of the disease can be unpredictable, and patients can be asymptomatic for many years. The treatment of choice remains surgical. For patients who underwent reoperation, the average time interval between the previous procedure and the reoperation was 8 years, with a range of 1 month to 37 years.<sup>1,2</sup> Reoperation is associated with an operative mortality rate of 6.9%.<sup>1</sup> Freedom from reoperation was 86% at 1 year and 72% at both 5 and 10 years, with survival rates at 1, 5, and 10 years of 94%, 79%, and 68%, respectively.<sup>1</sup> Risk factors for the development of pseudoaneurysms include history of aortic dissection, connective tissue disorders, infection, and the use of biological glues.<sup>2</sup>



**Figure 7** Continuous-wave Doppler interrogation of the left coronary button leak. Rhythm was atrial flutter. “T” wave was not identified because of flutter waves. Diastole was defined as aortic valve closure (AVC) to QRS complex onset.



**Figure 8** Surgical technique of mitral-aortic intervalvular fibrosa with CorMatrix patch repair. Illustrations by Joseph Pangrace, BFA, CMI and David Schumick, BS, CMI. Reprinted with the permission of the Cleveland Clinic Center for Medical Art & Photography © 2020. All Rights Reserved.



**Figure 9** Surgical technique of mitral-aortic intervalvular fibrosa with CorMatrix patch repair. Ao, Aortic. Illustrations by Joseph Pangrace, BFA, CMI and David Schumick, BS, CMI. Reprinted with the permission of the Cleveland Clinic Center for Medical Art & Photography © 2020. All Rights Reserved.

In addition to the pseudoaneurysm of the mitral-aortic intervalvular fibrosa, a leak around the left coronary button was visualized in our case. A previous case report described a pseudoaneurysm of the left

coronary orifice after a composite aortic graft replacement for an aortic dissection related to suture weakening.<sup>14</sup> The perioperative use of topical hemostatic agents such as BioGlue (CryoLife, Kennesaw, GA) is another factor associated with pseudoaneurysm formation, believed to be caused by an inflammatory reaction attributed to the slow release of glutaraldehyde from the polymerized BioGlue.<sup>15</sup> In our patient, during a preceding operation, topical hemostatic agents had been used at the anastomotic sites to achieve adequate hemostasis. The development of the pseudoaneurysm and leak may also have been related to the use of biological glues at the suture lines.

## CONCLUSION

Periprosthetic ascending aorta pseudoaneurysms are rare complications after aortic valve, root, and ascending aorta surgery. Use of multimodality imaging, including echocardiography, CT or computed tomographic angiography, and cardiac catheterization, is vital for anatomic evaluation and accurate diagnosis to guide complex reoperation. Treatment is surgical and has acceptable outcomes at expert centers.

## SUPPLEMENTARY DATA

Supplementary data related to this article can be found at <https://doi.org/10.1016/j.case.2020.06.003>.

## REFERENCES

- Malvindi PG, van Putte BP, Heijmen RH, Schepens MA, Morshuis WJ. Reoperations for aortic false aneurysms after cardiac surgery. *Ann Thorac Surg* 2010;90:1437-43.
- Bentall H, De Bono A. A technique for complete replacement of the ascending aorta. *Thorax* 1968;23:338-9.
- Malvindi PG, Cappai A, Raffa GM, Barbone A, Basciu A, Citterio E, et al. Analysis of postsurgical aortic false aneurysm in 27 patients. *Tex Heart Inst J* 2013;40:274-80.
- Sudhakar S, Sewani A, Agrawal M, Uretsky BF, Rock L. Pseudoaneurysm of the mitral-aortic intervalvular fibrosa (MAIVF): a comprehensive review. *J Am Soc Echocardiogr* 2010;23:1009-18.
- Sahan E, Gul M, Sahan S, Sokmen E, Guray YA, Tufekcioglu O. Pseudoaneurysm of the mitral-aortic intervalvular fibrosa: a new comprehensive review. *Herz* 2015;40:182-9.
- Nagai T, Arakawa J, Tabata H. Systolic collapse of aortic composite graft after Bentall operation: a sign of pseudoaneurysm formation. *Echocardiography* 2017;34:942-4.
- Antonellis J, Kostopoulos K, Routoulas T, Patsilinos S, Kranidis A, Salahas A, et al. Aneurysm of the mitral-aortic intervalvular fibrosa as a rare cause of angina pectoris: angiographic demonstration. *Cathet Cardiovasc Diagn* 1997;42:423-6.
- Choon Seng Lowa S, Attilib A, Bach D, Agarwald P. CT and MRI features of pseudoaneurysms of the mitral-aortic intervalvular fibrosa. *Clin Imaging* 2018;47:74-9.
- Kamdar AR, Meadows TA, Roselli EE, Gorodeski EZ, Curtin RJ, Sabik JF, et al. Multidetector computed tomographic angiography in planning of reoperative cardiothoracic surgery. *Ann Thorac Surg* 2008;85:1239-45.
- Mehta AR, Hammond B, Unai S, Navia JL, Gillinov M, Petterson GB. Percutaneous cardioplegic arrest before repeat sternotomy in patients with retrosternal aortic aneurysm. *J Thorac Cardiovasc Surg* 2020. <https://doi.org/10.1016/j.jtcvs.2019.09.191>.
- Poulin F, Horlick EM, David T, Woo A, Thavendiranathan P. 3-Dimensional transesophageal echocardiography-guided closure of a Gerbode shunt due to CorMatrix patch dehiscence. *J Am Coll Cardiol* 2013;62:e5.
- Iop L, Palmosi T, Dal Sasso E, Gerosa G. Bioengineered tissue solutions for repair, correction and reconstruction in cardiovascular surgery. *J Thorac Dis* 2018;10(suppl 20):S2390-411.
- Dobrilovic N, Soukas P, Sadiq I, Goldstein L, Raman J. Early complications of biologic extracellular matrix patch after use for femoral artery repair. *J Vasc Surg* 2017;65:705-10.
- Carrel T, Hurni S, Huber C, Englberger L. Simplified approach for repair of early pseudoaneurysm of the left coronary button following composite graft due to acute type A aortic dissection. *Aorta (Stamford)* 2016;4:244-7.
- Luk A, David TE, Butany J. Complications of Bioglue postsurgery for aortic dissections and aortic valve replacement. *J Clin Pathol* 2012;65:1008-12.