

REVIEW

Open Access



A framework for the evaluation of patients with congenital facial weakness

Bryn D. Webb^{1,2*} , Irini Manoli³, Elizabeth C. Engle^{4,5,6} and Ethylin W. Jabs^{1,2}

Abstract

There is a broad differential for patients presenting with congenital facial weakness, and initial misdiagnosis unfortunately is common for this phenotypic presentation. Here we present a framework to guide evaluation of patients with congenital facial weakness disorders to enable accurate diagnosis. The core categories of causes of congenital facial weakness include: neurogenic, neuromuscular junction, myopathic, and other. This diagnostic algorithm is presented, and physical exam considerations, additional follow-up studies and/or consultations, and appropriate genetic testing are discussed in detail. This framework should enable clinical geneticists, neurologists, and other rare disease specialists to feel prepared when encountering this patient population and guide diagnosis, genetic counseling, and clinical care.

Keywords: Congenital facial weakness, Facial paralysis, Clinical genetics, Clinical characterization

Clinical characteristics: congenital facial weakness

Congenital facial weakness (CFW) refers to decreased facial movement present at birth secondary to impaired function of facial musculature. CFW may be secondary to a defect in the motor nucleus of the facial nerve or the facial nerve itself (cranial nerve 7; CN7) (neurogenic), a defect at the neuromuscular junction, an inherent muscular problem (myopathic), or other unknown or mixed causes (Fig. 1). Congenital facial paralysis (CFP) is decreased (palsy/paresis) or absent (paralysis) facial movement present at birth that results specifically from loss of facial nerve function. CFP may be caused by an abnormal developmental process or other causes, including the most common cause of trauma, as in the case of temporary or permanent CFP resulting from the use of forceps during delivery. The differential provided in this review is useful after exclusion of post-traumatic CFP. An appropriate history and temporary CFP are important considerations for diagnosis of traumatic CFP.

CFW may be unilateral or bilateral and may be partial or complete (Fig. 2). Complete CFW refers to complete absence of facial movement in all four quadrants of the face (right upper quadrant, right lower quadrant, left upper quadrant, and left lower quadrant). Patients with complete absence of facial movement on the left side of the face may be described as having unilateral (left) complete CFW. Similarly, patients with reduced facial movement on the left side of the face may be described as having unilateral (left) partial CFW. Clinical characteristics of CFW may include: facial droop; absence of forehead, nasolabial, or periorbital folds; lagophthalmos (incomplete eyelid closure); open mouth posture or u-shaped upper lip; drooling; and inability to make facial expressions, wrinkle the forehead, whistle, and/or difficulties with articulation of labial consonants.

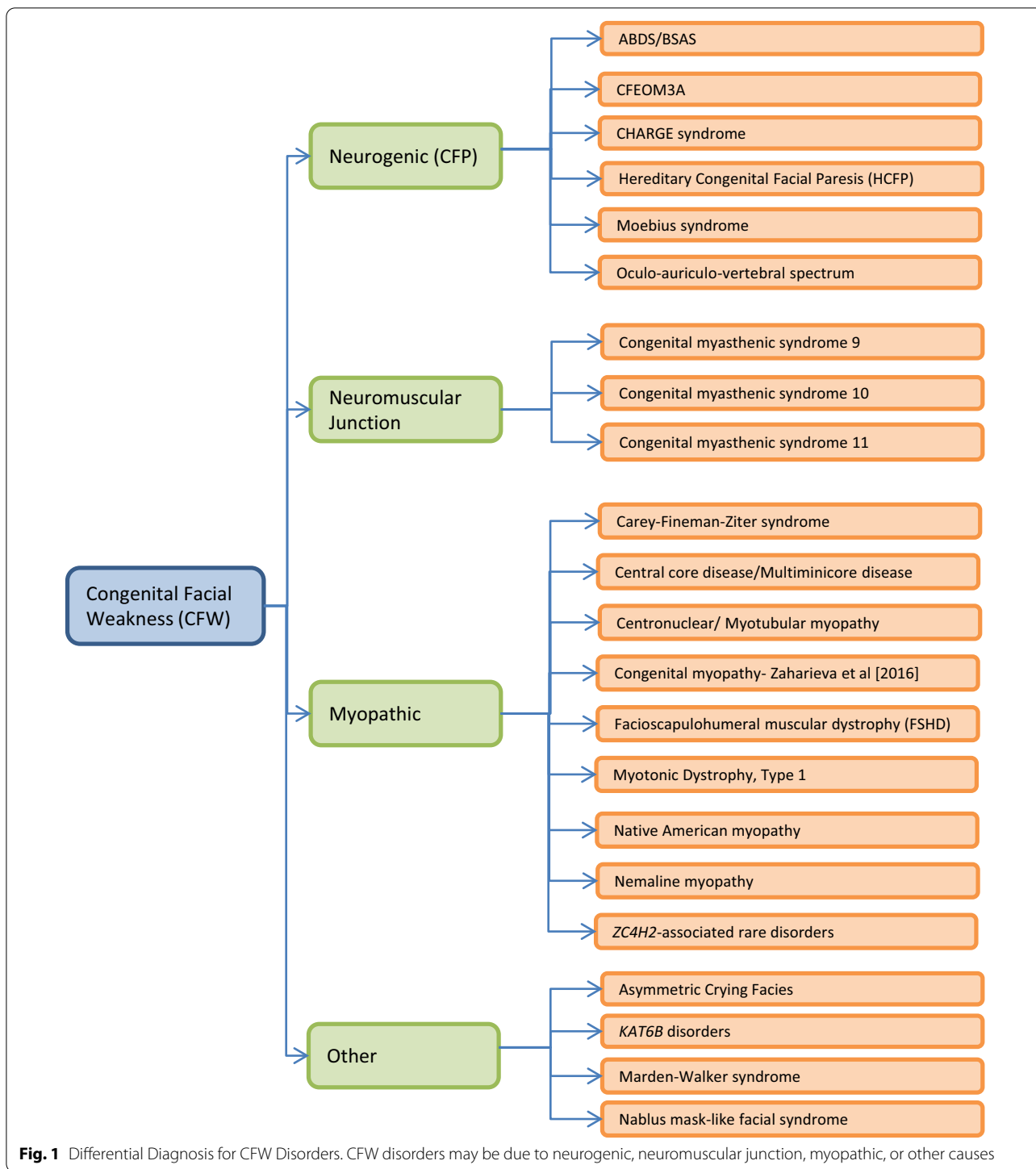
In some cases of CFW, recruitment of other musculature can result in asymmetric synkinesis of facial and neck musculature. Most commonly, synkinesis affects the eye and facial muscles. During voluntary movement of the mouth, there may be involuntary eye closure, and

*Correspondence: bryn.webb@mssm.edu

¹ Department of Genetics and Genomic Sciences, Icahn School of Medicine at Mount Sinai, New York, NY, USA

Full list of author information is available at the end of the article





during voluntary movement of the eye, there may be involuntary mouth or neck muscle movements [1].

In diagnosing CFW, it is important to establish that the facial weakness indeed was present at birth, as facial

weakness may also be *acquired*, resulting from a different set of etiologies including infection (Bell’s palsy), neoplasia, or neurodegeneration.

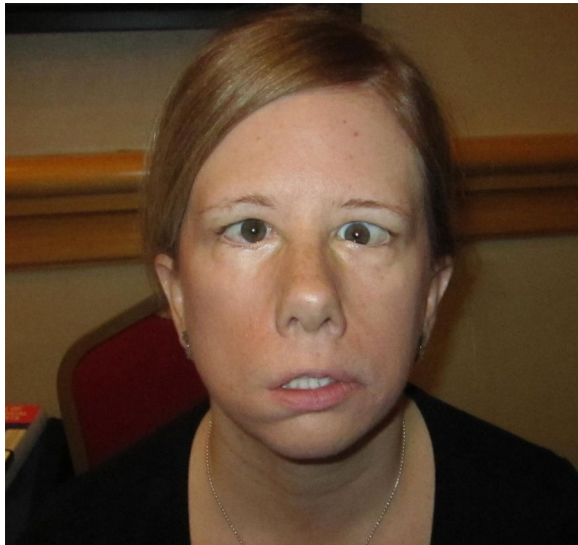

Fig. 2 CFW seen in an adult female. This adult female with Moebius syndrome has CFW, often described as causing a “mask-like” facial appearance. She has bilateral CFP and is more affected on her right side

Differential diagnosis of congenital facial weakness

There is a broad differential for disorders with a prominent characteristic of CFW. This differential includes neurogenic, neuromuscular junction, myopathic, and other unknown or mixed causes (Fig. 1).

Neurogenic causes of congenital facial weakness

There are a wide variety of neurogenic causes of congenital facial weakness including Athabascan brain stem dysgenesis/Bosley-Salih-Alorainy syndrome, congenital fibrosis of the extraocular muscles (CFEOM) type 3A, CHARGE syndrome, hereditary congenital facial paresis, Moebius syndrome, and oculo-auriculo-vertebral spectrum (Fig. 1 and Table 1).

Athabascan brain stem dysgenesis syndrome (ABDS) (ORPHA:69739)/ **Bosley-Salih-Alorainy syndrome (BSAS)** (ORPHA:69737)

Athabascan brain stem dysgenesis syndrome (ABDS) and Bosley-Salih-Alorainy (BSAS) syndrome are allelic *HOX* gene disorders caused by recessive, pathogenic loss-of-function variants in the gene *HOXA1*. The *HOX* genes are homeodomain containing proteins that are critical for anterior–posterior differentiation in the developing embryo. In the developing vertebrate central nervous system, *HOX* genes function in hindbrain or rhombencephalon development. BSAS was first identified in Saudi Arabian and Turkish families [2, 3], while ABDS was

first identified in Native American families [2, 4]. BSAS and ABDS are characterized by horizontal gaze palsy in which there is absent to markedly restricted ocular abduction and adduction. In some cases the horizontal gaze palsy is accompanied by retraction of the globe and narrowing of the palpebral fissure on attempted adduction, consistent with the diagnosis of Duane syndrome type 3. Most individuals with BSAS and ABDS also have bilateral sensorineural hearing loss caused by an absent cochlea and rudimentary inner-ear development and absent or hypoplastic carotid arteries with a corresponding absence of the carotid canal through which the artery normally passes. Approximately 20% of patients with BSAS or ABDS have congenital facial palsy [5]. Some affected individuals also have intellectual disability, autism spectrum disorder, moderate-to-severe central hypoventilation, swallowing difficulties, vocal cord paresis, conotruncal heart defects, macrocephaly, and malformations of inner ear bones and/or petrous bones. Individuals with simplex isolated Duane syndrome have not been found to harbor pathogenic variants in *HOXA1* [2].

Congenital fibrosis of the extraocular muscles 3A **with or without extraocular involvement (CFEOM3A)** (ORPHA:45358)

Congenital fibrosis of the extraocular muscles 3 (CFEOM3A) is a complex eye movement disorder with ptosis and restricted vertical and horizontal gaze with or without congenital facial palsy and non-ocular manifestations caused by a heterozygous, pathogenic missense variants in *TUBB3*, which encodes a beta-tubulin protein [6]. At least three specific *TUBB3* mutations are associated with CFEOM and CFP (c.1228G>A;p.Glu410Lys; c.785G>A;p.Arg262His; and c.1249G>C;p.Asp417His). Of these, the c.1228G>A;p.Glu410Lys variant is best defined, and the disorder caused by this specific mutation is known as the TUBB3 E410K syndrome. Features of the TUBB3 E410K syndrome (CFEOM3A, MIM #600638) include CFEOM, bilateral CFP, developmental delay, progressive sensorimotor polyneuropathy, Kallmann syndrome, stereotyped midface hypoplasia, and in some cases, vocal cord paralysis, tracheomalacia, and cyclic vomiting [7]. Patients with TUBB3 p.Arg262His and p.Asp417His mutations present with CFEOM, CFP, developmental delay, progressive sensorimotor polyneuropathy, and congenital joint contractures [6].

CHARGE syndrome (ORPHA:138)

CHARGE syndrome is a CFW syndrome due to heterozygous pathogenic variants in the gene *CHD7*, a chromatin helicase protein. CHARGE is a mnemonic for coloboma, heart defects, choanal atresia, retarded growth

Table 1 Differential diagnosis for CFW disorders

Disorder Gene		Neurogenic CFW					
		Athabaskan brainstem dysgenesis syndrome/ Bosley-Salih-Alorainy syndrome	Congenital fibrosis of the extraocular muscles 3A with or without extraocular involvement ¹	CHARGE syndrome	Hereditary congenital facial paresis type 3	Moebius syndrome ²	Oculo-auriculo-vertebral spectrum
	<i>HOXA1</i>		<i>TUBB3</i>	<i>CHD7</i>	<i>HOXB1</i>	<i>PLXND1, REV3L</i>	N/A
Mode of Inheritance	AR	AD	AD	AD	AR	IC; AD (rare)	IC; AD (rare)
Phenotype MIM #	#601536	#600638	#214800	#614744	#614744	%157900	%164210
ORPHA #	69739/69737	45358	138	306530	306530	570	141132
Distinguishing Clinical Features Summary	Limited horizontal gaze and sensorineural hearing loss are the most common features; CFW in ~20% of cases. Other specific features include carotid artery anomalies, conotruncal heart defects, and central hypoventilation	CFEOM and CFW are clinical characteristics of TUBB3 disease caused by p.E410K, R262H, or D417H mutations. Additional developmental delay, progressive axonal sensorimotor polyneuropathy, Kallman syndrome, vocal cord paralysis, cyclic vomiting, and/or congenital joint contractures	Unilateral or bilateral CFW seen in ~40%. Common features include coloboma, microphthalmia, choanal atresia, cranial nerve dysfunction, ear anomalies (external ear abnormalities, ossicular malformations, Mondini defect of the cochlea, temporal bone abnormalities, and/or absent or hypoplastic semicircular canals)	Bilateral CFW (100%); Full ocular motility; Strabismus (42%); Sensorineural hearing loss (90%)		Congenital, nonprogressive facial weakness with limitation in abduction of one or both eyes. Associated features may include other cranial nerve involvement, strabismus, hearing loss, club foot, limb reduction defects, other limb anomalies, Poland anomaly, developmental delay, and autism. For most persons with Moebius syndrome, the etiology is unknown	CFP seen in ~10–45% of affected individuals. Characterized by facial asymmetry, preauricular or facial tags, ear malformations, microtia/anothia, and hearing loss

Table 1 (continued)

Disorder gene	HPO Term	Neuromuscular CFW		Myopathic CFW		Central core disease/Multiminicore disease				
		Congenital myasthenic syndrome 9 associated with acetylcholine receptor deficiency	Congenital myasthenic syndrome 10	Congenital myasthenic syndrome 11 associated with acetylcholine receptor deficiency	Carey-Fineman-Ziter syndrome	<i>RYR1</i>	<i>SEPN1</i>	<i>BIN1</i>	<i>DNM2</i>	<i>MTM1</i>
<i>MUSK</i>		<i>DOK7</i>		<i>RAPSN</i>	<i>MYMK</i>	<i>RYR1</i>	<i>SEPN1</i>	<i>BIN1</i>	<i>DNM2</i>	<i>MTM1</i>
AR		AR	AR	AR	AR	AD, AR	AD, AR	AR	AD	XLR
Phenotype MIM #	#616325	#254300	#254300	#616326	#254940	#11700	#255310	#255200	#160150	#310400
ORPHA #	590	590	590	590	1358	597	2020	595	595	596
Distinguishing Clinical Features Summary	<i>MUSK</i> disease is characterized by early-onset muscle weakness with variable severity. Patients present with facial weakness, ptosis, ophthalmoplegia, episodic respiratory insufficiency and proximal muscle weakness	Clinical features of <i>DOK7</i> disease include limb-girdle pattern of weakness, waddling gait, ptosis, facial weakness, but rare is ophthalmoparesis	Clinical features of <i>DOK7</i> disease include limb-girdle pattern of weakness, waddling gait, ptosis, facial weakness, but rare is ophthalmoparesis	<i>RAPSN</i> disease may present in neonates. Some affected individuals have weakness confined to facial and masticatory muscles. Arthrogryposis multiplex congenita seems to be particularly common in infants with truncating <i>RAPSN</i> mutations	Clinical features include facial weakness, full ocular movements, upturned/broad nasal tip, micro/retrognathia, normal cognition, delayed motor milestones, and generalized muscle hypoplasia. Additional occasional signs and symptoms are congenital contractures, growth failure, feeding problems, ptosis, cleft palate, gastrojejunostomy, thin tubular neck, pectoralis hypoplasia, hypoglossia, scoliosis, pulmonary hypertension, and/or cryptorchidism	Characterized by muscle weakness and hypotonia. Symptoms may range from mild to severe. In early-onset disease, newborns may have respiratory insufficiency, facial weakness, and poor suck	Characterized by muscle weakness and hypotonia. Symptoms may range from mild to severe. In early-onset disease, newborns may have respiratory insufficiency, facial weakness, and poor suck	Pathogenic variants in <i>BIN1</i> have been described in a small group of individuals. Facial weakness may be present. The range of clinical severity is broad; presentation in infancy has been reported	Onset ranges from early (associated with severe disease) and late childhood or adulthood (associated with mild disease). Findings may include facial and extraocular muscle weakness, ptosis, and extremity weakness	Severe disease manifests prenatally with polyhydramnios and decreased fetal movement; newborns have profound weakness, hypotonia, and respiratory failure that usually requires ventilatory support. Facial and extraocular muscles are often involved resulting in myopathic facies and ophthalmoparesis, respectively. Motor milestones are significantly delayed and most affected males fail to achieve independent ambulation

Table 1 (continued)

Disorder Gene	HPO Term	Myopathic CFW																	
		Congenital myopathy-Zaharieva et al. [2016] ³		Facioscapulohumeral muscular dystrophy	Myotonic dystrophy, type 1	Native American myopathy	Nemaline myopathy												ZC4H2-associated rare disorders
		SCN4A	DUX4	SMCHD1	DMPK	STAC3	ACTA1	KLHL40	NEB	TPM2	TPM3	ZC4H2							
Mode of Inheritance		AR	AD	AD	AD	AR	AD,AR	AR	AR	AD	AD,AR	XLR							
Phenotype MIM #		N/A	#158900	#158901	#160900	#255995	#161800	#615348	#256030	#609285	#609284	#314580							
ORPHA #		N/A	269	269	273	168572	607	607	607	607	607	3454							

Table 1 (continued)

Disorder Gene	HPO Term	Mixed/unknown CFW	Marden-Walker syndrome ⁵	Nabbus mask-like facial syndrome
		Asymmetric crying facies ⁴	<i>PIEZO2</i>	8q22.1
Mode of Inheritance		IC; AD	IC; AD	AD
Phenotype MIM #		#125520	#603736	#608156
ORPHA #		1166	3047	178303
Distinguishing Clinical Features Summary		Congenital hypoplasia of the depressor anguli oris muscle; congenital heart defects; microcephaly; intellectual impairment	Severe blepharophimosis, an immobile mask-like face, severe hypotonia and feeding problems, dislocated patellae, structural cardiac defects, pointed teeth, hypothyroidism, severe intellectual impairment	Blepharophimosis, tight-appearing glistening facial skin, an abnormal hair pattern with an upswept frontal hair-line, sparse arched eyebrows, flat and broad nose, long philtrum, distinctive ears, and a happy demeanor

¹ The name listed in OMIM is Congenital fibrosis of the extraocular muscles 3A with or without extraocular involvement; however, extraocular muscle involvement is required for the diagnosis

² Identification of potentially pathogenic variants in *PLXND1* or *REV3L* for Moebius syndrome is extremely rare

³ Zaharieva et al. [2016], PMID=26700687

⁴ Some cases of asymmetric crying facies are associated with 22q11 deletion

⁵ Identification of potentially pathogenic variants in *PIEZO2* is extremely rare for Marden-Walker syndrome

Abbreviations: AD= autosomal dominant; AR= autosomal recessive; XLR= X-linked recessive; IC= isolated recessive; N/A= not applicable; MIM= Online Mendelian Inheritance in Man; ORPHA= Orphanet; HPO= Human Phenotype Ontology

and development, genital abnormalities, and ear anomalies. 39% of *CHD7* mutation positive CHARGE syndrome patients were noted to have unilateral or bilateral CFW [8]. Other notable clinical features include additional cranial nerve dysfunction, impaired hearing, swallowing difficulties, hypogonadotropic hypogonadism, orofacial clefts, and/or tracheoesophageal fistula.

Hereditary Congenital Facial Paresis (HCFP) (ORPHA:306530)

Hereditary congenital facial paresis (HCFP) is a disorder with apparently isolated dysfunction of the facial nerve of germline genetic etiology. HCFP type 3 (HCFP3) results from recessive pathogenic loss-of-function variants in the *HOXB1* gene [9]. At present, 17 affected individuals from 6 separate families have been identified [9–13]. All 17 affected patients had bilateral CFW and were described as having masked-like facies. Eleven of 15 patients or 73% were noted to have sensorineural hearing loss (information unavailable for 2 patients). Seven of 17 or 41% of patients were noted to have esotropia. Patients had full ocular motility, and thus did not meet the minimum diagnostic criteria for Moebius syndrome (see below). Dysmorphic features included midface retrusion (16 of 17 patients or 94%), upturned nasal tip (13 of 17 patients or 76%), smooth philtrum (12 of 17 patients or 71%), and low-set ears (5 of 17 patients or 29%) [9–12]. Four affected members of one family harboring a homozygous *HOXB1* c.66C>G;p.Tyr22* mutation and 3 members of a family harboring a homozygous c.296_302del;p.Y99Wfs*20 mutation were noted to have external ear/auricular malformations; these external ear malformations have not been seen in the 4 other families who harbor different *HOXB1* mutations [9–11, 13].

Two additional genetic loci (HCFP1 (MIM %601471) and HCFP2 (MIM %604185) have been reported in large autosomal dominant pedigrees with incomplete penetrance [14–16]. Both loci are associated with unilateral or bilateral facial palsy; some individuals with HCFP2 also had hearing loss (a few cases associated with anomalous formation of the petrous portion of the temporal bone). Ocular movements are reported to be normal [14, 16].

Moebius syndrome (ORPHA:570)

Due to discrepancies and confusion in the literature, Moebius syndrome was defined at the Scientific Conference on Moebius Syndrome in 2007 as congenital, non-progressive facial weakness with limited abduction of one or both eyes [17]. More recently, addition of the criterion of full ocular vertical motility to the minimum diagnostic criteria was suggested [18]. Given the diagnostic criteria, all persons with Moebius syndrome have CFW. The CFW may be unilateral or bilateral as well as partial or complete. Moebius subjects can present with additional

clinical manifestations, which can include bilateral horizontal gaze palsy, other cranial nerve dysfunction, craniofacial and limb deformities (e.g. Poland syndrome and clubbed foot), mirror movements, sleep disorders, seizures, and neurocognitive and social impairments.

For the majority of cases of Moebius syndrome, the etiology is unknown. Both genetic and environmental etiologies have been proposed. Additionally, prenatal exposure to misoprostol and other agents has been known to be associated with a Moebius syndrome phenotype [19, 20]. De novo heterozygous missense *PLXND1* variants were reported in three individuals with Moebius syndrome and variable dysmorphic features (including microcephaly, epicanthal folds, flat nasal bridge, micrognathia, external ear defects, dental defects, clinodactyly, and low-set thumbs) [21]. However, one of these three individuals was noted to have a synonymous variant in *PLXND1* that is not predicted to alter splicing and, therefore, is presumed not to affect gene function. Additionally, three individuals were reported with de novo, heterozygous missense variants in *REV3L* (two with Moebius syndrome and one with isolated CFW without a defect in ocular motility), suggesting that HCFP and Moebius syndrome may be allelic disorders. Analysis of *Plxnd1* and *Rev3l* mutant mice revealed hypoplasia of the facial motor nucleus [21]. To date confirmation of additional cases of Moebius syndrome or CFW with mutations in these genes has not been reported.

Oculo-auriculo-vertebral spectrum (ORPHA:141132)

Oculo-auriculo-vertebral spectrum is a developmental disorder involving abnormal development of the first and second pharyngeal arches. Characteristic findings include facial asymmetry resulting from maxillary and/or mandibular hypoplasia; preauricular or facial tags; ear malformations such as microtia, anotia, or aural atresia; and hearing loss. The phenotype is heterogeneous and ranges from subtle asymmetries to frank, bilateral craniofacial involvement with involvement of other organ systems. Facial palsy (unilateral or bilateral involvement of either part or all branches of CN7) is observed in ~10–45% of affected individuals [22], and other cranial nerve abnormalities may also be seen. Other craniofacial malformations that may be present include cleft lip and/or palate. Non-craniofacial malformations involving skeletal, renal, and cardiac systems may be seen. The etiology in most cases is currently unknown.

Neuromuscular junction causes of congenital facial weakness

Neuromuscular causes of congenital facial weakness include the congenital myasthenic syndromes, particularly types 9, 10, and 11 (Table 1).

Congenital myasthenic syndrome (CMS), types 9, 10, and 11 (ORPHA:590)

Congenital myasthenic syndromes are a group of disorders characterized by skeletal muscle weakness that worsens with exercise (myasthenia). The defect is due to recessive loss-of-function mutations in genes that encode proteins that function at the neuromuscular junction. While most congenital myasthenic syndromes may result in CFW, CFW is most typical in types 9, 10, and 11 [23–25]. Additional associated features may include ophthalmoplegia with congenital myasthenic syndrome, type 9 [26], respiratory muscle weakness with types 9, 10, and 11 [24, 27], and joint contractures and arthrogryposis, particularly with type 11. Treatment with cholinesterase inhibitors may be helpful for congenital myasthenic syndrome, type 9, treatment with cholinesterase inhibitors or amifampridine may be helpful for myasthenic syndrome, type 11 [27], and treatment with ephedrine may be helpful for congenital myasthenic syndrome type 10 [28].

Myopathic causes of congenital facial weakness

CFW has been associated with both congenital myopathies and muscular dystrophies. The congenital myopathies with CFW include Carey-Fineman-Ziter syndrome, central core disease/multiminicore disease, centronuclear/myotubular myopathy, congenital myopathy reported by Zaharieva et al., Native American myopathy, Nemaline myopathy, and *ZC4H2*-associated rare disorders. The muscular dystrophies include myotonic dystrophy, type 1 and infantile facioscapulohumeral muscular dystrophy (Table 1).

Carey-Fineman-Ziter syndrome (CFZS) (ORPHA:1358)

Carey-Fineman-Ziter syndrome, also known as congenital nonprogressive myopathy with Moebius sequence and Robin sequence, was first described by Carey et al. in 1982 in two siblings with Moebius sequence, Pierre Robin sequence, hypotonia, growth delay, and normal cognition. One sibling developed restrictive lung disease and died of pneumonia at age 37 years [29, 30]. CFZS results from recessive mutations in the *MYMK* gene [31]. *MYMK* encodes myomaker, a protein necessary for fusion of myoblasts to form multinucleated myofibers [31]. Compound heterozygous *MYMK* mutations were identified in the initial affected siblings reported by Carey et al., as well as 6 additional affected individuals from 4 additional families. All 8 affected individuals had facial weakness, an upturned/broad nasal tip, micro/retrognathia, delayed motor milestones, generalized muscle hypoplasia, and normal cognition. Some also had downslanting palpebral fissures, epicanthal folds, flat nasal root, and mandibular hypoplasia. None had an

abducens nerve palsy, a required feature for the diagnosis of Moebius syndrome [31].

Central core disease (ORPHA:597)/multiminicore disease (ORPHA:2020)

Central core disease and multiminicore disease may be caused by pathogenic variants in *RYR1* or *SEPNI*. Central core disease is named due to the presence of disorganized areas of ‘central cores’ seen on muscle biopsy, while multiminicore is named due to disorganized ‘minicores’.

Mutations in *RYR1* may cause autosomal recessive or autosomal dominant central core disease, autosomal recessive minicore myopathy with external ophthalmoplegia, and autosomal recessive or autosomal dominant neuromuscular disease, congenital, with uniform type 1 fiber. *RYR1* encodes the skeletal muscle ryanodine receptor, which is a ligand-gated calcium channel important in calcium signaling in the sarcoplasmic reticulum. For autosomal dominant central core disease, onset is typically at birth or early childhood with features of facial weakness and nonprogressive limb weakness, or in early childhood with nonprogressive limb weakness and hypotonia. Affected patients generally survive to adulthood. Multiminicore myopathy due to recessive mutations in *RYR1* presents generally in infancy with external ophthalmoplegia, limb weakness, and wasting of hip girdle muscles similar to central core disease [32]. Additional features include bulbar, facial, or respiratory weakness, and joint abnormalities including hyperlaxity, contractures, and arthrogryposis. Rare cases of autosomal recessive inheritance, with homozygous or compound heterozygous *RYR1* mutations have been described presenting with severe congenital ophthalmoplegia and facial weakness in the setting of only mild skeletal myopathy. These patients were susceptible to malignant hyperthermia [33].

Mutations in the selenoprotein N gene (*SEPNI*) have been identified in individuals with multiminicore disease, muscular dystrophy with rigid spine, and congenital myopathy with fiber-type disproportion. Homozygous or compound heterozygous mutations in *SEPNI* cause autosomal recessive multiminicore disease. Multiminicore disease is broadly classified into four groups: classic form (75% of individuals); moderate form with hand involvement (<10%); antenatal form with arthrogryposis multiplex congenita (<10%); and ophthalmoplegic form (<10%) [34]. Onset of the classic form is usually at birth or early in childhood with hypotonia, delayed motor milestones, scoliosis, and significant respiratory involvement. Most patients with multiminicore disease and *SEPNI* mutations exhibit a variable degree of facial weakness [34, 35].

Centronuclear (ORPHA:595, 596)/myotubular myopathy

Centronuclear/myotubular myopathy may be caused by homozygous or compound heterozygous pathogenic variants in the gene *BINI*, heterozygous pathogenic variants in the gene *DNM2*, or hemizygous pathogenic variants in *MTM1*. Muscle biopsy in these conditions reveals small, rounded myofibers with increased percentages of centrally located nuclei. Pathogenic variants in *BINI* have been described in a small group of individuals. *BINI* encodes amphiphysin-2, which binds to DNEM2 during clathrin-dependent endocytosis [36]. The range of clinical severity is broad, and CFW has been reported.

DNM2 encodes dynamin-2-protein, a large GTPase protein involved in clathrin-dependent and clathrin-independent endocytosis and intracellular membrane trafficking. For *DNM2* centronuclear/myotubular myopathy, the range of symptoms in affected individuals is broad, and severe disease may present with CFW. Findings may include facial and extraocular muscle weakness, ptosis, and extremity weakness [36].

MTM1 encodes myotubularin, a tyrosine phosphatase protein required for muscle cell differentiation. Myopathy due to *MTM1* mutations is also known as X-linked centronuclear myopathy (CNMX). In CNMX, muscle weakness ranges from mild to severe (classic disease). The muscle disease of CNMX is not obviously progressive. CFW may be present in severe/classic disease. Female carriers of CNMX are generally asymptomatic.

Congenital myopathy-Zaharieva et al. [2016]

Recessive loss of function homozygous or compound heterozygous variants in *SCN4A*, which encodes sodium voltage-gated channel, alpha subunit 4, have been reported to cause a spectrum of disease ranging from severe fetal hypokinesia to a 'classical' congenital myopathy. Affected individuals from four families with compound heterozygous pathogenic variants in *SCN4A* were reported to have symptoms of a congenital myopathy, and all were noted to have mild to moderate facial weakness that was either present at birth (3 of 4 families with CFW) or developed during the first few days of life (1 family). Associated features included moderate to severe hypotonia, reduced muscle bulk, and neck, axial, and limb weakness [37].

Facioscapulohumeral muscular dystrophy (FSHD) (ORPHA:269)

Facioscapulohumeral muscular dystrophy (FSHD) type 1 is an autosomal dominant condition caused by mutations in *DUX4* [38]. FSHD typically presents before age 20 years with weakness of the facial muscles and the stabilizers of the scapula or the dorsiflexors of the foot. There is extreme clinical variability. In some cases, CFW

may be present. In FSHD, the muscle weakness is slowly progressive and approximately 20% of affected individuals eventually require a wheelchair. Life expectancy is not shortened. The incidence is approximately 4 individuals affected per 100,000 people [38].

Although some controversy remains, FSHD is likely caused by inappropriate expression of the double homeobox-containing gene *DUX4* in muscle cells. *DUX4* lies in the macrosatellite repeat D4Z4 on chromosome 4q35, which has a length between 11 and 100 repeat units on normal alleles. Approximately 95% of individuals with FSHD have a D4Z4 allele of between one and ten repeat units. The shortening of the D4Z4 allele causes chromatin relaxation at the D4Z4 locus and *DUX4* promoter and thereby derepression of *DUX4*. This common form of FSHD is designated facioscapulohumeral muscular dystrophy 1 (FSHD1). Molecular genetic testing measures the length of the D4Z4 allele [38].

Myotonic dystrophy, type 1 (DM1) (ORPHA:273)

Myotonic dystrophy type 1 (DM1) is a multisystem disorder that affects skeletal and smooth muscle as well as the ocular, cardiovascular, endocrine, and central nervous systems. The clinical findings, which span a continuum from mild to severe, have been categorized into three overlapping phenotypes: mild, classic, and congenital. Congenital DM1 is characterized by hypotonia and severe generalized weakness at birth, including CFW. Affected infants often have an inverted V-shaped upper lip, which is characteristic of significant facial diplegia. Before birth polyhydramnios and reduced fetal movement may be noted. Positional malformations such as club foot and respiratory insufficiency leading to early death may also occur. Intellectual disability is common.

DM1 is caused by expansion of a CTG trinucleotide repeat in the non-coding region of *DMPK*. A normal allele has 5–34 CTG repeats, a premutation allele has 35–49 CTG repeats, and a full penetrance allele has ≥ 50 CTG repeats. Congenital DM1 is associated with a repeat size of >1000 CTG repeats. Generally, CTG repeat expansion causing congenital DM1 occurs when the mother is transmitting the abnormal allele [39].

Native American myopathy (NAM) (ORPHA:168572)

Native American myopathy is an autosomal recessive condition originally identified in the Lumbee Native American population of North Carolina, which presents with features of congenital onset of muscle weakness, susceptibility to malignant hyperthermia, multiple joint contractures, ptosis, and dysmorphic features. All reported patients had myopathic facies and hypotonia and generalized weakness present from birth. Muscle biopsies of affected individuals reveal a non-specific

myopathic pattern. Affected Native American individuals with Native American myopathy were identified to have a homozygous *STAC3* pathogenic variant, c.1046G>C;p.Trp284Ser [40].

Subsequently Native American myopathy also has been identified in individuals of non-Lumbee Native American descent and additional pathogenic variants other than the p.Trp284Ser variant have now been identified [41–43]. Native American myopathy has overlapping features with Moebius and Carey-Fineman-Ziter syndromes [42].

Nemaline myopathy (ORPHA:607)

Nemaline myopathy (NM) is named for the finding on muscle biopsy of abnormal rod-like structures within muscle cells termed nemaline bodies [44]. It can be caused by pathogenic variants in multiple genes, including *ACTA1*, *KLHL40*, *NEB*, *TPM2*, and *TPM3*.

ACTA1 encodes the skeletal muscle protein alpha-actin, which forms the core of the thin filament of the sarcomere that functions in muscle contraction. Biallelic pathogenic variants in *ACTA1* cause autosomal recessive NM; heterozygous pathogenic variants cause autosomal dominant NM3. *ACTA1* disease causes 20–25% of all nemaline myopathy, but 50% of severe nemaline myopathy. The age of presentation ranges from severe congenital myopathy to later childhood onset. Facial weakness may be present.

KLHL40, or kelch-like family member 40, is a protein that is necessary for sarcomere structure and contractility [45]. Biallelic pathogenic variants in *KLHL40* cause autosomal recessive nemaline myopathy 8. Findings are severe congenital lethal disease or fetal akinesia. In addition to severe fetal akinesia or hypokinesia, contractures, fractures, respiratory failure, and swallowing difficulties at birth, facial weakness was present at birth in all 26 individuals studied by Ravenscroft et al. [46].

NEB encodes nebulin, a cytoplasmic matrix protein in skeletal muscle. Biallelic pathogenic variants in *NEB* cause autosomal recessive, nemaline myopathy 2, which accounts for about 50% of cases of nemaline myopathy. The phenotype of the typical congenital form includes presentation within the first year of life with hypotonia, limb weakness, facial weakness, feeding difficulty, and respiratory weakness. The muscle disease is either static or slowly progressive such that most affected individuals survive to adulthood and live independently. Less common presentations are: death in utero due to fetal akinesia; severe hypotonia and weakness; CFW with a poor suck and swallow at birth; or predominantly distal weakness in older individuals [44].

TPM2 encodes beta-tropomyosin, a component of the thin filament of the sarcomere, and is primarily expressed in slow, type 1 skeletal muscle fibers. Heterozygous

pathogenic variants in *TPM2* cause autosomal dominant nemaline myopathy 4 which accounts for <1% of cases of nemaline myopathy. *TPM2* nemaline myopathy is generally causative of a typical congenital phenotype and is commonly associated with involvement of the masticator muscles and distal lower leg muscles. Affected patients typically have a myopathic face with facial diplegia.

TPM3 encodes alpha-tropomyosin, another thin filament component of the sarcomere. Biallelic pathogenic variants and heterozygous pathogenic variants in *TPM3* cause autosomal recessive or autosomal dominant nemaline myopathy, 1, respectively which accounts for ~2–3% of cases of nemaline myopathy. *TPM3* disease phenotypic range includes severe congenital (autosomal recessive; ~16% of cases), intermediate congenital, or childhood onset (autosomal dominant) types. Findings include weakness that is predominantly proximal and generalized with or without facial weakness; hypotonia and depressed deep tendon reflexes, with preserved sensation and normal cognition; and feeding difficulties related to facial and bulbar weakness, respiratory difficulties, recurrent infections or a weak cough related to restrictive lung disease from weakness of the respiratory muscles [44].

ZC4H2-associated rare disorders (ZARD) (ORPHA:3454)

ZC4H2-associated rare disorders includes a spectrum of disease with arthrogryposis multiplex and peripheral and central nervous system involvement [47]. This spectrum includes Wieacker-Wolff syndrome (WRWF), an X-linked recessive condition caused by pathogenic variants in *ZC4H2*. *ZC4H2* encodes a zinc-finger protein, expressed in a variety of tissues. Boys with WRWF generally had decreased fetal movements in utero and are born with severe contractures. Additional clinical findings include delayed motor development, CFW, bulbar weakness, characteristic dysmorphic facial features (carp-like mouth, narrow palate, micrognathia, long philtrum, upturned nares, and short neck), skeletal abnormalities such as hip dislocation, scoliosis, pes equinovarus, intellectual disability, and Duane syndrome. Carrier females may exhibit mild features of the disorder due to skewed X-chromosome inactivation [48].

Other, Including Unknown or Mixed Causes of Congenital Facial Weakness

There are other causes of CFW that are of other unknown or mixed etiology. These types of CFW include asymmetric crying facies, *KAT6B* disorders, Marden-Walker syndrome, and Nablus mask-like facial syndrome.

Asymmetric crying facies (ACF) (ORPHA:1166)

Asymmetric crying facies (ACF) describes newborns with unilateral facial weakness noticed when the infant

cries. Primary (myopathic) or secondary (neurogenic) agenesis or hypoplasia of the depressor anguli oris muscle may cause developmental forms of asymmetric crying facies, which is also known as congenital unilateral lower lip palsy (CULLP). ACF may be associated with heart defects and/or deletion 22q11 [49].

***KAT6B* disorders (ORPHA:3047)**

KAT6B disorders include Say-Barber-Biesecker-Young-Simpson syndrome (SBBYSS), characterized by distinctive facial features including severe blepharophimosis, an immobile, mask-like face, a bulbous nasal tip, and a small mouth with a thin upper lip; neurologic findings including severe hypotonia and feeding problems in infancy, severe intellectual disability, delayed motor milestones, and significantly impaired speech; and skeletal findings including joint laxity, abnormally long thumbs and great toes, and dislocated or hypoplastic patellae. The mask-like facial appearance is due to bilateral CFW. Other common findings are congenital heart defects (~50%), dental anomalies (small and pointed teeth), and abnormalities of thyroid structure or function. To date, most individuals with a *KAT6B*-related disorder have had a de novo dominant pathogenic variant in the *KAT6B* gene, which encodes a histone acetyltransferase [50].

Marden-Walker syndrome (MWKS) (ORPHA:2461)

Marden-Walker syndrome (MWKS) is characterized by “immobile facies,” blepharophimosis, joint contractures including camptodactyly, scoliosis, cleft palate, diminished muscular bulk, developmental delay, and hind-brain malformations, most commonly Dandy-Walker malformation. For the majority of cases, the etiology is unknown. One patient with MWKS has been identified with a de novo missense mutation (p.R2686C) in *PIEZO2*. Mutations in *PIEZO2* were also found in the phenotypically overlapping syndromes, Gordon syndrome or distal arthrogryposis, type 3 (DA3) and distal arthrogryposis, type 5 (DA5) [51].

Nablus mask-like facial syndrome (ORPHA:178303)

Nablus mask-like facial syndrome is a contiguous gene deletion syndrome at chromosome 8q22.1 characterized by blepharophimosis, tight-appearing glistening facial skin, an abnormal hair pattern with an upswept frontal hairline, sparse arched eyebrows, flat and broad nose, long philtrum, distinctive ears, and a happy demeanor [52–54].

Evaluation strategy for consultants

Establishing a specific cause of congenital facial weakness enables accurate discussions of treatment, management, and prognosis and allows for precise genetic counseling.

Consultations generally begin with a full medical history (including family history) and physical examination. Family history assessment includes an extended pedigree with attention to relatives with related craniofacial findings and documentation of relevant findings through direct examination or review of medical records, including results of molecular genetic testing. Depending on the diagnosis, genetic testing may be indicated (Table 2).

The medical history and physical examination are directed at identifying features associated with specific causes of congenital facial weakness (Table 1, Additional file 1). The consultant should obtain detailed information regarding the onset and severity of the CFW and the presence of additional symptoms. Past medical history, including surgical history, should be obtained with special attention to any incidence of malignant hyperthermia. A genetics evaluation should include dysmorphology assessment that may aid in narrowing the diagnosis. A full cranial nerve examination should be completed as well as an examination for signs and symptoms of primary muscle disease (preferably by a neurologist or neuromuscular specialist). Ocular motility should be assessed (preferably by an ophthalmologist or orthoptist). Patients should receive audiology evaluation as well as a smell test to assess for anosmia. Endocrine evaluation should be performed if there are signs of delayed puberty, growth failure, or thyroid abnormalities. A developmental assessment should be performed if developmental delays are suspected, and feeding or speech therapy and other supportive services may be offered to help with physical and social impairments and improve the quality of life of affected individuals. Additional work-up may include assessment for congenital heart defect, skeletal defects, dental or craniofacial anomalies, or other system involvement, guided by associated findings.

CFP with or without strabismus, but without a limitation in horizontal or vertical ocular movement and without other major systemic involvement is suggestive of HCFP and includes the *HOXB1* syndrome as well as genetically undefined forms of autosomal dominant CFP (HCFP1, HCFP2). Impairment in ocular abduction, with full ocular vertical mobility, in association with CFW suggests a diagnosis of Moebius syndrome [18] or *HOXA1* syndromes. CFP with both horizontal and vertical gaze limitations and ptosis (i.e. CFEOM) may be suggestive of *TUBB3* syndromes and should prompt further evaluations for associated peripheral axonal polyneuropathy, endocrine work-up for Kallmann syndrome, and neurocognitive testing. CFP in combination with a coloboma, deafness, and/or a distinctive ear appearance is suggestive of CHARGE syndrome. CFW in association

Table 2 Evaluation and examination recommended for patients with congenital facial weakness

For all patients with CFW:	
Dysmorphology exam by geneticist	Assess for dysmorphic features Obtain family history Assess for intrauterine exposures
Neurology exam	Full cranial nerve examination including testing for anosmia and hearing Assess for presence of peripheral neuropathy and mirror movements Assess for muscle weakness and signs of myopathy or myotonia
Ophthalmology exam	Assess extraocular movements and for presence of ptosis Assess for aberrant movements such as globe retraction found in Duane syndrome (associated with ABDS/BSAS)
For some patients with CFW:	
ENT referral	Assess for possible hearing loss and temporal bone/ear anomalies
Cardiology referral	Assess for congenital heart defect (associated with BSAS/ABDS, oculo-auriculo-vertebral spectrum disorder, and Moebius syndrome)
Endocrinology referral	Assess for hypogonadotropic hypogonadism/ Kallmann syndrome (associated with CFEOM3 and CHARGE)
Developmental pediatrics referral	Assess for developmental delays
Orthopedics/Physical Medicine and Rehabilitation referral	Assess for scoliosis, limb length discrepancy, and need for orthotics
Craniofacial Team/Dental referral	Assess for orofacial clefting, Pierre Robin sequence, palatal and tongue defects, dental anomalies

If facial asymmetry/hemifacial microsomia ± microtia present, consider a diagnosis of oculo-auriculo-vertebral spectrum disorder and order renal sonogram and cervical x-ray

If characteristic CHARGE ear present, consider a diagnosis of CHARGE syndrome

If ear anomalies are present, consider HCFP3

If Pierre-Robin sequence, cleft palate, scoliosis, and/or contractures are present, consider Carey-Fineman-Ziter or fetal akinesia syndromes

If personal or family history of malignant hyperthermia, consider Native American myopathy or *RYR1* disease

If a specific diagnosis is suspected that is caused by a single gene or few genes, especially in the case of positive family history, order sequencing with deletion/duplication analysis for the suspected genes or *D4Z4* allele contraction testing in the case of facioscapulohumeral muscular dystrophy

When a specific diagnosis caused by a single gene is not suspected, chromosome analysis and chromosomal microarray may be offered. Consider whole exome sequencing

Brainstem/cranial nerve/orbital MRI if considering diagnosis of Moebius syndrome or HCFP to assess for absence or hypoplasia of CN7 and other cranial nerves (1, 3, 6, 8–11). MRI may reveal abnormalities of the corpus callosum, pituitary gland, olfactory sulci and olfactory bulbs in individuals with TUBB3 E410K

EMG, nerve conduction studies to narrow differential

Consider EEG to rule out seizures

Consider muscle biopsy if limb muscles are abnormal

Consider sleep studies depending on history

If weakness of shoulder girdle, consider diagnosis of facioscapulohumeral muscular dystrophy

Isolated congenital lower lip palsy is suggestive of asymmetric crying facies

Peripheral neuropathy may be seen with CFEOM3

If abduction deficit or bilateral horizontal gaze palsy with full vertical motility, consider diagnosis of Moebius syndrome or ABDS/BSAS

Ophthalmoplegia and ptosis may be seen with CFEOM3, CMS9, and multimini-core myopathy

CT to assess for temporal bone abnormalities and/or hypoplastic semicircular canals in the case of CHARGE syndrome and ABDS/BSAS

Echocardiogram

Hormone testing

Smell testing

PT, OT, and ST as indicated

X-rays

Craniofacial exam by a craniofacial surgeon

Dental exam

with facial asymmetry, microtia, preauricular tags or pits, micrognathia, aural atresia, or conductive hearing loss is suggestive of oculo-auriculo-vertebral spectrum disorder. Isolated congenital lower lip palsy is consistent with a diagnosis of asymmetric crying facies. If history of malignant hyperthermia is present, a diagnosis of Native American Myopathy or other congenital myopathies like *RYR1* should be considered.

MRI of cranial nerves may reveal absence or hypoplasia of the facial nerve. Axial and sagittal oblique T2-SPACE MRI series is recommended for evaluation of the facial nerve. MRI of facial muscles may reveal absence or hypoplasia. Muscle ultrasound and MRI may help differentiate amongst the congenital myopathies based on the distribution of affected muscle groups. Additionally, electromyogram may aid in the diagnosis of myasthenia or a congenital myopathy as well as help identify an appropriate site for muscle biopsy. Nerve conduction studies may also be used to help narrow the differential. Creatine kinase levels may be elevated in cases of myopathy.

Genetic testing

Molecular genetic testing approaches may include a combination of gene-targeted testing (multi-gene panel or single-gene testing) and genomic testing (comprehensive genomic sequencing or chromosomal microarray analysis [CMA]). Gene-targeted testing requires the clinician to narrow in on a particular diagnosis and hypothesize which gene(s) are likely involved. Chromosomal microarray (CMA) may be considered in patients with distinguishing, multiple phenotypic features suggestive of a contiguous gene deletion syndrome. Whole exome sequencing (WES) and whole-genome sequencing (WGS) may be considered if the phenotype alone is insufficient to support gene-targeted testing. In some instances where the genetic etiology for a particular diagnosis is currently unknown, genetic testing may not be indicated at this time.

Conclusions

The differential diagnosis for congenital facial weakness conditions is quite broad and extensive. The clinician must be knowledgeable regarding the many neurogenic, neuromuscular junction, and myopathic causes of congenital facial weakness as well as other unknown or mixed causes to make an accurate diagnosis. Medical history, physical examination, and additional testing as indicated are necessary to narrow in on the correct diagnosis. Depending on the cause of the congenital facial weakness, confirmatory genetic testing may be available.

Abbreviations

ABDS: Athabascan brain stem dysgenesis; ACF: Asymmetric crying facies; BSAS: Bosley-Salih-Alorainy syndrome; CFEM: Congenital fibrosis of the extraocular muscles; CFP: Congenital facial paralysis; CFW: Congenital facial weakness; CFZS: Carey-Fineman-Ziter syndrome; CMS: Congenital myasthenic syndrome; CN7: Cranial nerve 7; DM1: Myotonic dystrophy, type 1; FSHD: Facioscapulohumeral muscular dystrophy; HCFP: Hereditary congenital facial paresis; MWKS: Marden-Walker syndrome; NAM: Native American myopathy; SBBYSS: Say-Barber-Biesecker-Young-Simpson syndrome; CNMX: X-linked centronuclear myopathy; ZARD: *ZC4H2*-Associated rare disorders.

Supplementary Information

The online version contains supplementary material available at <https://doi.org/10.1186/s13023-021-01736-1>.

Additional file 1. Clinical Features of CFW Disorders.

Acknowledgements

The authors acknowledge the Moebius Syndrome Research Consortium for their assistance, and the authors thank the Moebius Syndrome Foundation for their support. B.D.W. is a clinical geneticist, clinical molecular geneticist, and pediatrician specializing in genetic studies of rare, congenital anomalies. She is Co-Director of the Cleft and Craniofacial Program at the Icahn School of Medicine at Mount Sinai. I.M. is a clinical and biochemical geneticist and pediatrician with a focus on clinical and translational research in rare genetic syndromes and inborn errors of metabolism. She works at the National Human Genome Research Institute of the National Institutes of Health. E.C.E. is a child neurologist and neurogeneticist at Boston Children's Hospital and Harvard Medical School, whose research focuses on the phenotypic, genetic, and molecular definition of disorders altering cranial nerve and muscle development. E.W.J. is a medical geneticist at the Icahn School of Medicine at Mount Sinai with a clinical focus in dysmorphology and a clinical, translational, and basic research interest in developmental genetics, in particular craniofacial disorders.

Authors' contributions

B.D.W. wrote the manuscript. I.M., E.C.E. and E.W.J. edited the manuscript. All authors read and approved the final manuscript.

Funding

This work was supported by NIH grant U01HD079068.

Availability of data and materials

Not applicable.

Declarations

Ethics approval and consent to participate

Not applicable.

Consent for publication

Consent to publish the photograph of the patient in Fig. 2 was obtained.

Competing interests

None.

Author details

¹ Department of Genetics and Genomic Sciences, Icahn School of Medicine at Mount Sinai, New York, NY, USA. ² Department of Pediatrics, Icahn School of Medicine at Mount Sinai, New York, NY, USA. ³ Medical Genomics and Metabolic Genetics Branch, National Human Genome Research Institute, National Institutes of Health, Bethesda, MD, USA. ⁴ Department of Neurology, Boston Children's Hospital, Harvard Medical School, Boston, MA, USA. ⁵ Department of Ophthalmology, Boston Children's Hospital, Harvard Medical School, Boston, MA, USA. ⁶ Howard Hughes Medical Institute, Chevy Chase, MD, USA.

Received: 6 August 2020 Accepted: 10 February 2021
Published online: 07 April 2021

References

- Husseman J, Mehta RP. Management of synkinesis. *Facial Plast Surg*. 2008;24:242–9.
- Tischfield MA, Bosley TM, Salih MA, Alorainy IA, Sener EC, Nester MJ, Oystreck DT, Chan WM, Andrews C, Erickson RP, Engle EC. Homozygous HOXA1 mutations disrupt human brainstem, inner ear, cardiovascular and cognitive development. *Nat Genet*. 2005;37:1035–7.
- Bosley TM, Alorainy IA, Salih MA, Aldhalaan HM, Abu-Amero KK, Oystreck DT, Tischfield MA, Engle EC, Erickson RP. The clinical spectrum of homozygous HOXA1 mutations. *Am J Med Genet A*. 2008;146A:1235–40.
- Holve S, Friedman B, Hoyme HE, Tarby TJ, Johnstone SJ, Erickson RP, Clericuzio CL, Cuniff C. Athabascan brainstem dysgenesis syndrome. *Am J Med Genet A*. 2003;120A:169–73.
- Rankin JK, Andrews C, Chan WM, Engle EC. HOXA1 mutations are not a common cause of Mobius syndrome. *J AAPOS*. 2010;14:78–80.
- Tischfield MA, Baris HN, Wu C, Rudolph G, Van Maldergem L, He W, Chan WM, Andrews C, Demer JL, Robertson RL, Mackey DA, Ruddle JB, Bird TD, Gottlob I, Pieh C, Traboulsi EI, Pomeroy SL, Hunter DG, Soul JS, Newlin A, Sabol LJ, Doherty EJ, de Uzcategui CE, de Uzcategui N, Collins ML, Sener EC, Wabbers B, Hellebrand H, Meitinger T, de Berardinis T, Magli A, Schiavi C, Pastore-Trossello M, Koc F, Wong AM, Levin AV, Geraghty MT, Descartes M, Flaherty M, Jamieson RV, Moller HU, Meuthen I, Callen DF, Kerwin J, Lindsay S, Meindl A, Gupta ML Jr, Pellman D, Engle EC. Human TUBB3 mutations perturb microtubule dynamics, kinesin interactions, and axon guidance. *Cell*. 2010;140:74–87.
- Chew S, Balasubramanian R, Chan WM, Kang PB, Andrews C, Webb BD, MacKinnon SE, Oystreck DT, Rankin J, Crawford TO, Geraghty M, Pomeroy SL, Crowley WF Jr, Jabs EW, Hunter DG, Grant PE, Engle EC. A novel syndrome caused by the E410K amino acid substitution in the neuronal beta-tubulin isotype 3. *Brain*. 2013;136:522–35.
- Zentner GE, Layman WS, Martin DM, Scacheri PC. Molecular and phenotypic aspects of CHD7 mutation in CHARGE syndrome. *Am J Med Genet A*. 2010;152A:674–86.
- Webb BD, Shaaban S, Gaspar H, Cunha LF, Schubert CR, Hao K, Robson CD, Chan WM, Andrews C, MacKinnon S, Oystreck DT, Hunter DG, Iacovelli AJ, Ye X, Camminady A, Engle EC, Jabs EW. HOXB1 founder mutation in humans recapitulates the phenotype of Hoxb1^{-/-} mice. *Am J Hum Genet*. 2012;91:171–9.
- Uyguner ZO, Toksoy G, Altunoglu U, Ozgur H, Basaran S, Kayserili H. A new hereditary congenital facial palsy case supports arg5 in HOX-DNA binding domain as possible hot spot for mutations. *Eur J Med Genet*. 2015;58:358–63.
- Vogel M, Velleuer E, Schmidt-Jimenez LF, Mayatepek E, Borkhardt A, Alawi M, Kutsche K, Kortum F. Homozygous HOXB1 loss-of-function mutation in a large family with hereditary congenital facial paresis. *Am J Med Genet A*. 2016;170:1813–9.
- Sahin Y, Gungor O, Ayaz A, Gungor G, Sahin B, Yaykasli K, Ceylaner S. A novel homozygous HOXB1 mutation in a Turkish family with hereditary congenital facial paresis. *Brain Dev*. 2017;39(2):166–70.
- Vahidi Mehrjardi MY, Maroofian R, Kalantar SM, Jaafarinia M, Chilton J, Dehghani M. A novel loss-of-function mutation in HOXB1 associated with autosomal recessive hereditary congenital facial palsy in a large Iranian family. *Mol Syndromol*. 2017;8:261–5.
- Verzijl HT, van den Helm B, Veldman B, Hamel BC, Kuyt LP, Padberg GW, Kremer H. A second gene for autosomal dominant Mobius syndrome is localized to chromosome 10q, in a Dutch family. *Am J Hum Genet*. 1999;65:752–6.
- Michielse CB, Bhat M, Brady A, Jafrid H, van den Hurk JA, Raashid Y, Brunner HG, van Bokhoven H, Padberg GW. Refinement of the locus for hereditary congenital facial palsy on chromosome 3q21 in two unrelated families and screening of positional candidate genes. *Eur J Hum Genet*. 2006;14:1306–12.
- Kremer H, Kuyt LP, van den Helm B, van Reen M, Leunissen JA, Hamel BC, Jansen C, Mariman EC, Frants RR, Padberg GW. Localization of a gene for Mobius syndrome to chromosome 3q by linkage analysis in a Dutch family. *Hum Mol Genet*. 1996;5:1367–71.
- Miller G. Neurological disorders. The mystery of the missing smile. *Science*. 2007;316:826–7.
- MacKinnon S, Oystreck DT, Andrews C, Chan WM, Hunter DG, Engle EC. Diagnostic distinctions and genetic analysis of patients diagnosed with moebius syndrome. *Ophthalmology*. 2014;121:1461–8.
- Miller MT, Ventura L, Stromland K. Thalidomide and misoprostol: Ophthalmologic manifestations and associations both expected and unexpected. *Birth Defects Res A Clin Mol Teratol*. 2009;85:667–76.
- Ventura BV, Miller MT, Danda D, Carta A, Brandt CT, Ventura LO. Profile of ocular and systemic characteristics in Mobius sequence patients from Brazil and Italy. *Arq Bras Oftalmol*. 2012;75:202–6.
- Tomas-Roca L, Tsaalbi-Shtylik A, Jansen JG, Singh MK, Epstein JA, Altunoglu U, Verzijl H, Soria L, van Beusekom E, Roscioli T, Iqbal Z, Gilissen C, Hoischen A, de Brouwer APM, Erasmus C, Schubert D, Brunner H, Perez Aytes A, Marin F, Aroca P, Kayserili H, Carta A, de Wind N, Padberg GW, van Bokhoven H. De novo mutations in PLXND1 and REV3L cause Mobius syndrome. *Nat Commun*. 2015;6:7199.
- Heike CL, Luquetti DV, Hing AV. Craniofacial Microsomia Overview. In: *GeneReviews*(®). Seattle (WA);1993.
- Chevessier F, Faraut B, Ravel-Chapuis A, Richard P, Gaudon K, Bauche S, Prioleau C, Herbst R, Goillot E, loos C, Azulay JP, Attarian S, Leroy JP, Fournier E, Legay C, Schaeffer L, Koenig J, Fardeau M, Eymard B, Pouget J, Hantai D. MUSK, a new target for mutations causing congenital myasthenic syndrome. *Hum Mol Genet*. 2004;13:3229–40.
- Beeson D, Higuchi O, Palace J, Cossins J, Spearman H, Maxwell S, Newsom-Davis J, Burke G, Fawcett P, Motomura M, Muller JS, Lochmuller H, Slater C, Vincent A, Yamanashi Y. Dok-7 mutations underlie a neuromuscular junction synaptopathy. *Science*. 2006;313:1975–8.
- Ohno K, Engel AG, Shen XM, Selcen D, Brengman J, Harper CM, Tsujino A, Milone M. Rapsyn mutations in humans cause endplate acetylcholine-receptor deficiency and myasthenic syndrome. *Am J Hum Genet*. 2002;70:875–85.
- Mihaylova V, Salih MA, Mukhtar MM, Abuzeid HA, El-Sadig SM, von der Hagen M, Huebner A, Nurnberg G, Abicht A, Muller JS, Lochmuller H, Guergueltcheva V. Refinement of the clinical phenotype in musk-related congenital myasthenic syndromes. *Neurology*. 2009;73:1926–8.
- Goldhammer Y, Blatt I, Sadeh M, Goodman RM. Congenital myasthenia associated with facial malformations in Iraqi and Iranian Jews A new genetic syndrome. *Brain*. 1990;113(Pt 5):1291–306.
- Engel AG, Shen XM, Selcen D, Sine SM. Congenital myasthenic syndromes: pathogenesis, diagnosis, and treatment. *Lancet Neurol*. 2015;14:420–34.
- Carey JC, Fineman RM, Ziter FA. The Robin sequence as a consequence of malformation, dysplasia, and neuromuscular syndromes. *J Pediatr*. 1982;101:858–64.
- Carey JC. The Carey–Fineman–Ziter syndrome: follow-up of the original siblings and comments on pathogenesis. *Am J Med Genet A*. 2004;127A:294–7.
- Di Gioia SA, Connors S, Matsunami N, Cannavino J, Rose MF, Gillette NM, Artoni P, de Macena Sobreira NL, Chan WM, Webb BD, Robson CD, Cheng L, Van Ryzin C, Ramirez-Martinez A, Mohassel P, Leppert M, Scholand MB, Grunseich C, Ferreira CR, Hartman T, Hayes IM, Morgan T, Markie DM, Fagiolini M, Swift A, Chines PS, Speck-Martins CE, Collins FS, Jabs EW, Bonnemann CG, Olson EN, Moebius Syndrome Research C, Carey JC, Robertson SP, Manoli I, Engle EC. A defect in myoblast fusion underlies Carey-Fineman-Ziter syndrome. *Nat Commun* 2017;8:16077.
- Jungbluth H, Zhou H, Sewry CA, Robb S, Treves S, Bitoun M, Guicheney P, Buj-Bello A, Bonnemann C, Muntoni F. Centronuclear myopathy due to a de novo dominant mutation in the skeletal muscle ryanodine receptor (RYR1) gene. *Neuromuscul Disord*. 2007;17:338–45.
- Shaaban S, Ramos-Platt L, Gilles FH, Chan WM, Andrews C, De Girolami U, Demer J, Engle EC. RYR1 mutations as a cause of ophthalmoplegia, facial weakness, and malignant hyperthermia. *JAMA Ophthalmol*. 2013;131:1532–40.
- Beggis AH, Agrawal PB. Multimimicore Disease. In: *GeneReviews*(®). Seattle (WA);1993.
- Ferreiro A, Quijano-Roy S, Pichereau C, Moghadaszadeh B, Goemans N, Bonnemann C, Jungbluth H, Straub V, Villanova M, Leroy JP, Romero NB, Martin JJ, Muntoni F, Voit T, Estournet B, Richard P, Fardeau M, Guicheney P. Mutations of the selenoprotein N gene, which is implicated in rigid spine muscular dystrophy, cause the classical phenotype of

- multiminicore disease: reassessing the nosology of early-onset myopathies. *Am J Hum Genet*. 2002;71:739–49.
36. Nance JR, Dowling JJ, Gibbs EM, Bonnemenn CG. Congenital myopathies: an update. *Curr Neurol Neurosci Rep*. 2012;12:165–74.
 37. Zaharieva IT, Thor MG, Oates EC, van Karnebeek C, Hendson G, Blom E, Witting N, Rasmussen M, Gabbett MT, Ravenscroft G, Sframeli M, Suetterlin K, Sarkozy A, D'Argenzio L, Hartley L, Matthews E, Pitt M, Vissing J, Ballegaard M, Krarup C, Slordahl A, Halvorsen H, Ye XC, Zhang LH, Lokken N, Werlauff U, Abdelsayed M, Davis MR, Feng L, Phadke R, Sewry CA, Morgan JE, Laing NG, Vallance H, Ruben P, Hanna MG, Lewis S, Kamsteeg EJ, Mannikko R, Muntoni F. Loss-of-function mutations in SCN4A cause severe foetal hypokinesia or "classical" congenital myopathy. *Brain*. 2016;139:674–91.
 38. Preston MK, Tawil R, Wang LH. Facioscapulohumeral Muscular Dystrophy. In: *GeneReviews*(®). Seattle (WA);1993.
 39. Bird TD. Myotonic Dystrophy Type 1. In: *GeneReviews*(®). Seattle (WA);1993.
 40. Horstick EJ, Linsley JW, Dowling JJ, Hauser MA, McDonald KK, Ashley-Koch A, Saint-Amant L, Satish A, Cui WW, Zhou W, Sprague SM, Stamm DS, Powell CM, Speer MC, Franzini-Armstrong C, Hirata H, Kuwada JY. Stac3 is a component of the excitation-contraction coupling machinery and mutated in Native American myopathy. *Nat Commun*. 2013;4:1952.
 41. Grzybowski M, Schanzer A, Pepler A, Heller C, Neubauer BA, Hahn A. Novel STAC3 mutations in the first non-amerindian patient with native american myopathy. *Neuropediatrics*. 2017;48:451–5.
 42. Telegrafi A, Webb BD, Robbins SM, Speck-Martins CE, FitzPatrick D, Fleming L, Redett R, Dufke A, Houge G, van Harsseel JJT, Verloes A, Robles A, Manoli I, Engle EC, Moebius Syndrome Research C, Jabs EW, Valle D, Carey J, Hoover-Fong JE, Sobreira NLM. Identification of STAC3 variants in non-Native American families with overlapping features of Carey-Fineman-Ziter syndrome and Moebius syndrome. *Am J Med Genet A* 2017;173:2763–71.
 43. Zaharieva IT, Sarkozy A, Munot P, Manzur A, O'Grady G, Rendu J, Malfatti E, Amthor H, Servais L, Urtizberera JA, Neto OA, Zanolati E, Donkervoort S, Taylor J, Dixon J, Poke G, Foley AR, Holmes C, Williams G, Holder M, Yum S, Medne L, Quijano-Roy S, Romero NB, Faure J, Feng L, Bastaki L, Davis MR, Phadke R, Sewry CA, Bonnemenn CG, Jungbluth H, Bachmann C, Treves S, Muntoni F. STAC3 variants cause a congenital myopathy with distinctive dysmorphic features and malignant hyperthermia susceptibility. *Hum Mutat*. 2018;39:1980–94.
 44. North KN, Ryan MM. Nemaline Myopathy. In: *GeneReviews*(®). Seattle (WA);1993.
 45. Garg A, O'Rourke J, Long C, Doering J, Ravenscroft G, Bezprozvannaya S, Nelson BR, Beetz N, Li L, Chen S, Laing NG, Grange RW, Bassel-Duby R, Olson EN. KLHL40 deficiency destabilizes thin filament proteins and promotes nemaline myopathy. *J Clin Invest*. 2014;124:3529–39.
 46. Ravenscroft G, Miyatake S, Lehtokari VL, Todd EJ, Vornanen P, Yau KS, Hayashi YK, Miyake N, Tsurusaki Y, Doi H, Saito H, Osaka H, Yamashita S, Ohya T, Sakamoto Y, Koshimizu E, Imamura S, Yamashita M, Ogata K, Shiina M, Bryson-Richardson RJ, Vaz R, Ceyhan O, Brownstein CA, Swanson LC, Monnot S, Romero NB, Amthor H, Kresojic N, Sivadurai P, Kiraly-Borri C, Haliloglu G, Talim B, Orhan D, Kale G, Charles AK, Fabian VA, Davis MR, Lammens M, Sewry CA, Manzur A, Muntoni F, Clarke NF, North KN, Bertini E, Nevo Y, Willichowski E, Silberg IE, Topaloglu H, Beggs AH, Allcock RJ, Nishino I, Wallgren-Pettersson C, Matsumoto N, Laing NG. Mutations in KLHL40 are a frequent cause of severe autosomal-recessive nemaline myopathy. *Am J Hum Genet* 2013;93:6–18.
 47. Frints SGM, Hennig F, Colombo R, Jacquemont S, Terhal P, Zimmerman HH, Hunt D, Mendelsohn BA, Kordass U, Webster R, Sinnema M, Abdul-Rahman O, Suckow V, Fernandez-Jaen A, van Roozendaal K, Stevens SJC, Macville MVE, Al-Nasiry S, van Gassen K, Utzig N, Koudijs SM, McGregor L, Maas SM, Baralle D, Dixit A, Wieacker P, Lee M, Lee AS, Engle EC, Houge G, Gradek GA, Douglas AGL, Longman C, Joss S, Velasco D, Hennekam RC, Hirata H, Kalscheuer VM. Deleterious de novo variants of X-linked ZC4H2 in females cause a variable phenotype with neurogenic arthrogryposis multiplex congenita. *Hum Mutat*. 2019;40:2270–85.
 48. Hirata H, Nanda I, van Riesen A, McMichael G, Hu H, Hambrock M, Papon MA, Fischer U, Marouillat S, Ding C, Alirol S, Bienek M, Preisler-Adams S, Grimme A, Seelow D, Webster R, Haan E, MacLennan A, Stenzel W, Yap TY, Gardner A, Nguyen LS, Shaw M, Lebrun N, Haas SA, Kress W, Haaf T, Schellenberger E, Chelly J, Viot G, Shaffer LG, Rosenfeld JA, Kramer N, Falk R, El-Khechen D, Escobar LF, Hennekam R, Wieacker P, Hubner C, Ropers HH, Geetz J, Schuelke M, Laumonier F, Kalscheuer VM. ZC4H2 mutations are associated with arthrogryposis multiplex congenita and intellectual disability through impairment of central and peripheral synaptic plasticity. *Am J Hum Genet*. 2013;92:681–95.
 49. Giannotti A, Digilio MC, Marino B, Mingarelli R, Dallapiccola B. Caylor cardiofacial syndrome and del 22q11: part of the CATCH22 phenotype. *Am J Med Genet*. 1994;53:303–4.
 50. Lemire G, Campeau PM, Lee BH. KAT6B Disorders. In: *GeneReviews*(®). Seattle (WA);1993.
 51. McMillin MJ, Beck AE, Chong JX, Shively KM, Buckingham KJ, Gildersleeve HI, Aracena MI, Aylsworth AS, Bitoun P, Carey JC, Clericuzio CL, Crow YJ, Curry CJ, Devriendt K, Everman DB, Fryer A, Gibson K, Giovannucci Uzielli ML, Graham JM, Jr, Hall JG, Hecht JT, Heidenreich RA, Hurst JA, Irani S, Krapels IP, Leroy JG, Mowat D, Plant GT, Robertson SP, Schorry EK, Scott RH, Seaver LH, Sherr E, Splitt M, Stewart H, Stumpel C, Temel SG, Weaver DD, Whiteford M, Williams MS, Tabor HK, Smith JD, Shendure J, Nickerson DA, University of Washington Center for Mendelian Genomics, Bamshad MJ. Mutations in PIEZO2 cause Gordon syndrome, Marden-Walker syndrome, and distal arthrogryposis type 5. *Am J Hum Genet* 2014;94:734–44.
 52. Shieh JT, Aradhya S, Novelli A, Manning MA, Cherry AM, Brumblay J, Salpietro CD, Bernardini L, Dallapiccola B, Hoyme HE. Nablus mask-like facial syndrome is caused by a microdeletion of 8q detected by array-based comparative genomic hybridization. *Am J Med Genet A*. 2006;140:1267–73.
 53. Raas-Rothschild A, Dijkhuizen T, Sikkema-Raddatz B, Werner M, Dagan J, Abeliovich D, Lerer I. The 8q22.1 microdeletion syndrome or Nablus mask-like facial syndrome: report on two patients and review of the literature. *Eur J Med Genet* 2009;52:140–4.
 54. Jamuar SS, Duzkale H, Duzkale N, Zhang C, High FA, Kaban L, Bhattacharya S, Crandall B, Kantarci S, Stoler JM, Lin AE. Deletion of chromosome 8q22.1, a critical region for Nablus mask-like facial syndrome: four additional cases support a role of genetic modifiers in the manifestation of the phenotype. *Am J Med Genet A* 2015;167:1400–5.

Publisher's Note

Springer Nature remains neutral with regard to jurisdictional claims in published maps and institutional affiliations.