

Feasibility Study of a Novel Navigation System for Biopsy of Peripheral Lesions in the Lungs

L.G. GRUIONU^{1,2}, A. SĂFTOIU^{3,4}, T. POPA¹, C. CIOBÂRCĂ¹,
C.T. STREBA⁵, ANA-MARIA IONCICĂ⁵, G. GRUIONU^{1,6}

¹Medinsys Craiova, Romania

²Faculty of Mechanics, University of Craiova, Romania

³Research Center of Gastroenterology and Hepatology Craiova,
University of Medicine and Pharmacy of Craiova, Romania

⁴Endoscopy Department, Copenhagen University Hospital Herlev, Denmark

⁵Pulmonology Department, Emergency County Clinical Hospital Craiova, Romania

⁶Department of Surgery, Harvard Medical School and Massachusetts General Hospital, USA

ABSTRACT: A novel system for electromagnetic navigation in bronchoscopy (ENB) to improve peripheral lesion targeting and diagnostic is currently under development, and preliminary tests on a complex phantom are presented in this paper. The system named Transbite is proving to be easy to use, accurate and useful for experienced and beginner users, with precision around 5-9 mm in reaching targets in sub-segmental bronchi where a conventional video-bronchoscope cannot extent. Transbite system consists of a planning and orientation software, a navigation and biopsy forceps, an active marker that is placed on patient chest and an electromagnetic tracking system from the market connected to a computer containing the software. Transbite can be used with any bronchoscopy system, has a short set-up procedure and learning curve.

KEYWORDS: bronchoscopy, fusion imaging, computer tomography (CT), magnetic resonance (MR), electromagnetic tracking (EMT)

Introduction

Accounting for 28% of all cancer deaths and causing 1.3 million deaths worldwide every year [1], lung cancer is the most lethal cancer. In order to diagnose lung cancer, pulmonologists plan the transbronchial biopsy procedure by examining a number of Computed Tomography (CT) scan slices before the procedure. They then manipulate a video bronchoscope into segmental and sub-segmental bronchi as far as the diameter of the bronchoscope permits. Finally, they insert a biopsy forceps through the working channel of the bronchoscope and perform the biopsy. The diagnostic success rate is dependent on the size and location of the lesion. Consequently, ~43% of the procedures fail to reach peripheral targets [2]. When these failures occur, pulmonologists must repeat the procedure or switch to more invasive methods that have increased complication rates, such as CT-guided percutaneous needle biopsy or surgical biopsies. Currently, there are other technologies for guidance, including endobronchial ultrasound (EBUS) that is still difficult to use for peripheral lesions [3] or CT fluoroscopy [4] involving radiation for both doctors and patients. The feasibility of electromagnetic navigation

bronchoscopy (ENB) with a steerable instrument has been previously reported [5], [6].

A novel system TRANSBITE was developed for spatial guidance of a customized bronchoscopic forceps to reach peripheral targets within bronchial tree, further from the point where the diameter of the video bronchoscope permits. Preliminary tests using a complex phantom proved the system is easy to use and improves navigation through the bronchial tree. Further studies on phantom and large animals are planned to prove its efficacy for clinical and training usage.

Methods

TRANSBITE is an image-guided navigation system including an electromagnetic tracking system (ETS) AURORA from NDI (Northern Digital Inc., Ontario, Canada) for spatial positioning, connected to a computer that runs a specific software application, a single-use navigation forceps for biopsy, and an active marker placed on patient skin.

For a bronchoscopy procedure using TRANSBITE system, the patient first undergoes a CT scan and it is subsequently moved to the interventional room where an easy set-up is necessary. The computer is connected by S-video to a videobronchoscope for image

acquisition and by USB to the ETS system. The magnetic field generator is mounted on a flexible arm fixed on the bronchoscopy bed close to the patient, while the active marker (with positioning EM sensor) is placed on a specific location on patient skin (for example, the xiphoid bone). The navigation forceps is mounted in the bronchoscope working channel and is connected to the electromagnetic tracking system. The navigation forceps is similar to a

biopsy forceps for bronchoscopy and includes a 6DOF (degrees of freedom) electromagnetic sensor close to its tip to allow acquiring its spatial position and orientation in the AURORA magnetic field. Bronchoscopy using TRANSBITE starts by launching the specific software application on a computer, whilst patient CT data is loaded using the menu from the first screen.




Fig.1 a. GI room setup for EUS procedure using Transbite system. b. Navigation forceps for biopsy.

The Software Application

TRANSBITE software uses multiple technologies for anatomy tridimensional reconstruction, registration, manual calibration and navigation, with two main screens for user interface.

First screen (Fig.2) is for procedure planning and target identification. User loads the CT scans of the patient and the sagittal, coronal and

transverse CT planes are presented in windows 2 to 4 (Fig.2). The system automatically develops airways segmentation, semi-automated lung nodule segmentation, multiple targets selection (eight maximum), virtual bronchoscopy visualization and geodesic minimal path extraction and displays it in the first screen window (Fig.2).

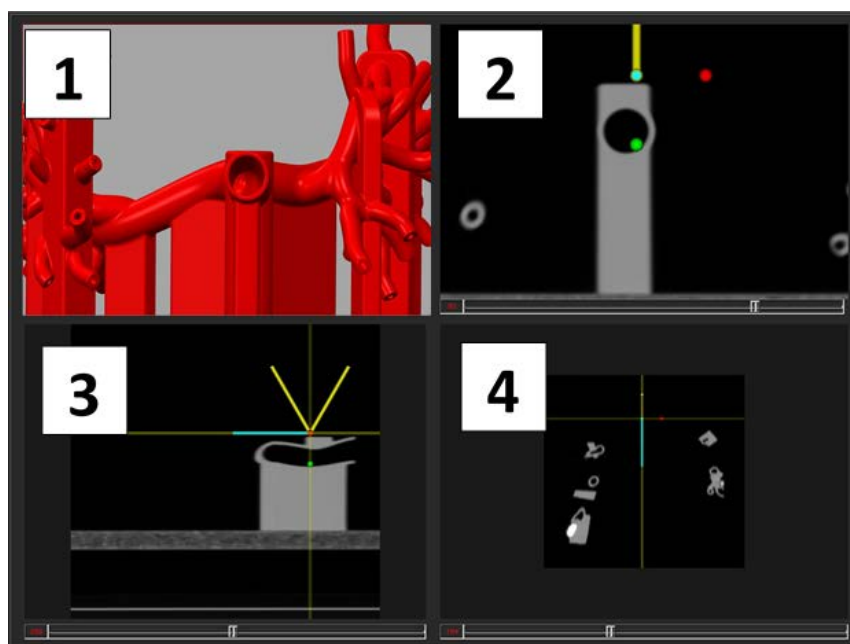


Fig.2. Planning screen of the TRANSBITE software.




Fig.3. Windows of the navigation screen of the TRANSBITE software: 1- virtual section in the CT stack, 2 - video from bronchoscope, 3 - 3D model of the patient lung and bronchoscope tip, 4 - virtual bronchoscopy.

The user will choose in any of CT windows the place of an active marker on patient skin (for example, the xiphoid bone), by navigating through CT planes. This marker will be used by the system for the initial registration. A careful placement of the marker on patient skin and precise identification of its location on CT planes will result in a better initial registration between patient space and CT volume. After choosing the active marker, the user will indicate on the virtual bronchoscopy or CT windows the entry point of the procedure, the target (a suspicious lesion, a nodule, etc.) and will select a pathway between the two by picking several points along airways to create a median line between them.

By launching the second screen (Fig.3), the system initialize the ETS system and starts to acquire spatial positioning and orientation data from active marker and navigation forceps. The second screen presents four windows: first is virtual section in the CT stack passing through the bronchoscope tip, the second presenting the video from bronchoscope, an overall 3D model of the patient lung and bronchoscope tip for navigation purposes is presented in the third window and the virtual bronchoscopy permanently updated from bronchoscope position is displayed in the fourth. The screen also includes six buttons on the right side for manual calibration of the registration using a 3D mouse.

Because the navigation forceps is placed initially inside the bronchoscope working channel, the system can compute the

instantaneous position of its tip related to the patient and CT space, and thus continuously present it in the third window, overlaid on the 3D model. The placement of the active marker on patient skin over the xiphoid bone and its location selection on CT scans depend on the user ability. Thus, additional positioning adjustments may be necessary for an accurate CT-3D model registration. Following the path to the target lesion in the bronchial tree, the user visually compare the images of the conventional videobronchoscope (**window 2**) and virtual bronchoscopy (**window 4**). The user can choose to correct the registration between the two images using a 3D mouse and the six buttons from the screen by slowly translating and rotating the virtual bronchoscopy while keeping the bronchoscope still, until the two images are similar.

When the videobronchoscope diameter is too big to be advanced in the sub-segmental bronchi, the user will be able to extend only the navigation forceps further towards the peripheral target. The navigation is performed using the virtual bronchoscopy image from fourth window and the instantaneous position of the forceps tip overlaid on the 3D model presented in the third window. The user is also able to investigate surrounding tissues using the virtual CT section in first window, and changing its orientation around bronchoscope axis. The biopsy using the forceps can be performed when the target is reached. Improved diagnosis is accomplished via enhanced navigation, targeting, as well as anatomical structure differentiation.

The Algorithm

The registration and navigation modules of the TRANSBITE system are developed using ITK, VTK and IGSTK open source libraries, in order to synchronize the information from the two imaging modalities (<http://www.igstk.org/>). Briefly, the CT, virtual bronchoscopy and videobronchoscope position are co-registered in real-time during procedure using spatial positioning data provided by the navigation forceps and the active marker from patient.

The initial registration algorithm is based on closed-form solution of absolute orientation using unit quaternions [7] and includes spatial positioning data from the three anatomical markers selected by the user plus the active marker from patient skin. A continuous registration correction is also performed during the videobronchoscopy procedure following patient movement using only the position and orientation data from the active marker. The user can also perform a fine re-alignment of the virtual bronchoscopy model and the patient by using a 3D mouse, comparing visually the images from the screen (**windows 2 and 4 from second screen**). Both the registration and manual corrections are computed using quaternions for positioning and orientation robustness and speed.

Quaternions are mathematical objects that can be used to describe in a concise manner the rotation of vectors in a 3D Euclidian space, or, equivalently, to measure the relative orientation of two reference frames. Compared to other mathematical methods used to describe the rotations and orientation (orientation matrices, or Euler angles), the quaternions present certain advantages like simple formulas and smaller errors in numerical computations.

The virtual bronchoscopy was developed based on a GPU implementation of the Marching Cubes algorithm for extracting surfaces from volumes using OpenCL and OpenGL [Smistad, 2012]. This algorithm has 6 stages:

1. Data transfer. Dataset is stored as a 3D texture on the GPU of NVidia Quadro 6000 model.
2. Base Level Construction. The base level of the Histogram Pyramids is created.
3. Histogram Pyramid Construction. The entire Histogram Pyramids structure can be constructed by a set of ND Range kernel calls in OpenCL.
4. Memory Allocation. Allocate memory on the graphics card (VBO) for all the vertices and normal needed to store the surface.
5. Histogram Pyramid Traversal. The memory is filled with the output of the Marching Cubes algorithm by running a ND Range kernel of the same size as the total sum of triangles
6. Render. The vertices and normal are stored in the VBO made in the previous step.

Results

In this preliminary phase of TRANSBITE development, a complex shape phantom of lung airways was used for tests (**Fig.4**). A 3D CAD model was designed using SolidWorks by segmentation and surface reconstruction using a previously acquired CT scan. The phantom was created on a precision Objet260 Connex 3D printer from a rigid material VeroGray RGD850. Several tumor models from ceramic powder, with diameters between 10-25mm were fixed in various locations on bronchial branches after phantom construction.

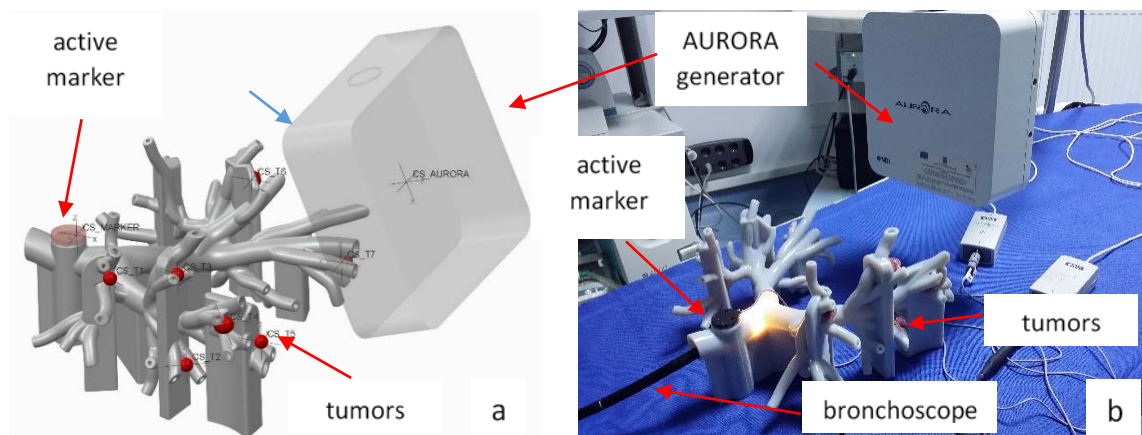


Fig.4. The CAD model (a) and the printed model (b) with bronchoscope and AURORA magnetic field generator.

The active marker used for these tests was an Aurora 6DOF Reference, 25 mm disc from NDI (part number 610066), while the exact position and orientation of the tumors on the phantom were measured using the Aurora system by touching every target with a 6DOF Probe, Straight Tip, Standard (part number 610065). A check between CAD model and phantom model was performed using the marker as a reference, whilst the tumors were located on the CAD model with a precision under 1 mm. The phantom and CAD model are used to test the navigation utility and accuracy, by steering the forceps in the proximity of tumors, for locations where bronchial diameter is too small for the bronchoscope. The feasibility tests were performed by three engineers and two experienced pulmonologists with instructions from the developer (LGG). An Olympus Bronchoscope was used in the bronchoscopy procedure room, at the Emergency Hospital from Craiova, Romania. There were seven "tumor" targets that the users had to reach at different depths inside the airway tract phantom. The absolute error (distance from the videobronchoscope tip to the target) and the procedure time were measured. The engineers reached the targets in 79.5 ± 2.7 sec with the Transbite system (8.3 ± 0.5 mm error) vs. 204.2 ± 3.7 sec with the videobronchoscope alone (28.7 ± 5.5 mm error). In comparison, the pulmonologists reached the targets in 71.3 ± 7.9 sec using Transbite (8.4 ± 1.8 mm error) and 74.3 ± 7.1 sec with the videobronchoscope alone (16.2 ± 3.3 mm error).

Discussion

We present here an innovative system designed to enhance the reach of conventional bronchoscopy techniques currently available. We used a combination of motion trackers and a computerized reconstructed 3D model to synchronize the movement of the biopsy forceps within the simulated airwaves of a shape phantom.

Pulmonologists have an array of conventional investigatory techniques for lung cancers; however, to accurately diagnose and stage the disease a tissue biopsy is imperatively needed. Obtaining tumor tissue is crucial for identifying tumor markers that can direct treatment, as targeted chemotherapy is significantly more effective than conventional oncologic treatments [8]. Moreover, an accurate early diagnosis significantly improves the

survival rates as surgical intervention is often possible [9].

Anatomy of the airways severely limits the capabilities of conventional bronchoscopy; both local morphology and associated illnesses may prevent the physician from performing a complete investigation. Bronchial lavage is usually insufficient for reaching a diagnosis, therefore endobronchial investigations need to be repeated in different circumstances [5]. Using TRANSBITE aids the bronchoscopist by providing detailed spatial guidance in real-time, its 3D render and spatial positioning of the biopsy forceps being sufficiently accurate in reaching the targeted lesion (8.4 ± 1.8 mm error versus 16.2 ± 3.3 mm error for conventional bronchoscopy).

Time constrains also apply as patient cooperation is needed, hence biopsy has to be carefully planned in advance by using CT data on location of the tumor and local conditions [10]. Bronchoscopy requires local anesthesia, so the patient is fully aware during the procedure; airflow impairment is minimum, however, it is perceived by the subject as major. Furthermore, a large percentage of patients suffers from obstructive or restrictive lung diseases that decrease the normal respiratory process, further impairing their ability to ventilate. The technique is eminently operator-dependent, a skilled physician being able to reach the targeted lesion much faster than a novice. Also, the position of the bronchoscope (i.e. the degree of rotation after performing the maneuvers needed to reach the location) when performing the biopsy affects the success rate of this procedure. The system described here improves the mean time required to perform a successful biopsy (71.3 ± 7.9 sec using Transbite versus 74.3 ± 7.1 by conventional bronchoscopy when used by trained medical professionals); the time needed to reach the site vastly improving in the case of non-trained personnel (79.5 ± 2.7 sec with the Transbite system vs. 204.2 ± 3.7 sec with only the videobronchoscope, when used by engineers).

Some factors need to be assessed for when transitioning from phantom to patient studies. Firstly, the quality of the virtual reconstruction is directly related to the acquired CT data. Anatomical detail is important, especially when the system positions the forceps in real-time; this requires CT slices to be as thin as possible, thus exposing the patient to more radiation during an extended investigation [11]. However, this inconvenient is mitigated by the fact that the patient is not required to undergo a second CT

investigation in case of failure; having the data in real-time and accurately positioning the biopsy forceps ensures the success of the investigation. The difference between diagnostic yield and reaching the lesion (success of the navigation alone) is another factor that needs to be accounted for. The main advantage of TRANSBITE is that it offers real-time positioning, as opposed to existing systems that use CT information separately, therefore the investigation not being really performed in real-time [12-14].

One of the major advantages this system might have over other virtual bronchoscopy or magnetic navigation techniques is that it combines both methods thus creating an approach which is independent of the diameter of the bronchoscope, is used for real-time assessment and intervention, is fast and should prove more accurate in reaching and intervening upon the lesions [14].

Further iterations of the device could include the use of cryobiopsy, biopsy needles for parenchymal lesions situated further from airways, as well as a combination of other investigatory techniques – endobronchial ultrasound and Doppler assessment, for accurate targeting lesions while avoiding major blood vessels and other obstacles.

Conclusions

The preliminary tests using a complex phantom proved that Transbite is easy to use and improves navigation through the bronchial tree, in both unexperienced and experienced operators. Further studies on phantom and large animals are planned to prove its efficacy for clinical and training use. In addition, we will further automatize some of the steps for magnetic navigation videobronchoscopy.

Acknowledgement

This research was supported by ANCSI-CNDI-UEFISCDI, contract number 87/2012, code PN-II-PT-PCCA-2011-3.2-0482 on the “PNII - Joint Applied Research Projects” program.

References

- Mascaux C, Peled N, Garg K, Kato Y, Wynes MW, Hirsch FR. Early detection and screening of lung cancer. *Expert Rev Mol Diagn.* 2010;10(6):799-815.
- Chee A, Stather DR, Maceachern P, Martel S, Delage A, Simon M, Dumoulin E, Tremblay A. Diagnostic utility of peripheral endobronchial ultrasound with electromagnetic navigation bronchoscopy in peripheral lung nodules. *Respirology.* 2013;18(5):784-9.
- Kurimoto N, Miyazawa T, Okimasa S, Maeda A, Oiwa H, Miyazu Y, Murayama M. Endobronchial ultrasonography using a guide sheath increases the ability to diagnose peripheral pulmonary lesions endoscopically. *Chest* 2004; 126:959–965.
- Shinagawa N, Yamazaki K, Onodera Y, Miyasaka K, Kikuchi E, Dosaka-Akita H, Nishimura M. CT-guided transbronchial biopsy using an ultrathin bronchoscope with virtual bronchoscopic navigation. *Chest* 2004; 125:1138–1143.
- Becker HD, Herth F, Ernst A, Schwarz Y. Bronchoscopic biopsy of peripheral lung lesions under electromagnetic guidance: a pilot study. *J Bronchol* 2005;12:9–13.
- Schwarz Y, Greif Y, Becker H, Ernst A, Mehta A. Real-time electromagnetic navigation bronchoscopy to peripheral lung lesions using overlaid CT images: the first human study. *Chest* 2006; 129:988–994.
- Berthold K. P. Horn, Closed-form solution of absolute orientation using unit quaternions, *JOSA A*, 1987; 4(4): 629-642.
- Saavedra D, García B, Lorenzo-Luaces P, González A, Popa X, Fuentes KP, Mazon Z, Crombet T, Neninger E, Lage A. Biomarkers related to immunosenescence: relationships with therapy and survival in lung cancer patients. *Cancer Immunol Immunother.* 2015 Nov 20. [Epub ahead of print]
- Booth CM, Nanji S, Wei X, Mackillop WJ. Outcomes of Resected Colorectal Cancer Lung Metastases in Routine Clinical Practice: A Population-Based Study. *Ann Surg Oncol.* 2015 Nov 16. [Epub ahead of print]
- Zhu P, Pan Q, Wang M, Zhong W, Zhao J. Efficacy of bronchoscopic biopsy for the detection of epidermal growth factor receptor mutations and anaplastic lymphoma kinase gene rearrangement in lung adenocarcinoma. *Thorac Cancer.* 2015;6(6):709-14
- Neumann K, Winterer J, Kimmig M, Burger D, Einert A, Allmann KH, Hauer M, Langer M: Real-time interactive virtual endoscopy of the tracheo-bronchial system: influence of CT imaging protocols and observer ability. *Eur J Radiol* 2000;33:50–54.
- Asano F1, Eberhardt R, Herth FJ. Virtual bronchoscopic navigation for peripheral pulmonary lesions. *Respiration.* 2014;88(5):430-40. doi: 10.1159/000367900. Epub 2014 Oct 1.
- Ishida T, Asano F, Yamazaki K, Shinagawa N, Oizumi S, Moriya H, Munakata M, Nishimura M: Virtual bronchoscopic navigation combined with endobronchial ultrasound to diagnose small peripheral pulmonary lesions: a randomised trial. *Thorax* 2011;66:1072–1077.
- Asano F, Shinagawa N, Ishida T, Shindoh J, Anzai M, Tsuzuku A, Oizumi S, Morita S: Virtual bronchoscopic navigation combined with ultrathin bronchoscopy. A randomized clinical trial. *Am J Respir Crit Care Med* 2013; 188:327–333.

Corresponding Author: Lucian Gruionu, University of Craiova, Faculty of Mechanics, Calea Bucuresti No. 107, Craiova 200512, Romania; e-mail: lgruionu@yahoo.com