



Clinical Approach to External Cervical Resorption in the Anterior Teeth: A Case Report Study

Andressa Bolognesi Bachesk^{a*} , Alfredo Franco Queiroz^a , Luiza Roberta Bin^b , Amanda Bolognesi Bachesk^a , Angelo Jose Pavan^a

^a State University of Maringá, Maringá, PR, Brazil; ^b Western Paraná State University, Cascavel, PR, Brazil

ARTICLE INFO

Article Type: Case Report

Received: 08 Dec 2020

Revised: 11 Feb 2021

Accepted: 23 Feb 2021

Doi: 10.22037/iej.v16i2.32373

*Corresponding author: Andressa Bolognesi Bachesk, State University of Maringá. Address: Mandacaru Avenue, 1550. CEP 87.083-240. Maringá- PR, Brazil.

E-mail: andressabachesk@gmail.com



© The Author(s). 2018 Open Access This work is licensed under the terms of the Creative Commons Attribution-NonCommercial-ShareAlike 4.0 International.

ABSTRACT

External cervical resorption (ECR) is a pathology that is difficult to diagnose early, and because it is often confused with root decay, it can be treated inadequately and even result in tooth loss. Currently, treatment does not have a defined protocol, being widely varied in the literature. This article proposes that cases of ECR should be treated individually, following different criteria, based on aspects related to the patient and the tooth involved. Furthermore, this work illustrates, through a case report, how a patient can present unique characteristics that require treatment to be case-dependent and should be discussed among a multidisciplinary team.

Keywords: Glass Ionomer Cements; Incisor; Root Resorption; Tooth Diseases; Tooth Resorption

Introduction

External cervical resorption (ECR) is a type of root resorption characterized by the gradual loss of hard dental tissue, as a result of the progressive action of hard tissue resorbing cells in the cervical third of the tooth root [1-3]. Its etiology is not totally defined, but it is believed to be more likely developed in teeth with a damaged root surface layer [4-6]. Possible etiological factors are trauma [6], orthodontic treatment, internal bleaching, periodontal treatment and idiopathic etiology [1, 3, 5, 7].

ECR is clinically characterized by the presence of an irregular cavity, usually identified through probing, located in the cervical region of the tooth root [2, 8]. It is frequently asymptomatic and pulp involvement is rare [2]. Radiographically, it is commonly seen as an irregular radiolucency at the cemento-enamel junction [1, 2, 9]. As stated by Heithersay [10], according to its severity, ECR can be classified into four categories, with higher classes

having worse prognosis. These classes are: 1. Small lesion in the cervical area with little penetration into the dentin; 2. Well-defined invasive lesion that penetrates deeply into the coronal dentin, close to the pulp, but without reaching the root dentin; 3. Deep resorptive lesion that invades the dentin and affects both the coronal dentin and the coronal third of the root; 4. Large invasive resorption that extends beyond the coronal third of the root [10].

ECR treatment varies, and although many authors defend its definition according to Heithersay's classification [10], its approach must consider etiologic factors related to the patient (medical history, emotional importance of the dental element, etc.) and the tooth (type of the affected tooth, defect extension, restorative possibility and type of material, etc.) [1, 8]. Therefore, the objective of this work is to assist the dentists in treatment planning for this type of pathology, through an unusual and well-illustrated case report.

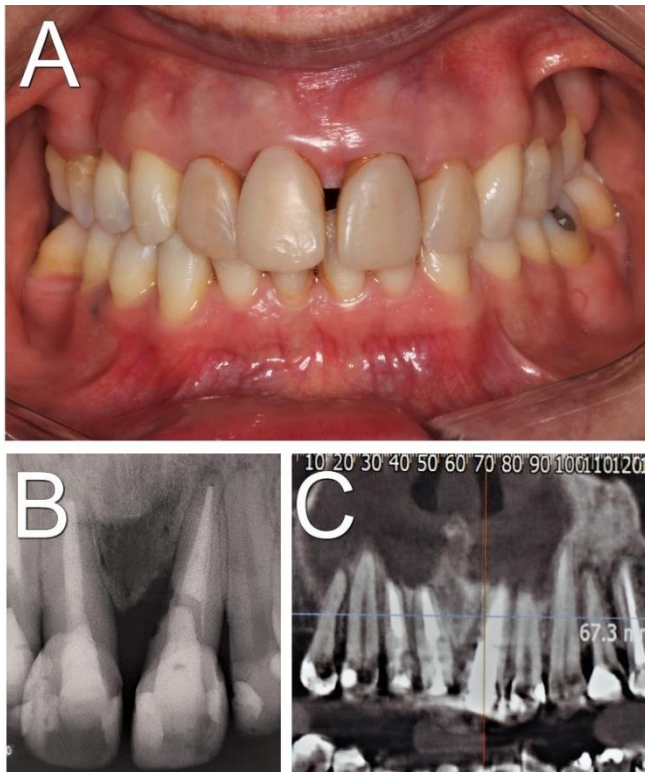


Figure 1. Initial assessment: A) Frontal intraoral photograph showing diastema between teeth 11 and 21, gingival recession in tooth 21 and good oral hygiene; B) Periapical radiography of upper incisors revealing a well-defined radiolucent lesion in the mesial of tooth 21, and vertical bone loss; C) Tomographic section of the tooth 21 revealing the extent of vertical bone loss

Case Report

A 51-year-old female patient was referred by a dentist to the oral and maxillofacial surgery team to perform dental implant surgery. During the anamnesis, the patient reported having undergone endodontic treatment for her upper incisor teeth a few years prior, due to the evolution of tooth decay. In addition, she used an orthodontic appliance for three years, having finished the treatment six months before our evaluation. She also reported having performed periodontal treatment with dental monitoring every six months. The patient informed that she did not have dental pain, was systemically healthy, and denied any history of trauma or non-vital bleaching. She was referred by her dentist for extraction of tooth 21, after diagnosing the tooth as broken and lost after analysis of the x-ray imaging. The patient conveyed discontentment with the outcome of the diagnosis.

Clinical examination showed gingival recession, satisfactory oral hygiene, diastema between teeth 11 and 21 and the absence of pain during percussion testing. There was no abscess or sinus tract (Figure 1A). During probing, there was a noticeable cervical lesion with irregular texture in the mesial of tooth 21. It was radiographically

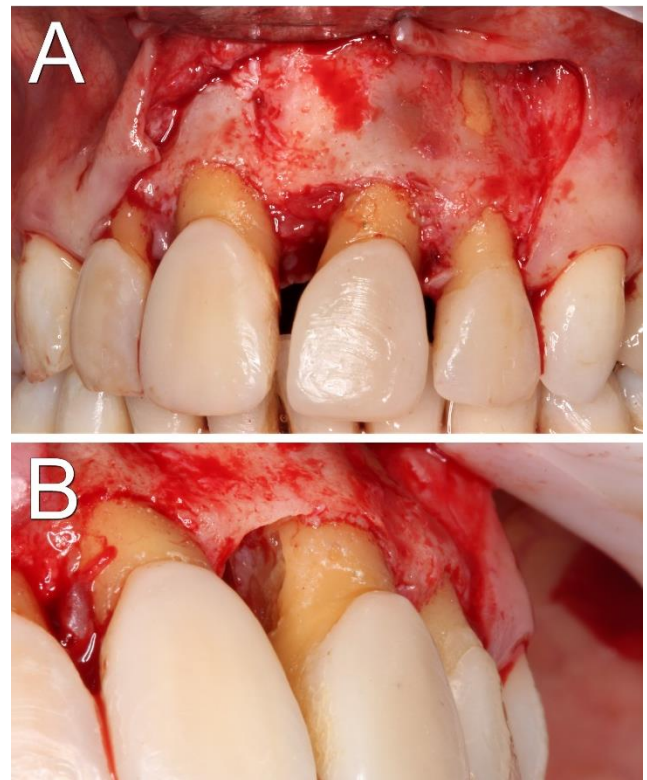


Figure 2. Trans-surgical photographs: A) Granulomatous lesion in the mesial of tooth 21 seen after incision and flap detachment; B) Exposure of external cervical resorption lesion

observed that tooth 21 had satisfactory endodontic treatment and a well-defined, irregularly shaped, radiolucent lesion in the cervical region of its mesial surface, associated with vertical bone resorption in the defect region (Figure 1B). A cone-beam computed tomography was requested, for better evaluation [6], which confirmed the aforementioned characteristics, with no signs of dental fractures (Figure 1C). By associating the clinical and imaging exams, the hypotheses of external cervical resorption and root decay were adopted. These hypotheses were explained to the patient, including possible forms of treatment and risks, whether related to conservative treatment, or related to tooth extraction and installation of an osseointegrated implant. The case was conducted in a multidisciplinary manner among endodontists, radiologists and surgeons, who, together with the patient, opted for exploratory surgery, seeking direct visualization of the lesion and dental maintenance if possible. Informed consent was obtained from the patient.

The surgical procedure started with the application of local anesthetic type 2% mepivacaine with 1:100000 epinephrine (Mepiadre, DFL, Rio de Janeiro, Brazil). Blockages of the anterior and middle upper alveolar nerve, nasopalatine nerve and infiltrative techniques around the involved area were performed. An intra-sulcular incision was made extending from

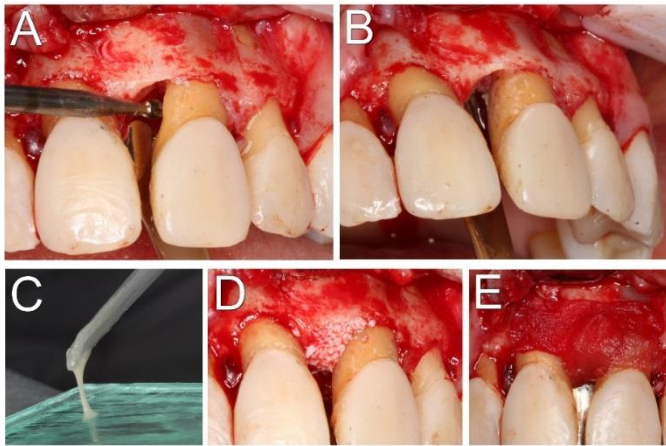


Figure 3. Treatment instituted - A) Defect regularization using a spherical drill; B) Immediate appearance after cavity restoration with resin-modified glass ionomer cement; C) Which was handling on a glass plate until it acquires adequate consistency for application; D) Insertion of the bovine bone graft to fill a previous bone defect and; E) Covering with bovine collagen membrane

tooth 12 to 22, with a distal relaxing incision. A granulomatous lesion was observed and removed in the mesial portion of tooth 21 (Figure 2A), allowing direct visualization of a crater-shaped lesion on the mesial surface of the tooth root, hard on palpation, with no signs of decayed tissue (Figure 2B). These observations were used to complete the diagnosis of external cervical resorption, possibly originated by orthodontic and/or periodontal treatment and/or idiopathic etiology. The surgery proceeded with scaling and root planning by means of Gracey curettes (Hu-Friedy, Chicago, USA), and regularization of the affected region with a spherical drill (KG Sorensen, Cotia, Brazil) No. 6 at low rotation (Figure 3A). After obtaining a regular concavity, resin-modified glass ionomer cement (Vitro Fil, DFL, Rio de Janeiro, Brazil) (Figure 3B and 3C) was opted for local restoration. Finally, in order to obtain vertical bone gain in the existing bone defect, the flaw was filled with bovine bone (Bioss, Geistlich Pharma AG, Wolhusen, Switzerland) graft and bovine collagen membrane (Lumina coat, Criteria, São Carlos, Brazil), and sutured with 6.0 nylon thread (Figure 3D and 3E).

The patient progressed satisfactorily, without pain complaints or signs of infection, maintaining strict oral hygiene care, and after ten days the sutures were removed. Clinical and radiological follow-ups continued for four months, until, after stabilization of the condition without signs of recurrence, she was referred to the restorative dentist. The patient is being monitored, and is currently in the 14 month postoperative period, with healthy looking gingival tissues and no signs of inflammation or pain complaints. Additionally, no bleeding occurred during the 3 mm probing and the restoration was clinically (Figure 4A and 4B) and radiographically adequate, being well adapted, with no signs of recurrence (Figure 4C).

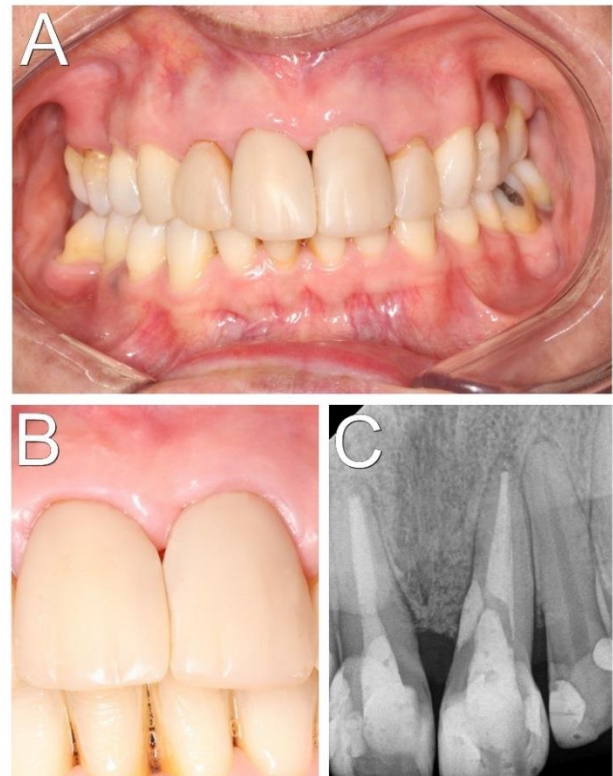


Figure 4. One year postoperative. A) Frontal intraoral photograph showing incisor teeth with permanent restorations, good gingival appearance, without signs of infection; B) Approximate photograph with an aspect of gingival health; C) Follow-up digital periapical radiography revealing adequate sealing of cervical resorption with restorative material, and bone formation

Discussion

The history of orthodontic and periodontal treatment in this case are possible causes for the development of class 2 ECR [4, 7, 9, 11]; however, it is not possible to clearly indicate whether one of these factors was the causative agent, because the patient did not present documentation to prove when this pathology started. A fact that commonly occurs, given that ECR is usually an asymptomatic alteration, and the time patients may take to seek care and obtain an early diagnosis is prolonged [1, 2, 8]. In the case of this patient, the disease was discovered by means of a routine radiographic examination, but was unduly diagnosed initially.

According to Heithersay's classification of ECR [10], authors suggest that the treatment could vary according to the progression of its classes, as follows:

A) In classification 1, the treatment can be obtained through surgical repair (which includes removal of the granulomatous and/or fibrous tissue, removal of the hard tissue from the resorption defect and sealing of the cavity) [1, 11], and in cases of non-vital teeth, they must be endodontically treated before surgical repair [1, 12].

B) In cases of classification 2 or 3, ECR can be treated with direct restoration by surgical repair [1], (although in many cases these teeth are considered poor candidates for treatment due to the extensive periodontal defect caused by surgical access) [12] or through intentional replantation (with tooth extraction, extra-oral restoration and endodontic treatment, followed by dental replantation) [13]. However, due to the lack of a well-defined treatment protocol and widely varied results, caution is recommended when considering intentional replantation, as its prognosis is uncertain, with a risk of recurrence or continued resorption [1, 5]. In addition, some authors cite the possibility of performing dental extrusion *via* orthodontic appliance to allow access to the defect; however, this form of treatment is debatable and depends on the quantity and quality of periapical and dental tissues [8, 12].

C) In case of classification 4, the tooth is non-restorable and requires extraction [1, 5].

The patient reported in this article had class 2 ECR, and therefore, one of the alternatives following this protocol would be intentional replantation, which is much more aggressive and with less predictability when compared to direct surgical repair, as was performed. This shows that the decision on the type of treatment to be performed is individual and case-dependent, and several factors must take into account, and not only its classification [1, 14]. Among these aspects, the following factors could be considered:

i) The factors related to the patient: among them, the importance of the tooth to the patient (emotional desire for tooth maintenance), the possibility and/or tolerance to the procedures (including medical history) [1, 12], and their cooperation in the treatment [15];

ii) Factors related to the tooth: position of the tooth in the dental arch (anterior esthetic or posterior region), extent of the defect and location (taking into account the classification by Heithersay, and whether there is a possibility of access and curettage of the lesion) and level of tooth integrity (if there are concomitant pathologies or factors of dental fragility) [1, 10, 13]. In the exposed case, the patient had dental restorations and endodontic treatment on tooth 21. The defect was located on the mesial surface of the tooth, a place that is generally challenging to approach, and therefore could be the target of a contraindication for attempted dental restoration and maintenance, due to its fragility and difficulty of access [1, 14]. However, the patient in question had a diastema between teeth 11 and 21, a fact that provided adequate access to the lesion, which presented moderate extension. Despite presenting endodontic treatment, satisfactory results were achieved, requiring no new approach. In addition, the patient was cooperative, which is a very

important factor in the treatment prognosis [15], as she maintained oral hygiene and local care as instructed by the professionals. Furthermore, there was the patient's desire for dental maintenance, as she is a vain, systemically healthy patient, who maintains regular monitoring by a dentist. Therefore, we observed that the case must be treated individually, and that the Heithersay classification must be seen as an important criteria to be evaluated in decision making; however, there are other factors that also influence the definitive choice of treatment [8, 14].

Regarding the material used to seal the cavity, it is known that no material meets the ideal requirements and can lead to chronic periodontal problems [8]; however, a variety of materials can be used for this purpose [2]. Mineral trioxide aggregate (MTA) has favorable chemical and physical properties, sealing ability, antibacterial activity and biocompatibility, and creates an ideal environment for the healing of hard tissues [15]. However, these beneficial properties are lost when exposed to the oral cavity, and because MTA has a propensity for teeth staining, they should be avoided in the aesthetic zone [1, 2, 8]. Materials such as silver amalgam also have favorable sealing capabilities; however, due to the risk of tooth and gingival discoloration, its use is also contraindicated in anterior regions [2, 8, 11].

The glass ionomer is a biocompatible adhesive restorative cement well tolerated by bone tissue; however, it has limitations due to its weak physical properties, susceptibility to dehydration and increased risk of plaque retention (due to its surface roughness) [2, 8]. However, with the emergence of resin-modified glass ionomer cements, this new category of biomaterials (hydrophilic monomers and photoinitiators), the physical and mechanical properties of conventional cements improved [2]. Nano-hybrid composite resins, although reducing plaque formation when well-polished (compared to conventional glass ionomer), are not compatible with periodontal tissues [2], and have less biocompatibility compared to resin-modified glass ionomer cement [8]. Thus, in our case, we opted for restoration with resin-modified glass ionomer cement, since the repair occurred in the aesthetic region, presented communication with the oral environment, and it has adequate physical-chemical properties.

It is worth mentioning that careful assessment and planning, together with informed consent about possible complications, are fundamental prerequisites for any intervention in ECR. This is because it is often difficult to classify the lesion and, frequently, additional treatments are necessary, such as the use of bone graft, gingival graft, orthodontic traction, *etc.* [8], and the possibility of tooth loss [1, 5].

Conclusion

This article aims to guide clinical dentists on how to act on external cervical resorption injuries, especially in the anterior region. We note the importance of a thorough clinical and imaging examination to obtain an early diagnosis and, consequently, a more predictable prognosis. For this, the multidisciplinary performance involving different professionals is fundamental for the aesthetic and functional success of the case.

In addition, treatment in cases of ECR should be individualized, taking into account different factors (*i.e.*, related to the patient and the tooth), before making a decision. The material of choice must also be carefully chosen. In cases occurring in the anterior esthetic region and/or in communication with the oral environment, the resin-modified glass ionomer cement presents itself as a viable and easy to handle option.

Acknowledgments

The authors are grateful to Gustavo Pereira Ribeiro for his support with the English language during the article translation. Furthermore, the authors are grateful to Dr. Margareth Calvo Pessuti Nunes for her great work regarding the aesthetic rehabilitation, with direct facet in composite resin in upper incisor teeth.

Conflict of Interest: 'None declared'.

References

1. Patel J, Beddis HP. How to assess and manage external cervical resorption. *Br Dent J.* 2019;227(8):695-701.
2. Patel S, Mavridou AM, Lambrechts P, Saberi N. External cervical resorption-part I: histopathology, distribution and presentation. *Int Endod J.* 2018;51(11):1205-23.
3. Mohammadi Z, Cehreli ZC, Shalavi S, Giardino L, Palazzi F, Asgary S. Management of Root Resorption Using Chemical Agents: A Review. *Iran Endod J.* 2016;11(1):1-7.
4. Tavares WLF, Lopes RCP, Oliveira RR, Souza RGd, Henriques LCF, Ribeiro-Sobrinho AP. Surgical management of invasive cervical resorption using resin-modified glass ionomer cement. *Gen Dent.* 2013;61(7):e16-e8.
5. Patel S, Lambrechts P, Shemesh H, Mavridou A. European Society of Endodontology Position Statement: External Cervical Resorption. *Int Endod J.* 2018;51(12):1323-6.
6. Sabbagh S, Shirazi AS, Torabzadeh H. Double Antibiotic Paste for Management of External Inflammatory Root Resorption. *Iran Endod J.* 2018;13(4):569-72.
7. Safi Y, Ghaedsharaf S, Aziz A, Hosseinpour S, Mortazavi H. Efficacy of Effect of Field Of View on Detection of External Root Resorption in Cone-Beam Computed Tomography. *Iran Endod J.* 2017;12(2):179-84.
8. Espona J, Roig E, Duran-Sindreu F, Abella F, Machado M, Roig M. Invasive Cervical Resorption: Clinical Management in the Anterior Zone. *J Endod.* 2018;44(11):1749-54.
9. Eftekhari L, Ashraf H, Jabbari S. Management of Invasive Cervical Root Resorption in a Mandibular Canine Using Biodentine as a Restorative Material: A Case Report. *Iran Endod J.* 2017;12(3):386-9.
10. Heithersay GS. Clinical, radiologic, and histopathologic features of invasive cervical resorption. *Quintessence Int.* 1999;30(1):27-37.
11. Warnsinck CJ, Shemesh H. External cervical root resorption. *Ned Tijdschr Tandheelkd.* 2018;125(2):109-15.
12. Asgary S, Nourzadeh M, Verma P, Hicks ML, Nosrat A. Vital Pulp Therapy as a Conservative Approach for Management of Invasive Cervical Root Resorption: A Case Series. *J Endod.* 2019;45(9):1161-7.
13. Krug R, Soliman S, Krastl G. Intentional Replantation with an Atraumatic Extraction System in Teeth with Extensive Cervical Resorption. *J Endod.* 2019;45(11):1390-6.
14. Shemesh A, Itzhak JB, Solomonov M. Minimally Invasive Treatment of Class 4 Invasive Cervical Resorption with Internal Approach: A Case Series. *J Endod.* 2017;43(11):1901-8.
15. Gürsoy H, Tanalp J, Yurdagüven H, Kayahan MB. Treatment of a cervical resorptive defect in a mandibular first premolar: An 18-month follow-up. *J Dent Sci.* 2014;9(4):412-6.

Please cite this paper as: Bachesk AB, Queiroz AF, Bin LB, Bachesk AB, Pavan AJ. Clinical Approach to External Cervical Resorption in the Anterior Teeth: A Case Report Study. *Iran Endod J.* 2021;16(2): 118-22. Doi: 10.22037/iej.v16i2.32373.