

fMRI for mapping language networks in neurosurgical cases

Santosh S Gupta

Department of Magnetic Resonance Imaging, P.D. Hinduja Hospital and Medical Research Centre, Veer Savarkar Marg, Mahim, Mumbai, Maharashtra, India

Correspondence: Dr. Santosh S Gupta, Consultant Radiologist, P.D. Hinduja Hospital and Medical Research Centre, Veer Savarkar Marg, Mahim, Mumbai - 400 016, Maharashtra, India. E-mail: drsantoshgupta@gmail.com

Abstract

Evaluating language has been a long-standing application in functional magnetic resonance imaging (fMRI) studies, both in research and clinical circumstances, and still provides challenges. Localization of eloquent areas is important in neurosurgical cases, so that there is least possible damage to these areas during surgery, maintaining their function postoperatively, therefore providing good quality of life to the patient. Preoperative fMRI study is a non-invasive tool to localize the eloquent areas, including language, with other traditional methods generally used being invasive and at times perilous. In this article, we describe methods and various paradigms to study the language areas, in clinical neurosurgical cases, along with illustrations of cases from our institute.

Key words: Functional magnetic resonance imaging; language; neurosurgical

Introduction

Language is one of the most basic functions of human beings, which distinguishes them from animals. Loss of language following a neurosurgery could lead to a great personal and social breakdown to a patient, and a surgeon always aims to preserve these eloquent areas. Use of anatomic landmarks alone is not adequate to localize language areas because of the complexity of these areas, shift of the functional area due to presence of the lesion, and plasticity of neurological functions. Localization of these areas preoperatively by functional magnetic resonance imaging (fMRI) not only provides guidance and a road map to the surgeon during the surgery, but also at times helps predict the outcome preoperatively.^[1-3]

Intraoperative cortical electrical stimulation (ECM)^[1] is the method often used for localizing the language areas, which has obvious disadvantages of invasiveness, complexity,

extended operation time, and failure to predict the risk of postoperative functional disorder. There are other ways to study language, such as magnetoencephalography (MEG)^[4] which is, however, not readily available. fMRI is a non-invasive, more readily available, and clinically feasible tool in clinical settings.

In this article, we discuss (1) the basic functional anatomy of language networks, which is followed by (2) paradigm planning and prerequisites to get good fMRI, (3) acquisition of fMRI data on table, (4) post-processing of the data and reporting pertaining to clinical neurosurgical cases, as well as (5) illustrations from our institute.

Functional Anatomy of Language Networks, with Paradigms Helping to Locate Them on fMRI

Brain anatomy relevant to its functions is complex, more so, when pertaining to language. In most right-handed individuals, the left cerebral hemisphere is dominant and major contributions in language are situated in inferior frontal gyrus and posterior temporal region. The inferior frontal gyrus is divided by two sulcal ramifications- anterior horizontal and anterior ascending- into three gyri, viz. pars orbitalis, pars triangularis, and pars opercularis. Broca's area is situated posteriorly in this region along the pars triangularis and opercularis [Figure 1]. Wernicke's

Access this article online

Quick Response Code:



Website:
www.ijri.org

DOI:
10.4103/0971-3026.130690

area is located in the posterior temporal region along the supramarginal/angular gyri with the exact location being in the posterior portion of superior temporal gyrus [Figure 1]. Please note that the supramarginal/angular gyri are parts of parietal lobe.

Broca's area proper can be depicted by expressive language such as word generation (WG) task, with other expressive language areas within the middle and superior frontal gyri.^[2] Patients are generally instructed to perform covert language production tasks, as words spoken aloud would induce artifactual gross head movements. Examples of WG tasks include noun-verb generation and picture naming (discussed below). Further, it has been reported that Broca's area is critically involved in syntactic, semantic, and phonological processing, with some functional imaging studies showing the pars triangularis portion of Broca's area getting activated in semantic processing, whereas the pars opercularis gets activated relatively more in phonological processing.^[5] It has been found that a lesion in Broca's area continues to be associated with speech disturbance, whereas a lesion deep to Broca's area including periventricular white matter is associated with longer-lasting nonfluent aphasia.^[6] The contribution of right Broca's homolog to language includes prosody, discourse, and processing of syntactic, which have been further discussed below.^[7] Role of Broca's and right ventral premotor cortex in promoting recovery of speech in nonfluent aphasia has been suggested since 1877 by Barlow.^[8]

Wernicke's area can be mapped by tasks requiring language comprehension,^[9] such as semantic judgment tasks. If semantic tasks are too difficult in cognitively slow patients, listening to spoken language or reading the written language may be an alternative.^[3]

It is to be noted that there is interconnection of white matter tracts between Broca's and Wernicke's areas, the major bundle being arcuate fasciculus. Diffusion tensor imaging (DTI) helps delineate these white matter tracts, which should always be a protocol to be performed along

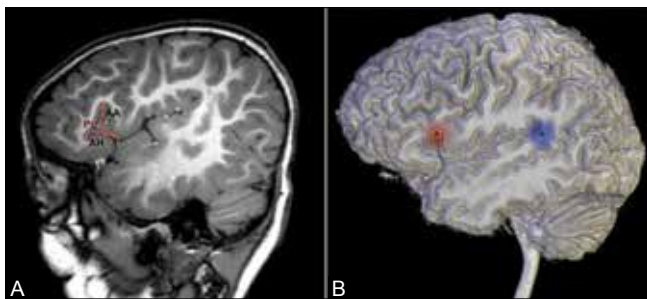


Figure 1 (A and B): Normal anatomy. (A) Sagittal T1W image shows two sulcal ramifications (shown by red lines) in the inferior frontal gyrus-anterior horizontal (AH) and anterior ascending (AA) sulci-which divide it into three gyri, viz. pars orbitalis, pars triangularis, (PT) and pars opercularis. (B) Lateral 3D view of brain shows usual location of Broca's (red circle) and Wernicke's areas (blue circle)

with the fMRI, since the loss of function can occur due to damage to the cortex or the white matter tracts, and demonstrating both is equally important.^[3]

Paradigm Designing, Prerequisites, and Acquisition of fMRI Data

The paradigm used during the fMRI enables the person to undergo a mental process, so as to activate the language networks, such as expression (in word/verb generation), or understand grammatical arrangement of words in a sentence (syntax), or the meaning of a word/phrase (semantics), or the rhythmic aspect, stress/intonation in language (prosody), depending upon the paradigm used. Therefore, patient cooperation and understanding is of utmost importance.

Patient preparation

A preliminary patient assessment, including evaluation of the intelligence level, is of prime importance. This is done by a trained neuropsychologist, in our institute, for all pediatric patients and difficult adult cases. This helps in creating or selecting paradigms and deciding the duration of paradigm, which is important in designing paradigms so as to get robust blood oxygen level dependent (BOLD) activity. Once the paradigms are decided upon, an imitation of the entire fMRI study is ideally done in a "simulation room." Care should be taken to see that simulation paradigms are different from the final paradigms in the scanner to avoid priming, which would result in reduced BOLD activity. Head motion is a big detriment to get good fMRI data, and clear instructions for the same including adequate precautions to be taken when placing the coil during the actual MRI are a basic prerequisite. Ideally, the head motion should be less than 1 voxel of movement in any direction during a run,^[10] exceeding which correction algorithms are applied, and if it fails, the data are rejected. In Dynasuite Neuro workstation (*In vivo* Corporation, Gainesville, USA), which we use in our institute for post-processing, the system gives a warning when motions are more than 3 mm or 3 degree, and will stop processing if the motions are more than 10 mm or 10 degree.

When a visual task is being used, patient's visual acuity should be checked and special MR-compatible spectacles with relevant numbers should be available to be used at the time of actual scanning. Since BOLD sensitivity is directly proportional to the magnetic field strength,^[11] all fMRI studies should be preferably on 3T or higher strength magnet with compatible hardware and software to be able to perform the fMRI study. In our institute, all such studies are performed on Philips Ingenia 3T digital scanner (Eindhoven The Netherlands), along with EPrime with ESys *In vivo* (*In vivo* Corporation, Gainesville- USA) hardware and software for fMRI [Figure 2]. Any such equipment may be used, which provides high-quality audio

and video for accurate and easy acquisition of data, as well as enhanced patient experience.

If a detailed MRI study is already done before, then in our institute, limited T2-weighted (T2W), three-dimensional T1-weighted (3D-T1W), and diffusion-weighted imaging (DWI) sequences are obtained along with the fMRI. The detailed parameters for each of these sequences are given in Table 1. This is followed by fMRI, after which diffusion-weighted (DW) sequence relevant for diffusion tensor imaging (DTI) and tractography is obtained [Table 1]. Dynamic susceptibility weighted (DSC) perfusion imaging should be performed in all suspected cases of major arterial stenosis, as alteration in perfusion can lead to altered fMRI BOLD contrast.^[12]

The fMRI sequences in most clinical situations will be of "block design." Others such as "event-related" or "mixed designs" may also be used. A 30-s rest period with visual fixation to central + sign or # sign, followed by a 30-s task is a basic standard block design. The rest period may have another task such as audio tone (discussed below). In our institute, each paradigm is of 4 min and has eight blocks of 30 s each with alternating rest and function blocks. A paradigm is a dynamic scan consisting of 80 dynamics, with dynamic scan time of 3 s. Each dynamic contains 48 slices, with the other parameters given in Table 1.

There are innumerable paradigms available in literature to evaluate language and should be judiciously used




Figure 2 (A and B): Hardware devices to generate and run the paradigms. (A) In this, (1) represents fiber media converter, (2) is ESys computer, and (3) is control computer. The other important components are shown in (B), which include (1) patient interface display, (2) fiber optic cable, (3) MR power supply, (4) power fiber cable, and (5) button response units

as discussed above to evaluate various components of language. Following are a few paradigms that we use in clinical cases.

- **Noun-verb generation:** In this, a noun is projected on the screen, such as "car," and the patient has to think its verb "drive." For a patient who may not be cooperative, a series of pictures of the same words may be projected instead of the actual words and the patient is asked to think of the verb (picture-verb generation task). This task may be done with auditory presentation instead of visual
- **Word generation:** Various alphabets are projected and the patient is asked to make as many words till the next alphabet appears
- **Comprehension task:** In this, a statement followed by a question is displayed on the video screen, followed by a YES/NO response to the question, which the patient on the MR scanner responds by pressing a hand switch/button (right-hand press for YES and left-hand press for NO). For example, the statement may be "The boy kept the book on the table" with the question below it as "Did the girl keep the book on the table?" The answer for this is obviously NO, so the patient presses left-hand button. The responses to various such tasks can be actually recorded on software, which further helps in validating the data
- **Semantic discrimination:** In this task, auditory stimuli can be used, when the patient hears single words and makes a button-press response if the item has target semantic properties (e.g. distinction between objects and animals). This can be alternated with a control tone decision task with a button press to a target sequence of tones. Another way is to ask the subject to listen to animal names and press a button if the animal is both found in one's own country and used by human beings
- **Story listening:** Passive story listening during the task phase may be used for patients, especially of pediatric age group with low IQ, followed by a period of rest.

All the above paradigms should be available in all native languages, and the decision of which language is to be used for the study is based on patient's comfort and whether it is the primary language or secondary, which will vary the outcome if not used judiciously (as discussed below). In

Table 1: Protocol and parameters

| Sequence | TR (ms) | TE (ms) | FOV (cm) | Flip angle (degrees) | Matrix size | Slice thickness/gap (mm) | TSE factor | Voxel size (mm) | EPI factor |
|---|---------|---------|-----------|----------------------|-------------|--------------------------|------------|-----------------|------------|
| T2W FSE | 3800 | 90 | 23×18 | 90 | 548×326 | 4.0/2.0 | 17 | NA | NA |
| 3DT1W | 7.6 | 3.5 | 25×25 | 8 | 228×227 | 0.6/0 | NA | 1.1×1.1×0.6 | NA |
| DWI for DTI (15 directions) B=800 or 1000 s/mm ² | 3464 | 94 | 22.4×22.4 | 90 | 92×88 | 2.5/0 | NA | NA | 45 |
| BOLD fMRI EPI sequence (80 dynamics with dynamic scan time of 3s) | 3000 | 35 | 22.4×24.8 | 90 | 76×80 | 3.0/0 | NA | 2.95×3.07×3.0 | 49 |

NA: Not applicable

our institute, we have these set in English, Hindi, Gujarati, and Marathi languages, which are common to this region. Generally, at least two different paradigms should be used, and if the patients allows, then three.

Post-processing

The most common standard software used is statistical parametric mapping (SPM), which requires extensive training and can be a time-consuming process when actually analyzing the data. There are various vendors who provide automated software, such as Brain Voyager and *In vivo* Dyna Suite Neuro. There are also software programs available as free downloads. In Dyna Suite Neuro, which we use in our institute, several automated steps are undertaken during processing of the fMRI data, such as correction for head motion, spatial normalization to a standard brain, spatial smoothing, and statistical techniques to separate relevant fMRI signal change from noise. While processing the data on the workstation, various quality checks are followed such as image/alignment co-registration, skull stripping, vessel segmentation (if contrast study has been performed), and fMRI quality check to look for motion correction (ideally less than 3 mm and 3°).

Discussion

Neurosurgery of a lesion in an eloquent area in the brain is always challenging. The language areas provide additional difficulty of preoperative evaluation for localization and lateralization due to their complexity.^[3] The preoperative methods used at present to identify the language networks in the frontal lobe and temporal lobe include the intracarotidamobarbital test (Wada test) and extra operative cortical stimulation mapping (EOCSM), which are invasive, can have potential limitations, and do not lend themselves to repeated studies.^[13]

Language evaluation on fMRI provides two kinds of basic information, one being lateralization and the second being exact localization of the language areas. In the brain, although the two hemispheres are in continual communication with each other, differences between the left hemisphere (LH) and right hemisphere (RH) are well known and documented in several studies with functional

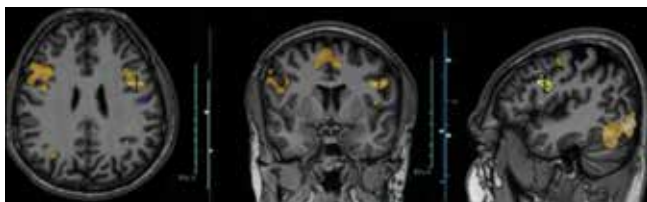

Figure 3: Language fMRI noun-to-verb task in a healthy 28-year-old subject in his native Gujarati language shows bilateral robust Broca's area activity; it is difficult to state which hemisphere is dominant. Laterality index would be needed to decide hemispheric dominance

neuroimaging.^[14] Various studies have clearly shown a LH dominance for language, of which left perisylvian regions in the frontal, temporal, and parietal lobes contribute to networks supporting many components of language processing, including word recognition, syntax, and semantics.^[15,16] On the other hand, processing prosodic information associated with speech is shown to rely more on right-hemispheric mechanisms.^[17] This hemispheric dominance in fMRI is calculated by a measurement called the laterality index (LI) and there are several methods used and issues encountered when assessing the LI.^[18] Although in most clinical scenarios, the lateralization may be most obvious looking at BOLD activity itself, at times it may be required to further use statistical data for calculating LI [Figure 3].

The LI may be computed using the following classic formula:^[19]

$$LI = f \frac{Q_{LH} - Q_{RH}}{Q_{LH} + Q_{RH}}$$

where Q_{LH} and Q_{RH} are representative quantities measured by fMRI for the LH and RH contributions, respectively. The factor f is a scaling factor that defines the range of LI values. In an older study,^[20] it was shown that 96% of right-handed subjects had fMRI changes lateralized to the LH, whereas 4% showed a bilateral activation pattern. In contrast, LH lateralization was seen in 76% of left-handers, bilateral activation in 14%, and RH lateralization in the remaining 10%.

An illustration of obvious right lateralization is seen in a case shown in Figure 4, where the patient had intractable epilepsy due to a large gliotic lesion in the left temporoparietal region and was posted for left functional hemispherectomy. Language fMRI clearly shows a right lateralization of the Broca's area, suggesting right-sided dominance, which was confirmed on Wada test. In a prospective research study by Janecek *et al.*,^[21] the degree of rightward shift of language dominance on fMRI testing showed strong correlation with Wada/fMRI discordance, which suggested that fMRI may be more sensitive than Wada to RH language processing.

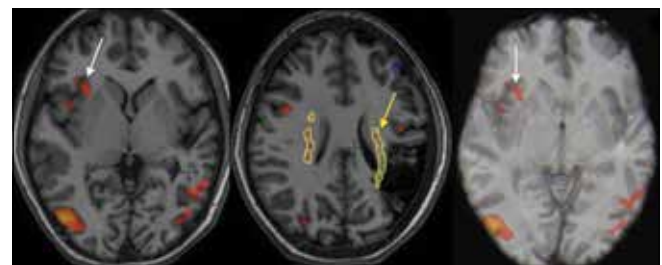


Figure 4: fMRI language task in a 19-year-old patient with intractable epilepsy and a large gliotic lesion in the left cerebral parenchyma (middle image) shows the Broca's area (white arrow) clearly lateralized to the right side; it is also depicted in the 3D image on the right. Cortico-spinal tract (yellow arrow) is seen along the medial margin of this lesion

In this study, 229 patients with epilepsy underwent both a standardized Wada test and a semantic decision fMRI language protocol.

Certain language paradigms, if designed and performed properly, can give a great amount of useful information, such as semantic decision task (details of this paradigm have been discussed above). The contrast of the semantic decision with tone decision task has an advantage as it can isolate speech perception and semantic language processes at the same time, controlling for attention, working memory, auditory, and motor processes, which is able to produce left-lateralized language activation in frontal, temporal, and parietal areas in healthy right-handed controls.^[22,23] Tasks such as these are known to activate numerous brain areas involved in language processing, such as inferior frontal and prefrontal cortex, superior and middle temporal regions, and in some, especially in adult subjects, activation has been depicted in medial temporal regions, angular and posterior cingulate.^[24]

In one study, three functional MRI paradigms were used: semantic decision/tone decision task (already discussed above), processing spoken stories, and prosody discrimination.^[23] Processing spoken stories task is a simple task based on a periodic 30-s on-off block design, wherein a different story can be read by a speaker, presented during each 30s on period (active), and contains, say for example, 10 sentences with simple and a variety of syntactic constructions, ideally designed by a speech-language pathologist, especially in case of children.^[25] Areas of activation in this group show multiple neural components and functionally connected regions, which include bilateral superior and middle temporal regions.^[23,25]

Prosody linguistic discrimination task can be designed, say for example, identifying statements versus questions when the lexical content is the same. This task relies on bilateral frontal and temporal mechanisms.^[26]

Some of the simpler language tasks that can be used to identify language-processing regions in the dominant hemisphere are verb generation,^[27] object naming, sentence comprehension, and single-word listening or reading.^[28] These fMRI studies, in general, reveal a left-lateralized language network of frontal and temporal cortices (the

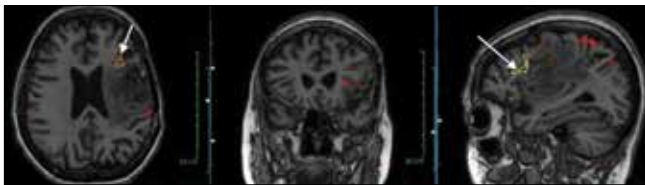


Figure 5: fMRI language task in a 54-year-old patient with a large heterogeneously enhancing mass (glioblastoma multiforme) in the left frontotemporal region shows the Broca's area (arrow) along the anterior margin of the lesion. Wernicke's area is not well depicted

traditional Broca's and Wernicke's areas). In a study, two simple paradigms, sentence generation (SG) and word generation (WG), were used.^[29] The results showed good success rates in localizing and lateralizing language. This was 96% for the Broca's and Wernicke's areas with the SG paradigm, 81% for the Broca's area and 80% for the Wernicke's area with the WG paradigm, and 98% for both areas when both the SG and WG paradigms were used together in combination. These paradigms showed consistent functional localizations in the inferior frontal gyrus (Broca's area) and the superior temporal, supramarginal, and angular gyri (Wernicke's area). Localization of Wernicke's area is more challenging, and many a times, routine paradigms such as verbal fluency/WG are inadequate to localize the temporal areas, in which case, other tasks such as comprehension or reading-based naming paradigm^[13] or comprehension tasks would be helpful.

Patient's primary and secondary languages are also taken into consideration while deciding the task, as it may slightly alter the output of fMRI data, although an overlap for different languages is known and is also dependent on the age of acquisition of the second language.^[30] This is especially true in Indian population, since most people are generally multilinguals, with knowledge of at least three different languages.

Location of the Broca's or Wernicke's area in relationship with the surgical lesion [Figures 5 and 6] can be depicted in multiple planes and also on a 3D model. Automated software allows superimposition of the BOLD activity, along with DTI, on both routine multiplanar and 3D models, all of which can be provided on a DICOM format either on a CD or transferred to neuro-navigation software in the surgical theater for direct use during the surgical procedure, where these data are extremely useful in planning and guiding surgery. Some software programs also allow superimposition of major venous channels, along with all the above data [Figure 6], which again is of great use to the neurosurgeon. The location of BOLD activity in relation with the lesion, especially when it is along the margin or within

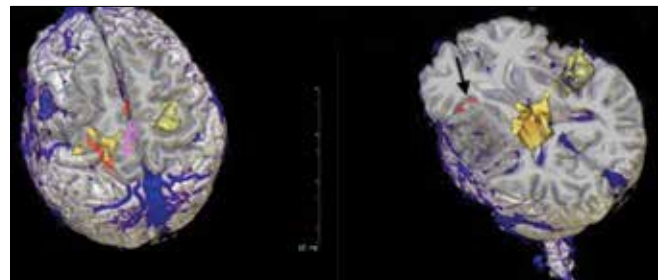


Figure 6: 3D reconstruction of the post-gadolinium study in the same patient as in Figure 4, along with superimposition of the BOLD activity-Broca's area (arrow), cortico-spinal tracts (in yellow color), and major venous sinuses (in blue). All these data can be sent in a DICOM format to a neuro-navigation workstation, which is extremely useful for planning and guidance during the surgery

the lesion, can pose dilemmas. In an earlier study by Yetkin *et al.*, it was suggested that a distance of greater than 2 cm provides safe margin with no post-operative deficit, whereas any lesion within 1 cm of the language area has 50% chance of deficit.^[31] In another more recent study, it was found that language deficits increased exponentially as the distance from the tumor to the language areas decreased below 1 cm.^[32] Resting state fMRI is a recent development which can reveal cortical connectivity among language network regions by evaluating correlations of spontaneous BOLD signal-intensity fluctuations without any imposed task.^[33]

Limitations and Pitfalls

There are various shortcomings of fMRI due to technical, physiologic reasons, lack of standardization, inadequate experience, etc., Success rates are, therefore, variable depending upon the above factors and documented to be about 80% in one such series.^[34] Apart from these, limitations especially pertaining to language fMRI are related to inadequate patient preparation, pre-procedure neuropsychological evaluation, selection of relevant paradigms, and post-processing (which include the type of software used and training for the same). Also to be noted are interpretative errors such as influence of tumors on fMRI activity and geometric distortion at air-tissue boundaries. Cortical BOLD activity can be reduced near glial tumors, both at the edge of the tumor and in normal vascular territories.^[35]

Conclusion

Thus, fMRI provides a non-invasive reproducible tool to study language areas in neurosurgical cases involving the eloquent areas. It, however, requires good training and has its limitations, the understanding of which is important. It allows assessment of the risk of therapeutic interventions, selection of patients for intraoperative mapping, and guides brain surgery itself.

Acknowledgment

I would like to wholeheartedly acknowledge the neurosurgeons and neurologists of Hinduja Hospital, Mumbai, all my colleagues and staff of our radiology department, with special thanks to Dr. Meher Ursekar (radiologist) and Dr. Urvashi Shah (neuropsychologist), without whom the work which we have been doing and this article would not have been possible.

References

- Kim KK, Privitera MD, Szaflarski JP. Lessons learned from a comparison of language localization using fMRI and electrocortical mapping: Case studies of neocortical epilepsy patients. *Epileptic Disord* 2011;13:368-74.
- Roux FE, Boulanouar K, Lotterie JA, Mejdoubi M, Lesage JP, Berry I. Language functional magnetic resonance imaging in pre-operative assessment of language areas: Correlation with direct cortical stimulation. *Neurosurgery* 2003;52:1335-45.
- Sunaert S. Presurgical Planning for Tumor Resectioning. *J Magn Reson Imaging* 2006;23:887-905.
- Maess B, Herrmann CS, Hahne A, Nakamura A, Friederici AD. Localizing the distributed language network responsible for the N400 measured by MEG during auditory sentence processing. *Brain Res* 2006;1096:163-72.
- Gough PM, Nobre AC, Devlin JT. Dissociating linguistic processes in the left inferior frontal cortex with transcranial magnetic stimulation. *J Neurosci* 2005;25:8010-6.
- Naeser MA, Palumbo CL, Helm-Estabrooks N, Stiassny-Eder D, Albert ML. Severe nonfluency in aphasia. Role of the medial subcallosal fasciculus and other white matter pathways in recovery of spontaneous speech. *Brain* 1989;112:1-38.
- Kaplan E, Naeser MA, Martin PI, Ho M, Wang Y, Baker E, Pascual-Leone A. Horizontal portion of arcuate fasciculus fibers track to pars opercularis, not pars triangularis, in right and left hemispheres: A DTI study *Neuroimage* 2010;52:436-44.
- Barlow T. A case of double hemiplegia, with cerebral symmetrical lesions. *Br Med J* 1877;28:103-4.
- Atlas SW, Howard RS 2nd, Maldjian J, Alsop D, Detre JA, Listerud J, *et al.* Functional magnetic resonance imaging of regional brain activity in patients with intracerebral gliomas: Findings and implications for clinical management. *Neurosurgery* 1996;38:329-38.
- Yerys BE, Jankowski KF, Shook D, Rosenberger LR, Barnes KA, Berl MM, *et al.* The fMRI success rate of children and adolescents: Typical development, epilepsy, attention deficit/hyperactivity disorder, and autism spectrum disorders. *Hum Brain Mapp* 2009;30:3426-35.
- Kruger G, Kastrup A, Glover GH. Neuroimaging at 1.5 T and 3.0 T: Comparison of oxygenation-sensitive magnetic resonance imaging. *Magn Reson Med* 2001;45:595-604.
- Schaaf M, Mommertz G, Ludolph A, Geibprasert S, Muhlenbruch G, Das M, Krings T. Functional MR Imaging in Patients with Carotid Artery Stenosis before and after Revascularization. *AJNR Am J Neuroradiol* 2010;31:1791-8.
- Cascino G. Functional MRI for language localization. *Epilepsy Curr* 2002;2:178-9.
- Hutsler J, Galuske RA. Hemispheric asymmetries in cerebral cortical networks. *Trends Neurosci* 2003;26:429-35.
- Martin RC. Language processing: Functional organization and neuroanatomical basis. *Annu Rev Psychol* 2003;54:55-89.
- Friederici AD, Ruschemeyer SA, Hahne A, Fiebach CJ. The role of left inferior frontal and superior temporal cortex in sentence comprehension: Localizing syntactic and semantic processes. *Cereb Cortex* 2003;13:170-7.
- Meyer M, Alter K, Friederici AD, Lohmann G, von Cramon DY. fMRI reveals brain regions mediating slow prosodic modulations in spoken sentences. *Hum Brain Mapp* 2002;17:73-88.
- Seghier LM. Laterality index in functional MRI: Methodological issues. *Magn Reson Imaging* 2008;26:594-601.
- Binder JR, Swanson SJ, Hammeke TA, Morris GL, Mueller WM, Fischer M. Determination of language dominance using functional MRI: A comparison with the Wada test. *Neurology* 1996;46:978-84.
- Pujol J, Deus J, Losilla MJ, Capdevila A. Cerebral lateralization of language in normal left-handed people studied by functional MRI. *Neurology* 1999;52:1038-43.
- Janecek JK, Swanson SJ, Sabsevitz DS, Hammeke TA, Raghavan M, E Rozman M, *et al.* Language lateralization by fMRI and Wada testing in 229 patients with epilepsy: Rates and predictors of discordance. *Epilepsia* 2013;54:314-22.
- Binder JR, Frost JA, Hammeke TA, Cox RW, Rao SM, Prieto T. Human brain language areas identified by functional magnetic resonance imaging. *J Neuroscience* 1997;17:353-62.

23. Vannest J, Karunanayaka PR, Schmithorst VJ, Szaflarski JP, Holland SK. Language networks in children: Evidence from functional MRI studies. *AJR Am J Roentgenol* 2009;192:1190-6.
24. Szaflarski JP, Holland SK, Jacola LM, Lindsell C, Privitera MD, Szaflarski M. Comprehensive presurgical functional MRI language evaluation in adult patients with epilepsy. *Epilepsy Behav* 2008;12:74-83.
25. Schmithorst VJ, Holland SK, Plante E. Cognitive modules utilized for narrative comprehension in children: A functional magnetic resonance imaging study. *Neuroimage* 2006;29:254-66.
26. Baum SR, Dwivedi VD. Sensitivity to prosodic structure in left and right-hemisphere-damaged individuals. *Brain Lang* 2003;87:278-89.
27. Holland SK, Plante E, Weber Byars A, Strawsburg RH, Schmithorst VJ, Ball WS Jr. Normal fMRI brain activation patterns in children performing a verb generation task. *Neuroimage* 2001;14:837-43.
28. Szaflarski JP, Binder JR, Possing ET, McKiernan KA, Ward BD, Hammeke TA. Language lateralization in left-handed and ambidextrous people: fMRI data. *Neurology* 2002;59:238-44.
29. Stippich C, Rapps N, Dreyhaupt J, Durst A, Kress B, Nennig E, *et al.* Localizing and Lateralizing Language in Patients with Brain Tumors: Feasibility of Routine Preoperative Functional MR Imaging in 81 Consecutive Patients. *Radiology* 2007;243:828-36.
30. Nidhi M, Elena P, Joel M, Lisa M, Theodore TP. fMRI variability and the localization of languages in the bilingual brain. *Neuro Report* 2003;14:1225-8.
31. Yetkin FZ, Ulmer JL, Mueller W, Cox RW, Klosek MM, Houghton VM. Functional magnetic resonance imaging assessment of the risk of postoperative hemiparesis after excision of cerebral tumors. *Int J Neuroradiol* 1998;4:253-7.
32. Wood JM, Kundu B, Utter A, Gallagher TA, Voss J, Nair VA, *et al.* Impact of brain tumor location on morbidity and mortality: A retrospective functional MR imaging study. *AJNR Am J Neuroradiol* 2011;32:1420-5.
33. Lee MH, Smyser CD, Shimony JS. Resting-State fMRI: A Review of Methods and Clinical Applications. *AJNR* 2013;34:1866-72.
34. Haberg A, Kvistad KA, Unsgard G, Haraldseth O. Preoperative blood oxygen level-dependent functional magnetic resonance imaging in patients with primary brain tumors: Clinical application and outcome. *Neurosurgery* 2004;54:902-14.
35. Schreiber A, Hubbe U, Ziyeh S, Hennig J. The influence of gliomas and non-glial space-occupying lesions on blood-oxygen-level-dependent contrast enhancement. *AJNR Am J Neuroradiol* 2000;21:1055-63.

Cite this article as: Gupta SS. fMRI for mapping language networks in neurosurgical cases. *Indian J Radiol Imaging* 2014;24:37-43.

Source of Support: Nil, **Conflict of Interest:** None declared.