

Case Studies

Sign of Leser-Trélat and Cutaneous T-Cell Lymphoma: A Rare Association

Raphaël André Emmanuel Laffitte Marem Abosaleh Bégonia Cortès
Laurence Toutous-Trellu Gürkan Kaya

Department of Dermatology, University Hospital of Geneva, Geneva, Switzerland

Keywords

Sign of Leser-Trélat · Seborrheic keratosis · T-cell lymphoma

Abstract

Sign of Leser-Trélat is a rare paraneoplastic cutaneous manifestation, characterized by the sudden appearance and rapid increase in size and number of seborrheic keratoses, accompanied by pruritus. Edmund Leser and Ulysse Trélat described this sign in 1890. Since their first description, their conclusions have been considered controversial and some authors assert the absence of a causal link. It seems to be frequently associated with solid tumors and in particular gastrointestinal cancer. Here, we describe a new case associated with a cutaneous T-cell lymphoma and a partial response to extracorporeal photopheresis.

© 2018 The Author(s)

Published by S. Karger AG, Basel

Case Report

A 73-year-old man with a 20-year history of psoriasis and a 7-year history of a generalized erythroderma came in for an examination in the dermatology clinic at the University Hospital of Geneva in 2017. Several biopsies had been performed on the patient and he received different treatments for the psoriasis including anti-TNF α and anti-IL17A. Physical examinations revealed a generalized erythroderma, with squamous lesions on the palms and soles including several fissures. There were seborrheic keratoses on his shoulders, back,

Raphaël André, MD
Hôpitaux Universitaires de Genève
4 rue Gabrielle-Perret-Gentil
CH-1205 Geneva (Switzerland)
E-Mail raphael.andre@hcuge.ch

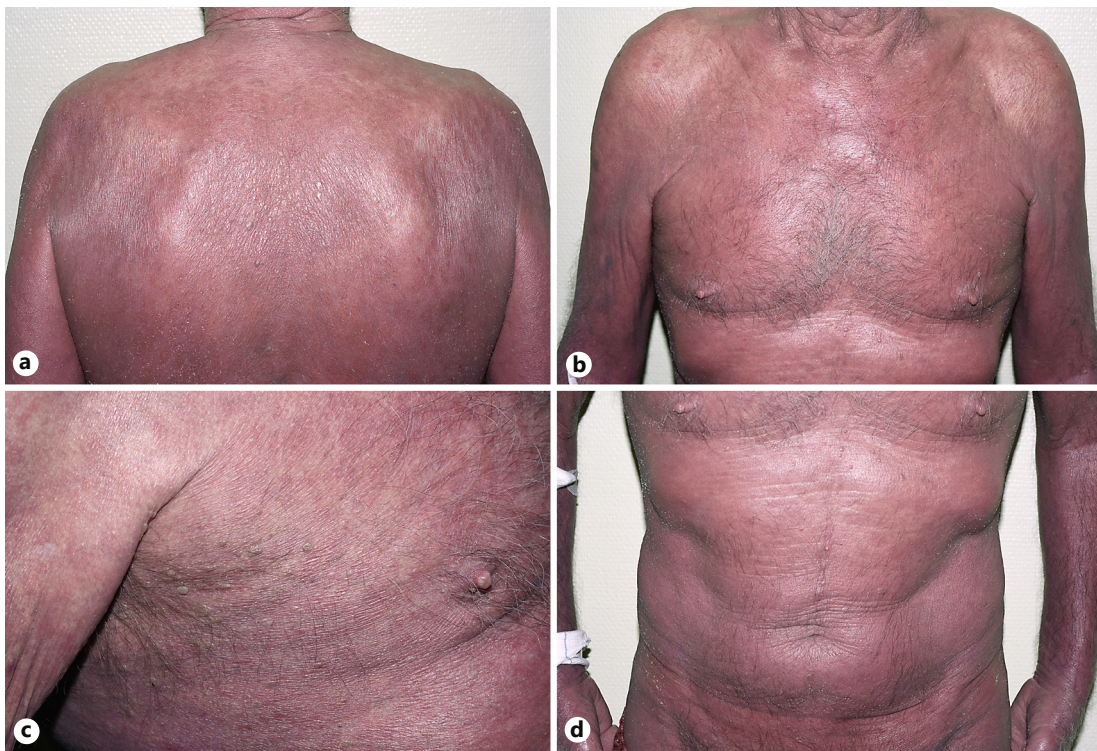


Fig. 1. Erythroderma with multiple seborrheic keratoses on the back (a), the chest (b), the right axillary region (c), and the abdomen (d).

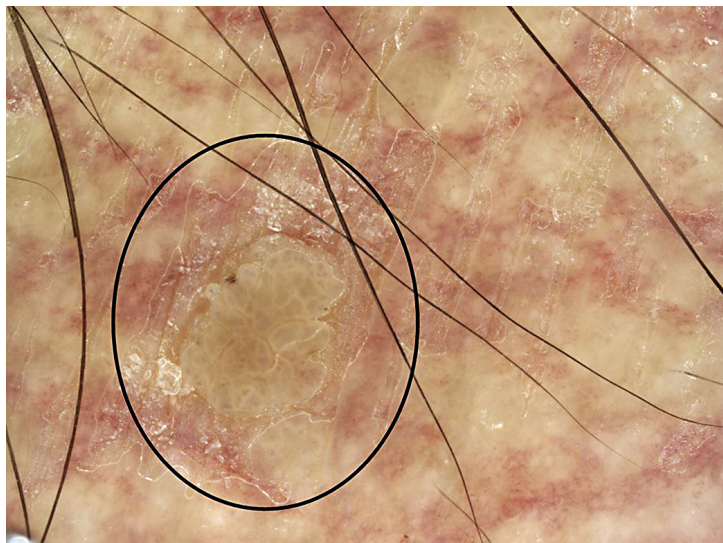


Fig. 2. Seborrheic keratosis on the dermoscopy: *cerebriform aspect*.

chest, and thighs. Inguinal lymphadenopathy was present. CT scan showed multiple lymph node enlargements. A few Sézary cells were detected in the peripheral blood. A new skin biopsy performed on a lesion located on the back showed a dense dermal atypical lymphocytic infiltrate with epidermotropism, which was consistent with mycosis fungoides (MF). He was treated in our department with topical steroids and extracorporeal photopheresis. After 2 cycles, the patient described new multiple axillary pruritic papillary papules (Fig. 1). Differ-

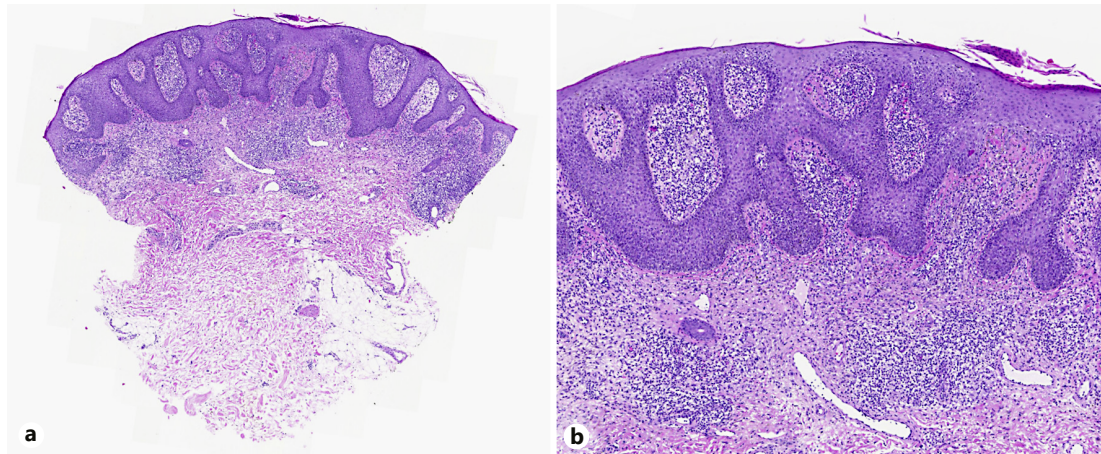


Fig. 3. Epidermal hyperplasia with a slight hyperkeratosis associated with an important dermal lymphocytic infiltrate. Hematoxylin and eosin. Original magnification $\times 3$ (a) and $\times 5$ (b).

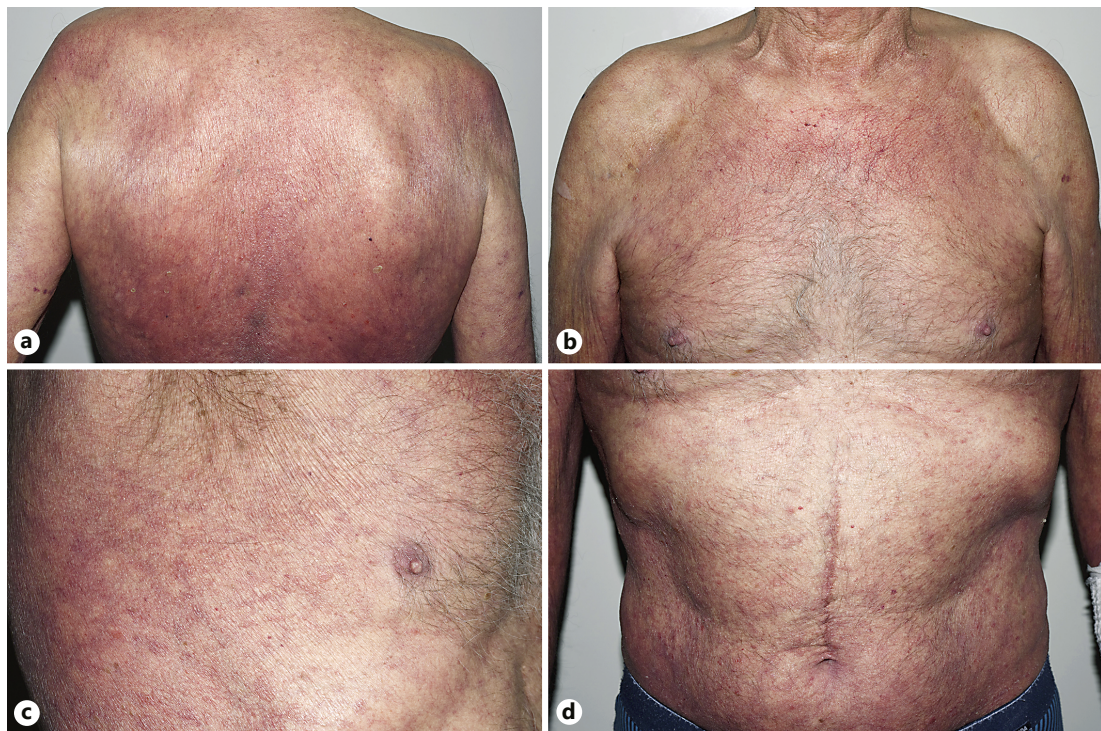


Fig. 4. After 6 months of extracorporeal photopheresis, we observed improvement of the erythroderma and the number of seborrheic keratoses on the back (a), the chest (b), the right axillary lesion (c), and the abdomen (d).

ential diagnosis was seborrheic keratoses, warts, and molluscum fibrosum. We confirmed the rapid development of seborrheic keratoses by performing a dermoscopy (Fig. 2) and a biopsy (Fig. 3). The diagnosis of MF with the sign of Leser-Trélat was made. Finally, after 6 months of extracorporeal photopheresis, we observed an improvement of the erythroderma and the number of seborrheic keratoses (Fig. 4).

Discussion

Sign of Leser-Trélat is a rare paraneoplastic cutaneous manifestation, characterized by the sudden appearance and rapid increase in size and number of seborrheic keratoses, accompanied by pruritus [1]. Edmund Leser and Ulysse Trélat described this sign in 1890. Since their first description, their conclusions have been considered controversial and some authors assert the absence of a causal link [2]. It seems to be frequently associated with solid tumors and in particular gastrointestinal cancer [1, 3, 4]. In our case, unfortunately the patient refused the intestinal endoscopy but the CT scan was normal.

A few cases of cutaneous T-cell lymphoma associated with eruptive seborrheic keratoses have been reported [1, 5–8]. Systemic lymphoma and leukemia were also associated with this manifestation in a recent review of the literature [9]. In addition to a simple association between seborrheic keratoses and MF, we observed in our case a modification during the beginning of photopheresis and then during subsequent cycles. This observation may suggest a link between these two entities and could imply that treatment could have a direct or indirect impact on seborrheic keratoses. One case of Sézary syndrome associated with this manifestation was reported with concomitant improvement after photopheresis [10].

The pathophysiology of the sign of Leser-Trélat remains unknown, and we did not observe a significant modification using dermoscopy and histopathology. In our case, we observed a steroid skin atrophy, an aging skin, previous seborrheic keratoses, a chronic skin inflammation, and a skin lymphoma. The dermoscopy showed several *fissures* showing a typical *cerebriform aspect*. Histopathological analysis of the lesion revealed a typical aspect of seborrheic keratosis associated with a dermal infiltrate corresponding to MF. Furthermore, we did not find any human papillomavirus virus (HPV) in the lesion after performing a polymerase chain reaction (PCR) research. Previous studies suggest that HPV could be a causative agent of seborrheic keratosis, more often in the genital location. However, this hypothesis remains controversial. Some authors suggest that genital seborrheic keratoses are similar to condylomata acuminata [11]. In a Korean review of 40 cases of nongenital seborrheic keratoses, among the types 6/11, 31 and 33, none showed any HPV [12]. After a research in Medline via PubMed, we did not find any study about HPV and the sign of Leser-Trélat. Finally, our observation does not corroborate a viral mechanism to explain the sign even in an immunosuppressed patient.

In conclusion, even if the sign of Leser-Trélat remains controversial, this case seems to show a strong correlation between his lymphoma and sudden eruptive pruritic seborrheic keratoses. Neither dermoscopy nor histopathology allow to distinguish a simple seborrheic keratosis and a neoplasia-associated seborrheic keratosis. A careful regular skin examination is required for such fragile patients.

Statement of Ethics

The manuscript was prepared in compliance with all ethical and confidentiality guidelines and principles.

Disclosure Statement

The authors declare no conflict of interest.

References

- 1 Dantzig PI: Sign of Leser-Trélat. *Arch Dermatol* 1973;108:700–701.
- 2 Fink AM, Filz D, Krajnik G, Jurecka W, Ludwig H, Steiner A: Seborrhoeic keratoses in patients with internal malignancies: a case-control study with prospective accrual of patients. *J Eur Acad Dermatol Venereol* 2009;23:1316–1319.
- 3 Chakradeo K, Narsinghpura K, Ekladios A: Sign of Leser-Trélat. *BMJ Case Rep* 2016, DOI: 10.1136/bcr-2016-215316.
- 4 Abakka S, Elhalouat H, Khoummane N, Achaaban M, ElAmrani S, Bargach S, Yousfi M: Uterine leiomyosarcoma and Leser-Trélat sign. *Lancet* 2013;381:88.
- 5 Lebas E, Quatresooz P, Arrese JE, Nikkels AF: Eruptive seborrhoeic keratoses restricted to plaque/patch-stage mycosis fungoides. *Case Rep Dermatol* 2017;9:35–39.
- 6 McCrary ML, Davis LS: Sign of Leser-Trélat and mycosis fungoides. *J Am Acad Dermatol* 1998;38:644.
- 7 Miyako F, Dekio S, Tamura H, Yamada Y, Miyata N, Jidoi J, Tohgi K: Mycosis fungoides with Leser-Trélat sign: the first report of a patient from Japan. *J Dermatol* 1994;21:189–193.
- 8 Toonstra J, Ramselaar CG, van der Putte SC: Leser-Trélat sign in mycosis fungoides. A further case report. *Dermatologica* 1985;171:247–249.
- 9 Narala S, Cohen PR: Cutaneous T-cell lymphoma-associated Leser-Trélat sign: report and world literature review. *Dermatol Online J* 2017;23.
- 10 Bursztejn AC, Doumat-Batch F, Granel-Brocard F, Perrin A, Cuny JF, Barbaud A, Schmutz JL: Sézary syndrome and Leser-Trélat sign: a chance association?. *Ann Dermatol Venereol* 2008;135:287–290.
- 11 Li J, Ackerman AB: “Seborrhoeic keratoses” that contain human papillomavirus are condylomata acuminata. *Am J Dermatopathol* 1994;16:398–405; discussion 406–398.
- 12 Lee ES, Whang MR, Kang WH: Absence of human papillomavirus DNA in nongenital seborrhoeic keratosis. *J Korean Med Sci* 2001;16:619–622.