

# Iatrogenic subcutaneous emphysema and pneumomediastinum due to dental extraction procedure

**Serdar Ozdemir, Serkan Emre Eroglu**

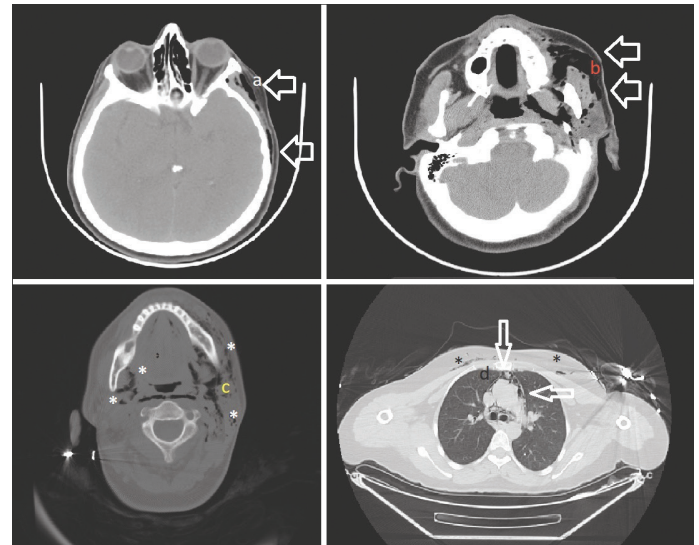
Department of Emergency Medicine, University of Health Sciences, Umraniye Training and Research Hospital, Istanbul, Turkey

**Cite this article as:** Ozdemir S, Eroglu SE. Iatrogenic subcutaneous emphysema and pneumomediastinum due to dental extraction procedure. *North Clin Istanbul* 2020;7(4):398–399.

A 37-year-old female patient was referred to our clinic by a dentist because of neck swelling during dental extraction. It was learned from the anamnesis taken from the dentist that neck swelling developed during the use of air-turbine dental drill after the extraction of the left lower first molar tooth. On admission, blood pressure was 135/65 mmHg, oxygen saturation was 96%, and fever was 36.5 °C. She had neck and chest pain. On physical examination, there was subcutaneous emphysema, especially on the left side of the neck, starting from the level of the left mastoid process. Laboratory parameters of the patient were leukocyte count 12300K/dL and neutrophil count 11400 K/dL. Other laboratory parameters were evaluated within normal limits.

Computed tomography showed free air densities in the subcutaneous soft tissues and muscle tissues, extending to the left orbital level in the anterior regions, more prominent on the left neck. This free air image was spread in the mediastinum, left hemithorax, anterior paracardiac regions, subcutaneous soft tissues in the neck and supraclavicular areas (Fig. 1). Prophylactic intravenous vancomycin, meropenem and gentamicin treatment was started. After six days of hospitalization, subcutaneous emphysema decreased, and the patient was discharged without any complication.

The most common etiologic causes of subcutaneous emphysema and pneumomediastinum are iatrogenic



**FIGURE 1.** Computed tomography images of the patient. **(A)** Subcutaneous emphysema at the level of the left orbital lateral wall (large arrows). **(B)** Subcutaneous emphysema at the left maxillary sinus level (large arrows). **(C)** Subcutaneous emphysema with more spread to the left side at the level of the mandible (white asterisks). **(D)** Air is located around the mediastinum and pericardium at the T4 level (small arrows); subcutaneous emphysema shown in the thoracic wall (black asterisks).

causes, including head and neck surgery, intubation, mechanical ventilation, and dental surgery [1]. During

Received: September 30, 2019 Accepted: December 23, 2019 Online: June 03, 2020

Correspondence: Serdar OZDEMIR, MD. Saglik Bilimleri Universitesi, Umraniye Egitim ve Arastirma Hastanesi, Acil Tip Klinigi, Istanbul, Turkey.

Tel: +90 505 267 32 92 e-mail: dr.serdar55@hotmail.com

© Copyright 2020 by Istanbul Provincial Directorate of Health - Available online at www.northclinist.com



a surgical tooth extraction, restoration of the tooth, or cleaning of bone tissue around the tooth, compressed air or fragments of the tooth and bone may advance through the surgical wound or dental socket by high-speed dental air turbine drills. This effect of air turbine drills is often limited to local tissue [2]. However, there are cases where compressed air progresses to the mediastinum, as in our case [3–5].

**Informed Consent:** Written informed consent was obtained from the patient for the publication of the case report and the accompanying images.

## REFERENCES

1. Kouritas VK, Papagiannopoulos K, Lazaridis G, Baka S, Mpoukovinas I, Karavasilis V, et al. Pneumomediastinum. *J Thorac Dis* 2015;7:S44–9.
2. Tan S, Nikolarakos D. Subcutaneous emphysema secondary to dental extraction: A case report. *Aust Dent J* 2017;62:95–7.
3. Yang SC, Chiu TH, Lin TJ, Chan HM. Subcutaneous emphysema and pneumomediastinum secondary to dental extraction: a case report and literature review. *Kaohsiung J Med Sci* 2006;22:641–5.
4. Goodnight JW, Sercarz JA, Wang MB. Cervical and mediastinal emphysema secondary to third molar extraction. *Head Neck* 1994;16:287–90.
5. Ocakcioglu I, Koyuncu S, Kupeli M, Bol O. Pneumomediastinum after Tooth Extraction. *Case Rep Surg* 2016;2016:4769180.