

ORIGINAL ARTICLE

Brain dysfunction in COVID-19 and CAR-T therapy: cytokine storm-associated encephalopathy

Umberto Pensato^{1,*} , Lorenzo Muccioli^{1,*} , Ilaria Cani¹, Damir Janigro², Pier Luigi Zinzani^{3,4}, Maria Guarino⁵, Pietro Cortelli^{1,5}  & Francesca Bisulli^{1,5} 

¹Dipartimento di Scienze Biomediche e Neuromotorie, Università di Bologna, Bologna, Italy

²Department of Physiology, Case Western Reserve University, Cleveland, OH

³IRCCS Azienda Ospedaliero-Universitaria di Bologna, Bologna, Italy

⁴Istituto di Ematologia "Seragnoli", Dipartimento di Medicina Specialistica, Diagnostica e Sperimentale, Università di Bologna, Bologna, Italy

⁵IRCCS Istituto delle Scienze Neurologiche di Bologna, Bologna, Italy

Correspondence

Francesca Bisulli, Department of Biomedical and Neuromotor Sciences, University of Bologna, Bellaria Hospital, Via Altura 3 Bologna 40139, Italy. Tel: +39 0514966937; Fax: +39 0514966080; E-mail: francesca.bisulli@unibo.it

Funding Information

No funding information provided.

Received: 24 February 2021; Revised: 3 March 2021; Accepted: 7 March 2021

Annals of Clinical and Translational Neurology 2021; 8(4): 968–979

doi: 10.1002/acn3.51348

*These authors contributed equally to this work.

Abstract

Objective: Many neurological manifestations are associated with COVID-19, including a distinct form of encephalopathy related to cytokine storm, the acute systemic inflammatory syndrome present in a subgroup of COVID-19 patients. Cytokine storm is also associated with immune effector cell-associated neurotoxicity syndrome (ICANS), a complication of chimeric antigen receptor T-cell (CAR-T) therapy, a highly effective treatment for refractory hematological malignancies. We investigated whether COVID-19-related encephalopathy, ICANS, and other encephalopathies associated with cytokine storm, share clinical and investigative findings. **Methods:** Narrative literature review. **Results:** Comparisons between COVID-19-related encephalopathy and ICANS revealed several overlapping features. Clinically, these included dysexecutive syndrome, language disturbances, akinetic mutism and delirium. EEG showed a prevalence of frontal abnormalities. Brain MRI was often unrevealing. CSF elevated cytokine levels have been reported. A direct correlation between cytokine storm intensity and severity of neurological manifestations has been shown for both conditions. Clinical recovery occurred spontaneously or following immunotherapies in most of the patients. Similar clinical and investigative features were also reported in other encephalopathies associated with cytokine storm, such as hemophagocytic lymphohistiocytosis, sepsis, and febrile infection-associated encephalopathies. **Interpretation:** COVID-19-related encephalopathy and ICANS are characterized by a predominant electro-clinical frontal lobe dysfunction and share several features with other encephalopathies associated with cytokine storm, which may represent the common denominator of a clinical spectrum of neurological disorders. Therefore, we propose a unifying definition of cytokine storm-associated encephalopathy (CySE), and its diagnostic criteria.

Introduction

Coronavirus disease 2019 (COVID-19) is a pandemic caused by severe acute respiratory syndrome coronavirus 2 (SARS-CoV-2), predominantly characterized by respiratory symptoms. The condition encompasses a broad spectrum of severity,¹ associated in a subgroup of patients with cytokine storm, an acute systemic inflammatory syndrome that may lead to multiorgan failure.² Both central and peripheral nervous system manifestations have been

reported.^{3,4} COVID-19-related encephalopathy has been described as a distinct clinical condition whose biological underpinnings have not been wholly unveiled.^{3–6} Although it was initially attributed to CNS invasion by SARS-CoV-2, based on evidence from other coronavirus neuroinvasive and neurotropic properties,^{7,8} SARS-CoV-2 RNA is almost invariably undetectable in the cerebrospinal fluid (CSF) of patients with neurological manifestations.^{3,9} Additionally, CSF analysis, neuroimaging, and neuropathological findings, as well as the clinical

response to various immunotherapies, are not consistent with an infectious disease targeting the brain but rather with an immune-mediated pathogenesis.^{4,9–11} Therefore, a cytokine-mediated neuroinflammatory process, associated with cytokine storm, has been suggested as the underlying pathogenic mechanism.^{5,10,12–14}

Chimeric antigen receptor T-cell (CAR-T) therapy is a novel and highly effective treatment for refractory hematological malignancies, whose most common complication is cytokine release syndrome, a cytokine storm disorder.^{14,15} Its therapeutic benefit is also limited by neurotoxicity, namely immune effector cell-associated neurotoxicity syndrome (ICANS), which may accompany cytokine storm.^{15–17} Notably, encephalopathy has been described as a recurrent manifestation also in other cytokine storm disorders, such as hemophagocytic lymphohistiocytosis and sepsis.¹⁴

Herein, we aimed to (i) briefly review different cytokine storm disorders (for a comprehensive description, we suggest a recently published review¹⁴); (ii) provide a detailed comparison between COVID-19-related encephalopathy and neurotoxicity related to CAR-T therapy to show that these conditions are characterized by overlapping clinical and investigative features; (iii) describe neurological manifestations in other hyperinflammatory syndromes, suggesting that these may belong to the same spectrum of cytokine storm-associated encephalopathy disorders.

Cytokine Storm Disorders

The cytokine storm umbrella encompasses several disorders at the intersection of hematology, oncology, rheumatology, and virology. Cytokine storm is characterized by a dysregulated immune response to various triggers and is

defined by elevated circulating cytokine levels, acute systemic inflammatory symptoms, and secondary organ dysfunction, including the brain.¹⁴ Activated macrophages and monocytes appear to be responsible for the pathological hyperinflammation, regardless of the triggers.^{14,18} Several cytokine storm disorders have been described, including COVID-19-associated cytokine storm,¹⁸ cytokine release syndrome,¹⁵ hemophagocytic lymphohistiocytosis (HLH),¹⁹ macrophage activation syndrome,²⁰ and multicentric Castleman disease.²¹ Although their *primum movens* differ, they share several laboratory abnormalities and clinical features, including encephalopathy (Table 1)^{14,18}; diagnostic criteria exist to discriminate between these hyperinflammatory disorders.^{15,18,22,23}

In COVID-19, SARS-CoV-2 invades macrophages/monocytes via the ACE2 receptor, leading to their activation.²⁴ As a result, a subgroup of COVID-19 patients develop cytokine storm that may exacerbate lung damage and lead to multiorgan failure.² Cytokine release syndrome is a supra-physiological response observed in oncological patients treated with CAR T-cells or other immune effector cell-engaging therapies.¹⁵ Activated T-cells directed against tumor antigens release interferon-gamma, which stimulates macrophages, resulting in cytokine storm.²⁵ A hyperinflammatory state coupled with a dysregulated immune system is also considered the underlying mechanism of HLH.²⁶ Various triggers, usually an acute viral infection, may lead to macrophage activation, resulting in hypercytokinemia in subjects unable to suppress these cells.²⁶ Predisposing conditions to HLH include malignancies and immunodeficiency disorders.²⁷ MAS is a condition observed in patients affected by rheumatological disorders with overlapping laboratory features with HLH, and is therefore frequently referred to as rheumatological HLH.¹⁴

Table 1. Features of interest in selected cytokine storm disorders.

	COVID-19-associated cytokine storm	Cytokine release syndrome	Macrophage activation syndrome	Hemophagocytic lymphohistiocytosis
Trigger	SARS-CoV-2 infection	CAR T-cell therapy	Autoimmune disorders	Viral infections, hematological cancers, inherited and acquired immunodeficiencies
Encephalopathy	++	+++	++	++
Fever	++	++	++	++
Lymphopenia	+++	+++	+	+++
Ferritin	++	+++	+++	++
Lactate dehydrogenase	++	+++	+++	++
D-dimer	+++	++	++	+++
Hypofibrinogenemia	None	+++	++	+++
IL-6	++	+++	+++	+++

Modified from Webb *et al.* Lancet Rheum 2020.¹⁸

Sepsis is defined as an overwhelming inflammatory response to an infection, where it is still unclear which immune cell types and cytokines may be responsible for propagating the pathological hyperinflammation.¹⁴ Notably, a subgroup of septic patients develop a macrophage activation-like syndrome.²⁸

Comparison of COVID-19-Related Encephalopathy and ICANS

Clinical features

COVID-19-related encephalopathy and ICANS are two neuropsychiatric syndromes with varying degrees of severity, ranging from mildly altered mental status to coma. Delirium is one of the most common and earliest symptoms of COVID-19-related encephalopathy,^{29–31} present in up to 85% of COVID-19 patients in ICU,³² and is also reported in up to 66% of patients with ICANS.³³

Language disturbances, notably expressive aphasia, are a frequent finding in both conditions, and may represent the first manifestation of CNS dysfunction, which may develop into a more severe form of encephalopathy.^{10,16,17,29,34} Aphasia usually develops over hours/days but may also present acutely, mimicking stroke.^{16,35} Akinetic mutism is an uncommon neurological presentation resulting from frontal-subcortical dissociation³⁶ that has been described as a specific feature of ICANS.¹⁵ This peculiar manifestation has also been observed in several case reports of COVID-19-related encephalopathy,^{10,11,30,37,38} and might help discriminate these conditions from other encephalopathies.¹⁵

Frontal release signs and dysexecutive symptoms represent a common finding in patients with COVID-19-related encephalopathy^{11,37,39} and are commonly encountered in ICANS,^{16,17} further suggesting a frontal lobe dysfunction.

Transitory motor deficits have been described for both conditions, while corticospinal tract signs have been observed in up to 67% cases with severe SARS-CoV-2 infection^{32,39} and various other case reports of COVID-19-related encephalopathy,^{11,29,40,41} potentially representing a recurrent feature of this condition. Movement disorders, such as tremor and myoclonus of varying severity, have also been observed in both disorders.^{6,17,30,42,43} Seizures represent a relatively frequent manifestation of ICANS, and their occurrence is a defining feature of severe neurotoxicity.^{15,17} Patients with COVID-19-related encephalopathy may also present with new-onset seizures, either focal or generalized, convulsive or non-convulsive, including status epilepticus.^{44–46}

Headache is another frequently reported symptom in COVID-19 and ICANS, occurring in 28% and 55% of patients, respectively.^{16,47} Even though this is a non-

specific manifestation and its features have been poorly described in both disorders, it may represent an early manifestation of CNS involvement.

EEG

Since the outbreak of SARS-CoV-2, several reports of EEG findings in COVID-19 patients have been published. Diffuse background slowing is the most frequent abnormality, reported in approximately two-thirds of patients.⁴⁸ Other diffuse EEG features include generalized rhythmic delta activity and periodic discharges with triphasic morphology.⁴⁸ Notably, many studies describe a preponderance of frontal lobe abnormalities, including frontal focal slowing and intermittent rhythmic delta activity (FIRDA), sharp waves, epileptiform discharges, and status epilepticus.^{10,32,45,49–52}

Similarly, diffuse slowing in the theta-delta range occurs in most ICANS patients, and FIRDA represents the most common rhythmic pattern, followed by generalized periodic discharges with triphasic morphology.^{16,53} In both conditions, EEG abnormalities correlate with the severity of the encephalopathy and might improve following immunotherapy.^{11,37,48,54}

Neuroimaging

Neuroradiological features of COVID-19-related encephalopathy are heterogeneous. Most patients present with an unremarkable examination, but a few recurring radiological features have been reported, including multifocal white matter hyperintensities, diffuse microbleeds, cortical diffusion restriction, and leptomeningeal enhancement.^{55,56}

Brain MRI in ICANS is also often unrevealing, but radiological abnormalities similar to those in COVID-19 have been described.^{16,17,33} Interestingly, lesion of the splenium of the corpus callosum^{5,17,57} and neuroradiological findings resembling acute necrotizing encephalopathy^{17,58,59} and posterior reversible encephalopathy syndrome (PRES)^{17,60–62} have been observed in both COVID-19 patients and CAR T-cell therapy recipients.

FDG-PET and perfusion studies in COVID-19-related encephalopathy showed frontal lobe hypometabolism and hypoperfusion, consistent with the observed electro-clinical frontal lobe dysfunction.^{38,39,63} In ICANS, FDG-PET shows variable patterns of cortical hypometabolism, often colocalized with EEG abnormalities.¹⁶

Pathophysiology

Several studies have shown a direct correlation between cytokine storm intensity and severity of neurological manifestations in COVID-19-related encephalopathy and

ICANS.^{11,32,33,39,64} The average lower serum cytokine load detected in COVID-19-associated cytokine storm compared with cytokine release syndrome may explain the lower incidence of encephalopathy observed in the former (Table 1).^{18,65} In COVID-19-related encephalopathy, CSF SARS-CoV-2 RNA remains almost invariably undetectable,^{3,9} making a pathogenic role of CNS viral invasion unlikely. Similarly, neurotoxicity grade in ICANS correlates with CSF cytokine levels but not with CAR T-cells in CSF.¹⁷ In both conditions, CSF investigations revealed normal or mildly elevated cell counts with variable protein levels and elevated cytokine levels with molecular consistency across conditions.^{10,13,16,17,37,38,66} Therefore, a cytokine-mediated neuroinflammatory process has been suggested as the underlying pathogenic mechanism.^{5,10,12,14}

Evidence suggests that peripheral inflammation may lead to endothelial activation and blood–brain barrier (BBB) disruption, resulting in microglia and astrocyte activation.^{9,67} This induces a neuroinflammatory process that promotes CNS cytokine production, oxidative stress, and immune-cell trafficking, further contributing to BBB disruption, resulting in a vicious circle (Fig. 1).^{5,9,67}

Accordingly, glial (CSF GFAP) and BBB disruption (serum S100B) markers have been found elevated in both ICANS and COVID-19-related encephalopathy.^{5,10,68,69}

Neuropathological findings in COVID-19 patients revealed mild abnormalities with pronounced inflammation due to diffuse astrocyte and microglia activation and infiltration of lymphocytes,^{9,70,71} similar to patients with sepsis.⁷² Additionally, the presence of SARS-CoV-2 RNA was not associated with the severity of neuropathological changes.^{9,70}

Preclinical models demonstrated that frontal lobes are most susceptible to cytokine-induced inflammation via the NF-κB signaling pathway,⁷³ potentially explaining the frontal-predominant dysfunction observed in both conditions.

Outcome and treatment

Spontaneous clinical recovery has been reported for various patients with COVID-19-related encephalopathy.^{10,29,30} However, a subgroup of patients may develop severe neurological manifestations (e.g., impairment of consciousness) lasting up to several weeks.^{11,64} High-dose corticosteroids, intravenous immunoglobulin, and plasmapheresis have shown efficacy in treating COVID-19-related encephalopathy, promoting recovery even in patients with a severe, persistent encephalopathy.^{10,11,37,64,74–76} Clinical responses may occur as soon as the first day following immunotherapy and may be

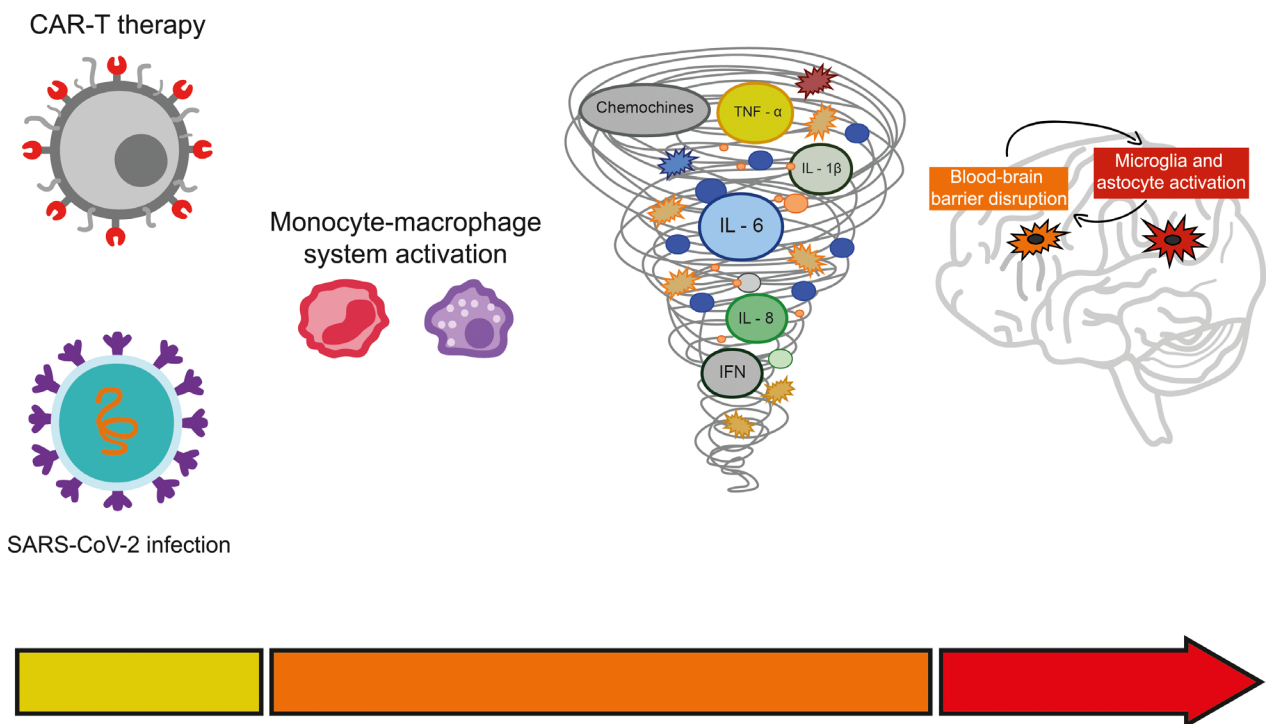


Figure 1. Schematic representation of the mechanisms underlying cytokine-mediated neuroinflammation. Different triggers, including CAR T-cell therapy and SARS-CoV-2 infection, may lead to a massive release of cytokines via activation of the monocyte/macrophage system. Peripheral cytokines promote blood–brain barrier disruption and microglia/astrocyte activation, which may act synergistically.

accompanied by a dramatic decrease of circulating and CSF cytokines.^{11,37} However, considering the absence of reliable response biomarkers, treatment duration should be primarily based on clinical response.

In ICANS, most symptoms are transient and fully reversible, with sparse reports of persistent abnormalities.^{17,77} In rare cases, encephalopathy may progress to coma and lead to death as a consequence of diffuse cerebral edema.¹⁶ Corticosteroids represent the first-line therapy for ICANS but are typically employed only in severe cases, as there is a potential concern of their interference with CAR T-cells anti-tumor action.^{77,78} Tocilizumab, an anti-IL-6 receptor antibody, is the standard of care in cytokine release syndrome¹⁵ and has also shown efficacy in COVID-19.⁷⁹ Yet, its role in the management of associated neurological manifestations remains controversial, as it may lead to increased IL-6 levels in the CSF, which may exacerbate neurotoxicity.¹⁵ In both conditions, the overall prognosis is strongly influenced by the course of systemic disease and not only by CNS involvement, which is linked to preexisting comorbidities.^{80–83}

Other Encephalopathies Associated With Systemic Hyperinflammation

Neurological manifestations of hemophagocytic lymphohistiocytosis

CNS involvement has been reported in up to 70% of HLH patients, either during the disease or presentation.^{84,85} Most of the data are derived from a pediatric population, while comparably fewer studies investigated neurological manifestations in adults.^{84,86,87} Clinical presentation is very heterogeneous, yet seizures and altered mental status represent the most common manifestations, with the former being more prevalent in pediatric patients.^{86,88} In an adult HLH case series with neurological involvement, encephalopathy and language disturbances were present in all patients and were variably associated with seizures, pyramidal dysfunction, and myoclonus.⁸⁴ CSF analysis usually shows normal or mildly elevated cell counts and variable protein levels, while several brain MRI abnormalities have been described, including T2/FLAIR hyperintensities, restricted diffusion, and gadolinium enhancement in multiple areas of the brain and meninges.^{84,86,87} Most of the neurological symptoms were present during highly active systemic disease; hence a cytokine-mediated neuroinflammatory process has been suggested as the main pathogenic mechanism,^{87,88} even though CSF cytokine levels have not been, to our knowledge, investigated. HLH-related encephalopathy is treated with immunotherapies with conflicting results, likely reflecting the severity of disease.⁸⁴

Febrile infection-associated encephalopathy disorders

Mild encephalopathy with a reversible splenic lesion (MERS), acute necrotizing encephalopathy (ANE), and febrile infection-related epilepsy syndrome (FIRES) are three neurological disorders that typically occur following an infectious febrile illness in otherwise healthy children and, more rarely, in adults.^{89–94}

Patients with MERS may present with seizures, mildly altered level of consciousness, delirium, and language disturbances, and mostly have a complete recovery after a short disease course.^{89,90} The neuroradiological hallmark of MERS is a transitory lesion of the splenium of the corpus callosum, a finding that has also been reported in COVID-19-related encephalopathy,^{5,57} ICANS,¹⁷ ANE,⁹⁵ and FIRES.⁹⁶

ANE is a life-threatening condition with similar manifestations yet much greater severity, where altered consciousness rapidly progresses to coma; survivors often retain neurological sequelae.^{91,92} Brain MRI shows multifocal, symmetric lesions involving the thalamus and other regions, including cerebral white matter, basal ganglia, brainstem, and cerebellum.^{91,92} Interestingly, clinical and radiological features of ANE have been described for several patients with HLH^{97–99} and COVID-19,^{58,100,101} as well as in CAR T-cell therapy recipients.¹⁷

FIRES is a devastating epilepsy syndrome with poor outcome, currently regarded as a subcategory of new-onset refractory status epilepticus (NORSE).^{94,102} Specifically, it shares several features with cryptogenic NORSE, including prodromal fever.¹⁰³ Patients with FIRES commonly have T2/FLAIR hyperintensities in the mesial temporal lobe and other brain structures, notably the claustrum in adult patients (so-called "claustrum sign").^{93,103,104} This latter finding is frequently encountered also in familial ANE¹⁰⁵ and has been reported in COVID-19-related encephalopathy.^{106,107} Additionally, HLH has been described in patients with FIRES.¹⁰⁸

Although the exact pathogenesis remains unclear, it is likely that abnormal host response to the pathogen leads, in predisposed subjects, to cytokine storm and then to cytokine-mediated neuroinflammation due to BBB disruption and microglia activation. This hypothesis is supported by several findings, including (i) the biphasic clinical course, where encephalopathy follows systemic inflammation, (ii) the presence of upregulated proinflammatory cytokines with elevated CSF/blood ratio, (iii) the absence of concomitant findings suggestive of infectious brain disease (absence of marked pleocytosis and pathogens in CSF), (iv) the variable responses reported to immunotherapies, including anti-cytokine drugs in FIRES, as well as (v) the associations mentioned above with well-

defined cytokine storm disorders and related encephalopathies.^{91,92,109–112}

Many other febrile infection-associated encephalopathy disorders showing overlapping clinical-radiological features and, presumably, similar pathogenesis have been described. These include acute infantile encephalopathy predominantly affecting the frontal lobes,¹¹³ acute encephalopathy with fulminant cerebral edema,¹¹⁴ acute encephalopathy with early biphasic seizures and late reduced diffusion,¹¹⁵ hemorrhagic shock and encephalopathy syndrome,¹¹⁶ hemiconvulsion-hemiplegia-epilepsy syndrome,¹¹⁷ and Reye-like syndrome.¹¹⁸

Sepsis-associated encephalopathy (SAE)

Septic patients frequently present with altered mental status, ranging from mild confusion to coma, which may be one of the earliest clinical manifestations and has been included in the diagnostic criteria of sepsis.^{119,120} SAE is defined in the presence of sepsis when other potential

causes of encephalopathy, including infectious brain disease, are reasonably excluded.¹²⁰ EEG is often characterized by diffuse background slowing but may also reveal a non-convulsive status epilepticus.¹²¹ Notably, EEG abnormalities have been observed in half of the septic patients without clinical evidence of SAE.¹²¹ CSF findings are usually unremarkable, except CSF proteins, which may be elevated, reflecting increased permeability of the BBB.¹²⁰ Neuroimaging is commonly unrevealing, although vasogenic edema, severe leukoencephalopathy, and PRES-like features may be observed.^{61,122}

The underlying pathophysiology is likely multifactorial, as several mechanisms have been proposed, including neuroinflammatory mechanisms similar to the abovementioned cytokine storm-associated conditions.^{120,123–125} The cornerstone of SAE treatment consists in resolving the underlying sepsis with antibiotic therapy and supporting failing organs.¹²³ Immunotherapies targeting proinflammatory mediators have been investigated in sepsis,¹²⁶ but not specifically in SAE.¹²³

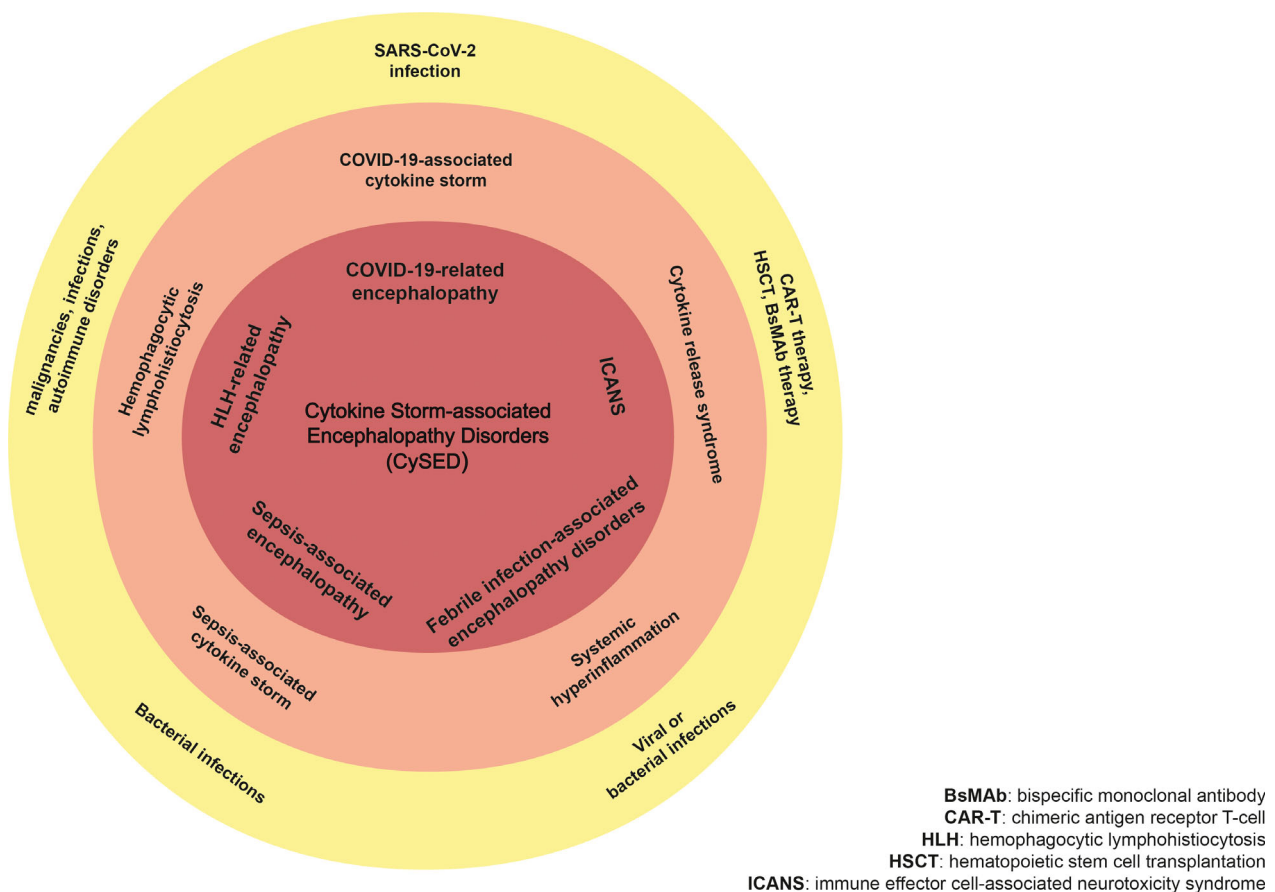


Figure 2. The spectrum of Cytokine Storm-associated Encephalopathy Disorders (CySED). The yellow circle relates to different triggers responsible for cytokine storm disorders (orange circle). Cytokine storm-associated encephalopathy disorders are shown in the red circle.

Discussion

The overwhelming wave of neurological complications observed during COVID-19 pandemic warrants an unmet need to understand the underlying pathophysiological mechanisms to inform treatment. COVID-19-related encephalopathy represents a distinct condition characterized by a predominant electro-clinical frontal lobe dysfunction; strong evidence argues for a cytokine-mediated neuroinflammatory process. As ICANS is a well-defined syndrome that shares the same pathogenic mechanism, we compared these encephalopathy disorders. We report a remarkable overlap of clinical, EEG, neuroradiological, and laboratory features, including the response to immunotherapies.

From these observations, we expanded our focus on neurological manifestations of other conditions associated with cytokine storm, HLH- and sepsis-associated encephalopathy, or where a common neurological mechanism is likely, febrile infection-associated encephalopathies. We found, perhaps surprisingly, that all these disorders have similar features suggesting a common overarching mechanism leading to encephalopathy.

Dysregulated cytokine networks in the CNS are implicated in the pathophysiology of a wide range of other neurological diseases, including autoimmune, infectious, and degenerative conditions.^{127–130} However, the association with cytokine storm observed in the encephalopathies reviewed herein suggests a primary role of proinflammatory cytokines in their pathogenesis.

To date, many of the neurological disorders discussed above have been defined based on clinical presentation associated with specific investigative findings, irrespective of the pathogenic mechanisms. In fact, the encephalopathies presented here have been previously described and named as distinct entities since they exhibit a wide range of clinical-radiological features, and the associated cytokine storm may have different causes. While acknowledging the presence of several differences among these conditions, we suggest that a uniform and comprehensive term may be useful to summarize phenotypic and pathophysiological similarities (Fig. 2). We, therefore, propose a unifying definition of cytokine storm-associated encephalopathy (CySE) based on the following criteria: encephalopathy with acute or subacute onset, association with cytokine storm (as defined by Fajgenbaum *et al.*), and exclusion of other causes that might independently account for the severity of neurological manifestations. These criteria, as well as supportive findings, are presented in Table 2. In a recent work by Leisman *et al.*,¹³¹ a meta-analysis was performed to investigate the pathological ranges of blood cytokines and biomarkers across different conditions, including disorders often characterized

Table 2. Proposed criteria for cytokine storm-associated encephalopathy (CySE).

Encephalopathy	<ul style="list-style-type: none"> -Acute or subacute onset -Severity ranging from mildly altered mental status to coma -Common manifestations include: delirium, language disturbances, seizures, and dysexecutive syndrome
Association with cytokine storm ¹	<ul style="list-style-type: none"> Cytokine storm criteria proposed by Fajgenbaum <i>et al.</i>¹ -Elevated circulating cytokine levels -Acute systemic inflammatory symptoms -Secondary organ dysfunction² beyond that which could be attributed to a pathogen, if a pathogen is present
Exclusion of other causes ³	<ul style="list-style-type: none"> Including, but not limited to: -Metabolic disturbances -Definite infectious brain disease -Autoantibody-mediated brain disease
Supportive findings	<ul style="list-style-type: none"> -CSF analysis: absence of marked pleocytosis, elevated cytokine CSF/serum ratio -EEG: frontal predominant abnormalities -Brain MRI⁴: diffuse microbleeds, cortical diffusion restriction, and leptomeningeal enhancement; T2/FLAIR hyperintensities of the splenium of the corpus callosum, thalami, or claustrum; PRES-like findings -FDG-PET/MRI perfusion: frontal predominant hypometabolism/hypoperfusion -Response to immunotherapies

¹Cytokine storm may occur concomitantly or precede neurological manifestations.

²This may include brain dysfunction.

³The presence of one or more concomitant conditions potentially contributing to encephalopathy should not be considered as an absolute exclusion criteria if these are not sufficient to account for clinical severity.

⁴Most of the patients present with unrevealing neuroradiological examinations. It is confounding to use number for references and notes in the same table. Would it be possible to use letters for table notes?

by cytokine storm-associated encephalopathy. This paper makes abundantly clear that an extreme variability exists across different centers and conditions, making it all but impossible at this stage to report a cut-off level for any of the molecular players involved. The absence of recognized diagnostic cut-offs for biomarkers of cytokine storm may limit the applicability of our proposed criteria in patients with milder systemic inflammation. Future studies are warranted to address this issue, to support clinicians in diagnosing cytokine storm and related complications, including CySE. This spectrum of neurological conditions likely includes other encephalopathies associated with

systemic hyperinflammation. We suggest that recognizing a spectrum of cytokine storm-associated encephalopathy disorders may facilitate the cross-translation of knowledge acquired from individual conditions, with potentially relevant clinical implications, such as targeted therapeutic approaches.

Acknowledgments

We thank our colleagues at the COVID-19 Unit, Bologna, Italy, in particular Drs. Luca Guerra and Stefania Zaccaroni, for their tireless work in assisting COVID-19 patients. We also thank Lara Alvisi for her precious assistance and Davide Bolognini, who provided technical support for the figures.

Conflict of Interest

The authors declare no conflict of interest.

References

- Guan WJ, Ni ZY, Hu Y, et al. Clinical characteristics of coronavirus disease 2019 in China. *N Engl J Med* 2020;382:1708–1720.
- Mehta P, McAuley DF, Brown M, et al. COVID-19: consider cytokine storm syndromes and immunosuppression. *Lancet* 2020;395:1033–1034.
- Pezzini A, Padovani A. Lifting the mask on neurological manifestations of COVID-19. *Nat Rev Neurol* 2020;16(11):636–644. <https://doi.org/10.1038/s41582-020-0398-3>
- Ellul MA, Benjamin L, Singh B, et al. Neurological associations of COVID-19. *Lancet Neurol* 2020;19:767–783.
- Perrin P, Collongues N, Baloglu S, et al. Cytokine release syndrome-associated encephalopathy in patients with COVID-19. *Eur J Neurol* 2020;28(1):248–258. <https://doi.org/10.1111/ene.14491>
- Garg RK, Paliwal VK, Gupta A. Encephalopathy in patients with COVID-19: a review. *J Med Virol* 2020;93(1):206–222. <https://doi.org/10.1002/jmv.26207>
- Gu J, Gong E, Zhang B, et al. Multiple organ infection and the pathogenesis of SARS. *J Exp Med* 2005;202:415–424.
- Xu J, Zhong S, Liu J, et al. Detection of severe acute respiratory syndrome coronavirus in the brain: potential role of the chemokine MIG in pathogenesis. *Clin Infect Dis* 2005;41:1089–1096.
- Solomon T. Neurological infection with SARS-CoV-2 — the story so far. *Nat Rev Neurol* 2021;17(2):65–66. <https://doi.org/10.1038/s41582-020-00453-w>
- Pilotto A, Masciocchi S. SARS-CoV-2 encephalitis is a cytokine release syndrome: evidences from cerebrospinal fluid analyses. *Clin Infect Dis* 2021;ciaa1933. <https://doi.org/10.1093/cid/ciaa1933>
- Muccioli L, Pensato U, Bernabe G, et al. Intravenous immunoglobulin therapy in COVID-19-related encephalopathy. *J Neurol* 2020;8:1–5. <https://doi.org/10.1007/s00415-020-10248-0>
- Muccioli L, Pensato U, Cani I, et al. Covid-19-associated encephalopathy and cytokine-mediated neuroinflammation. *Ann Neurol* 2020;88:860–861.
- Remsik J, Wilcox JA, Babady NE, et al. Inflammatory leptomeningeal cytokines mediate COVID-19 neurologic symptoms in cancer patients. *Cancer Cell* 2021;39:276–283.e3.
- Fajgenbaum DC, June CH. Cytokine storm. *N Engl J Med* 2020;383:2255–2273.
- Lee DW, Santomasso BD, Locke FL, et al. ASTCT consensus grading for cytokine release syndrome and neurologic toxicity associated with immune effector cells. *Biol Blood Marrow Transplant* 2019;25:625–638.
- Rubin DB, Danish HH, Ali AB, et al. Neurological toxicities associated with chimeric antigen receptor T-cell therapy. *Brain* 2019;142:1334–1348.
- Santomasso BD, Park JH, Salloum D, et al. Clinical and biological correlates of neurotoxicity associated with CAR T-cell therapy in patients with B-cell acute lymphoblastic leukemia. *Cancer Discov* 2018;8:958–971.
- Webb BJ, Peltan ID, Jensen P, et al. Clinical criteria for COVID-19-associated hyperinflammatory syndrome: a cohort study. *Lancet Rheumatol* 2020;2(12):e754–e763.
- Brisse E, Wouters CH, Matthys P. Hemophagocytic lymphohistiocytosis (HLH): a heterogeneous spectrum of cytokine-driven immune disorders. *Cytokine Growth Factor Rev* 2015;26:263–280.
- Ravelli A, Minoia F, Davi S, et al. 2016 classification criteria for macrophage activation syndrome complicating systemic juvenile idiopathic arthritis: a European League against Rheumatism/American College of Rheumatology/Paediatric rheumatology international trials organisation collaborative initiative. *Ann Rheum Dis* 2016;75:481–489.
- Fajgenbaum DC, Uldrick TS, Bagg A, et al. International, evidence-based consensus diagnostic criteria for HHV-8-negative/idiopathic multicentric Castleman disease. *Blood* 2017;129:1646–1657.
- Henter JI, Horne A, Arico M, et al. HLH-2004: diagnostic and therapeutic guidelines for hemophagocytic lymphohistiocytosis. *Pediatr Blood Cancer* 2007;48:124–131.
- Davi S, Consolaro A, Guseinova D, et al. An international consensus survey of diagnostic criteria for macrophage activation syndrome in systemic juvenile idiopathic arthritis. *J Rheumatol* 2011;38:764–768.
- Merad M, Martin JC. Pathological inflammation in patients with COVID-19: a key role for monocytes and macrophages. *Nat Rev Immunol* 2020;20:355–362.
- Wang Z, Han W. Biomarkers of cytokine release syndrome and neurotoxicity related to CAR-T cell therapy. *Biomark Res* 2018;6:4.

26. Filipovich A, McClain K, Grom A. Histiocytic disorders: recent insights into pathophysiology and practical guidelines. *Biol Blood Marrow Transplant* 2010;16:S82–S89.
27. Hayden A, Park S, Giustini D, et al. Hemophagocytic syndromes (HPSs) including hemophagocytic lymphohistiocytosis (HLH) in adults: a systematic scoping review. *Blood Rev* 2016;30:411–420.
28. Karakike E, Giamarellos-Bourboulis EJ. Macrophage activation-like syndrome: a distinct entity leading to early death in sepsis. *Front Immunol* 2019;10:55.
29. Paterson RW, Brown RL, Benjamin L, et al. The emerging spectrum of COVID-19 neurology: clinical, radiological and laboratory findings. *Brain* 2020;143:3104–3120.
30. Beach SR, Praschan NC, Hogan C, et al. Delirium in COVID-19: a case series and exploration of potential mechanisms for central nervous system involvement. *Gen Hosp Psychiatry* 2020;65:47–53.
31. Benussi A, Pilotto A, Premi E, et al. Clinical characteristics and outcomes of inpatients with neurologic disease and COVID-19 in Brescia, Lombardy, Italy. *Neurology* 2020;95:e910–e920.
32. Helms J, Kremer S, Merdji H, et al. Delirium and encephalopathy in severe COVID-19: a cohort analysis of ICU patients. *Crit Care* 2020;24:491.
33. Gust J, Hay KA, Hanafi LA, et al. Endothelial activation and blood-brain barrier disruption in neurotoxicity after adoptive immunotherapy with CD19 CAR-T cells. *Cancer Discov* 2017;7:1404–1419.
34. Muccioli L, Pensato U, Cani I, et al. COVID-19-related encephalopathy presenting with aphasia resolving following tocilizumab treatment. *J Neuroimmunol* 2020;349:577400.
35. Pensato U, Muccioli L, Pasini E, et al. Encephalopathy in COVID-19 presenting with acute aphasia mimicking stroke. *Front Neurol* 2020;11:1123.
36. Arnts H, van Erp WS, Lavrijsen JCM, et al. On the pathophysiology and treatment of akinetic mutism. *Neurosci Biobehav Rev* 2020;112:270–278.
37. Pilotto A, Odolini S, Masciocchi S, et al. Steroid-responsive encephalitis in coronavirus disease 2019. *Ann Neurol* 2020;88(2):423–427. <https://doi.org/10.1002/ana.25783>
38. Cani I, Barone V, D'Angelo R, et al. Frontal encephalopathy related to hyperinflammation in COVID-19. *J Neurol* 2021;268:16–19.
39. Helms J, Kremer S, Merdji H, et al. Neurologic features in severe SARS-CoV-2 infection. *N Engl J Med* 2020;382:2268–2270.
40. Ye M, Ren Y, Lv T. Encephalitis as a clinical manifestation of COVID-19. *Brain Behav Immun* 2020;88:945–946.
41. Yin R, Feng W, Wang T, et al. Concomitant neurological symptoms observed in a patient diagnosed with coronavirus disease 2019. *J Med Virol* 2020;92:1782–1784.
42. Muccioli L, Rondelli F, Ferri L, et al. Subcortical myoclonus in COVID-19: comprehensive evaluation of a patient. *Mov Disord Clin Pract* 2020;7(8):971–973. <https://doi.org/10.1002/mdc3.13046>
43. Rabano-Suarez P, Bermejo-Guerrero L, Mendez-Guerrero A, et al. Generalized myoclonus in COVID-19. *Neurology* 2020;95:e767–e772.
44. Hwang ST, Ballout AA, Mirza U, et al. Acute seizures occurring in association with SARS-CoV-2. *Front Neurol* 2020;11:576329.
45. Le Guennec L, Devianne J, Jalin L, et al. Orbitofrontal involvement in a neuroCOVID-19 patient. *Epilepsia* 2020;61:e90–e94.
46. Santos de Lima F, Issa N, Seibert K, et al. Epileptiform activity and seizures in patients with COVID-19. *J Neurol Neurosurg Psychiatry* 2020;324337. <https://doi.org/10.1136/jnnp-2020-324337>
47. Mao L, Jin H, Wang M, et al. Neurologic manifestations of hospitalized patients with coronavirus disease 2019 in Wuhan, China. *JAMA Neurol* 2020;77(6):683–690. <https://doi.org/10.1001/jamaneurol.2020.1127>
48. Antony AR, Haneef Z. Systematic review of EEG findings in 617 patients diagnosed with COVID-19. *Seizure* 2020;83:234–241. <https://doi.org/10.1016/j.seizure.2020.10.014>
49. Galanopoulou AS, Ferastraoar V, Correa DJ, et al. EEG findings in acutely ill patients investigated for SARS-CoV-2/COVID-19: a small case series preliminary report. *Epilepsia Open* 2020;5:314–324.
50. Pasini E, Bisulli F, Volpi L, et al. EEG findings in COVID-19 related encephalopathy. *Clin Neurophysiol* 2020;131:2265–2267.
51. Vellieux G, Rouvel-Talleg C, Jaquet P, et al. COVID-19 associated encephalopathy: is there a specific EEG pattern? *Clin Neurophysiol* 2020;131:1928–1930.
52. Vespignani H, Colas D, Lavin BS, et al. Report on electroencephalographic findings in critically ill patients with COVID-19. *Ann Neurol* 2020;88:626–630.
53. Rice J, Nagle S, Randall J, Hinson HE. Chimeric antigen receptor T cell-related neurotoxicity: mechanisms, clinical presentation, and approach to treatment. *Curr Treat Options Neurol* 2019;21:40.
54. Herlopian A, Dietrich J, Abramson JS, et al. EEG findings in CAR T-cell therapy-related encephalopathy. *Neurology* 2018;91:227–229.
55. Kandemirli SG, Dogan L, Sarikaya ZT, et al. Brain MRI findings in patients in the intensive care unit with COVID-19 infection. *Radiology* 2020;297(1):E232–E235. <https://doi.org/10.1148/radiol.2020201697>

56. Kremer S, Lersy F, de Seze J, et al. Brain MRI findings in severe COVID-19: a retrospective observational study. *Radiology* 2020;297(2):E242–E251. <https://doi.org/10.1148/radiol.2020202222>
57. Hayashi M, Sahashi Y, Baba Y, et al. COVID-19-associated mild encephalitis/encephalopathy with a reversible splenic lesion. *J Neurol Sci* 2020;415:116941.
58. Dixon L, Varley J, Gontsarova A, et al. COVID-19-related acute necrotizing encephalopathy with brain stem involvement in a patient with aplastic anemia. *Neurol Neuroimmunol Neuroinflamm* 2020;7(5):e789. <https://doi.org/10.1212/NXI.0000000000000789>
59. Poyiadji N, Shahin G, Noujaim D, et al. COVID-19-associated acute hemorrhagic necrotizing encephalopathy: imaging features. *Radiology* 2020;296:E119–E120.
60. Anand P, Lau KHV, Chung DY, et al. Posterior reversible encephalopathy syndrome in patients with coronavirus disease 2019: two cases and a review of the literature. *J Stroke Cerebrovasc Dis* 2020;29:105212.
61. Bartynski WS, Boardman JF, Zeigler ZR, et al. Posterior reversible encephalopathy syndrome in infection, sepsis, and shock. *Am J Neuroradiol* 2006;27:2179–2190.
62. D'Amore F, Vinacci G, Agosti E, et al. Pressing issues in COVID-19: probable cause to seize SARS-CoV-2 for its preferential involvement of posterior circulation manifesting as severe posterior reversible encephalopathy syndrome and posterior strokes. *Am J Neuroradiol* 2020;41:1800–1803.
63. Delorme C, Paccoud O, Kas A, et al. COVID-19-related encephalopathy: a case series with brain FDG-positron-emission tomography/computed tomography findings. *Eur J Neurol* 2020;27:2651–2657.
64. Cao A, Rohaut B, Le Guennec L, et al. Severe COVID-19-related encephalitis can respond to immunotherapy. *Brain* 2020;143(12):e102. <https://doi.org/10.1093/brain/awaa337>
65. Hoiland RL, Stukas S, Cooper J, et al. Amelioration of COVID-19-related cytokine storm syndrome: parallels to chimeric antigen receptor-T cell cytokine release syndrome. *Br J Haematol* 2020;190:e150–e154.
66. Bodro M, Compta Y, Llanos L, et al. Increased CSF levels of IL-1beta, IL-6, and ACE in SARS-CoV-2-associated encephalitis. *Neurol Neuroimmunol Neuroinflamm* 2020;7(5):e821. <https://doi.org/10.1212/NXI.0000000000000821>
67. Huang X, Hussain B, Chang J. Peripheral inflammation and blood-brain barrier disruption: effects and mechanisms. *CNS Neurosci Ther* 2021;27:36–47.
68. Gust J, Finney OC, Li D, et al. Glial injury in neurotoxicity after pediatric CD19-directed chimeric antigen receptor T cell therapy. *Ann Neurol* 2019;86:42–54.
69. Aceti A, Margarucci LM, Scaramucci E, et al. Serum S100B protein as a marker of severity in Covid-19 patients. *Sci Rep* 2020;10:18665.
70. Matschke J, Lutgehetmann M, Hagel C, et al. Neuropathology of patients with COVID-19 in Germany: a post-mortem case series. *Lancet Neurol* 2020;19:919–929.
71. Fabbri VP, Foschini MP, Lazzarotto T, et al. Brain ischemic injury in COVID-19-infected patients: a series of 10 post-mortem cases. *Brain Pathol* 2021;31(1):205–210. <https://doi.org/10.1111/bpa.12901>
72. Deigendesch N, Sironi L, Kutza M, et al. Correlates of critical illness-related encephalopathy predominate postmortem COVID-19 neuropathology. *Acta Neuropathol* 2020;140:583–586.
73. Young AM, Campbell EC, Lynch S, et al. Regional susceptibility to TNF-alpha induction of murine brain inflammation via classical IKK/NF-kappaB signalling. *PLoS One* 2012;7:e39049.
74. Chaumont H, San-Galli A, Martino F, et al. Mixed central and peripheral nervous system disorders in severe SARS-CoV-2 infection. *J Neurol* 2020;267:3121–3127.
75. Dogan L, Kaya D, Sarikaya T, et al. Plasmapheresis treatment in COVID-19-related autoimmune meningoencephalitis: case series. *Brain Behav Immun* 2020;87:155–158.
76. Pugin D, Vargas MI, Thieffry C, et al. COVID-19-related encephalopathy responsive to high doses glucocorticoids. *Neurology* 2020;95(12):543–546. <https://doi.org/10.1212/WNL.0000000000010354>
77. Santomaso B, Bachier C, Westin J, et al. The other side of CAR T-cell therapy: cytokine release syndrome, neurologic toxicity, and financial burden. *Am Soc Clin Oncol Educ Book* 2019;39:433–444.
78. Gardner R, Leger KJ, Annesley CE, et al. Decreased rates of severe CRS seen with early intervention strategies for CD19 CAR-T cell toxicity management. *Blood* 2016;128:586.
79. Salama C, Han J, Yau L, et al. Tocilizumab in patients hospitalized with covid-19 pneumonia. *N Engl J Med* 2021;384:20–30.
80. Zhou Y, Yang Q, Chi J, et al. Comorbidities and the risk of severe or fatal outcomes associated with coronavirus disease 2019: a systematic review and meta-analysis. *Int J Infect Dis* 2020;99:47–56.
81. Romagnolo A, Balestrino R, Imbalzano G, et al. Neurological comorbidity and severity of COVID-19. *J Neurol* 2021;268:762–769.
82. Kittai AS, Huang Y, Gordon M, et al. Comorbidities predict inferior survival in patients receiving chimeric antigen receptor T cell therapy for diffuse large B cell lymphoma: a multicenter analysis. *Biol Blood Marrow Transplant* 2021;27:46–52.
83. Del Valle DM, Kim-Schulze S, Huang HH, et al. An inflammatory cytokine signature predicts COVID-19 severity and survival. *Nat Med* 2020;26:1636–1643.
84. Gratton SM, Powell TR, Theeler BJ, et al. Neurological involvement and characterization in acquired

- hemophagocytic lymphohistiocytosis in adulthood. *J Neurol Sci* 2015;357:136–142.
85. Deiva K, Mahlaoui N, Beaudonnet F, et al. CNS involvement at the onset of primary hemophagocytic lymphohistiocytosis. *Neurology* 2012;78:1150–1156.
 86. Cai G, Wang Y, Liu X, et al. Central nervous system involvement in adults with haemophagocytic lymphohistiocytosis: a single-center study. *Ann Hematol* 2017;96:1279–1285.
 87. Song Y, Pei RJ, Wang YN, et al. Central nervous system involvement in hemophagocytic lymphohistiocytosis in adults: a retrospective analysis of 96 patients in a single center. *Chin Med J (Engl)* 2018;131:776–783.
 88. Horne A, Wickstrom R, Jordan MB, et al. How to treat involvement of the central nervous system in hemophagocytic lymphohistiocytosis? *Curr Treat Options Neurol* 2017;19:3.
 89. Yuan J, Yang S, Wang S, et al. Mild encephalitis/encephalopathy with reversible splenic lesion (MERS) in adults—a case report and literature review. *BMC Neurol* 2017;17:103.
 90. Zhu Y, Zheng J, Zhang L, et al. Reversible splenic lesion syndrome associated with encephalitis/encephalopathy presenting with great clinical heterogeneity. *BMC Neurol* 2016;16:49.
 91. Wu X, Wu W, Pan W, et al. Acute necrotizing encephalopathy: an underrecognized clinicoradiologic disorder. *Mediators Inflamm* 2015;2015:792578.
 92. Lin YY, Lee KY, Ro LS, et al. Clinical and cytokine profile of adult acute necrotizing encephalopathy. *Biomed J* 2019;42:178–186.
 93. Kramer U, Chi CS, Lin KL, et al. Febrile infection-related epilepsy syndrome (FIRES): pathogenesis, treatment, and outcome: a multicenter study on 77 children. *Epilepsia* 2011;52:1956–1965.
 94. Hirsch LJ, Gaspard N, van Baalen A, et al. Proposed consensus definitions for new-onset refractory status epilepticus (NORSE), febrile infection-related epilepsy syndrome (FIRES), and related conditions. *Epilepsia* 2018;59:739–744.
 95. Nakano Y, Yukifumi M, Mizuguchi M, et al. Acute encephalopathy with callosal, subcortical and thalamic lesions. *Neurology Asia* 2015;20:85–89.
 96. Nozaki F, Kumada T, Miyajima T, et al. Reversible splenic lesion in a patient with Febrile Infection-Related Epilepsy Syndrome (FIRES). *Neuropediatrics* 2013;44:291–294.
 97. Radmanesh F, Rodriguez-Pla A, Pincus MD, Burns JD. Severe cerebral involvement in adult-onset hemophagocytic lymphohistiocytosis. *J Clin Neurosci* 2020;76:236–237.
 98. Akiyoshi K, Hamada Y, Yamada H, et al. Acute necrotizing encephalopathy associated with hemophagocytic syndrome. *Pediatr Neurol* 2006;34:315–318.
 99. Dai D, Wen F, Liu S, Zhou S. Brain damage resembling acute necrotizing encephalopathy as a specific manifestation of haemophagocytic lymphohistiocytosis - induced by hypersensitivity. *Ital J Pediatr* 2016;42:79.
 100. Virhammar J, Kumlien E, Fallmar D, et al. Acute necrotizing encephalopathy with SARS-CoV-2 RNA confirmed in cerebrospinal fluid. *Neurology* 2020;95:445–449.
 101. Delamarre L, Gollion C, Grouteau G, et al. COVID-19-associated acute necrotising encephalopathy successfully treated with steroids and polyvalent immunoglobulin with unusual IgG targeting the cerebral fibre network. *J Neurol Neurosurg Psychiatry* 2020;91:1004–1006.
 102. van Baalen A, Hausler M, Boor R, et al. Febrile infection-related epilepsy syndrome (FIRES): a nonencephalitic encephalopathy in childhood. *Epilepsia* 2010;51:1323–1328.
 103. Yanagida A, Kanazawa N, Kaneko J, et al. Clinically based score predicting cryptogenic NORSE at the early stage of status epilepticus. *Neurol Neuroimmunol Neuroinflamm* 2020;7:e849.
 104. Meletti S, Slonkova J, Mareckova I, et al. Claustrum damage and refractory status epilepticus following febrile illness. *Neurology* 2015;85:1224–1232.
 105. Neilson DE, Adams MD, Orr CM, et al. Infection-triggered familial or recurrent cases of acute necrotizing encephalopathy caused by mutations in a component of the nuclear pore, RANBP2. *Am J Hum Genet* 2009;84:44–51.
 106. Ayatollahi P, Tarazi A, Wennberg R. Possible autoimmune encephalitis with claustrum sign in case of acute SARS-CoV-2 infection. *Can J Neurol Sci* 2020;1–3. <https://doi.org/10.1017/cjn.2020.209>
 107. Zuhorn F, Omainen H, Ruprecht B, et al. Parainfectious encephalitis in COVID-19: “The Claustrum Sign”. *J Neurol* 2020;1–4. <https://doi.org/10.1007/s00415-020-10185-y>
 108. Farias-Moeller R, LaFrance-Corey R, Bartolini L, et al. Fueling the FIRES: hemophagocytic lymphohistiocytosis in febrile infection-related epilepsy syndrome. *Epilepsia* 2018;59:1753–1763.
 109. Sakuma H, Tanuma N, Kuki I, et al. Intrathecal overproduction of proinflammatory cytokines and chemokines in febrile infection-related refractory status epilepticus. *J Neurol Neurosurg Psychiatry* 2015;86:820–822.
 110. Kenney-Jung DL, Vezzani A, Kahoud RJ, et al. Febrile infection-related epilepsy syndrome treated with anakinra. *Ann Neurol* 2016;80:939–945.
 111. Ito Y, Ichiyama T, Kimura H, et al. Detection of influenza virus RNA by reverse transcription-PCR and

- proinflammatory cytokines in influenza-virus-associated encephalopathy. *J Med Virol* 1999;58:420–425.
112. Miyata R, Tanuma N, Hayashi M, et al. Oxidative stress in patients with clinically mild encephalitis/encephalopathy with a reversible splenic lesion (MERS). *Brain Dev* 2012;34:124–127.
 113. Yamanouchi H, Mizuguchi M. Acute infantile encephalopathy predominantly affecting the frontal lobes (AIEF): a novel clinical category and its tentative diagnostic criteria. *Epilepsy Res* 2006;70(Suppl 1):S263–S268.
 114. Krishnan P, Glenn OA, Samuel MC, et al. Acute fulminant cerebral edema: a newly recognized phenotype in children with suspected encephalitis. *J Pediatric Infect Dis Soc* 2020;pii:063. <https://doi.org/10.1093/jpids/piaa063>
 115. Takanashi J, Oba H, Barkovich AJ, et al. Diffusion MRI abnormalities after prolonged febrile seizures with encephalopathy. *Neurology* 2006;66:1304–1309; discussion 291.
 116. Levin M, Hjelm M, Kay JD, et al. Haemorrhagic shock and encephalopathy: a new syndrome with a high mortality in young children. *Lancet* 1983;2:64–67.
 117. Salih MA, Kabiraj M, Al-Jarallah AS, et al. Hemiconvulsion-hemiplegia-epilepsy syndrome. A clinical, electroencephalographic and neuroradiological study. *Childs Nerv Syst* 1997;13:257–263.
 118. Mizuguchi M, Yamanouchi H, Ichiyama T, Shiomi M. Acute encephalopathy associated with influenza and other viral infections. *Acta Neurol Scand* 2007;115:45–56.
 119. Singer M, Deutschman CS, Seymour CW, et al. The third international consensus definitions for sepsis and septic shock (Sepsis-3). *JAMA* 2016;315:801–810.
 120. Gofton TE, Young GB. Sepsis-associated encephalopathy. *Nat Rev Neurol* 2012;8:557–566.
 121. Young GB, Bolton CF, Archibald YM, et al. The electroencephalogram in sepsis-associated encephalopathy. *J Clin Neurophysiol* 1992;9:145–152.
 122. Sharshar T, Carlier R, Bernard F, et al. Brain lesions in septic shock: a magnetic resonance imaging study. *Intensive Care Med* 2007;33:798–806.
 123. Robba C, Crippa IA, Taccone FS. Septic encephalopathy. *Curr Neurol Neurosci Rep* 2018;18:82.
 124. Jacob A, Brorson JR, Alexander JJ. Septic encephalopathy: inflammation in man and mouse. *Neurochem Int* 2011;58:472–476.
 125. Wu L, Feng Q, Ai ML, et al. The dynamic change of serum S100B levels from day 1 to day 3 is more associated with sepsis-associated encephalopathy. *Sci Rep* 2020;10:7718.
 126. Chousterman BG, Swirski FK, Weber GF. Cytokine storm and sepsis disease pathogenesis. *Semin Immunopathol* 2017;39:517–528.
 127. Becher B, Spath S, Goverman J. Cytokine networks in neuroinflammation. *Nat Rev Immunol* 2017;17:49–59.
 128. Calsolaro V, Edison P. Neuroinflammation in Alzheimer's disease: current evidence and future directions. *Alzheimers Dement* 2016;12:719–732.
 129. Magliozzi R, Howell OW, Nicholas R, et al. Inflammatory intrathecal profiles and cortical damage in multiple sclerosis. *Ann Neurol* 2018;83:739–755.
 130. Fortuna D, Hooper DC, Roberts AL, et al. Potential role of CSF cytokine profiles in discriminating infectious from non-infectious CNS disorders. *PLoS One* 2018;13:e0205501.
 131. Leisman DE, Ronner L, Pinotti R, et al. Cytokine elevation in severe and critical COVID-19: a rapid systematic review, meta-analysis, and comparison with other inflammatory syndromes. *Lancet Respir Med* 2020;8:1233–1244.