

Access this article online

Quick Response Code:



Website:
www.e-tjo.org

DOI:
10.4103/tjo.tjo_102_18

Current concepts and techniques of vitrectomy for retinopathy of prematurity

Shunji Kusaka

Abstract:

Retinopathy of prematurity (ROP) is a leading cause of childhood blindness worldwide. ROP screening and interventions (e.g., laser ablation and anti-vascular endothelial growth factor [VEGF] therapy) at the right time can reduce disease activity and prevent retinal detachment. However, sometimes, ROP is refractory to treatment, leading to tractional retinal detachment (TRD), requiring surgical intervention, such as vitrectomy. Vitrectomy for Stage 5 ROP (total retinal detachment) is beneficial in preventing total blindness in some patients. However, it has poor anatomical and functional results. Vitrectomy (lens-sparing vitrectomy, if possible) should be performed at Stage 4A ROP (partial TRD not involving the macula) because the anatomical and functional results are much better.

Keywords:

Antivascular endothelial growth factor therapy, lensectomy, lens-sparing vitrectomy, retinal detachment, retinopathy of prematurity, vitrectomy

Introduction

More than 70 years have passed since the first description of retinopathy of prematurity (ROP);^[1] however, it is still a leading cause of childhood blindness, both in industrialized and in developing countries.^[2] Every year, around 50,000 children are estimated to go blind because of ROP.^[3] However, ROP is a preventable disease, unlike other major causes of childhood blindness that are related to untreatable, congenital anomalies, or hereditary diseases such as microphthalmus, retinitis pigmentosa, and optic nerve atrophy. According to the Early Treatment for ROP Cooperative Group,^[4] retinal laser ablation at prethreshold retinopathy, rather than at threshold retinopathy, decreases the rate of unfavorable functional and structural outcomes from 19.5% to 14.5% and from 15.6% to 9.1%, respectively. However, nearly 10% of patients still suffer from severe

vision loss due to the development of retinal folds, retinal detachment, or retrolental fibroplasia.^[4]

Recently, anti-vascular endothelial growth factor (VEGF) therapy was introduced as an off-label treatment for severe ROP^[5-8] since VEGF is known to play a major role in ROP pathogenesis.^[9-11] Anti-VEGF therapy is effective in reducing disease activity and is likely to lead to better ROP treatment outcomes, especially in severe ROP cases, such as zone 1 plus ROP^[8] or aggressive posterior ROP (AP-ROP). However, anti-VEGF therapy has a couple of problems. First, as of 2018, since anti-VEGF therapy for ROP is an off-label treatment, it requires the approval of an institutional review board. Second, there are systemic safety concerns because anti-VEGF therapy suppresses systemic VEGF levels.^[12,13]

With anti-VEGF therapy, the number of patients who develop tractional retinal detachment (TRD) seems to be decreasing. However, some patients still require

This is an open access journal, and articles are distributed under the terms of the Creative Commons Attribution-NonCommercial-ShareAlike 4.0 License, which allows others to remix, tweak, and build upon the work non-commercially, as long as appropriate credit is given and the new creations are licensed under the identical terms.

For reprints contact: reprints@medknow.com

How to cite this article: Kusaka S. Current concepts and techniques of vitrectomy for retinopathy of prematurity. Taiwan J Ophthalmol 2018;8:216-21.

Department of
Ophthalmology, Kindai
University Faculty of
Medicine, Osaka, Japan

**Address for
correspondence:**

Prof. Shunji Kusaka,
Department of
Ophthalmology, Kindai
University Faculty of
Medicine,
377-2, Ohnohigashi,
Osakasayama,
589-8511 Osaka, Japan.
E-mail: kusaka-ns@umin.
net

Submission: 21-08-2018
Accepted: 17-10-2018

vitrectomy for TRD. The reasons include improper screening or treatment. Sometimes, in spite of proper treatment, the patients' condition progresses to TRD due to excessive prematurity. Therefore, surgical treatment for ROP is still necessary especially in developing countries. This study focused on the current concepts and techniques of vitrectomy for ROP.

Vitrectomy for Stage 4 Retinopathy of Prematurity

Ideally, vitrectomy for ROP should be performed at Stage 4A ROP, that is, focal TRD not involving the macula [Figures 1 and 2]. The reason is the anatomical and functional results of surgery worsen with the progression of the ROP stage.^[14-23] However, sometimes, even after laser ablation therapy for Stage 4A ROP, vascular activity in the eyes is still high. Performing vitrectomy on such eyes could lead to postoperative severe inflammation and postoperative vitreous hemorrhage. Therefore, if laser ablation has already been performed, anti-VEGF therapy should be considered to reduce vascular activity.^[6] However, in eyes with extensive fibrovascular membranes (FVMs), anti-VEGF therapy may worsen TRD by contraction of FVMs. Therefore, in such eyes, vitrectomy should be performed within a few days after anti-VEGF therapy before contraction of FVMs occurs. In eyes with AP-ROP, in which TRD is highly likely in spite of laser ablation and/or anti-VEGF therapy, studies have recommended a more aggressive approach, that is, early vitrectomy even before TRD development and have reported good surgical results.^[24,25]

Surgical technique

As originally described by Maguire and Trese,^[14] if the FVMs are located posterior to the equator in

eyes with Stage 4 ROP, lens-sparing vitrectomy can be performed. The authors used 20G instruments to perform two-port vitrectomy. This technique appears to prevent lens damage by the infusion port. However, 20G instruments, such as infusion light pipes and infusion spatulas, are not widely used today. Nowadays, many surgeons prefer a standard three-port, small-gauge system, such as 23G,^[6,16] 25G,^[15] and 27G instruments.

The anatomical features of eyes with ROP include a short pars plana^[26] and a relatively large lens size compared to adult eyes; therefore, extra caution should be exercised. After conjunctival peritomy, sclerotomy is performed 0.5–1 mm from the limbus. To avoid lens damage, the direction of sclerotomy should be more posterior rather than toward the center of the eyeball.^[16] Then, an infusion cannula (Kusaka infusion cannula 23G, (M. E. Technica, Japan), or a conventional disposable cannula (Disposable one step vitrectomy system (25G or 27G, DORC, Holland) is inserted, followed by insertion of the disposable cannulas, either by a one-step technique (sclerotomy by trocars) or by a two-step technique (sclerotomy by an MVR-Angled 23G, [MANI, Japan]), followed by trocars. Since the sclera of infants is thin and soft, self-sealing is difficult, even when using a small-gauge system. Therefore, personally, I prefer the two-step technique and closing every would using 10-0 Vicryl suture (Ethicon, USA).

For fundus view, a wide-angle viewing system, such as Resight® (Zeiss, Germany) or BIOM® (Oculus, Germany), is commonly used. Some surgeons use floating lenses with smaller diameters (HHV lens for small cornea, HOYA Japan) than the conventional lenses used for adult surgery.

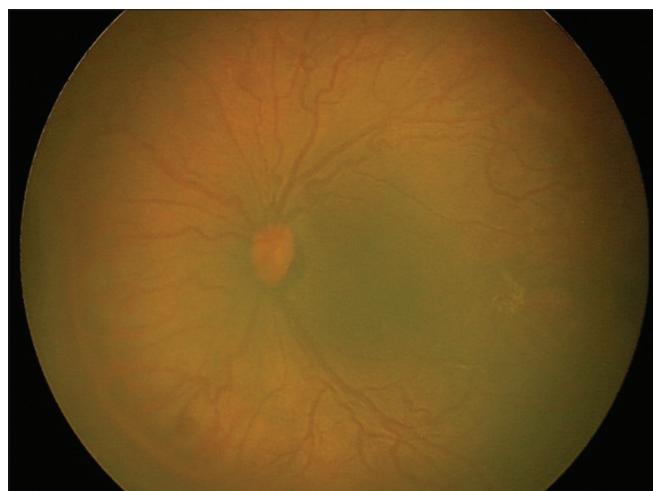


Figure 1: Stage 4A retinopathy of prematurity with high vascular activity after confluent laser ablation of the peripheral avascular retina the patient was born with. An anti-vascular endothelial growth factor agent (ranibizumab) was injected intravitreally

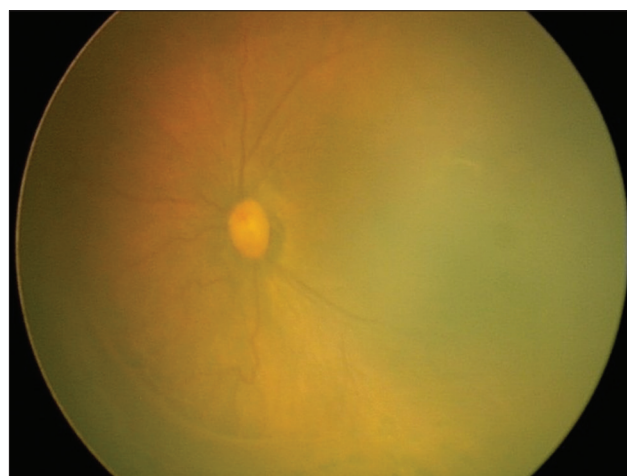


Figure 2: Two days after intravitreal injection of ranibizumab, an anti-vascular endothelial growth factor agent. Vascular tortuosity, dilatation, and injection of fibrovascular membranes are improved. Lens-sparing vitrectomy was performed

In eyes with Stage 4A ROP, fibrous tissue traction develops in various directions: between the lens and FVMs, between the peripheral retina and FVMs, between the posterior retina and FVMs, and in between FVMs (loop traction). If this traction is released by vitrectomy, the retina is gradually reattached postoperatively [Figure 3]. To achieve retinal reattachment, there is no need to remove the FVMs, unless the loop traction by FVMs is extensive and retinal reattachment is not expected. Therefore, the use of horizontal and/or vertical scissors should be minimized to avoid iatrogenic retinal hole formation and/or intraoperative bleeding.

If FVMs are anterior to the equator and/or the distance between the lens and FVMs is too little to dissect without removing the lens, lensectomy should be performed. If all the procedure is completed without creation of an iatrogenic retinal break, no air, gas, or silicone oil tamponade is necessary. If an iatrogenic retinal hole is formed, FVMs around the retinal break should be meticulously dissected to remove all traction. However, if the removal is incomplete, scleral buckling may be a good option. Next, fluid/air exchange and laser photocoagulation should be conducted. Either long-acting gas or silicone oil should be injected at the end of the procedure.

Another effective surgical technique for treating Stage 4 ROP is scleral buckling.^[27-29] Scleral buckling is effective in reducing vascular activity.^[29] However, vitrectomy can release traction to the FVMs more directly, with reasonable safety due to advances in modern instrumentation. In addition, better surgical results have been reported by vitrectomy than scleral buckling.^[28]

Surgical results

Comparatively, anatomical and functional results of vitrectomy for Stage 4 ROP are better than those

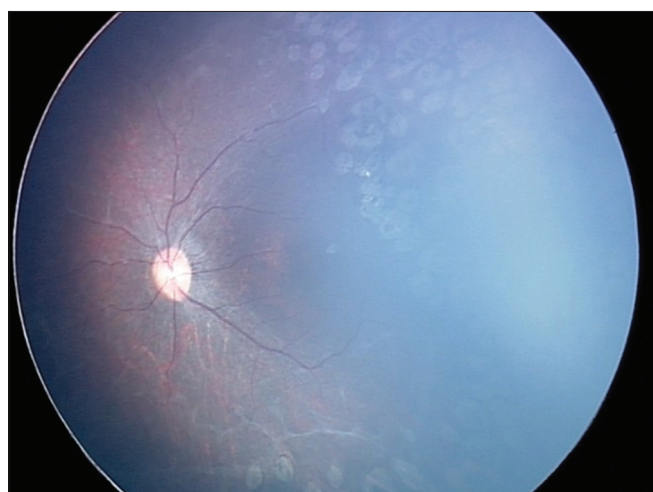


Figure 3: One year after lens-sparing vitrectomy for Stage 4A retinopathy of prematurity, the retina appears completely reattached

for Stage 5 ROP. According to the previous studies, the anatomical success rate of vitrectomy for Stage 4A and Stage 4B ROP ranges from 84% to 100% and 73% to 92%, respectively.^[16-21] In addition, the mean postoperative visual acuity in Stage 4A and Stage 4B ROP ranges from 20/550 to 20/58 and from 20/1600 to 20/200, respectively.^[21-23]

Vitrectomy for Stage 5 Retinopathy of Prematurity

The number of patients with Stage 5 ROP seems to be decreasing in developed countries because of improvements in neonatal care, the widespread use of appropriate screening, laser treatment, and the introduction of anti-VEGF therapy. However, in many developing countries, a large number of patients progress to Stage 5 ROP [Figure 4]. If eyes with stage 5 ROP are left untreated, there is no hope of maintaining any visual function. Vitrectomy for Stage 5 ROP is challenging, and its anatomical and functional results are poor. However, visual function of light perception is much better than no light perception at all, at least regarding maintaining the circadian rhythm.^[30]

Surgical technique

In most eyes with Stage 5 ROP, the FVMs are located close to the lens, and in such cases, lensectomy is necessary. Caution should be exercised regarding where to make surgical wounds. If the FVMs exist adjacent to the ciliary body, surgical incisions should be made at the limbus to avoid an iatrogenic retinal hole formation or ora dialysis. As an infusion cannula (Kusaka infusion cannula 23G, [M. E. Technica, Japan]) or anterior chamber maintainer (AC Maintainer, Inami, Japan) can be used. If there is some space between the ciliary body and FVMs, sclerotomy may be performed 0.5–1 mm from the limbus, allowing for better visibility and easier manipulation during vitrectomy. A mixture of limbal and pars plicata

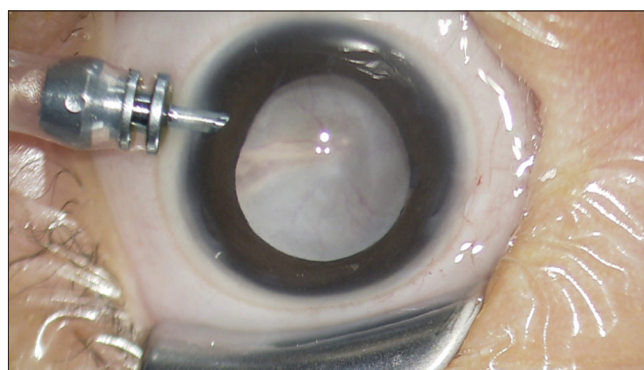


Figure 4: Anterior segment view of Stage 5 retinopathy of prematurity at the beginning of vitrectomy. Retrolental fibroplasia, a white membrane, and total retinal detachment are observed

incisions can be used, depending on the space between the ciliary body and FVMs where the incisions are to be made. Using vitrectomy probe, lensectomy should be performed thoroughly, that is, including the entire lens capsule, otherwise postsurgery, lens capsule remnants are likely to adhere to the iris and/or the remaining retrolental membrane. The FVMs are dissected usually by forceps (23G or 25G Shah Micro Serrated Jaws, DORC, Holland) and scissors (23G or 25G Vertical or Curved Horizontal, DORC, Holland), or a spatula (23G Extendible Curbed Spatula, DORC, Holland) using the bimanual technique [Figure 5]. The dissection can start in the center of the FVMs and extend peripherally in a concentric and/or circumferential manner. The FVMs should be removed as much as possible to increase the chances of retinal reattachment. However, iatrogenic retinal hole formation is associated with surgical failure; therefore, special care should be taken to avoid the complete removal of the FVMs, especially in the peripheral region, where it is sometimes difficult to distinguish between the thin FVM and the avascular retina. In addition, to avoid ora dialysis, the pulling of the FVMs should be minimized. If most of the FVMs can be removed, the retina gradually reattaches within several weeks [Figure 6]. Otherwise, another surgery to remove the residual FVMs should be considered.

Surgical results

As mentioned earlier, the surgical results of vitrectomy for Stage 5 ROP are generally poor. The Cryotherapy for Retinopathy Cooperative Group (CRYO-ROP)^[31] reported that after vitrectomy for Stage 5 ROP at 5.5 years of age, at least one portion of the retina reattached in 11 of 52 eyes (21%), and visual acuity was limited to light perception or no light perception in all but one eye. Cusick *et al.*^[32] reported in their study on 601 infants that partial retinal reattachment was achieved in 315 of 956 eyes (33%), with a visual acuity of better than 5/200 in 8 of 183 eyes. In our study on eyes with Stage 5 ROP evaluated 6 months postoperatively, 20 eyes (42.6%) and 5 eyes (10.6%) had total and partial

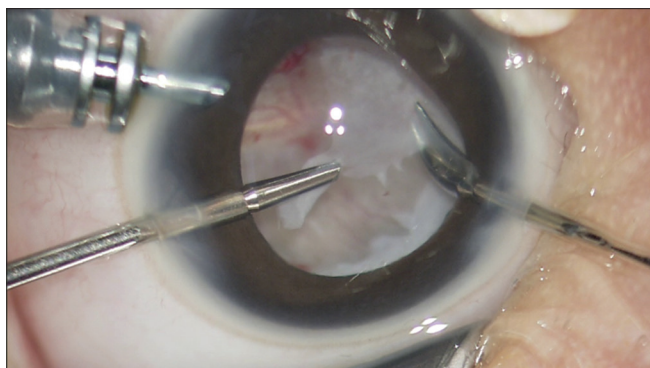


Figure 5: Intraoperative view of vitrectomy for Stage 5 retinopathy of prematurity. After lensectomy, membrane peeling and delamination are performed

reattachment of the retina, respectively (unpublished data). Similar results have been reported earlier, with a retinal reattachment rate of ~40%–60%^[32-37] and limited functional outcomes.^[32-40] The closed shape of the retinal detachment funnel, the presence of subretinal hemorrhage and vascularized membranes, and the age at vitrectomy appear to be associated with bad surgical outcomes.^[32,33,37]

Surgical Complications of Retinopathy of Prematurity Surgery

Intraoperative complications associated with ROP surgery include iatrogenic retinal break(s), intraoperative vitreous hemorrhage, and lens damage. Creation of iatrogenic retinal break(s) should be avoided, especially for Stage 5 ROP, because complete release of traction to the detached retina is extremely difficult. Postoperative complications include vitreous hemorrhage, proliferative vitreoretinopathy associated with retinal break(s) created intra- or post-operatively, cataract formation, and glaucoma.

Qualifications of Surgeons for Retinopathy of Prematurity

As described here, the approach for ROP surgery is different from that for adult retinal detachment surgery. The surgical techniques for pediatric retinal detachment, especially ROP, are much more challenging than those for adult retinal detachment surgery, and the surgical results are unforgiving. Therefore, surgeons who try to pursue this treatment should learn the pathology of ROP detachment and have sufficient skills and experience of adult, complex retinal detachment surgery.

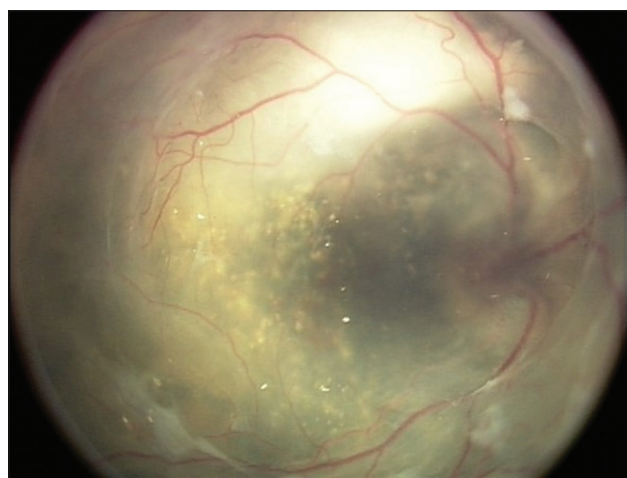

Figure 6: Stage 5 retinopathy of prematurity (right eye). Six days postoperatively, the retina is still detached; however, subretinal fluid is already reduced remarkably. The retina will be reattached within few weeks

Conclusions

Proper care of premature infants by neonatologists, screening at the proper time, and intervention using laser ablation or anti-VEGF therapy is key in ROP management. Surgical intervention, mainly vitrectomy, is necessary to prevent blindness in Stage 4–5 ROP patients. Vitrectomy (lens-sparing vitrectomy, if possible) should be performed at Stage 4A ROP, that is, before the macula is affected, to achieve good anatomical and functional results.

Declaration of patient consent

The authors certify that they have obtained all appropriate patient consent forms. In the form the patient(s) has/have given his/her/their consent for his/her/their images and other clinical information to be reported in the journal. The patients understand that their names and initials will not be published and due efforts will be made to conceal their identity, but anonymity cannot be guaranteed.

Financial support and sponsorship

Nil.

Conflicts of interest

The authors declare that there are no conflicts of interests of this paper.

References

1. Terry TL. Fibroblastic overgrowth of persistent tunica vasculosa lentis in infants born prematurely: II. Report of cases-clinical aspects. *Trans Am Ophthalmol Soc* 1942;40:262-84.
2. Steinkuller PG, Du L, Gilbert C, Foster A, Collins ML, Coats DK, *et al.* Childhood blindness. *J AAPOS* 1999;3:26-32.
3. Gilbert C. Retinopathy of prematurity: A global perspective of the epidemics, population of babies at risk and implications for control. *Early Hum Dev* 2008;84:77-82.
4. Early Treatment for Retinopathy Of Prematurity Cooperative Group. Revised indications for the treatment of retinopathy of prematurity: Results of the early treatment for retinopathy of prematurity randomized trial. *Arch Ophthalmol* 2003;121:1684-94.
5. Quiroz-Mercado H, Martinez-Castellanos MA, Hernandez-Rojas ML, Salazar-Teran N, Chan RV. Antiangiogenic therapy with intravitreal bevacizumab for retinopathy of prematurity. *Retina* 2008;28:S19-25.
6. Kusaka S, Shima C, Wada K, Arahori H, Shimojyo H, Sato T, *et al.* Efficacy of intravitreal injection of bevacizumab for severe retinopathy of prematurity: A pilot study. *Br J Ophthalmol* 2008;92:1450-5.
7. Wu WC, Yeh PT, Chen SN, Yang CM, Lai CC, Kuo HK, *et al.* Effects and complications of bevacizumab use in patients with retinopathy of prematurity: A multicenter study in Taiwan. *Ophthalmology* 2011;118:176-83.
8. Mintz-Hittner HA, Kennedy KA, Chuang AZ, BEAT-ROP Cooperative Group. Efficacy of intravitreal bevacizumab for stage 3+ retinopathy of prematurity. *N Engl J Med* 2011;364:603-15.
9. Sonmez K, Drenser KA, Capone A Jr., Trese MT. Vitreous levels of stromal cell-derived factor 1 and vascular endothelial growth factor in patients with retinopathy of prematurity. *Ophthalmology* 2008;115:1065-700.
10. Sato T, Kusaka S, Shimojo H, Fujikado T. Vitreous levels of erythropoietin and vascular endothelial growth factor in eyes with retinopathy of prematurity. *Ophthalmology* 2009;116:1599-603.
11. Sato T, Kusaka S, Hashida N, Saishin Y, Fujikado T, Tano Y, *et al.* Comprehensive gene-expression profile in murine oxygen-induced retinopathy. *Br J Ophthalmol* 2009;93:96-103.
12. Sato T, Wada K, Arahori H, Kuno N, Imoto K, Iwahashi-Shima C, *et al.* Serum concentrations of bevacizumab (avastin) and vascular endothelial growth factor in infants with retinopathy of prematurity. *Am J Ophthalmol* 2012;153:327-330.
13. Wu WC, Lien R, Liao PJ, Wang NK, Chen YP, Chao AN, *et al.* Serum levels of vascular endothelial growth factor and related factors after intravitreal bevacizumab injection for retinopathy of prematurity. *JAMA Ophthalmol* 2015;133:391-7.
14. Maguire AM, Trese MT. Lens-sparing vitreoretinal surgery in infants. *Arch Ophthalmol* 1992;110:284-6.
15. Gonzales CR, Boshra J, Schwartz SD. 25-gauge pars plicata vitrectomy for stage 4 and 5 retinopathy of prematurity. *Retina* 2006;26:S42-6.
16. Wu WC, Lai CC, Lin RI, Wang NK, Chao AN, Chen KJ, *et al.* Modified 23-gauge vitrectomy system for stage 4 retinopathy of prematurity. *Arch Ophthalmol* 2011;129:1326-31.
17. Capone A Jr., Trese MT. Lens-sparing vitreous surgery for tractional stage 4A retinopathy of prematurity retinal detachments. *Ophthalmology* 2001;108:2068-70.
18. Hubbard GB 3rd, Cherwick DH, Burian G. Lens-sparing vitrectomy for stage 4 retinopathy of prematurity. *Ophthalmology* 2004;111:2274-7.
19. Moshfeghi AA, Banach MJ, Salam GA, Ferrone PJ. Lens-sparing vitrectomy for progressive tractional retinal detachments associated with stage 4A retinopathy of prematurity. *Arch Ophthalmol* 2004;122:1816-8.
20. Lakhnpal RR, Sun RL, Albini TA, Holz ER. Anatomic success rate after 3-port lens-sparing vitrectomy in stage 4A or 4B retinopathy of prematurity. *Ophthalmology* 2005;112:1569-73.
21. Karacorlu M, Hocaoglu M, Sayman Muslubas I, Arf S. Long-term functional results following vitrectomy for advanced retinopathy of prematurity. *Br J Ophthalmol* 2017;101:730-4.
22. Prenner JL, Capone A Jr., Trese MT. Visual outcomes after lens-sparing vitrectomy for stage 4A retinopathy of prematurity. *Ophthalmology* 2004;111:2271-3.
23. Lakhnpal RR, Sun RL, Albini TA, Coffee R, Coats DK, Holz ER, *et al.* Visual outcomes after 3-port lens-sparing vitrectomy in stage 4 retinopathy of prematurity. *Arch Ophthalmol* 2006;124:675-9.
24. Azuma N, Ishikawa K, Hama Y, Hiraoka M, Suzuki Y, Nishina S, *et al.* Early vitreous surgery for aggressive posterior retinopathy of prematurity. *Am J Ophthalmol* 2006;142:636-43.
25. Azuma N, Ito M, Yokoi T, Nakayama Y, Nishina S. Visual outcomes after early vitreous surgery for aggressive posterior retinopathy of prematurity. *JAMA Ophthalmol* 2013;131:1309-13.
26. Hairston RJ, Maguire AM, Vitale S, Green WR. Morphometric analysis of pars plana development in humans. *Retina* 1997;17:135-8.
27. Noorily SW, Small K, de Juan E Jr., Machermer R. Scleral buckling surgery for stage 4B retinopathy of prematurity. *Ophthalmology* 1992;99:263-8.
28. Hartnett ME, Maguluri S, Thompson HW, McColm JR. Comparison of retinal outcomes after scleral buckle or lens-sparing vitrectomy for stage 4 retinopathy of prematurity. *Retina* 2004;24:753-7.
29. Yokoi T, Yokoi T, Kobayashi Y, Hiraoka M, Nishina S, Azuma N, *et al.* Evaluation of scleral buckling for stage 4A retinopathy of prematurity by fluorescein angiography. *Am J Ophthalmol* 2009;148:544-500.
30. Hartley S, Dauvilliers Y, Quera-Salva MA. Circadian rhythm

- disturbances in the blind. *Curr Neurol Neurosci Rep* 2018;18:65.
31. Quinn GE, Dobson V, Barr CC, Davis BR, Palmer EA, Robertson J, *et al*. Visual acuity of eyes after vitrectomy for retinopathy of prematurity: Follow-up at 5 1/2 years. The Cryotherapy for Retinopathy of Prematurity Cooperative Group. *Ophthalmology* 1996;103:595-600.
 32. Cusick M, Charles MK, Agrón E, Sangiovanni JP, Ferris FL 3rd, Charles S, *et al*. Anatomical and visual results of vitreoretinal surgery for stage 5 retinopathy of prematurity. *Retina* 2006;26:729-35.
 33. Hirose T, Katsumi O, Mehta MC, Schepens CL. Vision in stage 5 retinopathy of prematurity after retinal reattachment by open-sky vitrectomy. *Arch Ophthalmol* 1993;111:345-9.
 34. Fuchino Y, Hayashi H, Kono T, Ohshima K. Long-term follow up of visual acuity in eyes with stage 5 retinopathy of prematurity after closed vitrectomy. *Am J Ophthalmol* 1995;120:308-16.
 35. Trese MT, Droste PJ. Long-term postoperative results of a consecutive series of stages 4 and 5 retinopathy of prematurity. *Ophthalmology* 1998;105:992-7.
 36. Kono T, Oshima K, Fuchino Y. Surgical results and visual outcomes of vitreous surgery for advanced stages of retinopathy of prematurity. *Jpn J Ophthalmol* 2000;44:661-7.
 37. Jabbour NM, Eller AE, Hirose T, Schepens CL, Liberfarb R. Stage 5 retinopathy of prematurity. Prognostic value of morphologic findings. *Ophthalmology* 1987;94:1640-6.
 38. Mintz-Hittner HA, O'Malley RE, Kretzer FL. Long-term form identification vision after early, closed, lensectomy-vitrectomy for stage 5 retinopathy of prematurity. *Ophthalmology* 1997;104:454-9.
 39. Hartnett ME, Rodier DW, McColm JR, Thompson HW. Long-term vision results measured with teller acuity cards and a new light perception/Projection scale after management of late stages of retinopathy of prematurity. *Arch Ophthalmol* 2003;121:991-6.
 40. Seaber JH, Machemer R, Elliott D, Buckley EG, deJuan E, Martin DF, *et al*. Long-term visual results of children after initially successful vitrectomy for stage V retinopathy of prematurity. *Ophthalmology* 1995;102:199-204.