

Available online at www.sciencedirect.com

ScienceDirect

journal homepage: www.elsevier.com/locate/radcr

Case Report

Extrahepatic portomesenteric obstruction resulting in splanchnic hypertension and refractory ascites [☆]

Hussam Hindi, DO*, Jeffrey Critchfield, MD

Barbara Ann Karmanos Cancer Institute/Wayne State University, 4100 John R St, Detroit, MI 48201, USA

ARTICLE INFO

Article history:

Received 24 November 2022

Revised 5 December 2022

Accepted 10 December 2022

Keywords:

Portomesenteric obstruction

Splanchnic hypertension

Ascites

ABSTRACT

Portal hypertension is a commonly described etiology that typically stems from underlying cirrhosis. Interventional radiologists may offer several interventions in the multidisciplinary approach to managing these patients. However, it is important to ascertain the cause and type of hypertension before intervention to avoid poor outcomes. We describe a case of an 89-year-old male with pancreatic adenocarcinoma and isolated superior mesenteric venous hypertension secondary to external stent compression at the portomesenteric confluence. This resulted in refractory ascites which was significantly relieved after portal to superior mesenteric vein stent placement.

© 2022 The Authors. Published by Elsevier Inc. on behalf of University of Washington.

This is an open access article under the CC BY-NC-ND license

(<http://creativecommons.org/licenses/by-nc-nd/4.0/>)

Introduction

Portal hypertension is a complex disease process that causes significant patient morbidity and mortality. Typically, variceal bleeding and refractory ascites due to cirrhosis can be treated by interventional radiologists with transjugular intrahepatic portosystemic shunt (TIPS) placement. However, this is not always appropriate management. It is important to distinguish if symptoms are caused by portal hypertension or from isolated splanchnic involvement. Isolated mesenteric venous hypertension is usually secondary to tumor burden, post hepato-pancreato-biliary surgery, or liver transplantation [1]. However, we present an unusual case of superior mesenteric venous hypertension due to external mass-effect compression from 2 adjacent stents.

Case report

An 89-year-old male initially presented with chief complaint of new onset abdominal distention. On computed tomography (CT), he was found to have unresectable, locally invasive pancreatic adenocarcinoma. He subsequently underwent chemotherapy and radiation therapy. After 2 years, he developed obstructive jaundice due to mild progression of his disease. A covered metallic biliary stent was placed, and his hyperbilirubinemia resolved. Recently, he developed duodenal obstruction due to invasive pancreatic adenocarcinoma. A duodenal stent was placed to relieve the obstruction. After stent placement, he acutely developed large volume ascites and needed repeat 4–5 L paracentesis on a weekly basis.

[☆] Competing Interests: The authors declare that they have no known competing financial interests or personal relationships that could have appeared to influence the work reported in this paper.

* Corresponding author.

E-mail address: hussamhindi1@gmail.com (H. Hindi).

<https://doi.org/10.1016/j.radcr.2022.12.031>

1930-0433/© 2022 The Authors. Published by Elsevier Inc. on behalf of University of Washington. This is an open access article under the CC BY-NC-ND license (<http://creativecommons.org/licenses/by-nc-nd/4.0/>)

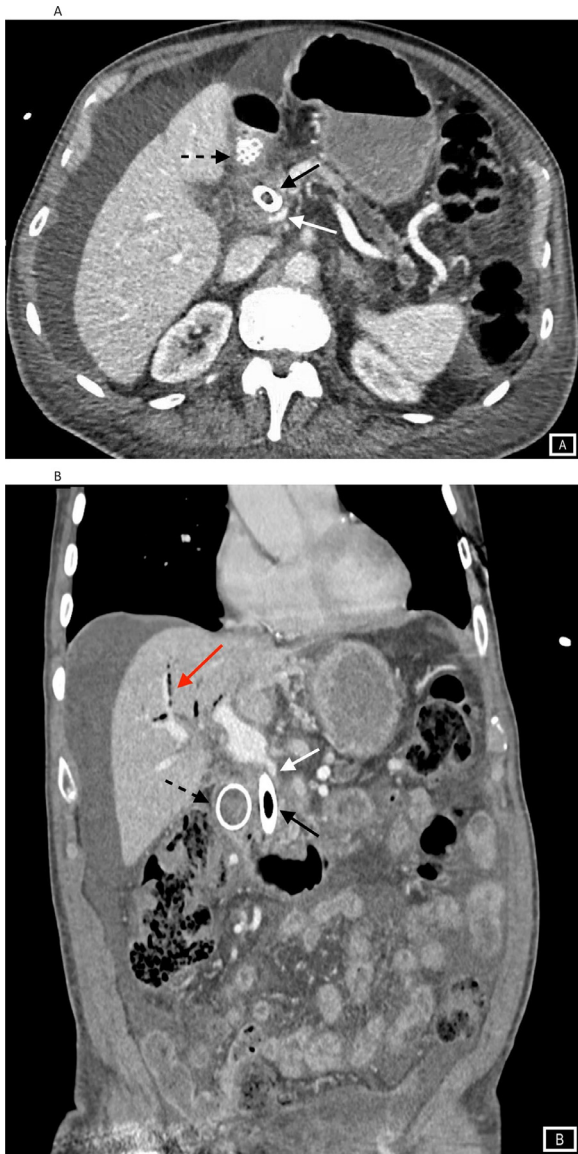


Fig. 1 – (A) Axial and (B) coronal contrast-enhanced images of the abdomen. (A, B) There is complete obstruction at the portomesenteric confluence (white arrow) due to the biliary (black arrow) and duodenal stent (dotted black arrow). (B) There is also pneumobilia secondary to biliary stent placement (red arrow). Both images show a normal liver contour with moderate intra-abdominal ascites.

The patient's vital signs were blood pressure 121/69 mmHg, heart rate 64 beats per minute, and respiratory rate 18. The total bilirubin was 1.20 mg/dL (normal range <1.50), ALT 15 Units/Liter (normal range 7-52), AST 21 Units/Liter (normal range 13-39), and albumin 3.4 g/dL (normal range 3.5-5.7). International normalized ratio was 1.01 (normal range 0.87-1.10), prothrombin time 10.8(s) (normal range 9.4-11.7) and partial thromboplastin time 26.9(s) (normal range 23.1-33.1). CA 19-9 was downtrending from 707.5 to 681 Units/mL (normal range 0.8-35.0).

The review of systems was negative for abdominal pain, melena, hematochezia, nausea, and vomiting. The patient had abdominal distention, but physical exam was otherwise unremarkable.

Contrast-enhanced CT scan demonstrated the known pancreatic adenocarcinoma measuring 3.5 cm in the pancreatic neck, 90-degree abutment of the superior mesenteric vein (SMV) without superior mesenteric or celiac artery involvement, and associated pancreatic duct dilatation. There was normal liver morphology and moderate ascites. The portomesenteric confluence was completely obstructed by external stent compression causing enlarged gastric and small bowel varices (Fig. 1). The decision was made to perform an interventional procedure to open the portal and SMVs to relieve the obstruction.

To start the procedure, an ultrasound-guided peritoneal drainage catheter was placed to monitor ascites. Transhepatic ultrasound-guided access of a segment 6 portal vein branch was obtained using a 21-gauge needle. On initial portal venogram, the paraumbilical vein was not recanalized (Fig. 2). A catheter was advanced to the main right portal vein and the pressure measured 12 cm H₂O. A portal venogram demonstrated sluggish hepatopetal flow. A Glide-wire Advantage (Terumo Interventional Systems, Somerset, NJ) was used to traverse the portal vein obstruction into the SMV, and pressures here measured 34 cm H₂O. The gradient measured 22 cm H₂O. Repeat portal venogram demonstrated complete obstruction at the portomesenteric confluence due to external compression from the common bile duct and duodenal stents with gastric and small bowel varices present (Fig. 2). The patent SMV measured 7 mm in diameter. A 16 mm × 60 mm self-expanding stent was deployed across the occlusion and an 8 mm × 40 mm balloon was used to further expand the stent. The SMV and main portal vein pressures were again obtained measuring 22 cm H₂O and 11 cm H₂O, respectively. The gradient across the lesion decreased from 22 to 11 cm H₂O. There was improved liver inflow, and the varices were no longer opacified (Fig. 2). Upon completion, the transparenchymal tract was occluded using Helitene (Integra LifeSciences Corporation, Plainsboro, NJ) injection under fluoroscopic guidance.

The patient tolerated the procedure well without complication. At 1-week follow-up, 750 mL of yellow ascites was removed by paracentesis. At 2 weeks, the patient had no detectable ascites.

Discussion

The most common cause of portal hypertension is hepatic cirrhosis. The diseased parenchyma increases intrahepatic vascular resistance to hepatopetal flow leading to portal hypertension. Portal hypertension then causes vascular beds in the systemic and splanchnic circulation to create collaterals. Splanchnic vasodilation and effective hypovolemia ultimately increases portal blood circulation and hypertension causing varices and ascites to develop [2]. Common imaging findings of portal hypertension include a dilated main portal vein, hepatofugal flow, splenomegaly, porto-systemic collateral forma-

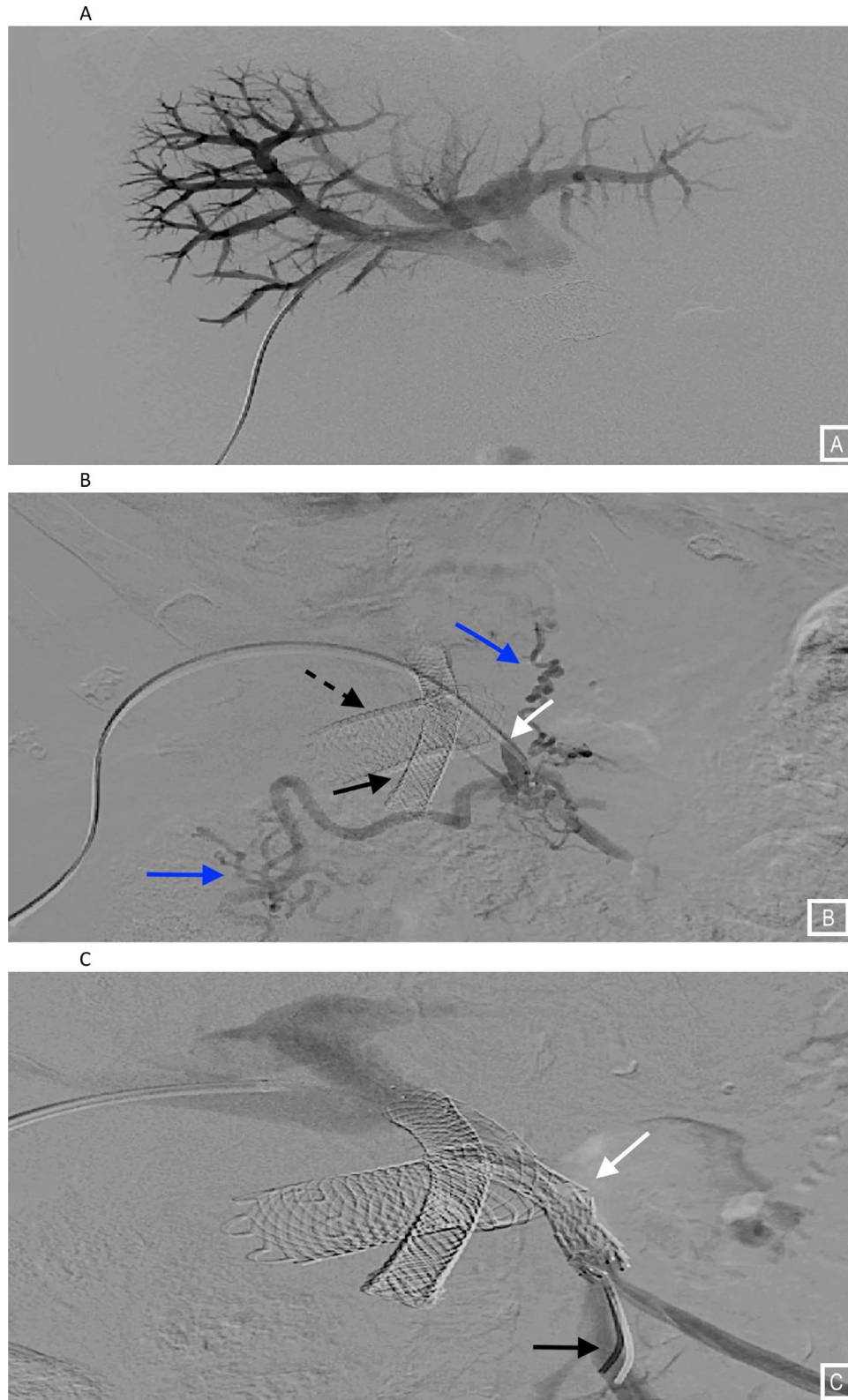


Fig. 2 - (A) Initial portal venogram of a segment 6 branch shows no recanalization of the paraumbilical vein. **(B)** Portal venogram from the superior mesenteric vein shows complete obstruction at the portomesenteric confluence (white arrow) due to biliary (black arrow) and duodenal stent (dotted black arrow) placement. Both gastric and small bowel varices are noted (blue arrows). **(C)** After stent placement (white arrow), repeat portal venogram from the superior mesenteric vein (black arrow) shows improved hepatopedal flow with no opacified varices.

tion, recanalized paraumbilical vein, and ascites. Patients that represent with refractory ascites and variceal bleeding may be candidates for TIPS. However, this was not properly indicated in this circumstance. A TIPS would have decompressed the portal system, a location distal to the site of obstruction, reducing perfusion of the liver even further without significantly decompressing the SMV. Therefore, the decision was made to place a stent to relieve the obstruction and decompress the SMV. Although the patient's absolute portal pressure remained slightly elevated at 12 cm H₂O, a gradient decrease from 22 to 11 cm H₂O was achieved.

Portomesenteric obstruction results from portal vein tumor thrombus or compression from neoplasms in 15%-24% of cases [3]. Other causes include benign portal vein thrombosis, post-operative stenosis, and inflammation secondary to pancreatitis. Portomesenteric obstruction secondary to external compression from another stent has not been previously described in the literature. Patients are likely to develop ascites, varices, and abdominal pain. Stent placement is a viable option for treatment in those patients who develop isolated mesenteric venous hypertension.

Park et al. described 14 patients who underwent stent placement for symptomatic portal vein stenosis, of which 13 of 14 resolved. After a median follow-up of 114 (range 25-260) days, stent occlusion occurred in 5 patients (36%). The median stent patency duration was 201 days [4]. Kim et al. showed that of 18 patients that underwent portal vein stent placement, the mean patency period of the benign stenosis group (30.1 ± 25.6 months) was longer than the tumor recurrence group (7.3 ± 7.7 months) [3].

Yamakado et al. evaluated 13 patients that underwent portal venous stent placement for malignancy. The main portal vein was invaded in 6 patients (group A). The main portal vein and splanchnic veins were involved in 7 patients (group B). In group A, blood flow through the stent was maintained in all patients and the symptoms had subsided at follow-up (mean, 12.5 months). In group B, symptoms were improved in 5 patients, but the stents were occluded in all but 1 patient at a mean follow-up of 1.5 months. It was concluded that patency is worse in patients with increased tumor burden. The portal venous pressure also decreased after stent placement, from $24.9 \text{ mm Hg} \pm 5.9$ (SD) to $15.8 \text{ mm Hg} \pm 4.6$ ($P < .001$) in this study [5].

Sheth et al. described 28 patients that met inclusion criterion for portal vein stent placement for refractory ascites and variceal bleeding. Stent deployment involved more than one portomesenteric vessel in most patients (20/26). The cumulative probability of symptom recurrence at 6, 12, 18, and 24 months was 12%, 16%, 26%, and 40%, respectively [6].

Sinistral portal hypertension (left-sided portal hypertension), usually caused by an occlusive thrombus in the splenic vein, is a rare cause of upper GI bleeding. Gastric varices arise due to back-pressure into the short gastric and gastroepiploic veins. Patients that undergo portal to SMV stent placement are at risk for developing sinistral portal hypertension due to eventual exclusion of the splenic and inferior mesenteric veins. This risk can be mitigated with the presence of inferior mesenteric to SMV varices to allow decompression [7]. Parallel stents placed in a Y configuration from the portal vein to SMV and splenic vein have been described. However, this decreases

the caliber of both stents, increasing the risk of thrombosis [8]. In the instance of sinistral portal hypertension, a partial splenic artery embolization to decrease the overall volume circulating through the spleen would prevent the development of new varices and decrease gastrointestinal bleeding risk [9].

The role of postoperative anticoagulation after portal vein stent placement is not well established. It has been suggested that stents intrinsically increase thrombogenicity; however, multiple publications have demonstrated similar patency rates in non-anticoagulated groups [6,10]. Nevertheless, anticoagulation should be weighed against the risk of gastrointestinal bleeding.

Conclusion

Careful consideration needs to be made before intervention in patients with ascites and varices. It is important to delineate portal hypertension from isolated splanchnic hypertension to provide a suitable outcome. Portomesenteric obstruction secondary to external stent compression has not been previously described. However, placement of a portal to superior mesenteric stent is a viable way to decompress isolated mesenteric venous hypertension and relieve patients of life-limiting refractory ascites and potentially catastrophic variceal bleeding.

Patient consent

Consent for publication was obtained for every individual person's data included in the study.

REFERENCES

- [1] Ponziani FR, Zocco MA, Campanale C, Rinninella E, Tortora A, Maurizio LD, et al. Portal vein thrombosis: insight into pathophysiology, diagnosis, and treatment. *World J Gastroenterol* 2010;16(2):143–55. doi:10.3748/wjg.v16.i2.143.
- [2] Bolognesi M, Di Pascoli M, Verardo A, Gatta A. Splanchnic vasodilation and hyperdynamic circulatory syndrome in cirrhosis. *World J Gastroenterol* 2014;20(10):2555–63. doi:10.3748/wjg.v20.i10.2555.
- [3] Kim KR, Ko GY, Sung KB, Yoon HK. Percutaneous transhepatic stent placement in the management of portal venous stenosis after curative surgery for pancreatic and biliary neoplasms. *AJR Am J Roentgenol* 2011;196(4):W446–50. doi:10.2214/AJR.10.5274.
- [4] Park JH, Yeo JH, Kim YS, Ahn HK, Sym S, Shin D, et al. Portal vein stent for symptomatic malignant portal vein stenosis: a single-center experience. *Curr Probl Cancer* 2020;44(2):100476. doi:10.1016/j.currprobcancer.2019.04.002.
- [5] Yamakado K, Nakatsuka A, Tanaka N, Fujii A, Isaji S, Kawarada Y, et al. Portal venous stent placement in patients with pancreatic and biliary neoplasms invading portal veins and causing portal hypertension: initial experience. *Radiology* 2001;220(1):150–6. doi:10.1148/radiology.220.1.r01j03150.
- [6] Sheth RA, Sabir SH, Parmet P, Amin R, Kuban JD, Huang SY, et al. Portomesenteric venous stenting for palliation of

- ascites and variceal bleeding caused by prehepatic portal hypertension. *Oncologist* 2018;23(6):712–18. doi:[10.1634/theoncologist.2017-0337](https://doi.org/10.1634/theoncologist.2017-0337).
- [7] Thompson SM, Fleming CJ, Yohanathan L, Truty MJ, Kendrick ML, Andrews JC. Portomesenteric venous complications after pancreatic surgery with venous reconstruction: imaging and intervention. *Radiographics* 2020;40(2):531–44. doi:[10.1148/rg.2020190100](https://doi.org/10.1148/rg.2020190100).
- [8] Kuban JD, Mahvash A, Sheth RA. Portomesenteric intervention in the cancer patient. *Endovasc Today* 2020;19(10):56–62.
- [9] Wang Q, Xiong B, Zheng C, Liang M, Han P. Splenic arterial embolization in the treatment of severe portal hypertension due to pancreatic diseases: the primary experience in 14 patients. *Cardiovasc Interv Radiol* 2016;39(3):353–8. doi:[10.1007/s00270-015-1199-8](https://doi.org/10.1007/s00270-015-1199-8).
- [10] Novellas S, Denys A, Bize P, Brunner P, Motamedi JP, Gugenheim J, et al. Palliative portal vein stent placement in malignant and symptomatic extrinsic portal vein stenosis or occlusion. *Cardiovasc Interv Radiol* 2009;32(3):462–70. doi:[10.1007/s00270-008-9455-9](https://doi.org/10.1007/s00270-008-9455-9).