

Original Article

## Anterior buccal mandibular depression: A descriptive study of CT findings

Ra'ed Al Sadhan, MS<sup>a</sup> and Ebtihal Zain-Alabdeen, MDS<sup>b,\*</sup>

<sup>a</sup> Department of Oral Medicine and Diagnostic Sciences, College of Dentistry, King Saud University, Riyadh, KSA

<sup>b</sup> Department of Oral Clinical and Basic Sciences, College of Dentistry, Taibah University, Almadinah Almunawwarah, KSA

Received 5 July 2021; revised 9 August 2021; accepted 13 August 2021; Available online 8 September 2021



### المخلص

**أهداف البحث:** تهدف الدراسة إلى تحديد توافق وجود السمات الشعاعية للمنخفضات الشذقية الأمامية في الفك السفلي والمنخفضات اللسانية الأمامية في الفك السفلي، عن طريق التصوير المقطعي المحوسب التقليدي ومسح الأشعة المقطعية المخروطية. كما قيمنا تأثير هذه المنخفضات على مكان زراعة الأسنان.

**طرق البحث:** تم إجراء مراجعة بأثر رجعي لصور الأشعة المقطعية لمجموعة من عظام الفك السفلي تحوي المنخفضات الشذقية الأمامية، لتقييم مكانها ومدى وجود ثقب ومنخفضات لسانية فيها، وسلامة الصفيحة القشرية لعظم الفك. قمنا بقياس عرض المنخفضات الشذقية الأمامية وطولها وعمقها، وقرارنا سماكة الصفيحة القشرية في الانخفاض مع سماكتها في عظم الفك الذي فوقه.

**النتائج:** تضمن البحث 37 مريضاً لديهم 74 منخفضاً شذقياً أمامياً، وجميعها وجدت في كلا جانبي الفك، ووجدت منخفضات شذقية أمامية مع منخفضات لسانية في نفس عظم الفك في 13 موقعا (17.6%). وفي 20 حالة (27.1%) وجدت ثقب واحدة على الأقل فيها. كانت قشرة العظم الشذقية في المنخفض سليمة في جميع الحالات. وأظهرت الصور أن محتويات المنخفضات الشذقية الأمامية كانت دهنية. وفي المتوسط كان طولها 7.1 ملم وعرضها 1.67 ملم وعمقها 18.8 ملم. وكان متوسط سماكة صفيحة العظم القشرية في المنخفضات الشذقية الأمامية 1.23 ملم (1.9-0.4 ملم)، وذلك على غرار سماكتها في العظم الذي يعطوه والتي كانت 1.34 ملم (2.0-0.7 ملم). كان متوسط السمك الإجمالي لعظم الفك السفلي من سطحه مما يلي الخد إلى سطحه مما يلي اللسان 8.72 ملم (15-4.4-13.4 ملم) في المواقع التي بها منخفضات شذقية بدون منخفضات لسانية بينما كانت فقط 4.6 ملم (8-1.8 ملم) في المواقع التي بها منخفضات شذقية مع منخفضات لسانية، وبلغ الحد الأدنى لهذه السماكة 1.8 ملم.

**الاستنتاجات:** وجود منخفضات شذقية مع منخفضات لسانية يقلل كمية العظام المتاحة لوضع غرسة زراعة الأسنان بشكل كبير.

**الكلمات المفتاحية:** المنخفضات الأمامية اللسانية للفك السفلي؛ الصفيحة القشرية؛ العرض العلوي السفلي؛ العمق الشذقي اللساني؛ تشريح الطول الإنسي القاصي

### Abstract

**Objective:** This study aims to report the concurrence of the radiographic features of anterior buccal mandibular depressions (ABMDs) and anterior lingual mandibular depressions (ALMDs) by conventional computed tomography (CT) and cone beam CT scans. We also assess the effect of ABMDs and ALMDs on dental implant sites.

**Methods:** A retrospective review of CT scans of the mandibles with ABMDs was conducted to assess the morphology, site, presence of foramina, ALMDs, and the integrity of the cortical plate. The superoinferior width of ABMD, the buccolingual depth, and mesiodistal length were measured and compared with the thickness of the cortical plate at the depression to the area superior to it.

**Results:** Thirty-seven patients with 74 ABMDs were included in this study. All observed ABMDs occurred bilaterally, and ALMDs with ABMDs occurred in 13 sites (17.56%). In 20 (54%) cases, at least one foramen was noted. The buccal cortical bone was intact in all cases. The contents of ABMDs were found to be fatty. On an average, their superoinferior width was 7.1 mm, buccolingual depth 1.67 mm, and mesiodistal length 18.8 mm. The average buccal cortical bone plate thickness at the ABMD was 1.23 mm (range 0.4–1.9 mm), while the average buccal cortical bone plate thickness coronal to the ABMD was 1.34 mm (range 0.7–2.2 mm). The average buccolingual dimension of the mandible was

\* Corresponding address: Department of Oral Clinical and Basic Sciences, College of Dentistry, Taibah University, P. O. Box 41411, Almadinah Almunawwarah, KSA.

E-mail: [ebtihalh@gmail.com](mailto:ebtihalh@gmail.com) (E. Zain-Alabdeen)

Peer review under responsibility of Taibah University.



8.72 mm (range 4.15–13.4 mm) at ABMD sites without ALMD and 4.6 mm with ALMD (range 1.8–8 mm).

**Conclusion:** When ALMD occurs in the presence of ABMD, the amount of bone available for implant placement is greatly reduced.

**Keywords:** Anterior lingual mandibular depressions; Buccolingual depth; Cortical plate; Mesiodistal length anatomy; Superoinferior width

© 2021 The Authors.

Production and hosting by Elsevier Ltd on behalf of Taibah University. This is an open access article under the CC BY-NC-ND license (<http://creativecommons.org/licenses/by-nc-nd/4.0/>).

## Introduction

The anterior buccal mandibular depression (ABMD) is a linear depression with an intact bone cortex on the buccal surface of the anterior mandibular body, located bilaterally on either side of the mandibular symphysis in the interforaminal region between the mental protuberance and alveolar ridge running parallel to the inferior border of the mandible.<sup>1–3</sup> It is differentiated from the incisive fossa of the anterior labial surface of the mandible (also called the mental fossa or fovea) by its location. The ABMD is bilateral and located more laterally on the buccal surface of the anterior mandible between the basal bone and mandibular alveolar process, closer to the inferior border of the mandible. The incisive fossa of the mandible, however, is a single depression found on the same surface of the mandible, closer to the midline and between the mental protuberance and alveolar ridge of the mandible in the lower incisor area. Anatomical studies on cadaveric human mandibles reported the prevalence of ABMD to be between 31.8%<sup>3,4</sup> and 19.8% in adults<sup>2</sup> and as low as 2.3% in the mandibles of adult Arabs.<sup>1</sup> In previous reports, ABMDs in adult mandibles were found to have a depth of 1.5–4 mm, a width of 3–6 mm, and a length of 10–15 mm.<sup>1,3</sup> The anterior lingual mandibular depression (ALMD) is a lingual concavity that has been reported to occur in the anterior mandible<sup>5</sup>; it has been compared to ABMD because they appear to be similar on periapical and panoramic radiographs as a result of superimposition.<sup>1</sup> However, no previous study has reported the occurrence of an ABMD and ALMD in the same mandible. Two previous reports described the radiographic features of ABMDs observed in human mandibles resected from cadavers using small field-of-view size 2 periapical radiographic examinations (31 × 41 mm) or panoramic radiography of the specimens; they found that most ABMDs were not clearly depicted on these radiographs and that ABMDs and ALMDs were indistinguishable based only on these radiographic examinations.<sup>2,4</sup> Only one study reported better detectability of ABMDs in resected mandibles on 14 computed tomography (CT) scans without reporting on the tomographic features of these depressions.<sup>4</sup> No previous studies described the tomographic features of ABMDs on CT or cone beam CT (CBCT) scans in vivo.

After tooth loss, vertical and horizontal residual alveolar ridge resorption occurs in the anterior mandible from the labial aspect.<sup>6</sup> Thus, cross-sectional imaging with CBCT is the current method of choice for presurgical assessment of the dental implant site.<sup>7</sup> The significance of ABMDs in oral implantology has been highlighted,<sup>8</sup> but no studies have investigated the effect of ABMDs on the assessment of proposed dental implant sites.

The purpose of this study was to describe the radiographic features of ABMDs on CT and CBCT examinations in patients and report on the occurrence of both ABMD and ALMD in the same mandible. In addition, we assessed the effect of ABMD together with ALMD on the dental implant site in the anterior mandible.

## Materials and Methods

Ethical permission was granted to conduct this retrospective study by the institutional review board for Health Sciences Colleges Research on Human Subjects at King Saud University (Ref. No. 21/0105/IRB). A sample size estimation of 35 patients was made considering the prevalence of depression in mandibles of adult Arabs of 2.3%,<sup>8</sup> a margin of error of 5%, and a confidence level of 95% as reported by Arensburg et al.<sup>1</sup> We reviewed the CT and CBCT scans of the mandibles of adult patients referred to the oral and maxillofacial radiology clinic at the Dental University Hospital at King Saud University in Riyadh. The CT examinations were made using a GE Lightspeed VCT 64 slice CT scanner (Milwaukee, Wisconsin, USA) with a tube voltage of 120 kV, auto mA tube current, and section thickness and separation between sections of 0.6 mm. The matrix size was 512 × 512 with a minimum 16 cm field of view. CBCT examinations were made with a Planmeca ProMax 3D CBCT unit (Planmeca Oy, Helsinki, Finland) with a voxel size of not more than 0.2 mm. The reconstructed images were then transferred to the workstation for reformatting and image analysis in DICOM format (Digital Imaging and Communications in Medicine) with the Romexis software version 5.2.0.R (Planmeca Oy, Helsinki, Finland). These examinations were originally requested to assess impacted third molars or a dental implant site.

Selection criteria for the chosen examinations were scans that included at least a field of view with both mental foramina and no intrabony pathology or history of previous surgery in the anterior mandible. Cases were selected when a well-defined depression between the mental protuberance and alveolar ridge was noted running parallel to the inferior border of the mandible in the buccal surface of the anterior mandible, with a clear superior rim observed. These inclusion criteria were similar to those used in previous anatomical studies.<sup>8–11</sup> The study variables collected for each case were as follows: age, sex, the presence of the ABMD unilaterally or bilaterally, the presence of foramina on the surface of the buccal cortical plate of the mandible at the ABMD unilaterally or bilaterally, the presence of the ALMD unilaterally or bilaterally, and the integrity of the buccal cortical plate at the ABMD. For linear measurements on cross-sectional images, CT and CBCT examinations in which the mandibular canines had fully erupted and were aligned within the lower dental arch; were free of gross

developmental anomalies of tooth shape; and had no malalignment, malposition, or rotation, were selected.

For all cases, an oral and maxillofacial radiologist with over 20 years of experience made and saved a standardised multiplanar reformatting (MPR) section along the middle mesiodistal, buccolingual, and coronal axes of the mandibular canine near the ABMD. The same operator viewed all the CT and CBCT examinations on a 22-inch Dell E228WFP flat panel monitor (Round Rock, TX, USA) with a display resolution of  $1680 \times 1050$  pixels. The images were viewed with the same software used for MPR. The observer could adjust the brightness and contrast, and evaluated and volumetrically rendered images to assess ABMDs and ALMDs and perform linear measurements. Prior to viewing, the observer was informed of the definition of the studied radiological features and measurements collected. The linear measurements were made along five lines drawn on the standardised buccolingual cross-section of the mandible at the site of the canine as follows:

1. Superoinferior ABMD width (line W): The distance between the superior and inferior rims of the ABMD.
2. Buccolingual ABMD depth (line D): The distance along the longest line that is drawn perpendicular to the W line to the surface of the buccal cortical plate of the mandible.
3. Buccal cortical bone thickness at the ABMD (line C1): The distance along a line that extends from the end of the D line at the surface of the mandible to the edge of the inner table of the buccal cortical plate.
4. Buccal cortical bone thickness coronal to the ABMD (line C2): The distance along a line that extends from the surface of the mandible to the edge of the inner table of the buccal cortical plate at a point in the middle distance

between the upper rim of the ABMD and the crest of the mandibular alveolar ridge.

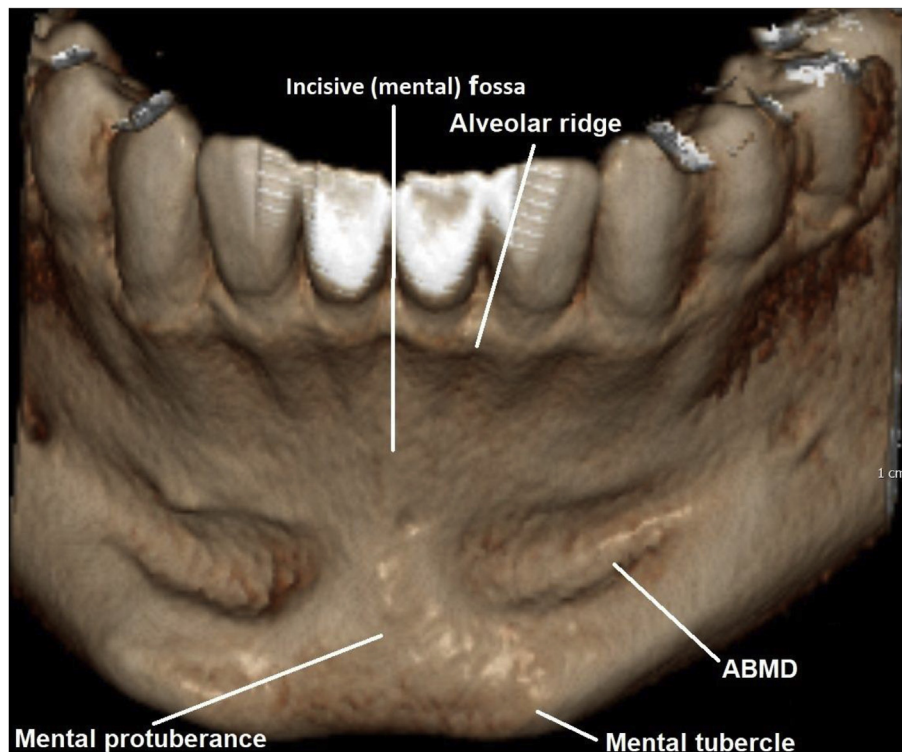
5. The mesiodistal length of the ABMD (L line): Measured from the most anterior part of the depression near the midline to the most posterior part of the depression near the mental foramen.

To assess the effect of the presence of the ABMD and ALMD on proposed dental implant sites in the anterior mandible, we measured the buccolingual dimension of the mandibular body at the ABMD (line BL) as the distance along a line drawn perpendicular to the coronal long axis of the canine at the deepest area of the ABMD (at the end of line D). The readings were compared with measurements made on a control group of matching age ( $\pm 1$  year) and sex. The buccolingual dimension of the mandible perpendicular to the long axis of the canine (line BL) was compared to the same measurements of the group of patients who had an ABMD.

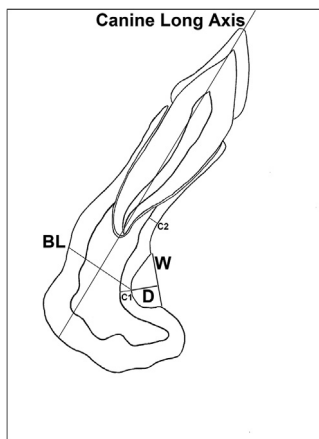
Measurement reliability was assessed as intra-rater reliability from the intra-class correlation coefficient. The reliability coefficient was excellent (0.81). Means and standard deviations were used for descriptive statistics with 95% confidence intervals. The t-test for independent variables were used to test any significant difference between the buccolingual thickness of mandible of patient with and without ABMD/ALMD using Stata version 13.1 (Stata-Corp, College Station, Texas 77845 USA).

## Results

Thirty-seven patients were included in this study, with 74 ABMDs. Of these, 27 were male and 10 were female (2.7:1



**Figure 1:** A volumetrically rendered CBCT image of the anterior mandible showing the alveolar ridge, ABMD, incisive (mental) fossa, mental protuberance, and mental tubercle.

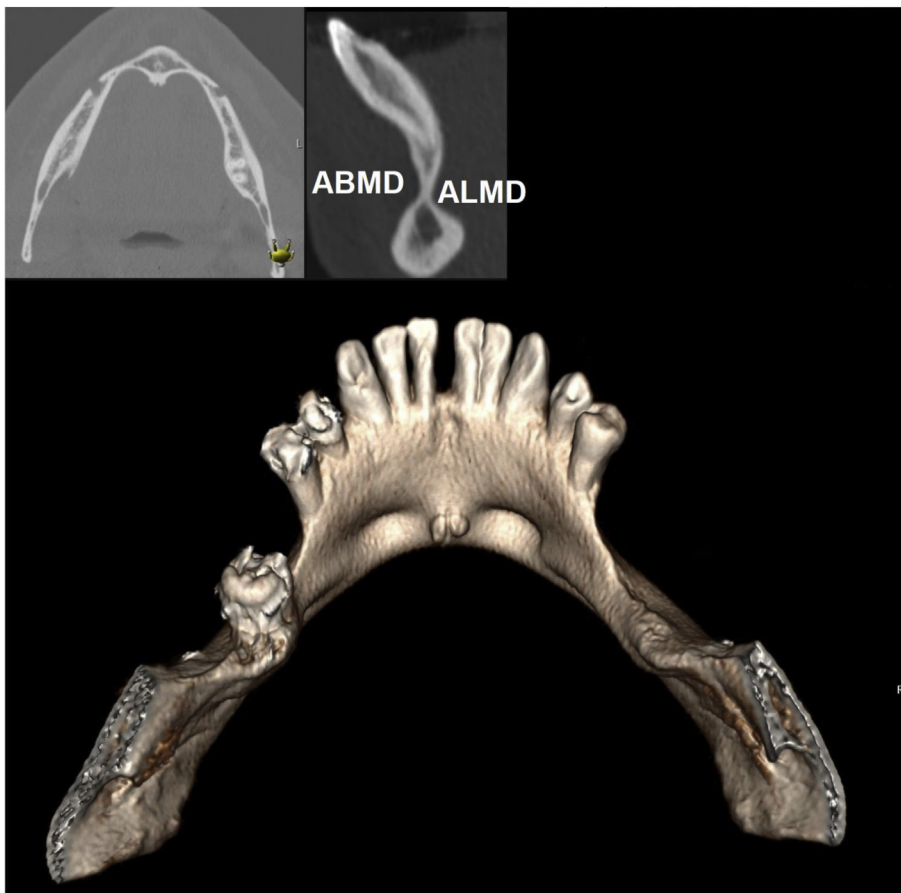


**Figure 2:** Illustration of the linear measurements made on a standardised buccolingual cross-section at the middle mesiodistal, buccolingual, and coronoapical axes of the mandibular canine near the ABMD: ABMD width (W), ABMD depth (D), cortical bone thickness at ABMD (C1), cortical bone thickness coronal to ABMD (C2), and buccolingual dimension of the mandible at ABMD (BL).

male-to-female ratio). The average age was 39.3 years (range 13–63 years). The ABMDs occurred symmetrically bilaterally in all cases. Bilateral ALMDs were noted to accompany ABMDs in the same mandible in 13 sites (17.56%). In this

<b>Table 1: Summary of the linear measurements.</b>		
	Mean (mm)	SD
Superoinferior ABMD width (line W)	7.09	1.89
Buccolingual ABMD depth (line D)	1.67	0.6
Cortical bone thickness at ABMD (line C1)	1.23	0.31
Cortical bone thickness coronal to ABMD (line C2)	1.34	0.4
Mesiodistal length of ABMD (line L)	18.8	3.1
Buccolingual dimension of mandible at ABMD (line BL) without ALMD	8.72	1.86
Buccolingual dimension of mandible at ABMD (line BL) with ALMD	4.6	2.03

study, ABMDs were observed on each side of the symphysis, anterior to the mental foramen and extending under the alveoli of the first premolar to the lateral or central incisor. The depression is horizontal or slightly oblique in a postero-superior to an antero-inferior direction (Figure 1). In 20 patients (54%), at least one foramen was noted on the surface of the buccal cortical plate of the mandible at the ABMD. These foramina were noted bilaterally in 10 cases (27%) and on only one side in 10 cases (27%). The buccal cortical bone was intact in all cases and no interruption was noted. The average buccolingual dimension of the mandibular body at the ABMD at sites that did not include ALMDs was 8.72 mm, whereas it was only 4.6 mm



**Figure 3:** Computed tomography images of the mandible showing ABMD ALMD occurring in the same case and resulting in thinning of the mandibular body.



at sites where ALMDs were observed; the minimum buccolingual thickness of the mandibular body observed measured only 1.8 mm (Figure 2). Table 1 summarises the linear measurements.

The independent t-test showed that the buccolingual width in ABMD group had a mean of 8.72 mm with a 95% confident interval of 8.25 mm–9.20 mm, which was significantly higher ( $P < .001$ ) than the buccolingual width in the group with both ABMD and ALMD, where the mean was 4.60 mm with a 95% confident interval of 3.37 mm–5.82 mm, indicating that the buccolingual width dropped to almost half of its width with the presence of ALMD.

## Discussion

The results of this study showed that ABMDs occurred bilaterally with an average width of about 7 mm and depth ranging from 0.8 mm to 4.5 mm as measured on buccolingual CT cross-sections. These findings were close to those of previous anatomical studies on mandibles with such depressions.<sup>1,2</sup> The intact cortical bone plate and the fatty nature of the ABMD content seen in this CT study is similar to findings in cadaveric dissection and other radiographic studies.<sup>2,3</sup> The average buccal cortical bone plate thickness at the ABMD was around 1.23 mm, which is close to the thickness coronal to the ABMD, which had an average measurement of 1.34 mm. This finding might reflect the developmental nature of the ABMD, showing that, because there did not appear to be a difference in the buccal cortical plate bone thickness, it most likely arose peripherally on the surface of the bone rather than inside the medullary inner portion of the mandible. ALMDs were found at the same site as ABMDs (Figure 3) in only 17.56% of patients included in this study. When dental implant site assessment was simulated at the site of the ABMD, sufficient buccolingual mandibular alveolar bone width was noted (0.9 mm) only if the ALMD did not exist on the same side, in which case the average width was only 4.6 mm and as narrow as 1.8 mm. ABMDs and ALMDs are indistinguishable on periapical and panoramic radiographs because of superimposition. It is not possible to palpate these depressions or inspect them during osteotomy development as it is recommended that the entire mentalis muscle should not be released from its attachment when a flap is raised.<sup>9</sup> Thus, the width of the residual alveolar ridge at the site of the ABMD can be overestimated and the cortical plates inadvertently perforated as a result. Linear measurements of CT scans for the assessment of dental implant sites produce errors mostly within 1 mm<sup>10,11</sup>; for this reason, when planning implants, a safety margin of 1 mm is recommended.<sup>12</sup> Therefore, a CT examination with a radiographic stent to demonstrate the site and path of insertion of planned dental implants is the most accurate way to estimate the diameter, length, and path of insertion to accommodate such depressions; to engage the bone during implant insertion; and to avoid implant dehiscence or fenestration.<sup>13</sup>

In this study, foramina were noted on the surface of the buccal cortical plate of the mandible at the ABMD. In their anatomic and histological dissection study, Littner et al.<sup>3</sup>

reported that all cadavers with ABMDs had intact cortical bone plates and that some had a small aperture containing nerves and blood vessels. Similar foramina have been reported on the lingual aspect of the mandibular body.<sup>14</sup>

Arensburg et al.<sup>1</sup> suggested both genetic and developmental origins of ABMDs. The resorptive and depository areas of the chin and anterior mandible follow changes related to the age process, such as teeth development and movement, as well as jawbone remodelling. The reversal or junction line between depository and resorptive growth fields usually occurs at the point where the concave surface contour becomes convex. The reversal line may be high or low, and the relative amounts of resorption and deposition may produce marked variations in the shape and size of the chin among individuals. The remodelling process of the mandible may explain how ABMDs develop. A depository region occurs in the basal buccal surface of the symphysis, while in the uppermost alveolar part a strongly resorptive area occurs. The reversal line where the depository area is bounded upward by a resorptive alveolar area and the ABMD represents an area between these two fields.

This study showed that the presence of the ABMD affected the buccolingual dimension of the mandible in the canine region, especially if it occurs with the ALMD. In patients requiring surgical intervention in the anterior mandible, such as dental implant insertion, orthognathic surgery, or bone graft harvesting, clinicians must assess the area with CBCT examination to avoid complications, such as dental implant fenestration or even mandibular body fracture.

One of the limitations of the current study is that the measurements of ABMDs and ALMDs were only performed on CT or CBCT sections made along a standardised MPR section along the middle mesiodistal, buccolingual, and coronal axes of the mandibular canine near the ABMD. Further measurements on additional reconstructed sections along these depressions may provide more information on its effect on dental implant site assessment in the mandibular incisors and premolar regions. Further studies can be conducted to assess the effect of the ABMD and the ALMD on the dental implant treatment planning, treatment, and outcome.

## Conclusion

The radiographic features of the ABMD are consistent with those of prior anatomical reports. When ALMDs occur on the same side of the mandible as ABMDs, the amount of mandibular bone width available for implant placement is greatly reduced.

## Source of funding

This research did not receive any specific grant from funding agencies in the public, commercial, or not-for-profit sectors.

## Conflict of interest

The authors have no conflict of interest to declare.

### Ethical approval

The Institutional Review Board at King Saud University reviewed and ethically approved the study on 15 January 2021 (02 Jumaada-Ii 1442).

### Authors contributions

RA wrote the literature review, collected the data, performed the statistical analysis, created the tables, wrote the discussion and limitations, performed the final revision, approved the version to be published, and submitted the manuscript. EHZ designed the research idea, interpreted the data, composed the results, helped in the discussion, organised and formatted the references, adjusted figures and tables, and approved the final version to be published. All authors have critically reviewed and approved the final draft and are responsible for the content and similarity index of the manuscript.

### Acknowledgment

English language editing was performed by Barbara Every, ELS, of BioMedical Editor.

### References

1. Arensburg B, Kaffe I, Littner MM. The anterior buccal mandibular depressions: ontogeny and phylogeny. *Am J Phys Anthropol* 1989; 78(3): 431–437. <https://doi.org/10.1002/ajpa.1330780311>.
2. Kaffe I, Littner MM, Arensburg B. The anterior buccal mandibular depression: physical and radiologic features. *Oral Surg Oral Med Oral Pathol* 1990; 69(5): 647–654.
3. Littner MM, Kaffe I, Levine T, Arensburg B. Anterior buccal mandibular depression (ABMD): anatomic and histologic features. *Surg Radiol Anat* 1994; 16(2): 179–182.
4. Littner MM, Kaffe I, Arensburg B, Calderon S, Levin T. Radiographic features of anterior buccal mandibular depression in modern human cadavers. *Dentomaxillofacial Radiol* 1995; 24(1): 46–49.
5. Altwaim M, Al-Sadhan R. Bilateral anterior lingual depression in the mandible: cone beam computed tomography case report and review of the literature. *Cureus* 2019; 11(12):e6348. <https://doi.org/10.7759/cureus.6348>.
6. Cawood JI, Howell RA. A classification of the edentulous jaws. *Int J Oral Maxillofac Surg* 1988; 17(4): 232–236.
7. Tyndall DA, Price JB, Tetradis S, Ganz SD, Hildebolt C, Scarfe WC, et al. Position statement of the American Academy of Oral and Maxillofacial Radiology on selection criteria for the use of radiology in dental implantology with emphasis on cone beam computed tomography. *Oral Surg Oral Med Oral Pathol Oral Radiol* 2012; 113(6): 817–826. <https://doi.org/10.1016/j.oooo.2012.03.005>.
8. Littner MM. The significance of the anterior buccal mandibular depression in oral implantology. *Dentomaxillofacial Radiol* 1991; 20(4): 227.
9. Resnik RR. Mandibular anatomic implications for dental implant surgery. In: Resnik RR, editor. *Misch's contemporary implant dentistry*. 4th ed. St. Louis: Mosby; 2020. pp. 737–770.
10. Al-Ekrish A, Ekram M. A comparative study of the accuracy and reliability of multidetector computed tomography and cone beam computed tomography in the assessment of dental implant site dimensions. *Dentomaxillofacial Radiol* 2011; 40: 67–75. <https://doi.org/10.1259/dmfr/27546065>.
11. Suomalainen A, Vehmas T, Korttesniemi M, Robinson S, Peltola J. Accuracy of linear measurements using dental cone beam and conventional multislice computed tomography. *Dentomaxillofacial Radiol* 2008; 37(1): 10–17. <https://doi.org/10.1259/dmfr/14140281>.
12. Horner K. Cone-beam computed tomography: time for an evidence-based approach. *Prim Dent J* 2013; 2(1): 22–31. <https://doi.org/10.1308/205016813804971582>.
13. Greenstein G, Cavallaro J, Tarnow D. Practical application of anatomy for the dental implant surgeon. *J Periodontol* 2008; 79(10): 1833–1846. <https://doi.org/10.1902/jop.2008.080086>.
14. Yildirim YD, Güncü GN, Galindo-Moreno P, Velasco-Torres M, Juodzbalys G, Kubilius M, et al. Evaluation of mandibular lingual foramina related to dental implant treatment with computerized tomography: a multicenter clinical study. *Implant Dent* 2014; 23(1): 57–63. <https://doi.org/10.1097/ID.0000000000000012>.

**How to cite this article:** Al Sadhan R, Zain-Alabdeen E. Anterior buccal mandibular depression: A descriptive study of CT findings. *J Taibah Univ Med Sc* 2022;17(2):283–288.