



Since January 2020 Elsevier has created a COVID-19 resource centre with free information in English and Mandarin on the novel coronavirus COVID-19. The COVID-19 resource centre is hosted on Elsevier Connect, the company's public news and information website.

Elsevier hereby grants permission to make all its COVID-19-related research that is available on the COVID-19 resource centre - including this research content - immediately available in PubMed Central and other publicly funded repositories, such as the WHO COVID database with rights for unrestricted research re-use and analyses in any form or by any means with acknowledgement of the original source. These permissions are granted for free by Elsevier for as long as the COVID-19 resource centre remains active.

- [2] Amhaz HH, Chamoun RB, Waguespack SG, Shah K, McCutcheon IE. Spontaneous involution of Rathke cleft cysts: is it rare or just underreported? *J Neurosurg* 2010;112:1327–32. <http://dx.doi.org/10.3171/2009.10.JNS091070>.
- [3] Kim CW, Hwang K, Joo JD, Kim YH, Han JH, Kim CY. Spontaneous involution of Rathke's cleft cysts without visual symptoms. *Brain Tumor Res Treat* 2016;4:58–62. <http://dx.doi.org/10.14791/btrt.2016.4.2.58>.
- [4] Saeki N, Kubota M, Yamaura A, Ishige N. Fluctuating visual field defects in Rathke's cleft cysts: MRI analysis. *J Clin Neurosci Off J Neurosurg Soc Australas* 1999;6:524–7. [http://dx.doi.org/10.1016/s0967-5868\(99\)90018-8](http://dx.doi.org/10.1016/s0967-5868(99)90018-8).
- [5] Nishio S, Morioka T, Suzuki S, Fukui M. Spontaneous regression of a pituitary cyst: report of two cases. *Clin Imaging* 2001;25:15–7. [http://dx.doi.org/10.1016/s0899-7071\(00\)00233-3](http://dx.doi.org/10.1016/s0899-7071(00)00233-3).

Le Uyen France Truong^{a,*}
 Benoît Marlier^a
 Bénédicte Decoudier^b
 Claude Fabien Litré^a
 Sara Barraud^{b,c}

^a Department of Neurosurgery of the CHU of Reims, Hôpital Maison Blanche, 45, rue Cognacq-Jay, 51100 Reims, France

^b Department of Endocrinology of the CHU of Reims, Hôpital Robert Debré, rue du Général-Koenig, 51100 Reims, France

^c CRESTIC EA 3804, Reims Champagne-Ardenne University, Moulin de la Housse, 51687, Reims, France

* Corresponding author.

E-mail address: luftruong@chu-reims.fr (L.U.F. Truong)

<https://doi.org/10.1016/j.ando.2022.03.004>

0003-4266 © 2022 Elsevier Masson SAS. All rights reserved.

Three cases of thyroiditis after COVID-19 RNA-vaccine



ARTICLE INFO

Keywords:

Thyroiditis
 COVID-19
 Vaccine
 Subacute thyroiditis
 Conversion to Graves' disease

1. Case Reports

Vaccines have demonstrated efficacy in SARS-CoV-2 infection. Four vaccines are currently authorized in Europe (Comirnaty, Pfizer®; Spikevax, Moderna®; Vaxzevria, AstraZeneca®; and Janssen, Johnson and Johnson®). Some vaccine technologies are already well known and others, such as messenger RNA (mRNA) vaccines, were first used during this pandemic. A lot of cases of thyroiditis have been reported during or after Covid-19 infection but only a few after vaccination. The present study reports 3 cases with different presentations of thyroiditis after mRNA vaccination.

Abbreviations: ASIA, Autoimmune/inflammatory syndrome induced by adjuvants; fT4, free thyroxine; SAT, subacute thyroiditis; TPO, thyro-peroxidase; TR, TSH receptor.

1.1. Case 1

A 56-year-old woman received two doses of the Spikevax vaccine, 4 weeks apart. One week after the second dose, she was admitted to hospital for fatigue, severe weight loss (–5 kg), evening fever (39.5 °C) with intense perspiration, diarrhoea episodes and tachycardia associated with biological inflammatory syndrome. A few days before admission, she experienced anterior neck pain and was treated with amoxicillin for 5 days, without improvement.

Thyroid function test found biological inflammatory syndrome (CRP: 70 mg/L) and overt moderate hyperthyroidism [TSH: 0.01 mIU/L, fT4: 25.7 pmol/L (normal: 9.3–17.1)], whereas 4 days prior to the routine second vaccine injection, her TSH level was 0.96 mIU/L. Thyroid ultrasound showed hypoechogenic areas in both lobes, consistent with subacute thyroiditis (SAT). TSH receptor (TR) and thyroperoxidase (TPO) antibodies were negative; only thyroglobulin antibodies were elevated (614 U/mL).

Because medical severity contrasted with the thyroid hormone level, explorations were pursued. Thoraco-abdominal CT scan and glucose analogue FDG-PET/CT did not find any sign of infection or neoplasm and confirmed thyroid inflammation (Fig. 1).

The patient received prednisone 40 mg for a week then lowered by 10 mg per week steps, with rapid clinical improvement and thyroid function normalization.

1.2. Case 2

A 44-year-old female nurse came to our emergency room for severe anterior right neck pain associated with headache. She had no history of thyroid or autoimmune disease. Symptoms appeared 5 weeks after the first dose of Comirnaty vaccine and did not improve despite 6 days' self-medication with non-steroidal anti-inflammatory drugs.

Her heart rate was 93 bpm, with 38.3 °C fever. Thyroid palpation found global sensitivity, with pain especially on the right side. Thyroid function was normal (TSH: 0.75 mIU/L), thyroid antibodies were negative, but CRP level was elevated (21 mg/L). Thyroid ultrasound revealed a large hypoechogenic area with blurred outline on the right lobe and a smaller one on the left, associated with healthy thyroidal parenchyma areas, confirming the diagnosis of SAT.

Prednisone 40 mg/day was initiated and then tapered weekly. Her complaints regressed 3 days after treatment initiation, but pain reappeared at the end of the corticosteroid therapy, with new elevation of CRP and enlargement of the left hypoechogenic area. Reintroduction of prednisone was effective. Being a nurse, she was obliged to receive a second dose of vaccine 4 months after the first. She did not develop any symptoms, and TSH level remained normal.

1.3. Case 3

TA 44-year-old female with regular medical follow-up for Hashimoto's disease had been treated with 75 µg levothyroxine (Levothyrox®) for 20 years. At initial diagnosis, TPO antibody level was high, while TR antibodies were negative.

Five days after the first dose of Comirnaty vaccine, her TSH level was low (<0.01 mIU/L), and the levothyroxine dose was reduced. On thyroid ultrasound, volume was 7.4 mL with hypervascularization in both lobes (15 years earlier, the volume was 8.5 mL). She did not present neck pain or fever, TR antibodies were positive (twice the upper limit of normal) and anti-TPO antibodies were negative. At the time of writing, levothyroxine had been reduced to 25 µg, with normal thyroid function. As in case 2, the patient received a second dose of Comirnaty vaccine 4 weeks later, without any changes.

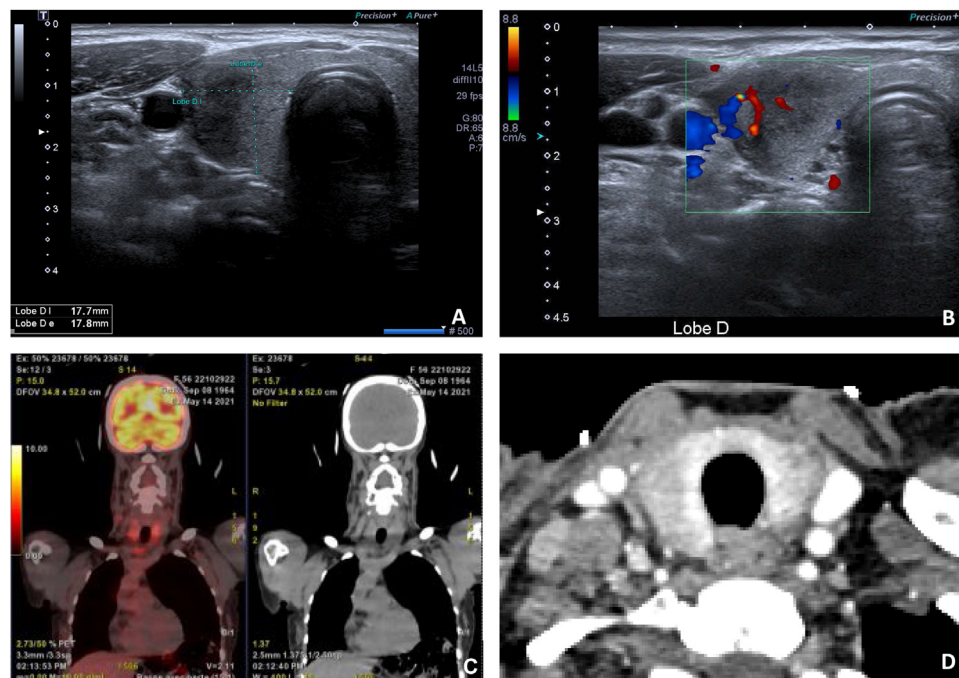


Fig. 1. Thyroid imaging. A. Thyroid ultrasonography images of patient 1. Focal hypoechoic area on the right lobe. B. Thyroid ultrasonography images of patient 2. Decreased blood flow on Doppler USG in the right lobe except for one healthy part in the middle. C. PET/CT of patient 1, showing thyroid uptake. D. Thyroid CT showing hypodensity on both thyroid sides.

2. Discussion

We report two cases of subacute thyroiditis and one conversion from Hashimoto's to Graves' disease after Covid-19 RNA vaccination. Many observations of subacute thyroiditis and endocrine autoimmune disorders have been made after classical vaccination, and now a few after Covid-19 vaccination.

To our knowledge, 24 cases of SAT associated with a COVID vaccine have been reported: 6 after inactivated virus vaccination, 4 after adenovirus vectored vaccination, 13 after RNA vaccination and 1 after an unspecified type [1–16]. As usual in post-viral SAT, in the 24 SAT cases, there was a clear majority of women: 19 women versus 5 men. Median age was 45 years, but the affected women were younger (median age, 41 years) than the men (median age, 55 years). Personal or familial history of autoimmune disease was reported only for 2 patients. This growing number of observations seems to implicate vaccination as a trigger for the disease. However, SAT is not exceptional and given the large number of vaccinated individuals, chance association cannot be ruled out. The rarity of occurrence may also be due to differences in genetic susceptibility, as suggested by Stasiak et al. They found the presence of two HLA risk alleles in two patients with post-vaccination SAT [16]. Upper airway infection usually precedes SAT, but did not occur in the present two cases, which could be consistent with vaccine involvement.

SAT pathophysiology is incompletely understood and still debated. There are two main hypotheses: either direct thyrocyte damage by the virus, or activation of cytotoxic lymphocytes impairing thyroid cells in a non-specific way [17]. The occurrence of cases of SAT after vaccination suggests that direct viral attack may not be the only pathophysiological mechanism involved. To explain this Covid vaccine side-effect, a few hypotheses have been suggested, depending on the vaccine components. The first hypothesizes a form of autoimmune/inflammatory syndrome induced by adjuvants (ASIA), previously reported following live attenuated vaccines (influenza, HPV and Coronavac vaccines). This syndrome is explained by the use of adjuvants in the vaccine to increase the immunogenic response. They prolong the presence of the

inoculated antigen in the bloodstream and improve its transport to lymph nodes, the main site of the cellular immune response. However, RNA and adenovirus vectored vaccines, such as Pfizer, Moderna and AstraZeneca, do not contain adjuvants. They all lead to spike protein expression, which shows similarities to a thyrocyte membrane protein [18]. This can trigger antigenic cross-reactivity and an autoimmune response. RNA and DNA vaccines also stimulate cellular immune response [18]. Thus, thyroid cytotoxicity may be induced by activation of T CD4+ and CD8+ lymphocytes.

Seven cases of Graves' disease after COVID 19 vaccination have also been reported, but no cases of conversion of Hashimoto's disease [19–23]. Graves' disease is an auto-immune disease due to production of class 1 IgG, stimulating the TSH receptor. These antibodies are produced secondary to a Th1 immune response in which interferon-gamma plays a key role [24]. As anti-SARS-Cov-2 vaccines lead to a production of Th1 cells, a similar mechanism could be involved in vaccine-induced Graves' disease.

The third case we describe was atypical and exceptional. This patient presented with hypothyroidism of more than 20 years' progression, well balanced on a stable dose of L-thyroxine. She had no anti-TSH receptor antibodies at diagnosis, but did show anti-TPO antibodies. Shortly after the first dose of vaccine, her L-thyroxine requirements collapsed, without revealing spontaneous hyperthyroidism. In view of the evolution of L-thyroxine requirements and the appearance of anti-TSH receptor antibodies, this case seems to involve conversion from Hashimoto's thyroiditis to a form close to Graves' disease.

Conversion to Graves' disease from Hashimoto's thyroiditis is rare, and the contrary is much more frequent; nevertheless, it has been reported and seems to be caused by a change in the balance between the levels of stimulating and blocking antibodies to the thyroid-stimulating hormone receptor [25]. Patients maintaining average residual thyroid tissue are certainly more likely to be affected. To our knowledge, we report here the first case of development of Graves' disease from Hashimoto's thyroiditis after SARS-CoV-2 vaccination. A drastic decrease in L-thyroxine needs should raise the suspicion of such a conversion.

Some scientific societies have taken a position in favour of vaccination for patients with stabilized pre-existing thyroid pathology.

However, the question of thyroid damage due to vaccination has not been addressed. These side effects can occur after only one dose, raising the question of whether a second dose should be administered. Our second patient, a nurse, was professionally obliged to receive the 2nd dose, in spite of the episode of thyroiditis. She did not present any recurrence of symptoms and TSH remained normal.

We report 3 cases of thyroiditis following RNA vaccination against Covid-19: two cases of SAT and one conversion from Hashimoto's thyroiditis to Graves' disease years after diagnosis. Two patients received a second dose of vaccine without worsening. SAT symptomatology is not always typical but can be significant and thus may wrongly suggest infectious or neoplastic pathology. It is therefore essential that the medical community be aware of this potential rare side-effect, especially with the need for boosters. Despite the initial symptoms, which were sometimes serious, the final consequences were minimal.

Funding

This research did not receive any specific grant from any funding agency in the public, commercial or not-for-profit sectors.

Disclosure of interest

The authors declare that they have no competing interests.

Statement of ethics

Written informed consent was obtained from the patients for publication of these case reports and the accompanying images. There was no need for institutional review board approval, as this was only a case report with a review and did not involve a study protocol.

Acknowledgement

The authors thank the patient for granting permission to publish this information.

References

- İremli BG, Şendur SN, Ünlütürk U. Three cases of subacute thyroiditis following SARS-CoV-2 Vaccine: post-vaccination ASIA syndrome. *J Clin Endocrinol Metab* 2021, <http://dx.doi.org/10.1210/clinem/dgab373> [dgab373].
- Bornemann C, Woyk K, Bouter C. Case report: two cases of subacute thyroiditis following SARS-CoV-2 vaccination. *Front Med* 2021;8:737142, <http://dx.doi.org/10.3389/fmed.2021.737142>.
- Jeeyavudeen MS, Patrick AW, Gibb FW, Dover AR. COVID-19 vaccine-associated subacute thyroiditis: an unusual suspect for de Quervain's thyroiditis. *BMJ Case Rep* 2021;14, <http://dx.doi.org/10.1136/bcr-2021-246425> [e246425].
- Oyibo SO. Subacute thyroiditis after receiving the adenovirus-vectored vaccine for Coronavirus Disease (COVID-19). *Cureus* 2021;13, <http://dx.doi.org/10.7759/cureus.16045> [e16045].
- Patel KR, Cunnane ME, Deschler DG. SARS-CoV-2 vaccine-induced subacute thyroiditis. *Am J Otolaryngol* 2021;43:103211, <http://dx.doi.org/10.1016/j.amjoto.2021.103211>.
- Plaza-Enriquez L, Khatiwada P, Sanchez-Valenzuela M, Sikha A. A case report of subacute thyroiditis following mRNA COVID-19 vaccine. *Case Rep Endocrinol* 2021;2021, <http://dx.doi.org/10.1155/2021/8952048> [8952048].
- Şahin Tekin M, Şaylısoy S, Yorulmaz G. Subacute thyroiditis following COVID-19 vaccination in a 67-year-old male patient: a case report. *Hum Vaccines Immunother* 2021;1–3, <http://dx.doi.org/10.1080/21645515.2021.1947102>.
- Saygılı ES, Karakılıç E. Subacute thyroiditis after inactive SARS-CoV-2 vaccine. *BMJ Case Rep* 2021;14, <http://dx.doi.org/10.1136/bcr-2021-244711> [e244711].
- Soltanpoor P, Norouzi G. Subacute thyroiditis following COVID-19 vaccination. *Clin Case Rep* 2021;9, <http://dx.doi.org/10.1002/ccr3.4812> [e04812].
- Schimmel J, Alba EL, Chen A, Russell M, Srinath R. Letter to the editor: thyroiditis and thyrotoxicosis after the SARS-CoV-2 mRNA vaccine. *Thyroid Off J Am Thyroid Assoc* 2021, <http://dx.doi.org/10.1089/thy.2021.0184>.
- Siolos A, Gartzonika K, Tigas S. Thyroiditis following vaccination against COVID-19: Report of two cases and review of the literature. *Metab Open* 2021;12:100136, <http://dx.doi.org/10.1016/j.metop.2021.100136>.
- Kyriacou A, Ioakim S, Syed AA. COVID-19 vaccination and a severe pain in the neck. *Eur J Intern Med* 2021, <http://dx.doi.org/10.1016/j.ejim.2021.10.008>.
- Pujol A, Gómez L-A, Gallegos C, Nicolau J, Sanchís P, González-Freire M, et al. Thyroid as a target of adjuvant autoimmunity/inflammatory syndrome due to mRNA-based SARS-CoV2 vaccination: from Graves' disease to silent thyroiditis. *J Endocrinol Invest* 2021, <http://dx.doi.org/10.1007/s40618-021-01707-0>.
- Ratnayake GM, Dworakowska D, Grossman AB. Can COVID-19 immunisation cause subacute thyroiditis? *Clin Endocrinol (Oxf)* 2021, <http://dx.doi.org/10.1111/cen.14555>.
- Franquemont S, Galvez J. Subacute thyroiditis after mRNA vaccine for Covid-19. *J Endocr Soc* 2021;5, <http://dx.doi.org/10.1210/jendso/bvab048.1954>.
- Stasiak M, Zawadzka-Starczewska K, Lewiński A. Significance of HLA haplotypes in two patients with subacute thyroiditis triggered by mRNA-Based COVID-19 vaccine. *Vaccines* 2022;10:280, <http://dx.doi.org/10.3390/vaccines10020280>.
- Stasiak M, Lewiński A. New aspects in the pathogenesis and management of subacute thyroiditis. *Rev Endocr Metab Disord* 2021, <http://dx.doi.org/10.1007/s1154-021-09648-y>.
- Sahin U, Muik A, Derhovanessian E, Vogler I, Kranz LM, Vormehr M, et al. COVID-19 vaccine BNT162b1 elicits human antibody and TH17 cell responses. *Nature* 2020;586:594–9, <http://dx.doi.org/10.1038/s41586-020-2814-7>.
- Sriprapradang C. Aggravation of hyperthyroidism after heterologous prime-boost immunization with inactivated and adenovirus-vectored SARS-CoV-2 vaccine in a patient with Graves' disease. *Endocrine* 2021;74:226–7, <http://dx.doi.org/10.1007/s12020-021-02879-8>.
- Sriprapradang C, Shantavasinkul PC. Graves' disease following SARS-CoV-2 vaccination. *Endocrine* 2021;74:473–4, <http://dx.doi.org/10.1007/s12020-021-02902-y>.
- Vera-Lastra O, Ordinola Navarro A, Cruz Domiguez MP, Medina G, Sánchez Valadez TI, Jara LJ. Two cases of Graves' Disease following SARS-CoV-2 vaccination: an autoimmune/inflammatory syndrome induced by adjuvants. *Thyroid Off J Am Thyroid Assoc* 2021;31:1436–9, <http://dx.doi.org/10.1089/thy.2021.0142>.
- Zettinig G, Krebs M. Two further cases of Graves' disease following SARS-Cov-2 vaccination. *J Endocrinol Invest* 2021, <http://dx.doi.org/10.1007/s40618-021-01650-0>.
- Pierman G, Delgrange E, Jonas C. Recurrence of Graves' Disease (a Th1-type Cytokine Disease) Following SARS-CoV-2 mRNA vaccine administration: a simple coincidence? *Eur J Case Rep Intern Med* 2021;8, <http://dx.doi.org/10.12890/2021.002807> [002807].
- Li Q, Wang B, Mu K, Zhang J-A. The pathogenesis of thyroid autoimmune diseases: New T lymphocytes - Cytokines circuits beyond the Th1-Th2 paradigm. *J Cell Physiol* 2019;234:2204–16, <http://dx.doi.org/10.1002/jcp.27180>.
- Gonzalez-Aguilera B, Betea D, Lutteri L, Cavalier E, Geenen V, Beckers A, et al. Conversion to Graves disease from Hashimoto thyroiditis: a study of 24 patients. *Arch Endocrinol Metab* 2018;62:609–14, <http://dx.doi.org/10.20945/2359-3997000000086>.

Florence Brès^a
Marie-Alix Joyeux^a
Brigitte Delemer^{a,b}
Géraldine Vitellius^a
Sara Barraud^{a,b,*}

^a Service d'Endocrinologie – Diabète – Nutrition, CHU de Reims, hôpital Robert-Debré, avenue du Général Koenig, 51092 Reims Cedex, France

^b CRESTIC EA 3804, université de Reims Champagne Ardenne, UFR Sciences Exactes et Naturelles, Moulin de la Housse, BP 1039, 51687 Reims Cedex 2, France

*Corresponding author at: Service d'endocrinologie – diabète – nutrition, CHU de Reims, hôpital Robert-Debré, avenue du Général Koenig, 51092 Reims Cedex, France.
E-mail address: sbarraud@chu-reims.fr (S. Barraud)

<https://doi.org/10.1016/j.ando.2022.04.014>

0003–4266 © 2022 Elsevier Masson SAS. All rights reserved.

An atypical alpelisib-induced hyperglycemic hyperosmolar and diabetic ketoacidosis state: A case report and critical analysis of alpelisib-induced hyperglycemia management guidelines



A 72-year-old woman was referred by her general practitioner to the emergency room on November 28th, 2020, for new-onset diabetes after presenting progressive polyuria and polydipsia for 10