



Endoscopic Ganglionectomy of Palmar Ganglion via Flexor Carpi Radialis Tendoscopy

Tun Hing Lui, M.B.B.S.(H.K.), F.R.C.S.(Edin.), F.H.K.A.M., F.H.K.C.O.S.

Abstract: Palmar ganglion is rare. Deep palmar ganglion usually arises from the wrist joint and may cause compression neuropathy. Superficial palmar ganglion may arise from the flexor tendons of the wrist. The chance of compression neuropathy is expected to be less than deep palmar ganglion. However, there is a higher chance of perforation through the skin and the ganglion may affect hand grip. Open resection of the ganglion does not require extensive deep soft tissue dissection. However, the skin incision can still be extensile to trace the stalk to the tendon of origin. The purpose of this Technical Note is to report the details of endoscopic ganglionectomy for superficial palmar ganglion arising from the flexor carpi radialis tendon.

Ganglions are common on the volar surface of the wrist because they often arise from radiocarpal or intercarpal joints.¹ The most volar ganglions present as painless masses at or proximal to the wrist crease.² Palmar ganglion is rare.^{1,3} It usually arises from the wrist joint and may cause compression neuropathy.^{1,4} Excision of deep palmar ganglion requires extensile incision to trace the proximal stalk to its joint of origin.^{1,4} However, palmar ganglion superficial to the palmar aponeurosis is expected to arise from superficial structures, for example, flexor tendons of the wrist. The chance of compression neuropathy is expected to be less than deep palmar ganglion. However, there is a higher chance of perforation through the skin and the ganglion may affect hand grip. Open resection of the ganglion does not require extensive deep soft tissue dissection. However, the skin incision can still be extensile to trace the stalk to the tendon of origin. Arthroscopic ganglionectomy of

wrist ganglia is a well-established approach.^{2,5,6} Techniques of tendoscopy of the wrist have been recently reported.^{7,8} This raises the possibility of endoscopic ganglionectomy for ganglia arising from the tendons of the wrist. In this Technical Note, endoscopic ganglionectomy of superficial palmar ganglion arising from the flexor carpi radialis tendon is reported. It is indicated for symptomatic superficial palmar ganglion of the flexor carpi radialis tendon. It is contraindicated for palmar ganglion deep to the transverse carpal ligament and the palmar aponeurosis or the ganglion arising from the other tendons of the wrist (Table 1).

Technique

Preoperative Planning and Patient Positioning

Preoperative magnetic imaging is useful to demonstrate the superficiality of the ganglion and study the relation of the ganglion with the flexor carpi radialis tendon (Fig 1). Any stenosing tenosynovitis or tendinosis of the flexor carpi radialis (FCR) tendon can be detected.

Table 1. Indications and Contraindications of Endoscopic Ganglionectomy of Palmar Ganglion via Flexor Carpi Radialis Tendoscopy

Indications	Contraindications
1. Symptomatic superficial palmar ganglion of the flexor carpi radialis tendon	1. Palmar ganglion deep to the transverse carpal ligament and the palmar aponeurosis 2. Ganglion arising from the other tendons of the wrist

From the Department of Orthopaedics and Traumatology, North District Hospital, Sheung Shui, NT, Hong Kong SAR, China.

The author reports that he has no conflicts of interest in the authorship and publication of this article. Full ICMJE author disclosure forms are available for this article online, as [supplementary material](#).

Received March 28, 2017; accepted June 1, 2017.

Address correspondence to Tun Hing Lui, M.B.B.S.(H.K.), F.R.C.S.(Edin.), F.H.K.A.M., F.H.K.C.O.S., Department of Orthopaedics and Traumatology, North District Hospital, 9 Po Kin Road, Sheung Shui, NT, Hong Kong SAR, China. E-mail: luithderek@yahoo.co.uk

© 2017 by the Arthroscopy Association of North America. Published by Elsevier. This is an open access article under the CC BY-NC-ND license (<http://creativecommons.org/licenses/by-nc-nd/4.0/>).

2212-6287/17398

<http://dx.doi.org/10.1016/j.eats.2017.06.002>

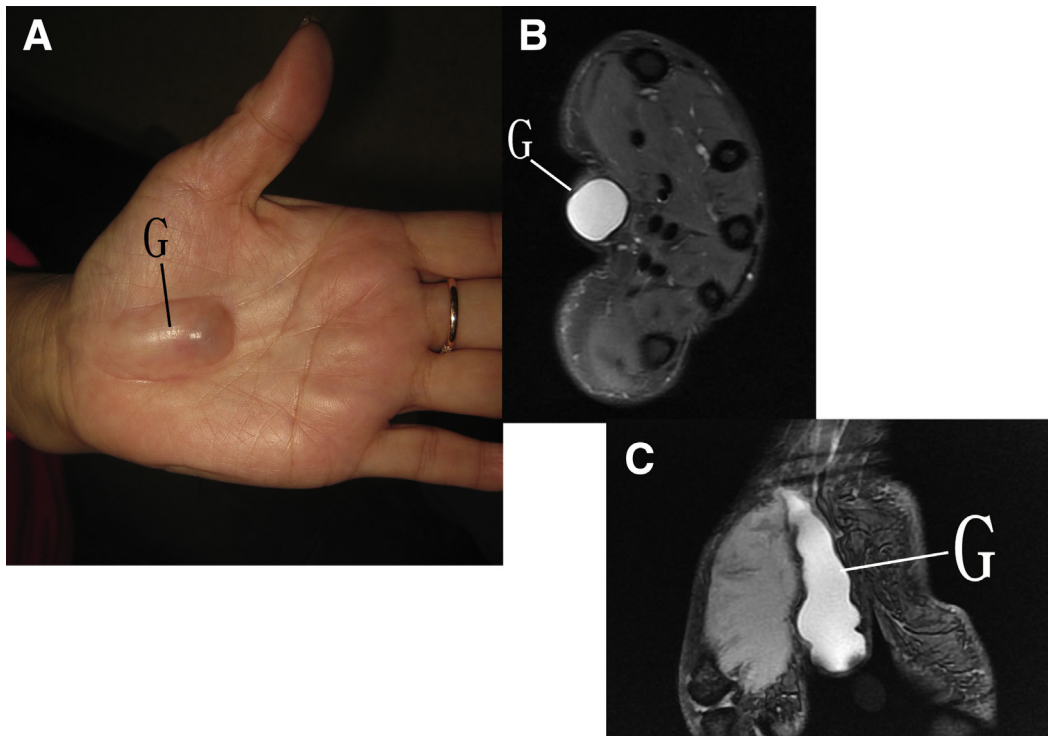


Fig 1. Endoscopic ganglionectomy of palmar ganglion of the left hand via flexor carpi radialis tendoscopy. The patient is in the supine position with the hand on the side table. (A) Clinical photograph of the illustrated case shows the palmar ganglion with near perforation at its distal end. (B) Transverse MRI view shows that the ganglion is superficial to the palmar aponeurosis. (C) Coronal MRI view shows the ganglion stalk arising from the FCR tendon. (FCR, flexor carpi radialis; G, palmar ganglion; MRI, magnetic resonance imaging.)

The patient is in the supine position with the hand on a side table. An arm tourniquet is applied to provide a bloodless operative field. A 2.7-mm 30° arthroscope (Henke Sass Wolf, Tuttlingen, Germany) is used for this procedure. Fluid inflow is by gravity and no arthropump is used.

Portal Placement

The proximal and distal portals are used for this procedure. The proximal portal is an FCR portal and is located over the FCR tendon and 2 to 3 cm proximal to

the volar joint line of the radiocarpal joint. The distal portal is the ganglion portal. Ideally, it is located at the distal end of the ganglion. The location of the portal is modified and placed more proximally to avoid the nearly perforated part of the ganglion.

Enlargement of the Communication Between the Ganglion Sac and the Flexor Carpi Radialis Tendon Sheath

A 3- to 4-mm longitudinal incision is made at the proximal portal. The subcutaneous tissue is bluntly

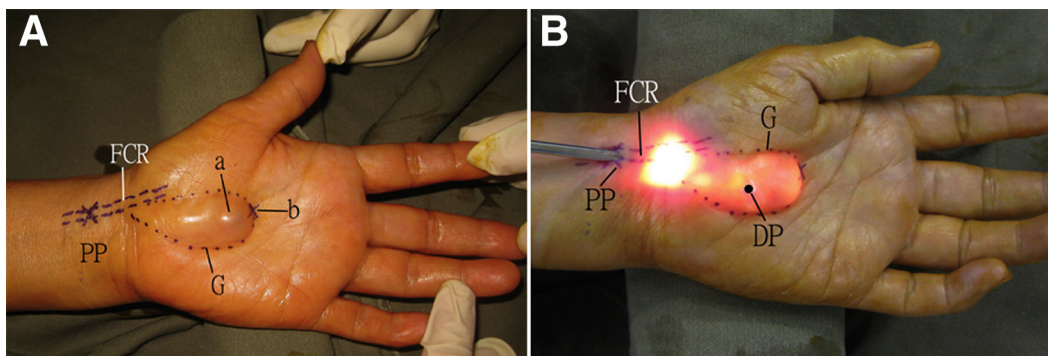


Fig 2. Endoscopic ganglionectomy of palmar ganglion of the left hand via flexor carpi radialis tendoscopy. The patient is in the supine position with the hand on the side table. (A) The flexor carpi radialis (FCR) tendon and palmar ganglion (G) are outlined. The proximal portal (PP) locates over the FCR tendon and 2 to 3 cm proximal to the volar joint line of the radiocarpal joint. a: near perforation of the ganglion; b: ideal distal portal, which is at the distal end of the ganglion. (B) The arthroscope is inserted via the proximal portal and the ganglion sac is lightened. The distal portal (DP) is then located.

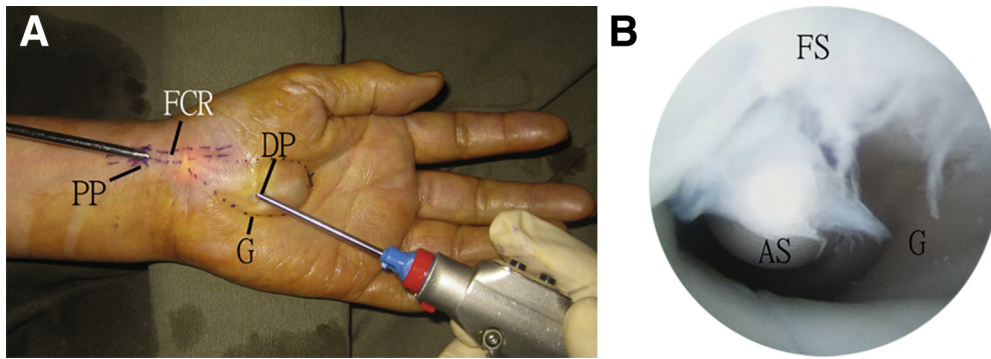


Fig 3. Endoscopic ganglionectomy of palmar ganglion of the left hand via flexor carpi radialis tendoscopy. The patient is in the supine position with the hand on the side table. (A) The proximal portal (PP) is the viewing portal and the distal portal (DP) is the working portal. (B) The communication between the FCR fascia tendon sheath (FS) and the ganglion sac (G) is enlarged by an arthroscopic shaver (AS). (FCR, flexor carpi radialis.)

dissected with a hemostat. The deep fascia is incised open to expose the FCL tendon. The arthroscope is inserted and the ganglion sac is lightened (Fig 2). Another 3- to 4-mm longitudinal incision is made at the distal portal. The ganglion sac is perforated by the tip of the hemostat. With the proximal portal as the viewing portal, the stalk of the ganglion is resected by an arthroscopic shaver (Dyonics, Smith & Nephew, Andover, MA) via the distal portal. The communication between the FCR tendon sheath and the ganglion sac is enlarged (Fig 3). This can eliminate the valvular mechanism of the ganglion.

Resection of the Distal Part of the Ganglion Sac

The proximal portal is the viewing portal. The distal part of the ganglion is resected with the shaver via the distal portal (Fig 4). The resection is started at the radial and ulnar sides of the ganglion sac. It is not aimed at complete resection of the sac. The most distal part of the sac that is nearly perforated through the skin should be preserved to avoid iatrogenic perforation of the skin or disturbance of the dermal vascular plexus. The shaver can be placed at the center of the sac and full suction is applied. The freely mobile portion of the sac can be sucked into the shaver orifice and resected by the shaver. The deep part of the ganglion sac that is stuck onto the palmar aponeurosis should be preserved to avoid damage to the deep structures.

Resection of the Proximal Part of the Ganglion Sac

After resection of the distal portion of the ganglion sac, the arthroscope is advanced distally and exited through the distal portal. The scope is removed and the cannula is left in situ. A 2.7-mm Wissinger rod is inserted into the cannula. The cannula is removed and reinserted along the rod via the distal portal (Fig 5). With the distal portal as the viewing portal, the proximal portion of the ganglion sac is resected by the shaver via the proximal portal (Fig 6). The resection should be started from the distal cut end of the sac and

performed proximally. The part of the ganglion sac tightly stuck on the transverse carpal ligament should be preserved to avoid damage to the palmar cutaneous branch of the median nerve.

Synovectomy and Release (Optional) of the Flexor Carpi Radialis Longus Tendon

After ganglionectomy, the arthroscope is advanced proximally to the FCR tendon. Flexor carpi radialis tendoscopy is performed and any inflamed synovium is resected with the shaver via the proximal portal. The tendon is traced distally to the fibro-osseous tunnel at

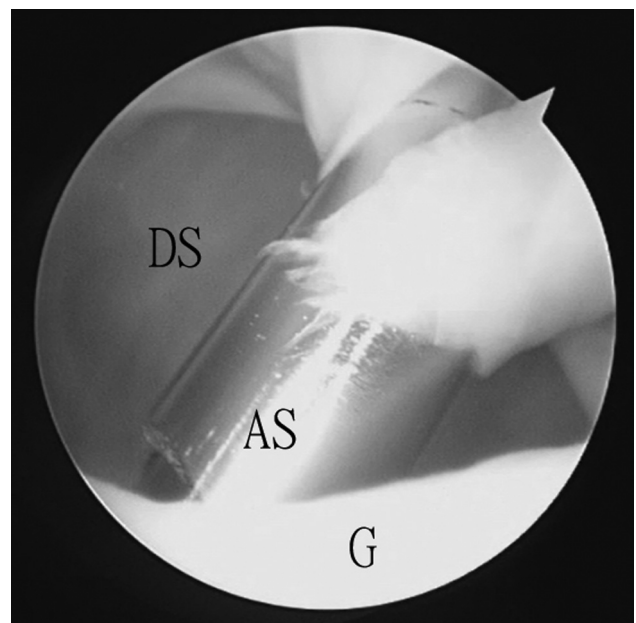


Fig 4. Endoscopic ganglionectomy of palmar ganglion of the left hand via flexor carpi radialis tendoscopy. The patient is in the supine position with the hand on the side table. The proximal portal is the viewing portal. The distal part of the ganglion (G) is resected with the arthroscopic shaver (AS) via the distal portal. (DS, distal part of the ganglion sac that is nearly perforated through the skin.)

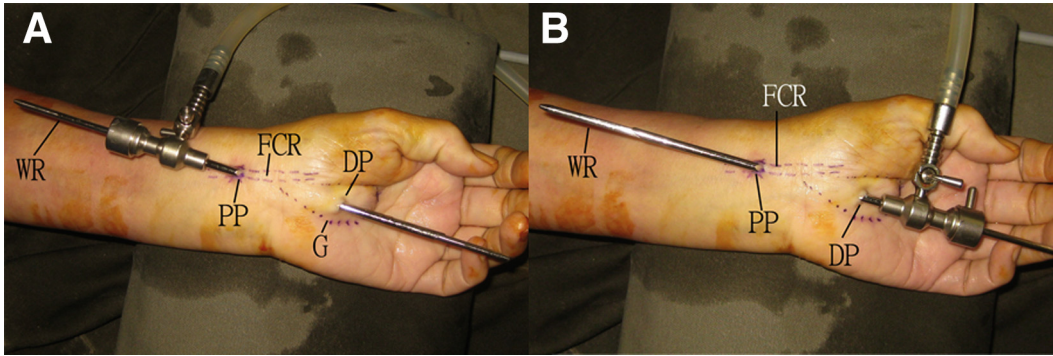


Fig 5. Endoscopic ganglionectomy of palmar ganglion of the left hand via flexor carpi radialis tendoscopy. The patient is in the supine position with the hand on the side table. Switch of the viewing and working portals. After resection of the distal portion of the ganglion sac. (A) The arthroscope is advanced distally and exited through the distal portal. The scope is removed and the cannula is left in situ. A 2.7-mm Wissinger rod is inserted into the cannula. (B) The cannula is removed and reinserted along the rod via the distal portal. (DP, distal portal; FCR, flexor carpi radialis; G, ganglion; PP, proximal portal; WR, Wissinger rod.)

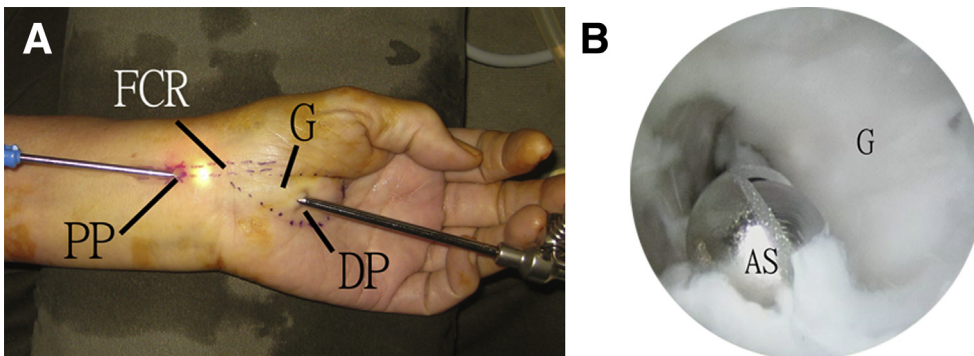


Fig 6. Endoscopic ganglionectomy of palmar ganglion of the left hand via flexor carpi radialis tendoscopy. The patient is in the supine position with the hand on the side table. (A) The distal portal is the viewing portal and the proximal portal is the working portal. (B) The proximal portion of the ganglion sac is resected by the arthroscopic shaver. (AS, arthroscopic shaver; DP, distal portal; FCR, flexor carpi radialis tendon; G, ganglion; PP, proximal portal.)

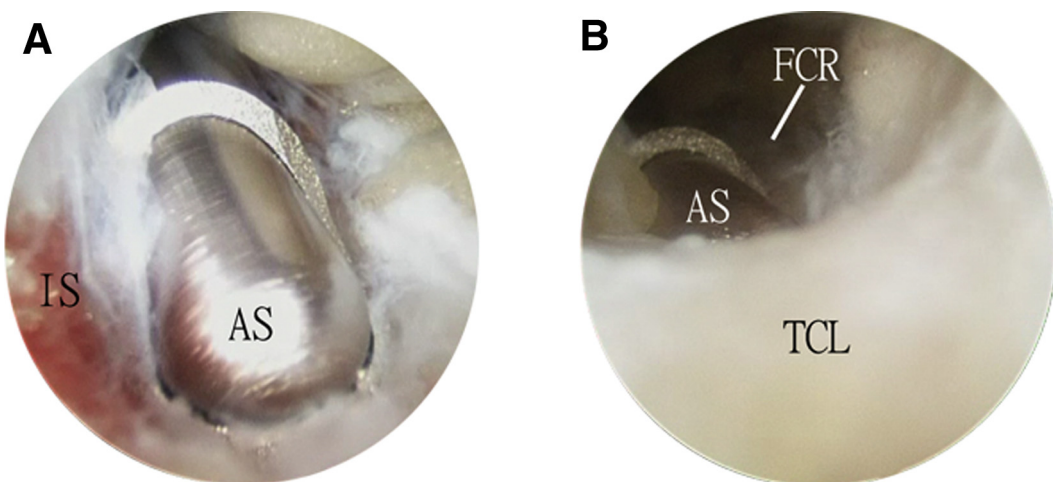


Fig 7. Endoscopic ganglionectomy of palmar ganglion of the left hand via flexor carpi radialis tendoscopy. The patient is in the supine position with the hand on the side table. The distal portal is the viewing portal and the proximal portal is the working portal. (A) After ganglionectomy, the arthroscope is advanced proximally to the FCR tendon. Flexor carpi radialis tendoscopy is performed and any inflamed synovium (IS) is resected with the arthroscopic shaver (AS) via the proximal portal. (B) The tendon is traced distally to the fibro-osseous tunnel at the wrist. The overlying transverse carpal ligament can be released if stenosing tenosynovitis is confirmed. (FCR, flexor carpi radialis tendon; TCL, transverse carpal ligament.)

Table 2. Pearls and Pitfalls of Endoscopic Ganglionectomy of Palmar Ganglion via Flexor Carpi Radialis Tendoscopy

Pearls	Pitfalls
1. The ganglion sac can be lightened by the arthroscope via the proximal portal. This can help determination of the distal portal and avoid placing the portal at the near perforated part of the ganglion or the subcutaneous vessels	1. Debridement of the flexor carpi radialis tendon sheath should be carefully performed so as not to injure the nearby median nerve and radial artery
2. The part of the ganglion sac at the nearly perforated part of the ganglion and over the transverse ligament should be preserved	2. Pathology of the flexor carpi radialis tendon distal to the transverse carpal ligament is not accessible through this approach

the wrist. The overlying transverse carpal ligament can be released if stenosing tenosynovitis is confirmed (Fig 7, Video 1, Table 2). After the procedure, the wounds are closed with simple suture (Fig 8) and a bulky dressing is applied for 2 to 4 weeks.

Discussion

Endoscopic ganglionectomy can have 2 approaches: endoscopic resection of the ganglion and endoscopic internal drainage of the ganglion.⁹ In this reported technique, both approaches are used. It is because the flexor tendon may not be a good site of internal drainage as compared with the wrist joint because of the limited synovial lining to absorb the content of the ganglion. Complete resection of the ganglion sac is also not possible without the risk of iatrogenic skin perforation and damage to the palmar cutaneous branch of the median nerve. The combined internal drainage and ganglion resection hopefully can reduce the risk of recurrence.

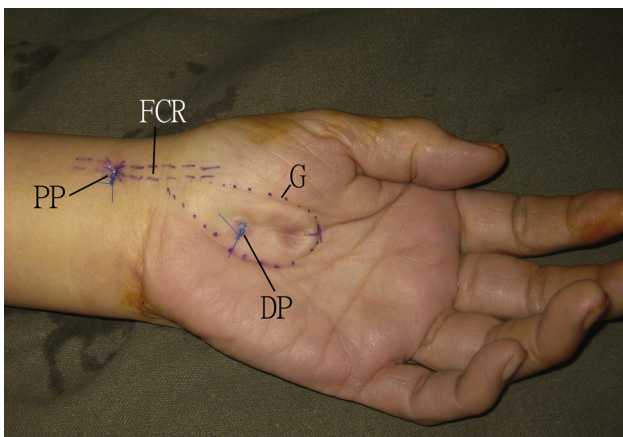


Fig 8. Endoscopic ganglionectomy of palmar ganglion of the left hand via flexor carpi radialis tendoscopy. The patient is in the supine position with the hand on the side table. The ganglion is collapsed. The portal incisions are closed with simple suture. (DP, distal portal; FCR, flexor carpi radialis tendon; G, ganglion; PP, proximal portal.)

Table 3. Advantages and Risks of Endoscopic Ganglionectomy of Palmar Ganglion via Flexor Carpi Radialis Tendoscopy

Advantages	Risks
1. Less wound complication	1. Recurrence of the ganglion
2. Less soft tissue trauma	2. Injury to the FCR tendon
3. Better cosmesis	3. Injury to the radial artery
4. No wound retraction needed, low risk of skin necrosis	4. Injury to the median nerve
5. Avoidance of scar across the wrist creases	5. Injury to the palmar cutaneous branch of the median nerve
6. Possibility of managing concomitant pathology of the FCR tendon	6. Iatrogenic skin perforation

FCR, flexor carpi radialis.

This approach can also be used to deal with other pathology of the FCR tendon including stenosing tenosynovitis. However, pathology of the tendon distal to the transverse carpal ligament cannot be dealt with because it is not accessible through the distal portal.

The advantages of this minimally invasive approach include better cosmesis, less soft tissue dissection, no wound retraction needed, low risk of skin necrosis, avoidance of scar across the wrist creases, and the possibility of managing concomitant pathology of the FCR tendon. The potential risk of this procedure includes recurrence of the ganglion, injury to the FCR tendon, radial artery, median nerve, palmar cutaneous branch of the median nerve, and iatrogenic skin perforation (Table 3).

References

- Cornwall R, Koris MJ, Jupiter JB. Wrist joint ganglion presenting as a painless mass in the palm: Report of 2 cases. *J Hand Surg Am* 2004;29:289-292.
- Gallego S, Mathoulin C. Arthroscopic resection of dorsal wrist ganglia: 114 cases with minimum follow-up of 2 years. *Arthroscopy* 2010;26:1675-1682.
- Kato H, Ogino T, Nanbu T, Nakamura K. Compression neuropathy of the motor branch of the median nerve caused by palmar ganglion. *J Hand Surg Am* 1991;16:751-752.
- Margles SW. Palmar ganglion producing diminished sensation in the distribution of the radial digital nerve of the thumb: A case not previously reported. *Plast Reconstr Surg* 1994;93:1512-1513.
- Osterman AL, Raphael JS. Arthroscopic resection of dorsal ganglion of the wrist. *Hand Clin* 1995;11:7-12.
- Ho PC, Lo WN, Hung LK. Arthroscopic resection of volar ganglion of the wrist: A new technique. *Arthroscopy* 2003;19:218-221.
- Lui TH. Extensor tendoscopy of the wrist. *Arthrosc Tech* 2016;5:e751-e756.
- Lui TH. Flexor pollicis tendoscopy. *Arthrosc Tech* 2017;6:e249-e254.
- Lui TH. Arthroscopic ganglionectomy of the foot and ankle. *Knee Surg Sports Traumatol Arthrosc* 2014;22:1693-1700.