

A rare cause of abdominal pain: Mesenteric panniculitis

 Tolga Duzenli,  Huseyin Koseoglu

Department of Gastroenterology, Hitit University Erol Olcok Training and Research Hospital, Corum, Turkey

Cite this article as: Duzenli T, Koseoglu H. A rare cause of abdominal pain: Mesenteric panniculitis. North Clin Istanbul 2021;8(2):186.

A 54-year-old woman presented to the emergency department with complaint of abdominal pain lasting for 3 days. Her abdominal pain was in the epigastric region spreading to the left lower quadrant. Oral and IV contrasted abdominal computed tomography (CT) revealed inflammation surrounded by heterogeneous pseudocapsule in the mesenteric fatty tissue starting from the mesenteric root. This inflammation encircled the mesenteric artery and veins and there was a fat halo sign around the vein (Fig. 1). The patient's condition significantly improved with conservative treatment including antibiotics (ceftriaxone i.v.) and nonsteroidal anti-inflammatory drugs (NSAIDs) (diclofenac i.m.).

Mesenteric panniculitis is a rare, chronic inflammatory disease observed in mesentery. Histopathologically, the mesentery exhibits fat necrosis, acute/chronic inflammation, and fibrosis. Etiology is not clear, and its prevalence is 0.16–7.8% [1]. It is frequently seen between the ages of 50 and 60. Mostly, small intestine mesentery is affected. The most common symptoms are abdominal pain, nausea, vomiting, and fullness. The disease is usually self-limited but can progress to small bowel obstruction, ischemia, and superior mesenteric venous thrombosis. This rare disease is usually diagnosed incidentally. Abdominal CT is typically diagnostic without the need for a biopsy [2].

Abdominal CT findings are characteristic for the diagnosis. Therefore, unnecessary biopsy or surgical procedures should be avoided. In symptomatic and progressive patients, steroids and immunosuppressive treatments may be required. However, usually conservative management with antibiotics and NSAIDs is satisfactory in most patients.

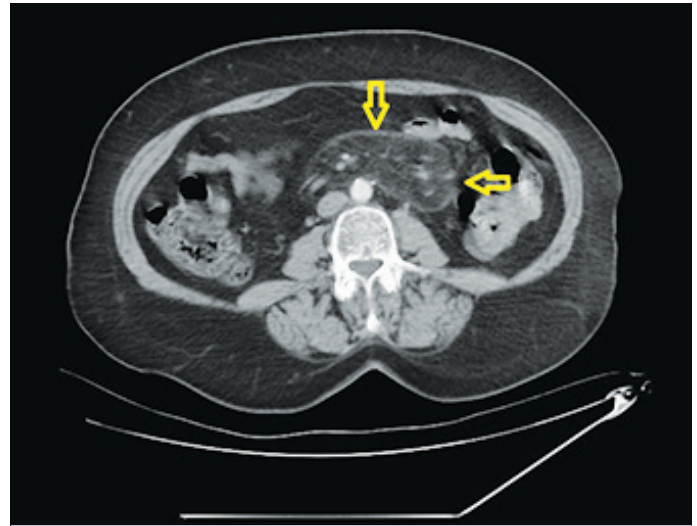


FIGURE 1. Inflammation surrounded by heterogeneous pseudocapsule in the mesenteric fatty tissue starting from the mesenteric root. This inflammation encircled the mesenteric artery and veins and there was a fat halo sign.

Informed Consent: Written informed consent was obtained from the patient for the publication of the case report and the accompanying images.

REFERENCES

1. van Putte-Katier N, van Bommel EF, Elgersma OE, Hendriksz TR. Mesenteric panniculitis: prevalence, clinicoradiological presentation and 5-year follow-up. Br J Radiol 2014;87:20140451.
2. van Breda Vriesman AC, Schuttevaer HM, Coerkamp EG, Puy-laert JB. Mesenteric panniculitis: US and CT features. Eur Radiol 2004;14:2242–8.

Received: July 01, 2020 Accepted: November 05, 2020 Online: February 25, 2021

Correspondence: Tolga DUZENLI, MD. Hitit Universitesi Erol Olcok Egitim ve Arastirma Hastanesi, Gastroenteroloji Klinigi, Corum, Turkey.

Tel: +90 364 219 30 00 e-mail: tolgaduzenli@yahoo.com

© Copyright 2021 by Istanbul Provincial Directorate of Health - Available online at www.northclinist.com

