

Role of Brain Perfusion SPECT with ^{99m}Tc HMPAO in the Assessment of Response to Drug Therapy in Patients with Autoimmune Vasculitis: A Prospective Study

Liberatore Mauro, Morreale Manuela¹, Megna Valentina, Collorone Sara², Sotirios Chondrogiannis³, Drudi Francesco Maria, Anagnostou Christos, Civitelli Liana, Francia Ada², Anna Margherita Maffione³, Maria Cristina Marzola³, Domenico Rubello³

Departments of Radiological, Oncological and Anatomic-Pathological Sciences,¹Medical and Surgical Sciences and Biotechnologies, Section of Neurology, Neuropsychology Outpatients Service, ²Department of Neurology and Psychiatry, University of Rome "Sapienza", Rome, ³Department of Nuclear Medicine, Santa Maria della Misericordia Hospital, Rovigo, Italy

Abstract

Background: The diagnosis of vasculitis in the brain remains a quite difficult achievement. To the best of our knowledge, there is no imaging method reported in literature which is capable of reaching to a diagnosis of vasculitis with very high sensitivity. **Aim:** The aim of this study was to determine whether perfusion brain single photon emission computed tomography (SPECT) can be usefully employed in monitoring the treatment of vasculitis, allowing treating only potentially responder patients and avoiding the side effects on patients who do not respond. **Materials and Methods:** Twenty patients (two males and 18 females) suffering from systemic lupus erythematosus (SLE; $n = 5$), Behcet's disease (BD; $n = 5$), undifferentiated vasculitis (UV; $n = 5$), and Sjogren's syndrome (SS; $n = 5$) were included in the study. All patients underwent a wide neurological anamnestic investigation, a complete objective neurological examination and SPECT of the brain with ^{99m}Tc-hexamethyl-propylene-aminoxime (HMPAO). The brain SPECT was then repeated after appropriate medical treatment. The neurological and neuropsychiatric follow-up was performed at 6 months after the start of the treatment. **Results:** Overall, the differences between the scintigraphic results obtained after and before the medical treatment indicated a statistically significant increase of the cerebral perfusion (CP). In 19 out of 200 regions of interest (ROI) studied, the difference between pre- and post treatment percentages had negative sign, indicating a worsening of CP. This latter event has occurred six times (five in the same patients) in the UV, 10 times (eight in the same patients) in the SLE, never in BD, and three times (two in the same patient) in the SS. **Conclusion:** The reported results seem to indicate the possibility of identifying, by the means of a brain SPECT, responder and nonresponder (unchanged or worsened CP) patients, affected by autoimmune vasculitis, to the therapy.

Keywords: Autoimmune vasculitis, brain perfusion, central nervous system, HMPAO, SPECT, therapy

Address for correspondence: Dr. Mauro Liberatore, Dip. di Scienze Radiologiche, Oncologiche ed Anatomico-Patologiche, Policlinico Umberto I, Viale regina Elena, 324, Roma-00161, Italy. E-mail: maurilib@tin.it

Introduction

Central nervous system (CNS) can be involved during several autoimmune systemic vasculitis. Neurological and neuropsychiatric manifestations are still object of debate in literature. It has been estimated that the prevalence of CNS involvement during vasculitis may vary from 2.5 to 60%, depending on the reported experiences and tests of evaluation.^[1-3]

Access this article online

Quick Response Code:



Website:
www.najms.org

DOI:
10.4103/1947-2714.156008

This is particularly true in cases of early impairment in which a mild cognitive impairment (MCI) can be the only symptom.^[4,5] Often CNS involvement can precede clinical diagnosis by many years and determine an underestimation of other neurological and/or systemic diseases.^[6] Moreover, prompt diagnosis and treatment could significantly ameliorate neurological symptoms and improve prognosis. The most commonly applied radiologic techniques, such as computed tomography (CT) and magnetic resonance imaging (MRI), are not enough sensitive to reflect the pathophysiological changes happening in CNS during vasculitis. Also cerebral angiography is characterized by a low sensitivity and is burdened by some risk.^[7,8]

Therefore, more sensitive diagnostic techniques which are able to assess CNS subclinical involvement is advisable, especially for patients with atypical neurologic and neuropsychiatric manifestations or patients at a very early stage of disease. According to literature,^[9,10] single photon emission computed tomography (SPECT) is more sensitive than MRI in revealing damage in CNS related to vasculitis; moreover, SPECT seems able to provide additional information during follow-up, especially in the monitoring phase of the disease severity and treatment.^[11-17]

The purpose of this study was to determine whether brain SPECT using ^{99m}Tc-hexamethyl-propylene-aminoxime (HMPAO) as radiocompound can be usefully employed in monitoring the treatment of vasculitis, allowing selection patients with high likelihood to obtain benefit from specific treatment, and at the same time avoid side effects on nonresponder patients.

Materials and Methods

Patients

The present research has been approved by our Institutional Ethics Committee. Moreover, all patients gave their informed consent before entering the study.

The study was performed on 20 prospectively and consecutive enrolled patients, affected by autoimmune vasculitis and adopting the following inclusion criteria:

1. Age less than 45 years;
2. negative brain MRI;
3. presence of nonspecific neurological and neuropsychiatric symptoms (headache, disorders' attention, and so forth);
4. no previous treatments (corticosteroids) for at least 3 months, and
5. time from disease diagnosis less than 5 years.

On this basis, 20 patients (2 males and 18 females) were recruited: Five were affected by systemic lupus

erythematosus (SLE), five by Behcet's disease (BD), five by undifferentiated vasculitis (UV), and five by Sjogren's syndrome (SS). The mean age of patients was 36.3 years (standard deviation (SD) ± 10.6 years) and the mean disease duration was 1.77 years (SD ± 0.83).

Clinical, psychiatric, and neuropsychological evaluation

All patients underwent neurological history and physical examination. Moreover, various serological tests were taken into account.

Specific subjective symptoms were evaluated with appropriate tools as presented in Table 1.

The Second Edition of the International Classification of Headache Disorders (ICHD-II) was applied to establish a headache diagnosis and score.^[18]

The psychiatric assessment was based on history and clinical interview focused on:

- a. Current or past psychopathological disorders;
- b. structure of the personality; and
- c. signs and symptoms of reactive disorders to chronic illness, steroids, or disease-modifying (biological) therapies.

Moreover, all patients underwent a global screening test using the Clinical Global Impression Severity Scale (CGIs) and following specific tests to detect possible behavioral correlates of executive functions: Beck Depression Scale II (BDII), State-Trait Anxiety Inventory Y1 and Y2 (STAY), and Apathy Evaluation Scale (AES). Basal cognitive evaluation was evaluated by Mini-Mental State Examination (MMSE) for cognitive efficiency and Brief Intelligence Test (TIB) for intelligent quotient (IQ). Regardless of screening tests, all patients underwent a complete neuropsychological assessment in order to explore the main cognitive domains by means of:

Table 1: Mean and standard deviation (SD) of the percentage of the maximum count rate registered on the encephalon, calculated for all the region of interest selected: Comparison between the values obtained before and after the medical treatment

Calculated parameters	UV	SLE	BD	SS
Mean ± SD (pretreatment)	59±6	59±4	60±5	55±2
Mean ± SD (post treatment)	63±5	62±5	65±4	57±2
T	6.259	5.03	10.122	7.52
P	<0.001	<0.001	<0.001	<0.001

SLE = Systemic lupus erythematosus, BG = Behcet's disease, UV = Undifferentiated vasculitis, SS = Sjogren's syndrome

- Verbal span;
- Trail Making Test (parts A & B);
- Rey Auditory Verbal Learning Test;
- the Rey-Osterrieth Complex Figure Test (ROCF) (with immediate and delayed recall);
- Test of Weights and Measures Estimation (STEP);
- Test of Phonological Verbal Fluency/Semantics;
- Corsi Block Tapping Test; Tower of London - Italian version;
- Token Test; and
- Achener Aphasia Test. Raw scores have been adjusted for age, sex, and education parameters.

Scintigraphic studies

All patients were prescribed to suspend the intake of coffee, alcohol, and tobacco at least 48 h before scintigraphic examination. All were evaluated by brain SPECT using ^{99m}Tc -HMPAO as radiocompound. ^{99m}Tc -HMPAO is a lipophilic radiopharmaceutical used for the assessment of cerebral perfusion (CP). This product was prepared using a commercial kit (Ceretek®, GE Healthcare Italy, Milan) to which was added $740 \div 1110$ MBq of ^{99m}Tc -pertechnetate in 2 ml of saline. The radiopharmaceutical was administered to patients intravenously 15 min after its preparation. After injection, the patient was placed on the bed of the gamma-camera and kept away from light and sound stimulation for 15 min. Forty minutes later, patient head was fixed in the orbitomeatal line position by a hemicylindrical plastic head-holder to maintain immobilization during acquisition.

Brain SPECT was performed by a dual-head, large field of view gamma camera (Infinia®, GE Healthcare Italy, Milan) equipped with a couple of high-resolution, low-energy parallel holes collimators.

Acquisition was performed on a circular orbit of 360° , applying the smallest possible radius, with sampling angle of about 3° and a time of 25 s per projection, with acquisition matrix 128×128 . The energy window was positioned on the peak of ^{99m}Tc ($140 \text{ keV} \pm 10\%$). Image reconstruction was performed using filtered back projection with a Butterworth filter and a ramp filter. Transaxial, coronal, and sagittal sections, oriented along the orbitomeatal line, were then generated. Image analysis was performed using a specific software (Neurogam®, GE Healthcare Italy, Milan) capable of providing for each cerebral area the mean and the SD of the counts recorded expressed as a percentage of the maximum count rate registered on the encephalon. Ten regions of interest (ROI) were selected for each patient, corresponding to the entire cortex and the parietal, temporal, frontal, and occipital regions. The brain SPECT was then repeated after appropriate medical treatment

and the data of the second test were compared with those of the first, for each group of pathology, subtracting the pre-treatment values from those post-treatment.

Statistical methods

Mean values were statistically compared by *t*-test and differences in number of groups' values by chi-square test. *P* - value less than 0.05 were statistically considered as significant. Version 17.0 of Statistical Package for Social Sciences (SPSS) software (SPSS Inc, Chicago, Illinois, USA, 2008) was used.

Results

Clinical, psychiatric and neuropsychological evaluation

According to imaging and neurological evaluations, nonfocal and subclinical CNS involvement was observed in all patients. Particularly, headache was the most frequent observed symptom occurring in 14 patients (70%). Cognitive impairment was observed in 11 patients (55%); five patients (25%) had sensitive disorders and pain, seven (35%) had fatigue, eight (40%) had mood disorders, and only one patient (0.5%) had seizures [Figure 1]. None of the patients showed focal neurological deficits. Headache was defined on the basis of the ICHD-II diagnostic criteria. The most frequently observed headache (71.4% of the patients, $n = 10$) satisfied ICHD-II criteria for migraine without aura (MWO) with generally unilateral pain; oppressive-throbbing type and moderate-to-severe intensity; worsened by physical activity; and associated with nausea, photophobia, and phonophobia. From the cognitive point of view, 55% ($n = 11$) of the patients enrolled presented an impairment of at least one neuropsychological tests used. Between the explored functions, the most compromised were executive functions and verbal memory, significantly

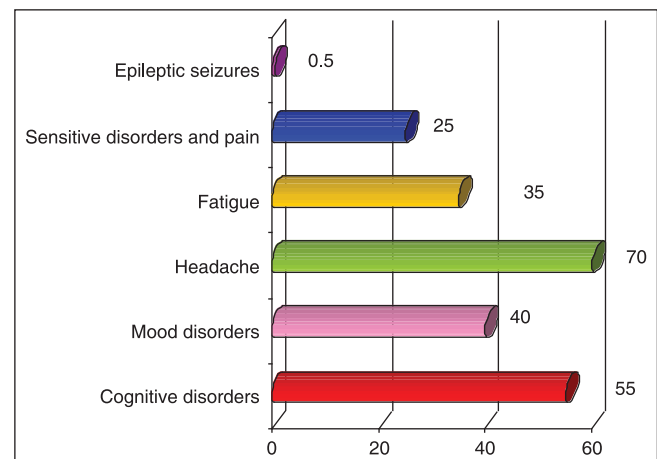


Figure 1: Percentage of central nervous system manifestations occurred in our patients

altered in 66.7% ($n = 8$) patients. On the basis of psychiatric evaluation, 40% ($n = 8$) of patients showed a score higher than 14 on the BDI-II as in depressive disorder, while STAY Y1 and Y2 were pathological in 15% ($n = 3$) and 0.5% ($n = 1$) of cases, respectively. A high score on the AES was observed in 30% of patients ($n = 6$).

After the execution of the clinical evaluations and the first scintigraphy, all patients started treatment on the basis of rheumatologist antivasculitis prescription. All patients received corticosteroids, at doses ranging from 5 to 25 mg/day. Five patients (25%) were given also ticlopidine, five (25%) colchicines, and eight (40%) chloroquine.

The neurological and neuropsychiatric follow-up was performed at 12 months after the beginning of the treatment. At this time, five patients (25%) (two patients with UV, two patients with SLE, and one patients with SS) showed worsening in clinical and neuropsychiatric evaluations in spite of treatment, whereas the other an amelioration.

Scintigraphic studies

In most cases, the differences between the percentages (of the maximum count rate registered on the brain) calculated after and before medical treatment by means of ROI method had positive signs, indicating an increase of the CP. In 19 of the 200 ROIs studied, the difference between pre- and post treatment percentages had negative sign, indicating a worsening of CP. This latter event has occurred six times (five in the same patients) in the UV [Figure 2], 10 times (eight in the same patients) in the SLE [Figure 3], never in BD [Figure 4], and three times (two in the same patient) in the SS [Figure 5]. The number of areas

that showed no variations between the SPECT performed before and after the treatment was as follows: Five areas in UV, seven areas in SLE, 0 in BD, and 6 in SS.

The scintigraphic results are summarized in Table 1, which shows the overall means and SDs calculated on the areas of interest for each disease. In the same table can be seen as the differences between the values obtained before and those obtained after treatment are statistically significant.

Discussion

Vasculitis is an inflammation of the walls of blood vessels. This inflammatory process can occur without known cause (primary vasculitis), or secondarily as a result of an infectious process, or in combination with other conditions. In vasculitis, the immune system is overactive and mistakenly recognizes the blood vessel cells as foreign and dangerous, so it attacks them as they were a bacterium or a virus. It is not always clear why this happens, but an infection, certain types of cancer and immune system disorders, certain medications, or an allergic reaction often act as a trigger. The inflammatory process leads to changes in the walls of blood vessels, narrowing the lumen of the vessels and reducing the amount of blood that reaches tissues and organs. In some cases, in an affected vessel may occur a thrombus or a granuloma, which obstructs the blood flow. Other times, instead of narrowing the vessel, vasculitis weakens the blood vessel, resulting in the occurrence of an aneurysm.

The use of brain ^{99m}Tc -HMPAO SPECT in the early diagnosis of vasculitis has been widely reported in

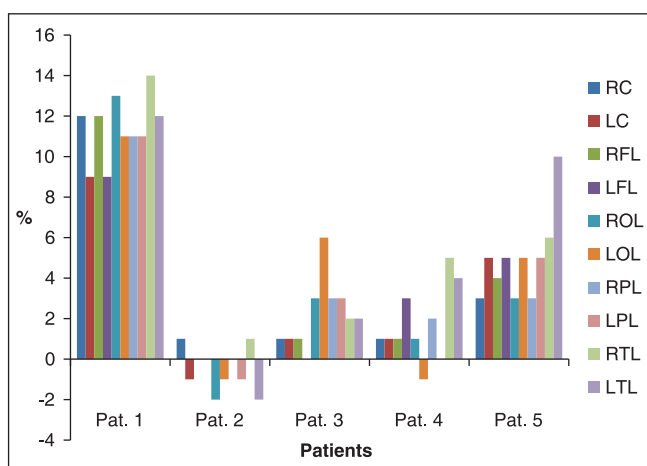


Figure 2: Percentage increase of the radiopharmaceutical uptake after medical treatment in patients with undifferentiated vasculitis. RC = Right cortex, LC = Left cortex, RFL = Right frontal lobe, LFL = Left frontal lobe, ROL = Right occipital lobe, LOL = Left occipital lobe, RPL = Right parietal lobe, LPL = Left parietal lobe, RTL = Right temporal lobe, LTL = Left temporal lobe

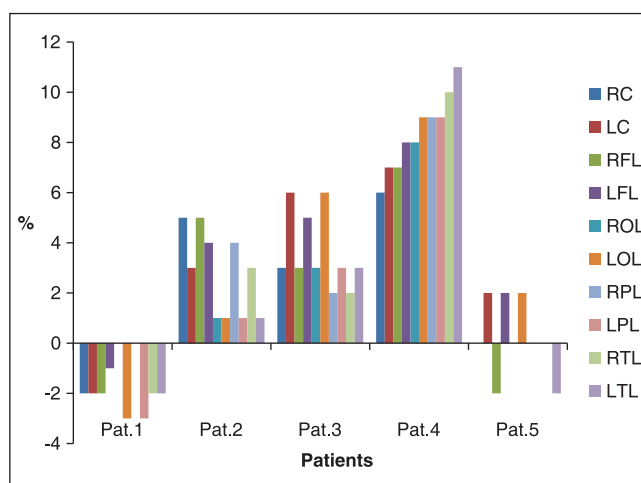


Figure 3: Percentage increase of the radiopharmaceutical uptake after medical treatment in patients with systemic lupus erythematosus (SLE) RC = Right cortex, LC = Left Cortex, RFL = Right frontal lobe, LFL = Left frontal lobe, ROL = Right occipital lobe, LOL = Left occipital lobe, RPL = Right parietal lobe, LPL = Left parietal lobe, RTL = Right temporal lobe, LTL = Left temporal lobe

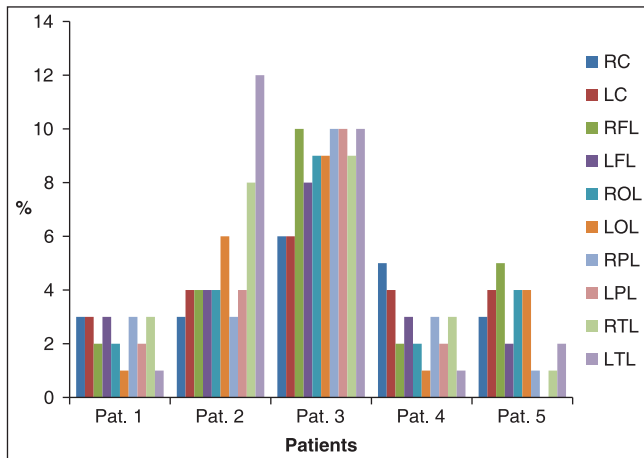


Figure 4: Percentage increase of the radiopharmaceutical uptake after medical treatment in patients with Behcet's disease RC = Right cortex, LC = Left Cortex, RFL = Right frontal lobe, LFL = Left frontal lobe, ROL = Right occipital lobe, LOL = Left occipital lobe, RPL = Right parietal lobe, LPL = Left parietal lobe, RTL = Right temporal lobe, LTL = Left temporal lobe

the literature since the 1990s. In 1996, Meusser *et al.*,^[19] studied 40 patients affected by systemic vasculitis, finding SPECT abnormalities both in patients with major (motoric or sensible defects) or mild (headache or cognitive disorders) neuropsychiatric symptoms both in patients with none of these symptoms.

Similar results were obtained, some years after, in another study carried out in 78 patients affected by SLE.^[20] In that study, patients were divided into two groups: Group 1 including 48 cases with definite neuropsychiatric symptoms and Group 2 consisting of 30 cases having no neuropsychiatric symptoms. Ninety percent of the patients of Group 1 and 20% of those of Group 2 showed brain hypoperfusion areas.

99mTc-HPAO brain SPECT was found to be useful for detecting subclinical perfusion abnormalities also in patients affected by BD.^[21] In these study, SPECT revealed abnormalities in 16 out of 25 patients (64%) suffering from headaches alone, not accompanied by abnormal signs on neurological examination.

In patients with BD submitted to SPECT because of neuropsychiatric signs/symptoms, revealed reduced perfusion in the watershed areas of the frontal lobes whose severity was correlated with the severity of cognitive dysfunction.^[22]

Lass *et al.*,^[23] studied with 99mTc-HMPAO brain SPECT 21 patients affected by SS and they found a high rate of alterations in cerebral blood flow in SS, both psychoneurologically symptomatic and asymptomatic. Perfusion deficits were seen in 17 of 21 patients

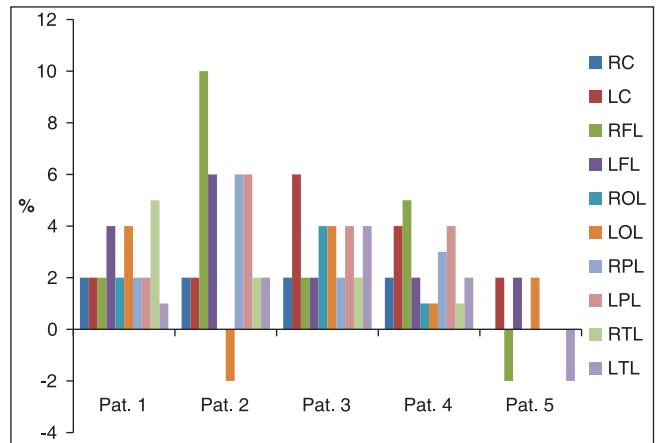


Figure 5: Percentage increase of the radiopharmaceutical uptake after medical treatment in patients with Sjogren's syndrome RC = Right cortex, LC = Left Cortex, RFL = Right frontal lobe, LFL = Left frontal lobe, ROL = Right occipital lobe, LOL = Left occipital lobe, RPL = Right parietal lobe, LPL = Left parietal lobe, RTL = Right temporal lobe, LTL = Left temporal lobe

(80.9%) with SS: 13/15 symptomatic (86.6%) and 4/6 asymptomatic (66.6%).

MRI is a very useful tool in the study of brain disease and it is for this reason that the experimental design of many studies is based on a comparison between the results of this examination and those of brain SPECT. In 1997, Lin *et al.*, studied 72 SLE patients divided into three groups: Group 1 with definite neuropsychiatric disorders, Group 2 with minor neuropsychiatric disorders, and Group 3 without any of these disorders. SPECT results were abnormal in all patients of Group 1, in 84.6% of patients of Group 2, and in 13% of patients of Group 3. MRI resulted less sensitive, being normal in 27.3% of patients with definite neuropsychiatric disorders.^[24] Other authors had already reported a poor correlation of SPECT with MRI, on numerically inferior series, arguing that SPECT was the most sensitive exam.^[10]

A comparison between SPECT and MRI was performed in 40 patients affected by SLE, with active and inactive CNS manifestations; using, as brain perfusion agent, 99mTc-ethyl-cysteinate-dimer (ECD).^[25] The authors found a significant hypoperfusion in frontal, parietal, and temporal lobes in patients with active CNS involvement when compared with patients with past history of CNS involvement or with healthy volunteers. These perfusion abnormalities occurred in areas without structural abnormalities on MRI.

In 2008, Castellino *et al.*, studied 107 patients with SLE in order to assess the relationship between clinical picture and neuroimaging in patients affected by SLE with and without neuropsychiatric involvement.^[26] Since normal findings contemporarily detected by

SPECT and MRI were rarely observed in patients with neuropsychiatric involvement, the authors feel that combining these two techniques is more useful than the two techniques alone in the assessment of neuropsychiatric involvement.

More recent experiences seem to confirm that SPECT is more sensitive than MRI in revealing the involvement of the CNS in some autoimmune diseases. A total of 24 patients with BD and signs or symptoms of CNS involvement were enrolled in a study which contemplated the execution of SPECT with 99mTc-HMAPO, CT, and MRI. SPECT showed impaired perfusion in all cases with neurological complaints, while brain MRI and CT images were normal or nonspecific in all cases.^[27] In the same study, eight patients underwent to a clinical and instrumental follow-up in order to assess the effect of therapy. The authors concluded that brain SPECT is also a useful modality for evaluating the effects of treatment and disease monitoring.

The utility of SPECT in monitoring the treatment of vasculitis has been reported since 1992 and even in this kind of application, this test seems to provide better results compared to MRI. However, most of the studies are case reports,^[11,12] retrospective studies,^[13] or small series of patients.^[14-17]

From the above, it can be argued that SPECT is the most sensitive investigation in evaluating the flow alterations in cerebral vasculitis in patients with minor neuropsychiatric disorders or even in patients without any of these disorders, since it seems able to reveal changes in cerebral blood flow in patients with negative MRI. Furthermore, it is considered an objective tool for measuring the effect of therapy. On this basis was built our experimental design, which is focused on the study of changes in cerebral blood flow after therapy in patients with negative basal MRI.

The SPECT results clearly show an improvement of blood flow after therapy in large part of the studied cerebral areas [Figures 6 and 7]. The magnitude of this improvement is quite similar, in percentage terms, in all the studied diseases (5% in BD, 4% in UV, 3% in SLE, and 2% in SS) and corresponds to an effective partial reduction of clinical symptoms.

Similar results have already been reported in the literature,^[12-17] and the present study constitutes only a confirmation obtained with a prospective approach and in a sufficient number of patients (considering that these diseases are relatively rare) with a relatively low disease duration. The information resulting from the analysis of the cases characterized by a deterioration of cerebral blood flow after treatment, however, seems more interesting. In fact, our findings reveal that most of the brain areas with a worsening of the blood flow after therapy are concentrated in some patients for each group of pathology. In a patient affected by UV, CP decreased in five areas after therapy and remained unchanged in three areas. In the group of SLE, eight areas of decreased CP after therapy and two area without valuable changes were found in a patient; while in another case, two areas showed a decreased CP and five areas remained unchanged. Similar results were found in a patients suffering from SS (two cerebral areas with a reduction of CP after therapy and five areas unchanged). These scintigraphic results completely agree with the clinical worsening observed in all the above mentioned four patients, in which the majority of cerebral areas did not show any improvement of CP after therapy.

In another case of SS characterized by a stable clinical picture, only one area showed a worsening CP, while one area did not show significant changes. The interpretation of this result seems more problematic. This mismatch between scintigraphy and clinical findings can be explained in at least two ways:

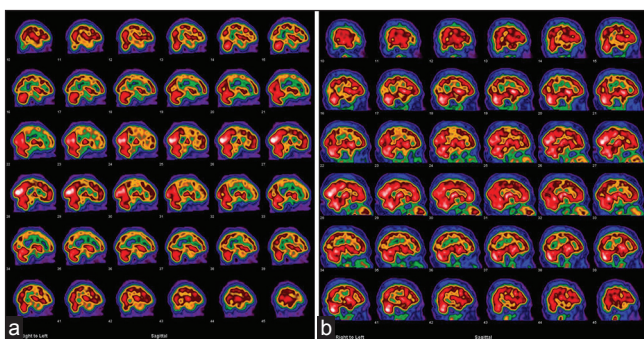


Figure 6: Patient affected by Behcet's disease. Sagittal reconstructions. (a) Basal SPECT and (b) = SPECT after 1 year therapy (colchicine). Significant improvement of cerebral blood flow associated with regression of the clinical symptoms was noted. SPECT = Single photon emission computed tomography

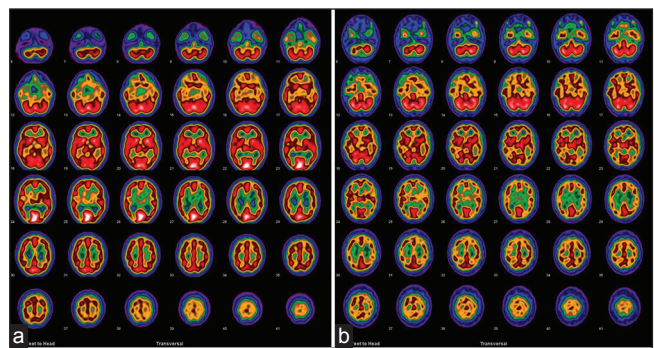


Figure 7: Transaxial reconstruction of brain 99mTc-HMPAO SPECT in a patient affected by SLE pre- (a) and posttreatment (b). After therapy, the patient developed a worsening of cerebral perfusion and clinical symptoms (headache, tingling, and memory deficits). HMPAO = Hexamethyl-propylene-aminoxime

1. The scintigraphic worsening is too small (only one area) and is not sufficient to cause effects on the overall clinical picture; and
2. The scintigraphic result underestimates the actual condition of CP.

Taking into account the second hypothesis, it is reasonable to assume an underestimation also in the remaining areas that show, wrongly, an improved CP which instead is worsened or stable. If so, however, the clinical picture should be worse and not stable, given that, as shown by the results reported above, there is some correlation between the results of SPECT and clinical symptoms. It is possible, therefore, that the first hypothesis is valid, although it would be necessary to study many more cases to confirm it.

In conclusion, the reported results seem to indicate the possibility of identifying, with the brain SPECT, those patients who do not respond to therapy, that is, those patients who showed a CP unchanged or worsened after therapy in the majority of brain regions studied. It can be imagined what this possibility means in terms of elimination of unnecessary side effects and allocation of resources. On the other hand, caution is required in evaluating cases with scintigraphic results showing reduced or stable CP in a few areas of the brain. Further experiments should be conducted in order to interpret such cases. In BD, cerebral areas with a worsening of the cerebral blood flow after therapy have not been found and the improvement of perfusion registered with brain SPECT reached the highest value observed in the present study (5%). This may indicate that this condition could be treated more easily.

References

1. Harboe E, Tjensvoll AB, Maroni S, Gøransson LG, Greve OJ, Beyer MK, *et al.* Neuropsychiatric syndromes in patients with systemic lupus erythematosus and primary Sjögren syndrome: A comparative population-based study. *Ann Rheum Dis* 2009;68:1541-6.
2. Campello Morer I, Velilla Marco J, Hortells Aznar JL, Almárcegui Lafita C, Barrera Caballo R, Oliveros Juste A. Neurological involvement in systemic sclerosis. *Rev Clin Esp* 2003;203:373-7.
3. Sanna G, Bertolaccini ML, Cuadrado MJ, Khamashta MA, Hughes GR. Central nervous system involvement in the antiphospholipid (Hughes) syndrome. *Rheumatology (Oxford)* 2003;42:200-13.
4. Le Guern V, Belin C, Henegar C, Moroni C, Maillet D, Lacau C, *et al.* Cognitive function and 99mTc ECD brain SPECT are significantly correlated in patients with primary Sjögren's Syndrome: A case-control study. *Ann Rheum Dis* 2010;69:132-7.
5. Kozora E, Filley CM, Zhang L, Brown MS, Miller DE, Arciniegas DB, *et al.* Immune function and brain abnormalities in patients with systemic lupus erythematosus without overt neuropsychiatric manifestations. *Lupus* 2012;21:402-11.
6. Massara A, Bonazza S, Castellino G, Caniatti L, Trotta F, Borrelli M, *et al.* Central nervous system involvement in Sjögren's syndrome: Unusual, but non unremarkable – clinical, serological characteristics and outcomes in a large cohort of Italian patients. *Rheumatology (Oxford)* 2010;49:1540-9.
7. Axford JS, Howe FA, Heron C, Griffiths JR. Sensitivity of quantitative (1) H magnetic resonance spectroscopy of the brain in detecting early neuronal damage in systemic lupus erythematosus. *Ann Rheum Dis* 2001;60:106-11.
8. Zhang X, Zhu Z, Zhang F, Shu H, Li F, Dong Y. Diagnostic value of single-photon-emission computed tomography in severe central nervous system involvement of systemic lupus erythematosus: A case-control study. *Arthritis Rheum* 2005;53:845-9.
9. Lim MK, Suh CH, Kim HJ, Cho YK, Choi SH, Kang JH, *et al.* Systemic lupus erythematosus: Brain MR imaging and single-voxel hydrogen 1 MR spectroscopy. *Radiology* 2000;217:43-9.
10. Emmi L, Bramati M, De Cristofaro MT, Mascalchi M, Dal Pozzo G, Marconi GP, *et al.* MRI and SPECT investigations of the CNS in SLE patients. *Clin Exp Rheumatol* 1993;11:13-20.
11. Markus HS, Bunker CB, Kouris K, Costa DC, Harrison MJ. rCBF abnormalities detected, and sequentially followed, by SPECT in neuro-Behçet's syndrome with normal CT and MRI imaging. *J Neurol* 1992;239:363-6.
12. Mathieu A, Sanna G, Mameli A, Pinna C, Vacca A, Cauli A, *et al.* Sustained normalization of cerebral blood-flow after iloprost therapy in a patient with neuropsychiatric systemic lupus erythematosus. *Lupus* 2002;11:52-6.
13. Oku K, Atsumi T, Furukawa S, Horita T, Sakai Y, Jodo S, *et al.* Cerebral imaging by magnetic resonance imaging and single photon emission computed tomography in systemic lupus erythematosus with central nervous system involvement. *Rheumatology (Oxford)* 2003;42:773-7.
14. Baca V, Lavalle C, García R, Catalán T, Saucedo JM, Sánchez G, *et al.* Favorable response to intravenous methylprednisolone and cyclophosphamide in children with severe neuropsychiatric lupus. *J Rheumatol* 1999;26:432-9.
15. Liu FY, Huang WS, Kao CH, Yen RF, Wang JJ, Ho ST. Usefulness of Tc-99m ECD brain SPECT to evaluate the effects of methylprednisolone pulse therapy in lupus erythematosus with brain involvement: A preliminary report. *Rheumatol Int* 2003;23:182-5.
16. Sun SS, Huang WS, Chen JJ, Chang CP, Kao CH, Wang JJ. Evaluation of the effects of methylprednisolone pulse therapy in patients with systemic lupus erythematosus with brain involvement by Tc-99m HMPAO brain SPECT. *Eur Radiol* 2004;14:1311-5.
17. De Cata A, Intiso D, Bernal M, Molinaro F, Mazzoccoli G, D'Alessandro V, *et al.* Prolonged remission of neuro-Behçet disease following autologous transplantation. *Int J Immunopathol Pharmacol* 2007;20:91-6.
18. Headache Classification Subcommittee of the International Headache Society. The International Classification of Headache Disorders: 2nd ed. Vol 24. Cephalalgia; 2004. p. 1-160.
19. Meusser S, Rubbert A, Manger B, Bock E, Platsch G, Feistel H, *et al.* 99m-Tc-HMPAO-SPECT in diagnosis of early cerebral vasculitis. *Rheumatol Int* 1996;16:37-42.
20. Huang WS, Chiu PY, Tsai CH, Kao A, Lee CC. Objective evidence of abnormal regional cerebral blood flow in patients

- with systemic lupus erythematosus on Tc-99m ECD brain SPECT. *Rheumatol Int* 2002;22:178-81.
21. Zayed H, Effat D, Nawito Z, Abdou AA, El Din MN, El-Refaei S, *et al.* Silent central nervous system involvement in Egyptian Behçet's disease patients: Clinical, psychiatric, and neuroimaging evaluation. *Clin Rheumatol* 2011; 30:1173-80.
 22. Driver CB, Wallace DJ, Lee JC, Forbess CJ, Pourrabbani S, Minoshima S, *et al.* Clinical validation of the watershed sign as a marker for neuropsychiatric systemic lupus erythematosus. *Arthritis Rheum* 2008;59:332-7.
 23. Lass P, Krajka-Lauer J, Homziuk M, Iwaszkiewicz-Bilikiewicz B, Koseda M, Hebanowski M, *et al.* Cerebral blood flow in Sjögren's syndrome using 99mTc-HMPAO brain SPET. *Nucl Med Commun* 2000;21:31-5.
 24. Lin WY, Wang SJ, Yen TC, Lan JL. Technetium-99m-HMPAO brain SPECT in systemic lupus erythematosus with CNS involvement. *J Nucl Med* 1997;38:1112-5.
 25. Appenzeller S, Amorim BJ, Ramos CD, Rio PA, de C Etchebehere EC, Camargo EE, *et al.* Voxel-based morphometry of brain SPECT can detect the presence of active central nervous system involvement in systemic lupus erythematosus. *Rheumatology (Oxford)* 2007;46:467-72.
 26. Castellino G, Padovan M, Bortoluzzi A, Borrelli M, Feggi L, Caniatti ML, *et al.* Single photon emission computed tomography and magnetic resonance imaging evaluation in SLE patients with and without neuropsychiatric involvement. *Rheumatology (Oxford)* 2008;47:319-23.
 27. Chuang YW, Hsu CC, Huang YF, Lin HF, Chang CC, Lin CY, *et al.* Brain perfusion SPECT in patients with Behçet's disease. *J Neuroradiol* 2013;40:288-93.

How to cite this article: Mauro L, Manuela M, Valentina M, Sara C, Chondrogiannis S, Maria DF, *et al.* Role of brain perfusion SPECT with 99mTc HMPAO in the assessment of response to drug therapy in patients with autoimmune vasculitis: A prospective study. *North Am J Med Sci* 2015;7:135-42.

Source of Support: Nil. **Conflict of Interest:** None declared.