



RBO
REVISTA BRASILEIRA DE ORTOPEDIA

www.rbo.org.br/



Case Report

Traumatic rupture of the tibialis anterior tendon: A case report

Maria Elisa Rodrigues,^{1,*} Alexandre Pereira,¹ Bruno Alpoim,¹ José Muras Geada²

¹Medical Intern in Orthopedics and Traumatology at Centro Hospitalar do Porto, Portugal.

²Assistant Physician Specialist in Orthopedics and Traumatology at Centro Hospitalar do Porto, Portugal.

This study was carried out at the Service of Orthopedics and Traumatology of Centro Hospitalar do Porto, Portugal.

ARTICLE INFO

Article history:

Received on April 25, 2012

Accepted on August 22, 2012

Keywords:

Rupture

Patellar ligament

Tendon injuries

A B S T R A C T

Objective: The authors report a case of a traumatic rupture of the tibialis anterior tendon (TTA) that was early diagnosed and treated in the emergency service. This is a rare clinical entity with few cases reported in the literature. **Case report:** A 66-year old female presented at the emergency service complaining about pain at the anterior aspect of her ankle and inability to walk normally, after a fall. Physical examination revealed clinical signs for TTA rupture, which was later confirmed by ultrasound. Surgical treatment was performed immediately – the tendon was anchored into the medial cuneiform with a soft tissue-to-bone anchor. The follow-up revealed good functional result. **Conclusion:** Physical examination and a high index of suspicion are important when facing a patient who had sustained an ankle trauma. The TTA rupture is a diagnosis to consider because unrecognized ruptures led to important functional deficits and poor functional results.

© 2013 Sociedade Brasileira de Ortopedia e Traumatologia. Published by Elsevier Editora Ltda. Este é um artigo Open Access sob a licença de [CC BY-NC-ND](#)

*Corresponding author at: Rua 31 de Janeiro, nº 718, 3º, 4910-455, Vila Praia de Âncora, Portugal. Phone: +351 910415771

E-mail: maria.elisa.gr@gmail.com

Introduction

Rupture of the tibialis anterior tendon (TAT) is a rare occurrence,^{1,2} and few cases have been described in the literature. The causes of rupture are divided into traumatic and nontraumatic (spontaneous). In the latter case, diagnosis is often delayed. Risk factors for rupture include nontraumatic inflammatory arthropathy (RA), gout, diabetes and chronic steroid therapy.^{1,3} Men older than 45 years are also in a high risk group.⁴

Traumatic ruptures result from lacerations or blunt trauma, typically due to forced plantar flexion of the foot and ankle.⁵

The diagnosis is clinical and is based on clinical history and a physical examination. Surgical treatment is mandatory in traumatic ruptures¹ because it is associated with better functional outcomes and lower complication rates compared with conservative treatment.^{6,7}

Clinical case

A 66-year-old female patient was admitted to the emergency room (ER) due to a fall that resulted in left foot trauma involving forced plantar flexion. The patient complained of pain in the tibiotarsal joint and difficulty walking.

A physical examination revealed swelling and pain on palpation of the anteromedial ankle with decreased strength in foot dorsiflexion and loss of the normal TAT contour.

The X-ray study showed no alterations. The ultrasound showed complete rupture of the TAT, which was redundant and retracted proximally, with a small volume of liquid distending the synovial sheath. The patient was subjected to a surgical procedure on the same day.

An anteromedial approach was utilized along the TAT trajectory; the intact superior and inferior extensor retinaculum was opened. The proximal portion was identified at the level of the proximal edge of the superior extensor retinaculum. The TAT rupture had occurred approximately 0.5 cm proximal to its insertion on the medial plantar aspect of the medial cuneiform (Fig. 1).

The tendon was reinserted into the medial cuneiform with an anchor and peritendon suture (Fig. 2). The superior and inferior extensor retinaculum was reconstructed to prevent adhesion of the tendon to the subcutaneous tissue; this was followed by wound closure and plaster immobilization at 10 degrees of dorsiflexion for six weeks. The postoperative period was uneventful.

The patient started physical therapy at six weeks and showed acceptable functional recovery at six months with no foot deformities or gait alterations (American Orthopedic Foot and Ankle Society [AOFAS] score of 89 points) (Figs. 3 and 4).

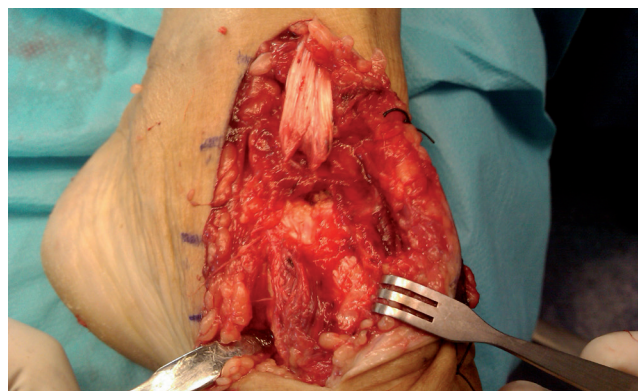


Fig. 1 - Rupture of the tibialis anterior tendon.

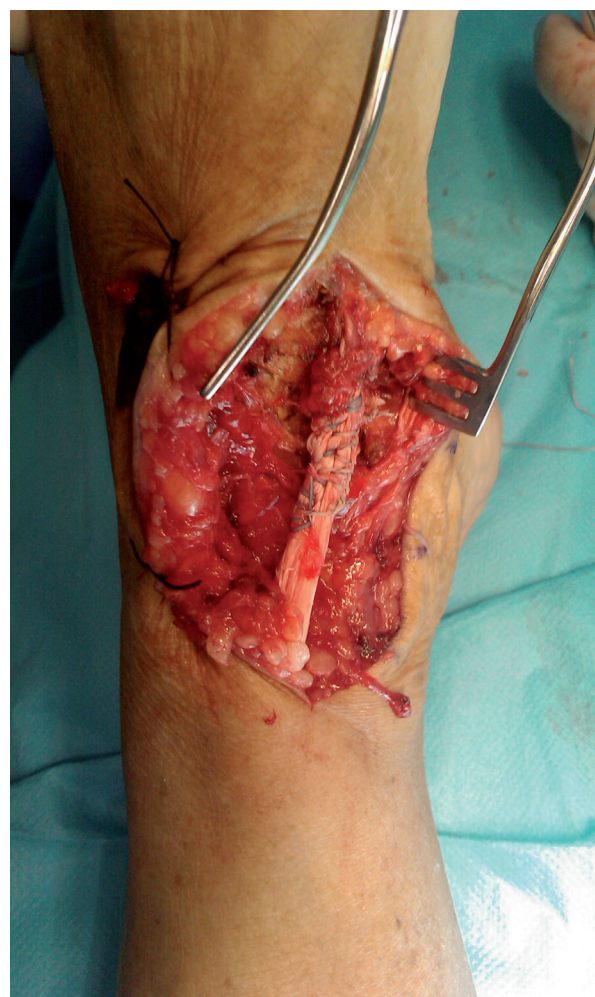
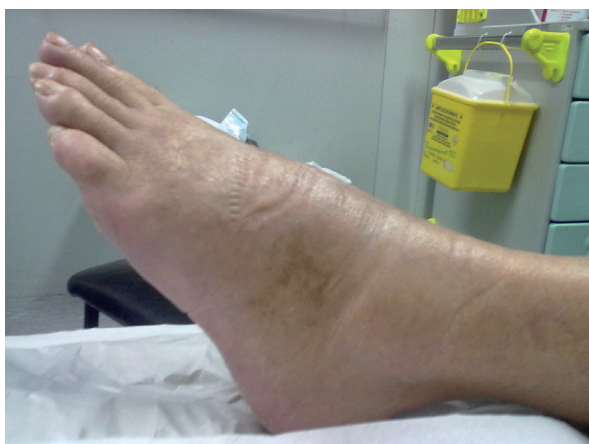
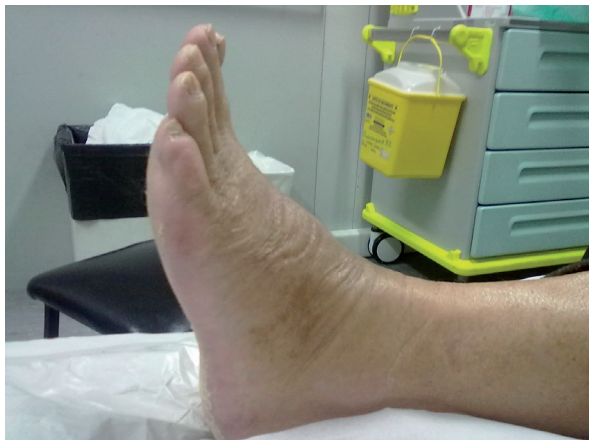Fig. 2 - Reinserted tendon.



Figs. 3 and 4 - Postoperative period.

Discussion

The tibialis anterior is the most important muscle in ankle dorsiflexion and accounts for more than 80% of the strength required for this movement.

TAT rupture is a rare occurrence for which the diagnosis is often delayed because the symptoms are indolent (low-intensity pain) and the gait is often counterbalanced by the extensor hallucis longus and extensor digitorum communis.

Spontaneous rupture occurs more often in men older than 45 years with preexisting degenerative tendinopathy and in patients with risk factors such as diabetes, gout, rheumatoid arthritis or chronic steroid therapy.^{1,3,4}

Traumatic ruptures result from lacerations or blunt trauma, typically due to forced plantar flexion of the foot and ankle.⁵

The diagnosis is clinical and is based primarily on a physical examination. The classic triad consists of (1) pseudotumor of the anterior ankle (which corresponds to the tendon extremity), (2) loss of normal tendon contour

and (3) inadequate ankle dorsiflexion accompanied by hyperextension of the hallux and toes.^{1,6}

The degree of functional impairment is evident when the patient is asked to walk with weight bearing on the heel.

Anterior tibial syndrome and peroneal nerve palsy are differential diagnoses that should be excluded.^{6,8}

An X-ray is performed to exclude bone lesions, and an ultrasound is used to confirm the diagnosis.

Nuclear magnetic resonance (NMR) is a fundamental test in chronic cases because it plays an important role in the detection and final characterization of the rupture as well as in the planning of surgery (access route and surgical technique).^{6,9}

Due to the small number of cases described, there is no consensus regarding the optimal treatment.¹⁰

More recent studies have demonstrated the superiority of surgical treatment in terms of functional outcomes and lower complication rates in relation to conservative treatment regardless of factors such as age, comorbidities, functional status of patients prior to surgery and timeliness of the surgical procedure (immediate or delayed).^{1,6,7}

Prompt diagnosis and surgical treatment increases the likelihood of a satisfactory functional result.^{5,7}

Conservative treatment is indicated in elderly patients with low functional demands or in cases in which the surgery is contraindicated due to associated comorbidities.^{1,10}

In the described case, an adequate physical examination allowed early diagnosis and surgical treatment with a good functional outcome.

TAT rupture occurred 0.5 cm proximal to its insertion on the medial plantar aspect of the medial cuneiform, which allowed its reinsertion with an anchor.

In case it is not possible to perform a direct suture of the tendon or reinsert the tendon into the bone, a tendon reconstruction technique can be used by interposing an autologous graft, such as the plantaris tendon, extensor digitorum longus tendon, peroneus tertius tendon, Achilles tendon or semitendinosus muscle tendon.^{1,2,6} The extensor retinaculum should always be reconstructed to prevent the bowstringing phenomenon and cicatricial adhesion to the subcutaneous cell tissue.¹

After a period of six weeks of immobilization with plaster cast, the patient began active mobilization and physical therapy rehabilitation. At six months of follow-up, she showed satisfactory recovery, with a return to the activities of daily living. The patient had no gait alterations and showed only a slight decrease in plantar flexion compared with the contralateral ankle.

This case report aims to draw attention to an uncommon clinical entity for which diagnosis requires a careful physical examination and a high degree of clinical suspicion. Despite the age of the patient, surgical treatment allowed an excellent functional recovery, and her activity returned to a pre-injury level.

Conflicts of interest

The authors declare no conflict of interest.

R E F E R E N C E S

1. Sammarco VJ, Sammarco GJ, Henning C, Chaim S. Surgical repair of acute and chronic tibialis anterior tendon ruptures. *J Bone Joint Surg Am.* 2009;91(2):325-32.
2. Trout BM, Hosey G, Wertheimer SJ. Rupture of the tibialis anterior tendon. *J Foot Ankle Surg.* 2000;39(1):54-8.
3. DiDomenico LA, Williams K, Petrolia AF. Spontaneous rupture of the anterior tibial tendon in a diabetic patient: results of operative treatment. *J Foot Ankle Surg.* 2008;47(5):463-7.
4. Bernstein RM. Spontaneous rupture of the tibialis anterior tendon. *Am J Orthop (Belle Mead NJ).* 1995;24(4):354-6.
5. Moyer J, Kosanovich R. Anterior tibial tendon injuries. *Clin Podiatr Med Surg.* 2002;19(3):433-40.
6. Carvalho Júnior AE, Bittar CK, Salomão O, Miranda JB, Ninomiya A, Silva DB. Tendinopatia do compartimento anterior do tornozelo. *Rev Bras Ortop.* 2010; 2010;45(2):141-7.
7. Ouzounian TJ, Anderson R. Anterior tibial tendon rupture. *Foot Ankle Int.* 1995;16(7):406-10.
8. Neuber M, Vennemann B, Brug E. Closed rupture of the tendon of the anterior tibial muscle. *Unfallchirurg.* 1998;101(4):319-22.
9. Gallo RA, Kolman BH, Daffner RH, Sciulli RL, Roberts CC, DeMeo PJ. MRI of tibialis anterior tendon rupture. *Skeletal Radiol.* 2004;33(2):102-6.
10. Markarian GG, Kelikian AS, Brage M, Trainor T, Dias L. Anterior tibialis tendon ruptures: an outcome analysis of operative versus nonoperative treatment. *Foot Ankle Int.* 1998;19(12):792-802.