



Case report

The role and safety of endobronchial ultrasound-guided transbronchial needle aspiration in the diagnosis and management of infected bronchogenic mediastinal cysts in adults

Hazim S. Bukamur^{a,*}, Emad Alkhankan^a, Haitem M. Mezughi^b, Nancy J. Munn^a,
Yousef R. Shweihat^a

^a Department of Pulmonary and Critical Care Medicine, Marshall University, Joan C. Edwards School of Medicine and the Huntington Veterans Administration Medical Center, Huntington, WV 25701, USA

^b Department of Internal Medicine, Marshall University, Joan C. Edwards School of Medicine, Huntington, WV 25701, USA

ARTICLE INFO

Keywords:

Endobronchial ultrasound

Fine needle aspiration

Bronchogenic cyst

ABSTRACT

Bronchogenic and other duplication cysts are congenital abnormalities that can present at any age including adulthood years. They are usually asymptomatic and discovered incidentally on radiological imaging of the chest. They are commonly treated by surgical resection. Recently, endobronchial ultrasound has been used to assist in diagnosis when radiologic imaging is not definitive. Endobronchial ultrasound has been used rarely to drain infected cysts, a rare complication of the bronchogenic cyst. We present a unique case of an infected large bronchogenic cyst treated with endobronchial ultrasound drainage combined with conservative medical therapy. We also review the scarce available literature describing such an approach and its potential complications and add recommendations based on our experience in managing these anomalies.

1. Introduction

Bronchogenic cysts represent a spectrum of bronchopulmonary malformations that result from an abnormal budding of the tracheobronchial tree during fetal development. Most bronchogenic cysts (BCs) are located in the mediastinum with 15%–20% occurring in the lung parenchyma, mostly in lower lobes. Communication with the airway is rare but can predispose to cyst infection [1–4]. Most patients with mediastinal BC are asymptomatic and found incidentally on radiological imaging of the chest. The most frequent symptoms are cough (the most common presentation), dyspnea, fever and pain [1,3,4]. Some patients present with complications, including respiratory distress from airway compression, infection, vascular compression, malignant transformation or airway fistulae [3,4]. Mediastinal BC is usually diagnosed with CT scan or MRI revealing fluid density or resonance in the abnormality detected [4]. BCs are treated with resection even when asymptomatic due to the small increased risk of malignancy [5]. However, not all authors agree with this invasive approach [6]. Surgical drainage and resection of the cyst has been the classic approach for complicated or large mediastinal cysts [7]. This is reported to prevent rupture and seepage of the fluids, especially if infected, into the mediastinum and pleural space [7]. Moreover, minimally invasive surgical

methods, such as mediastinoscopy, percutaneous drainage approach and endobronchial ultrasound-transbronchial needle aspiration (EBUS-TBNA) now appear safe [8–11].

2. Case presentation

A 33-year-old male had symptoms of cough, sputum production and shortness of breath 4 months before admission. He presented with symptoms of upper respiratory tract infection with fever, chills, productive cough and retrosternal chest pain. He had these symptoms start shortly after a previous similar episode. He denied weight loss. On exam, the patient was tachycardic, with a heart rate of 150 bpm. Otherwise his exam was normal. Laboratory workup revealed leukocytosis and normal chemistry panel and thyroid function panel. Blood cultures were negative. EKG showed atrial fibrillation with rapid ventricular response that converted to sinus rhythm with medical treatment. His CXR showed a widened mediastinum and possible lung infiltrates. CT of the chest revealed a mediastinal homogeneous mass with fluid density, located within the prevascular space and sub-carinal area measuring approximately 8.6×2.4 cm (Fig. 1-a, b, c). It was thought his atrial fibrillation was directly related to compression of the cyst on the atria or related to the inflammation/irritation caused by the

* Corresponding author.

E-mail address: hazimbukamur@gmail.com (H.S. Bukamur).

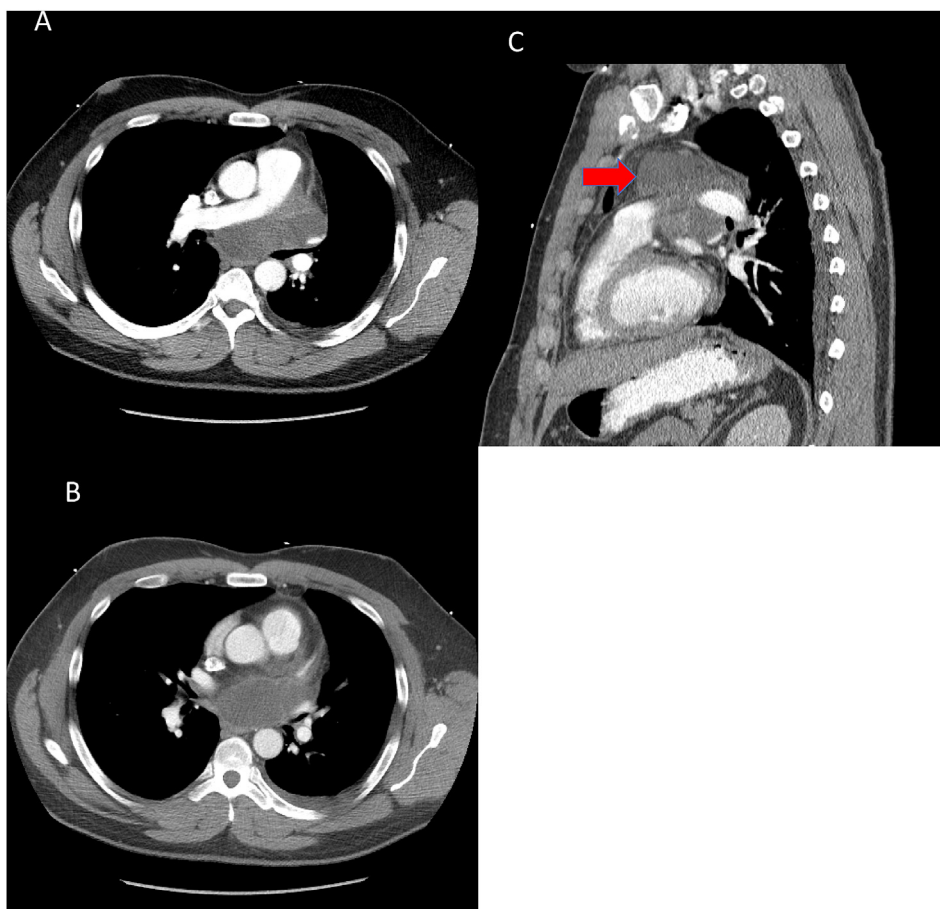


Fig. 1. A and B showing mid and lower sections through the fluid filled bronchogenic cyst in the subcarinal location. C shows the uppermost border of the cyst and its extension into the pre-vascular space (Arrow).

infected cyst on the atrial wall. We performed EBUS flexible bronchoscopy in the operating room under general anesthesia. A round hypoechoic structure, suspicious for a septated cystic lesion was detected. A fine needle aspiration was performed under direct visualization removing 50 ml of thick yellow material after single puncture of the cyst. Cytology from the aspirate was negative; culture grew *Streptococcus viridans*, *Coryneform bacteria* and *Prevotella melaninogenica*. The patient was treated with antibiotics. He improved significantly and was discharged to be evaluated for resection after infection was controlled. The patient was evaluated by a multidisciplinary approach and referred to an advanced thoracic surgery quaternary center. Due to the complexity and location of the cyst and resolution of symptoms at time of the evaluation, the conservative approach of follow up was elected. He was treated with 4 weeks of Amoxicillin/clavulanic acid and was followed up clinically at 3 months intervals. He had CT scans every 6 months for the first year and yearly thereafter.

3. Discussion

We believe the cyst we encountered in this case to be a bronchogenic cyst given the location in the subcarinal and prevascular mediastinal location. The absence of other systemic symptoms or manifestations make acquired cystic diseases like lymphoma or hydatid cyst unlikely. Esophageal cysts are usually tubular and in close association with the esophagus unlike our case that is extensive and extends to the prevascular space. Cytologic examination of aspirate did not reveal any lymphocytic or thymic tissue effectively ruling out lymphomas and thymus related cysts. Other etiologies like pericardial cyst is highly unlikely based only on location.

Infection is a rare complication of bronchogenic cysts but it is among the most serious, potentially life-threatening conditions. Early presentation of cyst infection is vague and nonspecific. It often will progress insidiously over time [1] as probably occurred in our patient. Delayed treatment increases risk of complications. Thus, early diagnosis and prompt management would likely assure a good prognosis [1,12].

There is little argument on the usefulness of EBUS in diagnosis of bronchogenic cysts [13]. The ultrasonic characteristics of the cyst can be assessed accurately. The EBUS commonly shows the BC as anechoic or hypoechoic well defined structure without color flow signal and differentiates it from tumors or vascular abnormalities. It can also show septations, the presence of hyperechoic thickening within the cyst walls in case of complications [13,14]. It can also examine the echogenicity of the fluid similar to pleural fluids and help assess if it is a source of infection depending on the fluid characteristics [15].

The issues with using EBUS in sampling the structure or in drainage of suspected infected cysts are multifaceted. In the case of a non-complicated cyst, inserting the needle through the bronchoscopic channel and then into the sterile environment of a cyst will surely increase the risk of getting it infected [16]. In the case of an infected bronchogenic cyst, a needle puncture might cause leakage of the infected fluid into the mediastinum, or cause rupture of the cyst with grave consequences [7,11,17]. In both instances, the needle aspiration would not per se prevent re-accumulation of the fluids and thus the recurrence of BC [18]. In addition, It would not eliminate the theoretical increased risk of malignancy since the wall of the cyst persists even though it may not refill with fluids [5]. In a systematic literature review by Maturu et al., 32 patients identified by 26 case reports had EBUS guided drainage of bronchogenic cysts for therapeutic (most commonly) and diagnostic

reasons. Only 5 patients had complications of which 4 were infectious. There were no deaths and no recurrences over 14 months of follow up [15]. Other authors later described complications of mediastinitis, pneumonia and cystic rupture with the use of EBUS [7,11,17,19].

Complete Surgical excision, on the other hand, ensures the lack of recurrence and eliminates the theoretical risk of malignancy, since the wall of the cyst is removed [5]. That said, the surgical approach is not free of problems [20]. Most of the cysts are in the mediastinum and require at least VATS for complete removal, if not thoracotomy [21]. These procedures are major operations. The latter has significant mortality and morbidity [20]. If the cyst were infected, it would be impossible for the surgeon to empty the cyst and remove its wall without contaminating the mediastinum [3]. In addition, infection causes an inflammatory reaction resulting in adhesions and infiltration of the inflammation to nearby structures [22]. This can make surgery very risky given the location of the cysts near vital structures. There are multiple reports of recurrence after surgery especially if complete excision is not performed [23–25].

In our experience in draining bronchogenic cysts, several factors and maneuvers might affect the outcome. These are mainly anecdotes that are yet to be verified in randomized trials that are unlikely to be performed given the rarity of the anomaly. First, to prevent recurrence of the cyst, complete drainage is critical. Allowing the cystic walls to collapse, along with the injury induced by needle penetration, can induce enough inflammation enough to cause the adhesion of the cavity walls and reduce recurrence risk [18,26,27]. To do this, the needle needs to be placed in the most dependent part of the cyst (i.e. near the posterior wall of the cyst if the patient is lying flat or the inferior wall of the cyst if the patient is sitting during the bronchoscopic procedure). Applying suction multiple times to the needle will facilitate emptying the cyst while keeping the needle in its place. Emptying the cyst from the first attempt is important in preventing spillage of the contents into the mediastinum or to the airway. In addition, like any infected space, complete drainage is important in controlling sepsis. Second, in our experience, prophylactic antibiotics during the drainage of sterile cysts can prevent infections of the cyst. We base this on the recommendations set in the American Society of Gastroenterology Endoscopy (ASGE) guidelines and commonly extend the antibiotic prophylaxis per the recommendations to 3–5 days [28]. These recommendations are weak recommendations and not based on randomized trials as mentioned above. Third, in the case of an infected mediastinal cyst, the priority should be to drain the septic source using the least invasive method until stabilization of clinical status is achieved. EBUS or EUS drainage is well suited given the simplicity and the low risk of endoscopic procedures per se, especially when compared to risk of a surgical procedure in infected or septic patients [22]. Fourth, after resolution of sepsis and stabilization of clinical status, complete surgical excision can be assessed [22]. The risk and benefit ratio of this approach needs to be discussed with the patient and follow up only offered as an alternative. If complete excision is not possible, then surgical approach is probably not justified since BC has been reported to recur in these instances [23–25]. In addition, incomplete resections do not eliminate the theoretical risk of malignancy and offers no advantage in our opinion over the less invasive bronchoscopic approach. Treatment with toxic agents such as ethanol injection into the cyst wall or doxorubicin injection for sclerosing can be attempted. This approach can induce inflammation and may make it difficult to differentiate septic from chemical inflammatory reactions. In addition, the use of sclerosing agent is rare in the literature and should be attempted if recurrence occurs and patient is not a surgical candidate [23].

In our case, the patient was evaluated for surgical resection after resolution of sepsis and elected follow up over the risk of surgery. There is no known optimal duration of follow up and recurrence has been noted after (24–36) months of treatment in some cases. Until now (32 months) our patient has not had a recurrence. If follow up is chosen as an approach for management, it might not be unreasonable to

recommend follow up on yearly basis after multiple CT scans in the initial year showed continued absence of recurrence. Follow up should probably be continued for at least 36 months since there are currently no reports that suggest recurrence can occur later than that.

4. Conclusion

The optimal strategy for management of patients with infected mediastinal bronchogenic cysts remains unknown. EBUS-TBNA can be both diagnostic and therapeutic. Single needle aspiration with total drainage of cyst contents along with appropriate follow-up is a viable alternative to surgery in patients with infected mediastinal BC [26]. Surgical resection may be entertained if needle aspiration is unsuccessful [22,29] and after stabilization from sepsis. Prophylactic antibiotics for aspiration of sterile cyst can prevent infection of the cyst per expert opinion. If bronchoscopic approach alone is chosen, follow up for at least 36 months is suggested [1,30,31].

Data availability

All data are available in the manuscript.

Conflicts of interest

Hazim S. Bukamur, Haitem M. Mezughi, Emad Alkhankan, Nancy J. Munn and Yousef R. Shweihat have no conflict of interests to disclose related to the contents of the manuscript.

Funding statement

Not applicable.

No funding was provided to any of the authors by any institution to write this case report and article review.

Authors' contributions

Hazim S. Bukamur, Haitem M. Mezughi, and Emad Alkhankan participated in data collection and interpretation, and drafted the initial manuscript. Yousef R. Shweihat and Nancy J. Munn critically edited and revised the manuscript.

Consent for publication

Not applicable.

No consent needed as this is a case report without any patient identifiers.

Ethics approval and consent to participate

Not applicable.

No ethics approval nor consent is needed as this is a case report without any patient identifiers.

Acknowledgements

Not applicable.

Appendix A. Supplementary data

Supplementary data related to this article can be found at <http://dx.doi.org/10.1016/j.rmcr.2018.04.002>.

References

- [1] S.R. Patel, D.P. Meeker, C.V. Biscotti, et al., Presentation and management of bronchogenic cysts in the adult, *Chest* 106 (1) (1994) 79–85.

- [2] M.E. Ribet, M.C. Copin, B. Gosselin, Bronchogenic cysts of the mediastinum, *J. Thorac. Cardiovasc. Surg.* 109 (5) (1995) 1003–1010.
- [3] A. Sarper, A. Ayten, I. Golbasi, et al., Bronchogenic cyst, *Tex. Heart Inst. J.* 30 (2) (2003) 105–108.
- [4] S. Takeda, S. Miyoshi, M. Minami, et al., Clinical spectrum of mediastinal cysts, *Chest* 124 (1) (2003) 125–132.
- [5] J.W.R. Bolton, D.M. Shahian, Asymptomatic bronchogenic cysts: what is the best management? *Ann. Thorac. Surg.* 53 (6) (1992) 1134–1137.
- [6] R.B. Ponn, Simple mediastinal cysts: resect them all? *Chest* 124 (no. 1) (2003) 4–6.
- [7] R. Rajmane, A.M. Adams, O. Rajmane, et al., Cyst rupture after endobronchial ultrasound-guided transbronchial needle aspiration, *J. Bronchol. Interv. Pulmonol.* 23 (2) (2016) e20–e22.
- [8] D.J. Sugarbaker, Thoracoscopy in the management of anterior mediastinal masses, *Ann. Thorac. Surg.* 56 (3) (1993) 653–656.
- [9] J.D. Urschel, T.A. Horan, Mediastinoscopic treatment of mediastinal cysts, *Ann. Thorac. Surg.* 58 (6) (1994) 1698–1700.
- [10] M.K. Whyte, C.T. Dollery, A. Adam, et al., Central bronchogenic cyst: treatment by extrapleural percutaneous aspiration, *BMJ Br. Med. J.* 299 (6713) (1989) 1457–1458.
- [11] A. Singh, S. Singh, A. Malpani, et al., Treatment of bronchogenic cyst surgical versus transbronchial drainage? *J. Bronchol. Interv. Pulmonol.* 18 (4) (2011) 359–361.
- [12] C.-H. Kuo, F.-T. Chung, H.-P. Kuo, Infected bronchogenic cyst diagnosed by endobronchial ultrasound-guided transbronchial needle aspiration, *J. Formos. Med. Assoc.* 112 (7) (2013) 436–437.
- [13] D. Anantham, G.-C. Phua, S.-Y. Low, M.-S. Koh, Role of endobronchial ultrasound in the diagnosis of bronchogenic cysts, *Diagn. Ther. Endosc.* 2011 (2011) 468237, <http://dx.doi.org/10.1155/2011/468237> 3 pages.
- [14] R. Franco-Elizondo, S. Patnaik, K.H. Huang, et al., Role of endobronchial ultrasound in the diagnosis and management of bronchogenic cysts: two case descriptions and literature review, *Southwest J. Pulmonary Critical Care* 9 (2) (2014) 115–122.
- [15] V.N. Maturu, S. Dhooria, R. Agarwal, Efficacy and safety of transbronchial needle aspiration in diagnosis and treatment of mediastinal bronchogenic cysts, *J. Bronchol. Interv. Pulmonol.* 22 (3) (2015) 195–203.
- [16] A. Gamrekeli, G. Kalweit, H. Schäfer, et al., Infection of a bronchogenic cyst after ultrasonography-guided fine needle aspiration, *Ann. Thorac. Surg.* 95 (6) (2013) 2154–2155.
- [17] G. Hong, J. Song, K.-J. Lee, et al., Bronchogenic cyst rupture and pneumonia after endobronchial ultrasound-guided transbronchial needle aspiration: a case report, *Tuberc. Respir. Dis.* 74 (4) (2013) 177–180.
- [18] G. Galluccio, G. Lucantoni, Mediastinal bronchogenic cyst's recurrence treated with EBUS-FNA with a long-term follow-up, *Eur. J. Cardio. Thorac. Surg.* 29 (4) (2006) 627–629.
- [19] T. Onuki, M. Kuramochi, M. Inagaki, Mediastinitis of bronchogenic cyst caused by endobronchial ultrasound-guided transbronchial needle aspiration, *Respirol. Case Rep.* 2 (2) (2014) 73–75.
- [20] F. Granato, L. Voltolini, C. Ghiribelli, et al., Surgery for bronchogenic cysts: always easy? *Asian Cardiovasc. Thorac. Ann.* 17 (5) (2009) 467–471.
- [21] U. Cioffi, L. Bonavina, M. De Simone, et al., Presentation and surgical management of bronchogenic and esophageal duplication cysts in adults, *Chest* 113 (6) (1998) 1492–1496.
- [22] Y. Kawaguchi, J. Hanaoka, S. Asakura, et al., Infected bronchogenic cyst treated with drainage followed by resection, *Ann. Thorac. Surg.* 98 (1) (2014) 332–334.
- [23] A.H. Alraiyes, K. Shaheen, J. Reynolds, et al., Recurrent bronchogenic cyst after surgical resection, *Ochsner J.* 15 (2) (2015) 176–179.
- [24] D.C. Rice, J.B. Putnam Jr., Recurrent bronchogenic cyst causing recurrent laryngeal nerve palsy, *Eur. J. Cardio. Thorac. Surg.* 21 (3) (2002) 561–563.
- [25] M.H. Chamberlain, F.C. Wells, Recurrent bronchogenic cyst in a Jehovah's witness, *J. Cardiovasc. Surg.* 41 (5) (2000) 785–786.
- [26] R.F. Casal, C.A. Jimenez, R.J. Mehran, et al., Infected mediastinal bronchogenic cyst successfully treated by endobronchial ultrasound-guided fine-needle aspiration, *Ann. Thorac. Surg.* 90 (4) (2010) e52–e53.
- [27] A. Andreani, G. Cappiello, M. Valli, M. Giovannini, TBNA for the treatment of non complicated bronchogenic cyst, *Monaldi Arch. Chest Dis.* 79 (3–4) (2013).
- [28] M.A. Khashab, K.V. Chithadi, R.D. Acosta, et al., Antibiotic prophylaxis for GI endoscopy, *Gastrointest. Endosc.* 67 (6) (2008) 791–798.
- [29] A.R. Twehues, S.U. Islam, A. Vaida, Management of mediastinal bronchogenic cyst with transbronchial needle aspiration, *Chest* 136 (4) (2009) 23S.
- [30] T. Nakajima, K. Yasufuku, K. Shibuya, et al., Endobronchial ultrasound-guided transbronchial needle aspiration for the treatment of central airway stenosis caused by a mediastinal cyst, *Eur. J. Cardio. Thorac. Surg.* 32 (3) (2007) 538–540.
- [31] H. Liu, S. Li, Z. Cao, et al., Clinical features and treatment of bronchogenic cyst in adults, *Chin. Med. Sci. J.* 24 (1) (2009) 60–63.