

The effects of morus nigra on the alveolar bone loss in experimentally-induced periodontitis

Purpose

The aim of this study is to evaluate the anti-inflammatory effects of morus nigra on experimentally-induced periodontitis in rats.

Materials and Methods

Twenty-four Wistar-albino rats were randomly divided into three groups: control group (C, n=8), experimental periodontitis (PER, n=8), experimental periodontitis and treated with Morus nigra (MN+PER, n=8) (50 mg/kg per day for 21 days). After 21 days, the rats were sacrificed, and alveolar bones were evaluated histopathologically and histometrically analyzed to obtain level of alveolar bone loss. The detection of RANKL and OPG were immunohistochemically performed. Serum and tissue levels of MMP-8 and MMP-13 were also analyzed.

Results

Morus nigra treatment decreased tissue MMP-8 and MMP-13 levels and there were significant differences in the case of tissue levels of MMP-8 and MMP-13 between groups PER and MN+PER ($p=0.035$, $p=0.041$). There were no significant differences among all the groups serum levels of MMP-8 and MMP-13 ($p=0.067$, $p=0.082$). In the histometric evaluation, alveolar bone loss was greater in the PER group compared to C and MN groups ($p=0.035$). Immuno-histochemical staining of RANKL activities were found significantly lower ($p=0.037$) and OPG activities were found significantly higher in MN+PER group when compared to PER group ($p=0.021$).










Conclusion

The present study reveals that systemic administration of Morus nigra significantly inhibited the regional alveolar bone resorption and contributes to periodontal healing in the rat experimental-periodontitis models.

Keywords: Experimental periodontitis; cytokines; MMP-8; MMP-13; morus nigra

Introduction

Periodontal diseases are chronic inflammatory disorders that affect periodontal attachments and alveolar bone around the teeth (1). The main etiological factors for the initiation and progression of periodontitis are; genetic predisposition, environmental factors and a dysbiotic microbiota with an excessive host response (2). A microbial biofilm layer starts periodontal disorders by alerting immune system with periodontopathogens and plays a significant role in the advancement of this diseases (3). Osteoclastogenic mediators, matrix metalloproteinases (MMPs), and inflammatory cytokines are released from immune system cells during periodontal inflammation. These factors also improve the association between the receptor activation of nuclear factor κ B (RANK) and its ligand (RANKL) (4). An excessive host response is dependent on periodontopathogens that cause tissue degradation due to complicated associations between periodontopathogens and the host's defense system (4).

Tuba Talo Yildirim¹ ,
 Gonca Ozan² ,
 Serkan Dunder¹ ,
 Alihan Bozoglan¹ ,
 Tahir Karaman³ ,
 Neval Dildes⁴ ,
 Can Ayhan Kaya⁵ ,
 Nalan Kaya⁶ ,
 Elif Erdem⁶ 

ORCID IDs of the authors: T.T.Y. 0000-0002-7577-5703;
 G.O. 0000-0001-6874-3669; S.D. 0000-0003-3944-1957;
 A.B. 0000-0003-3420-5816; T.K. 0000-0002-3764-637X;
 N.D. 0000-0002-1942-3746; C.A.K. 0000-0001-8226-7603;
 N.K. 0000-0001-8880-4932; E.E. 0000-0002-2097-7818

¹Department of Periodontology, Faculty of Dentistry, Firat University, Elazig, Turkey

²Department of Biochemistry, Faculty of Veterinary Medicine, Firat University, Elazig, Turkey

³Department of Prosthodontics, Faculty of Dentistry, Firat University, Elazig, Turkey

⁴Department of Orthodontics, Faculty of Dentistry, Firat University, Elazig, Turkey

⁵Diyarbakir Vocational High School, Dicle University, Diyarbakir, Turkey.

⁶Department of Histology and Embriology, Faculty of Medicine, Firat University, Elazig, Turkey

Corresponding Author: Tuba Talo Yildirim

E-mail: dt_talo@hotmail.com

Received: 31 August 2018

Revised: 22 November 2018

Accepted: 25 January 2019

DOI: 10.26650/eor.20190021

MMPs are proteolytic enzymes that are responsible for tissue remodeling and destruction of the extracellular matrix (ECM) (5). Various hormones and pro-inflammatory cytokines such as interleukin (IL) 8, IL-1 β , and tumor necrosis factor (TNF)- α , which are released during the inflammatory process, cause the release of MMPs from inflammatory cells (5). Metalloproteinases are classified into five subgroups: collagenases, gelatinases, stromelysins, membrane types, and others. Previous studies related to MMPs have suggested that MMP-8 and MMP-13 are the major mediators of collagenases and are effective in the destruction of type I, II, and III collagen (6). MMP-8 is an important factor of degradation in inflammatory disorders and associated with periodontal diseases. MMP-13 has a significant role in various aspects of bone metabolism such as resorption and remodeling (7). Furthermore, MMP-13 is one of the most dominant MMPs in resorption areas in bone tissue (6). Previous studies related to MMP-8 and MMP-13 suggest that these are indicators of the destruction of tissue in periodontal diseases (5). Most of the studies have suggested that MMP-13 and MMP-8 are released in higher levels in patients with periodontal diseases than healthy individuals (6). RANKL, a member of the TNF superfamily, is a crucial factor in bone resorption. RANKL expression has been detected in osteoblastic, stromal, and activated B- and T cells (4). RANKL stimulates osteoclast differentiation and bone resorption (1). IL-1 β and TNF- α lead to periodontal tissue destruction and alveolar bone resorption via decreases in osteoprotegerin (OPG). OPG has an important role in inhibiting bone resorption (8). Bone loss occurs as a result of an increased RANKL/OPG ratio, and this ratio is increased at the sites of active periodontal disease and related to the disease severity (9). Previous studies have suggested that RANKL levels in gingival crevicular fluid (GCF) are increased in individuals with periodontitis (1, 4).

Morus nigra (Urticales Moraceae), commonly known as the black mulberry, possesses many characteristics including anxiolytic, sedative, diuretic, analgesic and hypotensive properties. It is also used in the treatment of various disorders including inflammatory diseases (10) pharyngitis, toothache, snake bites, antidote to action poisoning (11). The berries, bark, and leaves of *M. nigra* are used for various ailments. The berries inhibit inflammation and hemorrhage, the leaves are an antidote to poisoning, and the bark is used for odontalgia (12). The anti-inflammatory and analgesic activities of *M. nigra* have been shown in several experimental models (10). *M. nigra* is also used to make traditional Turkish foods such as mulberry pekmez, mulberry pestil, and mulberry kome. In addition, the fruit are eaten fresh and made into natural dyes, marmalades, liquors, and juices (13).

Based on the beneficial properties of *M. nigra*, we suggest that it may decrease both inflammation in periodontal tissue and alveolar bone loss rate in periodontal disorders. To the best of our knowledge, there are limited number of investigations focused on the effect of *M. nigra* on periodontal tissues (10-13). Therefore, current research was planned to analyze the possible therapeutic effects of systemic delivery of *M. nigra* extract on alveolar bone resorption by examining RANKL, OPG, MMP-8, and MMP-13 levels in both periodontal tissues and serum in ligature induced periodontitis models.

Materials and Methods

Experimental design

All experimental procedures and animal care were performed in accordance with the protocol approved by the Animal Experimental Ethics Committee of the Firat University, Elazığ, Turkey (No: 2012-013). The rats used in this study were maintained in accordance with the Declaration of Helsinki. The sample size ($n=8$) was determined with a power calculation to provide 80% power to recognize significant differences among groups with a 95% confidence interval ($\alpha=0.05$), considering the means and standard deviations of the alveolar bone in the furcation area of the study by Saglam et al. (1) and MMPs (14). Twenty-four 12-week old male Wistar rats (weight: 220 ± 10 g) were divided randomly into three groups as follows: control (C), experimental periodontitis (PER) with no treatment, and experimental periodontitis treated with *M. nigra* (MN+PER). Pairs of rats were placed in wire cages and maintained on a 12:12-hour light-dark cycle with an ambient room temperature of 23 ± 2 °C. Rats were fed with standard rat pellets and tap water ad libitum.

For experimental periodontitis induction, xylazine hydrochloride (Rompun, Bayer, Germany; 10 mg/kg) and ketamine hydrochloride (Ketalar, Bayer, Germany; 40 mg/kg) were used to provide anesthesia. 3-0 sterile silk sutures were ligatured two sides of the mandibular first molars of the rats in the PER and MN+PER groups for 21 days in a submarginal position to induce microbial dental plaque accumulation and inflammation, according to previous studies (15). The MN+PER group received *M. nigra* with an intragastric dose of 50 mg/kg/day until their sacrifice at 21st day (11).

Preparation of the M. nigra extract

Fresh fruits of *M. nigra* were collected from Elazığ, Sivrice, Turkey, during its fruit season between 15 August and 15 September 2015. *M. nigra* extract was prepared from fresh fruits. We homogenized 200 grams of fruit in 200 ml of water and the homogenization was then filtered through cheese cloth. The filtrate was boiled for 10 minutes. The final solution was dissolved in distilled water at 50 mg/kg concentrations for the experiment. After obtaining the extract, it was stored at -20 °C until tested (11).

Blood and tissue sampling

After 21 days, xylazine hydrochloride (Rompun, Bayer, Germany; 10 mg/kg) and ketamine hydrochloride (Ketalar, Bayer, Germany; 40 mg/kg) were used for anesthesia. After the cardiac blood samples were collected from the heart, the animals were sacrificed by guillotine method. Mandibula samples were removed from the heads. The mandibles were divided into two equal pieces (16). The right sides were forwarded to the histology laboratory for histological evaluation and 10% neutral-buffered formaldehyde solution was used for fixation. The left sides of the mandibula were sent to the biochemistry laboratory for biochemical analysis. The blood samples were centrifuged at 3500 xg for 15 minutes to obtain serum. Sterile polypropylene tubes were used to save

serum samples and kept at -80°C until being analyzed for MMP-8 and MMP-13 (1).

Biochemical measurement of serum and tissue parameters

In all groups, periodontal soft tissues from the left side of the mandibula were carefully retained for biochemical analysis. A buffer solution (4.5 ml) was added into 0.5 g of the periodontal soft tissue. After 15 minutes homogenization, the mixtures were filtered and centrifuged at 3500 rpm using a refrigerated centrifuge at 4°C . The tissue and serum samples were used for analysis of MMP-8 and MMP-13 levels by rat enzyme linked immunosorbent assay (Rel assay -ELISA, Gaziantep, Turkey) kits (4).

Histopathological and histometric evaluation

Alveolar bone samples were removed from the mandibles of rats for histological analysis. These samples were then fixed for 72 hours in 10% formalin and washed with phosphate buffered saline (PBS) (P4417, Sigma-Aldrich, St. Louis, Missouri, USA). Then, the tissues were immersed in 10% ethylenediaminetetraacetic acid (EDTA) for decalcification for approximately 60 days. At the end of this decalcification process, routine paraffin techniques were applied. Tissues that were embedded in paraffin blocks were cut into 5–6- μm thick sections. The prepared slides were then stained with hematoxylin and eosin (H&E). Finally, the stained slides were interpreted and imaged under a light microscope (Olympus, CH BI45 T S, Japan)(1).

Histometric evaluation was done according to the method explained by Lucinda et al.. Three points were considered as that is, the apex of the distal/mesial root (A), the alveolar bone on the distal/mesial area of the tooth (B), and the top of the distal/mesial cusp (C) (Figure 1) (17). The distances between AB and AC points were calculated to determine the periodontal bone level with this formula: $AB/AC \times 100$ (15). All measurements were performed by a single examiner (E.E.) and a mean value was defined for each tooth.

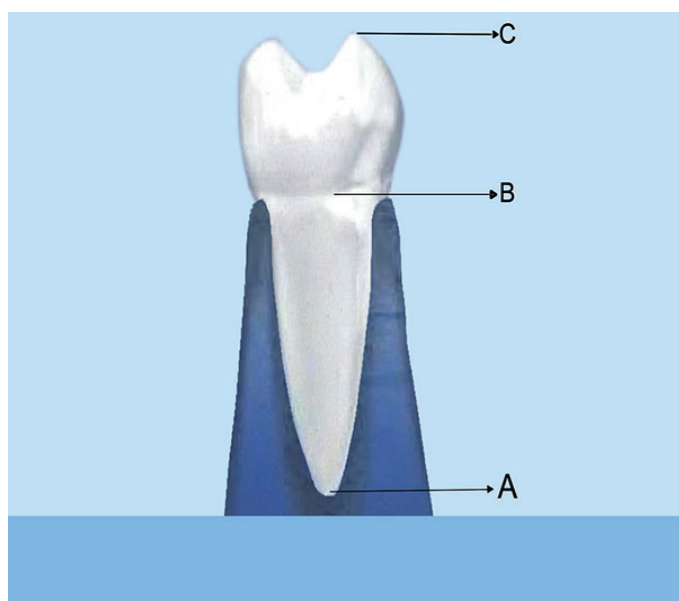


Figure 1. Periodontal bone loss measurement: A, root apex; B, crest bone; C, tip of the cusp of the first molar.

Immunohistochemical evaluation

An avidin-biotin-peroxidase complex procedure was applied to determine RANKL and OPG immunoreactivities in rat alveolar bone tissue. The 5–6- μm thickness tissue slides with poly L lysine were prepared. Deparaffinized and rehydrated tissues were then boiled in a citrate buffer at a pH of 6.5 in a microwave oven (750 W) for 7+5 minutes and cooled for about 20 minutes at room temperature. After washing with PBS for 3 \times 5 minutes, the tissues were incubated in hydrogen peroxide (Hydrogen Peroxide Block, Thermo Fisher Scientific, TA-125-HP, Fremont, California, USA) for 5 minutes to obstruct endogenous peroxidase activity and then washed with PBS for 3 \times 5 minutes. Ultra V Block (Ultra V Block, TA-125-UB, Fremont, California, USA) was enforced for 5 minutes in order to avoid background staining. Tissues were incubated in 1/200 diluted primary antibodies (RANKL (sc-9073) and OPG (sc-11383) Rabbit Polyclonal IgG Antibodies, Santa Cruz Biotechnology, Santa Cruz, California, USA) in a humid environment for 60 minutes at room temperature, they were then washed with PBS for 3 \times 5 minutes. The tissues were then incubated with a secondary antibody (Biotinylated Goat Anti-Polyvalent, Thermo Fisher Scientific, TP-060-BN, Fremont, California, USA) in a humid environment for 30 minutes at room temperature. After that, tissues were washed with PBS for 3 \times 5 minutes and incubated with streptavidin peroxidase (Streptavidin Peroxidase, Thermo Fisher Scientific, TS-060-HR, Fremont, California, USA) in a humid environment for 30 minutes at room temperature. Then, 3 amino 9-ethylcarbazol (AEC) solution (Large Volume AEC Substrate System (RTU), Thermo Fisher Scientific, TA-060-HA, Fremont, California, USA) was dropped into the tissues and the tissues were examined by light microscopy. The reaction was completed when the video signal was received. Counterstaining textures of tissues were provided with Mayer's hematoxylin staining. The stained slides were then closed with a proper closing solution (Large Volume Vision Mount, Thermo Fisher Scientific, TR-125-UG, Fremont, California, USA). The slides were imaged under a light microscope (Olympus, CH-BI45-T-S, Japan) The immunohistochemical histoscore was created on the basis of immunoreactivity prevalence (0.1: < 25%, 0.4: 26-50%, 0.6: 51-75%, 0.9: 76-100 %) and severity (0: no, +0.5: very little, +1: little, +2: medium, +3: severe) (Histoscore = prevalence \times severity) (18).

Statistical analysis

SPSS 23.0 (IBM Corp. Released 2015. IBM SPSS Statistics for Windows, Version 23.0. Armonk, NY, USA) software was used for statistical analysis. One-way analysis of variance (ANOVA) and Tukey's HSD post hoc tests were performed. Data was expressed as mean \pm standard deviation (SD). The confidence interval was set to 95% and p values less than 0.05 were considered statistically significant.

Results

Biochemical results

The mean percentage values of MMP-8 and MMP-13 in tissue are shown in Table 1. The MMP-8 and MMP-13 levels were higher in the PER group tissue samples than in the

Table 1. The tissue levels of MMP-8 and MMP-13. Values are expressed as means±standard deviations. The different letters in the same row indicate significant differences among the study groups (MMP: matrix metalloproteinase, PER: periodontitis, MN+PER: periodontitis and morus nigra treatment).

	CONTROL	PER	MN+PER
MMP-8	0.50 ±0.16a	0.75±0.10b	0.19±0.20c
MMP-13	0.36±0.21a	0.74±0.23b	0.40±0.17c

Table 2. The serum levels of MMP-8 and MMP-13. Values are expressed as means±standard deviations (MMP: matrix metalloproteinase, PER: periodontitis, MN+PER: periodontitis and morus nigra treatment).

	CONTROL	PER	MN+PER
MMP-8	0.76±0.26	0.81±0.15	0.75± 0.09
MMP-13	0.98±0.15	0.99±0.08	0.90±0.04

Table 3: The level of RANK-L and OPG

	CONTROL	PER	PER+MN
RANK-L	0.817±0.22 ^a	2.15±0.64 ^{a,b}	1.25±0.48 ^b
OPG	1.68±0.64 ^c	0.70±0.41 ^{c,d}	1.58±0.67 ^d

Values are expressed as means±standard deviation. Letters (a, b, c or d) in the same row indicate significant differences between groups (n=8); p<0.05. For statistical analysis, differences between groups were tested by analysis of variance followed by the Tukey post hoc test.

fibers, and the destruction of cemento enamel attachments were detected (Figure 2). However, in the MN+PER group, there were decreases in both the resorption of alveolar bone and the destruction of cemento enamel attachments and periodontal ligaments (Figure 2).

In the histometric evaluation, alveolar bone loss was greater in the PER group compared to C and MN groups (p=0.035; Figure 3). There were no difference between C and MN+PER groups (p=0.084).

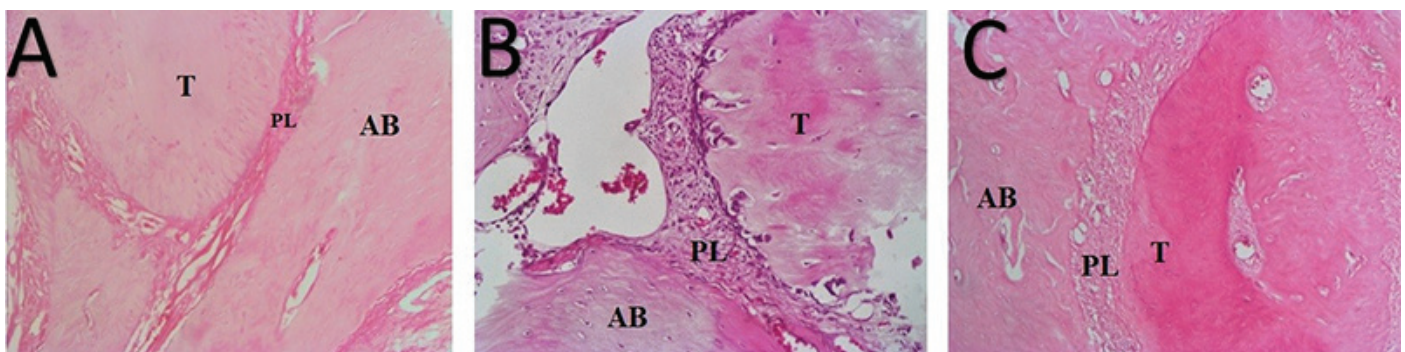


Figure 2. Histopathological findings on the alveolar bone (H&E staining 100x magnification). Control group (A); showing normal periodontium, periodontitis group (B); showing intense inflammatory cell infiltrate, dilated blood vessels, and osteoclasts in their Howship's lacunae with multiple resorption foci, periodontitis group treated with morus nigra (C); showing moderate inflammatory cell infiltrate in periodontal ligament and osteoclasts in their Howship's lacunae with multiple resorption foci (AB: alveolar bone, T: tooth, PL: periodontal ligament).

control group and were significantly lower in the MN+PER group compared with the PER group (p =0.035, p= 0.041). In contrast, there were no significant differences in the serum levels of MMP-8 and MMP-13 between all groups (p=0.067, p=0.082) (Table 2). According to these results, while M. nigra treatment significantly reduced MMP 8 and MMP-13 levels in gingival tissue (p=0.035, p=0.041), no significant differences were detected between the C and MN+PER groups (p= 0.075).

Histopathological, histometric and immunohistochemical results

In the histopathological evaluation, normal histological structures, connective tissue, and fiber organization were observed in sections of the control group (Figure 2). In the sections of the PER group, resorption of alveolar bone, degradation of periodontal ligaments, disorganization of

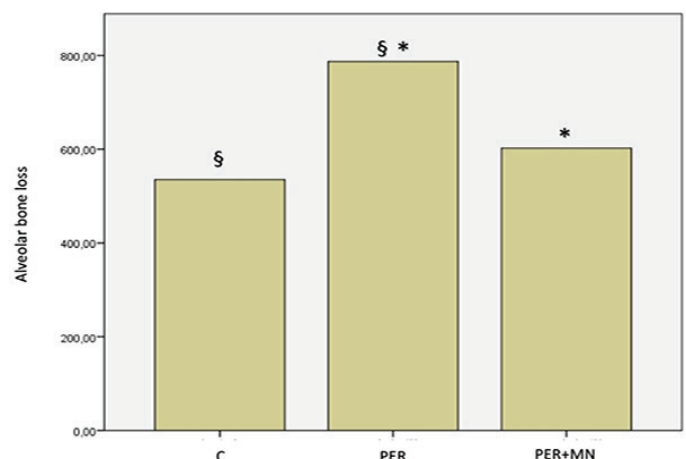


Figure 3. Graphical representation of the mean alveolar bone loss in the study groups (C: control group, PER: experimental periodontitis, MN+PER: experimental periodontitis group treated with morus nigra).

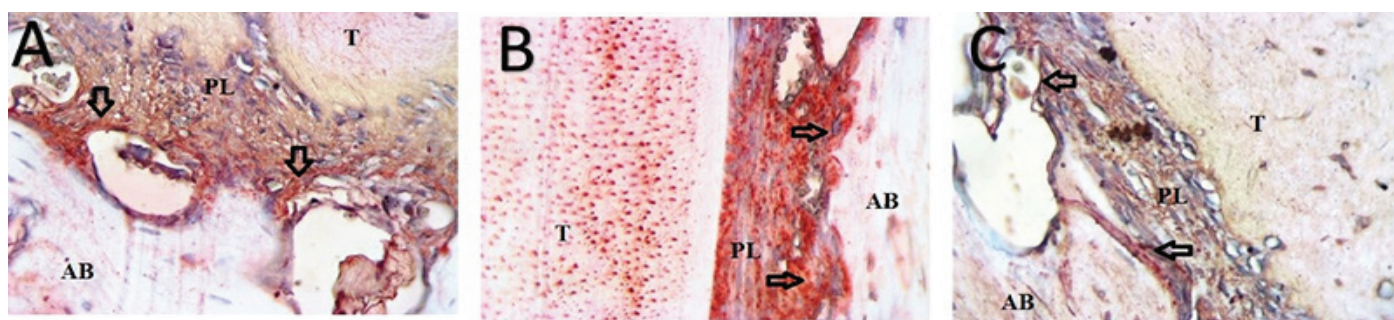


Figure 4. RANKL expressions in the study groups. (A) control group at 200x magnification, (B) periodontitis group at 200x magnification, (C) periodontitis group treated with morus nigra at 200x magnification (AB: alveolar bone, T: tooth, PL: periodontal ligament).

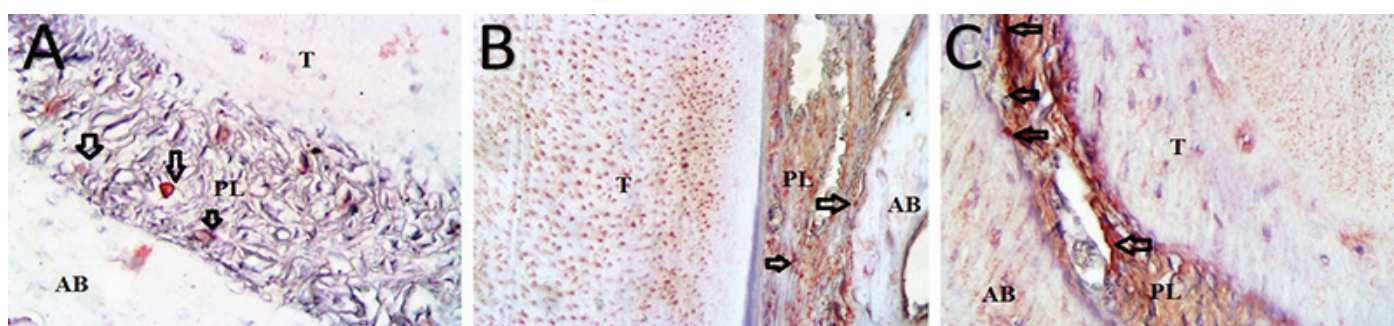


Figure 5. OPG expressions in the study groups. (A) control group at 200x magnification, (B) periodontitis group at 200x magnification, (C) periodontitis group treated with morus nigra at 200x magnification (AB: alveolar bone, T: tooth, PL: periodontal ligament).

These results show that the levels of RANKL were higher in PER group when compared to the control group (Figure 4) (Table 3). These findings also present that the administration of *M. nigra* markedly decreased the level of anti-RANKL-positive cells in comparison with the PER group ($p = 0.037$) (Figure 4). In addition, the immunoreactivity level of OPG decreased in the PER group when compared with the MN+PER group (Figure 5) (Table 3). Also significant differences were observed between the PER and MN+PER groups ($p = 0.021$). However, the immunoreactivity levels of OPG were similar in the C and MN+PER groups (Figure 5) ($p = 0.085$).

Discussion

The current study establishes the therapeutic effects of *M. nigra* on alveolar bone loss in rats with experimental periodontitis. Our findings show that MMP-8 and MMP-13 levels were significantly lower in the MN+PER group ($p = 0.035$, $p = 0.041$). Further, in the MN+PER group, alveolar bone resorption decreases and the levels of RANKL were higher in PER group. Furthermore, the immunoreactivity level of OPG decreased in the PER group.

M. Nigras importance has been shown in worldwide for over 40 years by experimental studies (12). *M. nigra* has many characteristics that include analgesic, diuretic, antitussive, sedative, anxiolytic, and hypotensive properties. Furthermore, it has been used in the treatment of various disorders (pharyngitis, toothache, snake bites), including inflammatory diseases (10). Inflammation is a complex of defensive reactions to remove the irritating stimuli from the organism with various pathophysiological stimuli to repair tissue. Periodontitis is also a chronic inflammatory disease connected with the destruction of tissue (19). In the

current research, we revealed the therapeutic effects of *M. nigra* extract on alveolar bone loss, RANKL, OPG expression, and MMP-8 and MMP-13 levels in both tissue and serum in a rat periodontitis model. The present study is the first to demonstrate the effects of *M. nigra* on these variables in an experimental periodontitis model.

Periodontitis is an inflammatory disorder characterized with degradation of extra-cellular matrix (ECM), connective and bone tissues. MMP-8 and MMP-13 including collagenases are able to degradate all components of ECM (24). MMP-8, the main interstitial collagenase, destroys the ECM in periodontitis. We can also accept that MMP-8 is the main form of collagenase in chronic periodontal diseases (20). In the current research, the highest tissue MMP-8 levels were detected in the PER group. There was a significant difference between the PER and MN+PER groups. However, serum MMP-8 levels were similar in all groups. These results may explain how periodontal diseases commonly cause local inflammation. *Morus nigra*, includes germanicol, betulinic acid and β sitosterol (10). The anti-inflammatory properties of betulinic acid were demonstrated with the experimental models in mice (21). β Sitosterol was found to possess potent anti-inflammatory activity, similar to that of hydrocortisone when administered intraperitoneally (22). For these properties, findings of this study suggest that *M. nigra* extract may reduce MMP-8 expression by its anti-inflammatory properties. The anti-inflammatory properties of *M. nigra* extract have also been shown in the literature (10, 23). In addition, most studies have shown that the levels of MMPs are higher with periodontitis compared with gingivitis or the levels observed in healthy people (24, 25). Similar to our results, previous studies have suggested that MMP-8 levels are higher in periodontitis sites than in healthy control sites (25).

MMP-13 has significant role in the pathological processes of periodontitis, rheumatoid arthritis, and osteoarthritis (26). The level of collagenase is increased with different disorders characterized by the destruction of bone and non-mineralized connective tissues, such as with periodontitis (26). The current study investigated the therapeutic effects of *M. nigra* in experimental periodontitis. Our findings suggest that *M. nigra* can significantly reduce only tissue MMP-13 levels and not serum levels in the MN+PER group in experimental periodontitis. Serum findings were not different between groups, it may be related that experimental periodontitis was only in the lower molar region. There was no severe inflammatory response to affect the level of inflammatory mediators in the serum. Furthermore, we observed that these results may be attributed to the inhibitory effects of *M. nigra* on MMP-13 expression. Previous studies have suggested that pro-inflammatory cytokines are found in increased levels in periodontitis sites and can stimulate MMP-13 expression (6, 27). Zelova et al. (19) reported that compounds of *M. Nigra* (prenylated flavonoids, kuwanon, morusinol) inhibit the dominant role of TNF- α and IL-1 β in the pathogenesis of inflammation. However, we found no studies which have investigated the effect of *M. nigra* on MMP-13 levels in ligature-induced rat periodontitis. Previous studies have also observed that alveolar bone resorption is affected by the level of MMP 13 expression (6, 26). Hence, the therapeutic effects of *M. nigra* on alveolar bone may partially contribute to the decrease in MMP-13 levels (28).

OPG and RANKL can be found in different tissues and fluids such as serum, saliva, gingival crevicular fluid (GCF), and gingival tissue. These findings can aid in identifying the periodontal disease severity (29). Garlet et al. (30) reported that the levels of both RANKL and OPG expressions were increased in gingival tissues (aggressive periodontitis [AP] and chronic periodontitis [CP] tissues) compared to healthy tissues. In the present research, we also examined RANKL and OPG levels to assess periodontal bone level in ligature induced periodontitis. Bone formation and resorption are related to RANK-RANKL and OPG. OPG binds to RANKL and inhibits the RANK-RANKL connection and osteoclastic bone resorption (8). The ratio RANKL/OPG levels plays an important role bone resorption in periodontitis (1). This ratio is increased at the sites of active periodontal disease and is also related to the disease severity (29).

In the current study, we detected a significant effect of *M. nigra* on RANKL and OPG levels. The RANKL level was lower and the OPG level was higher in the MN+PER group compared to the PER group. RANKL is a member of the TNF ligand super-family which is responsible for osteoclast activation and increased of bone loss (4). For these reasons, we observed that treatment of *M. Nigra* can change these events by regulating RANKL expression via decreasing the release of pro-inflammatory molecules with support the bone remodeling. This finding may be related to the anti-inflammatory effect of *M. nigra*. These results suggest that *M. nigra* also has antiresorptive effects on alveolar bone. Many studies have reported that the GCF levels of RANKL are increased patients with periodontal diseases. In addition, additional host response modulation therapies could be beneficial in decreasing the RANKL/OPG ratio for periodontal

disease treatment (4). Most studies have reported that the ligature-induced experimental periodontitis model increases RANKL activity (1, 29). The limitations of this study may be the only administration of *M. nigra* systemically in a single dose. The number of groups could be increased and the effect of the *M. nigra* on periodontitis at different doses could be evaluated.

Conclusion

This study demonstrates that *M. nigra* treatment significantly decrease MMP-8 and MMP-13 levels in periodontal tissue through its anti-inflammatory properties. Our results also shows that *M. nigra* inhibits alveolar bone resorption by suppressing the expression of RANKL and OPG. However, the therapeutic effects of the *M. nigra* should be explored in further studies.

Türkçe Öz: *Morus nigra*'nın deneysel olarak oluşturulmuş periodontite alveolar kemik kaybı üzerine etkisi. Amaç: Bu çalışmanın amacı, *Morus nigra*'nın ratlarda deneysel olarak oluşturulmuş periodontitis üzerindeki anti-enflamatuar etkisini değerlendirmektir. Gereç ve Yöntem: Yirmi dört Wistar-albino rat; kontrol (K, n = 8), deneysel periodontitis (PER, n = 8), deneysel periodontitis ve *Morus nigra* (MN + PER, n = 8) (21 gün boyunca günde 50 mg / kg) olmak üzere üç gruba ayrıldı. 21 gün sonra, ratlar sakrifiye edildi ve alveolar kemikleri histopatolojik olarak değerlendirildi ve alveolar kemik kaybı seviyesini belirlemek için histometrik analizler kullanıldı. RANKL ve OPG düzeyi immünohistokimyasal olarak tespit edildi. Ayrıca Serum ve doku MMP-8 ve MMP-13 seviyeleri de analiz edildi. Bulgular: *Morus nigra* tedavisinin doku MMP-8 ve MMP-13 seviyesini azalttığı ve MMP-8 ve MMP-13 doku seviyelerinde PER ve MN + PER grupları arasında anlamlı fark olduğu tespit edilmiştir (p = 0.035, p = 0.041). Buna karşın, tüm gruplar arasında MMP-8 ve MMP-13 serum seviyeleri konusunda anlamlı bir fark yoktur (p = 0.067, p = 0.082). Histometrik değerlendirmede, alveolar kemik kaybı PER grubunda K ve MN gruplarına göre daha yüksektir (p = 0.035). RANKL aktivitesi PER grubuna kıyasla MN + PER grubunda anlamlı olarak daha düşük bulunmuştur (p = 0.037) ve OPG aktivitesi ise, MN + PER grubunda anlamlı olarak daha yüksek tespit edilmiştir (p = 0.021). Sonuç: Bu çalışma *Morus nigra*'nın sistemik uygulamasının bölgesel alveolar kemik rezorpsiyonunu anlamlı şekilde inhibe ettiğini ve deneysel-periodontitis oluşturulan rat modellerinde periodontal iyileşmeye katkıda bulunduğunu ortaya koymaktadır. Anahtar Kelimeler: Deneysel periodontitis; sitokin; MMP-8; MMP-13; *morus nigra*

Ethics Committee Approval: The study protocol was approved by the Animal Experimental Ethics Committee of the Firat University, Elazığ, Turkey (No: 2012-013).

Informed Consent: Not required.

Peer-review: Externally peer-reviewed.

Author contributions: TTY and CAK designed the study. GO, TK, NK and EE participated in generating the data for the study. SD, ND, NK and EE participated in gathering the data for the study. GO, TK and ND participated in the analysis of the data. TTY and AB wrote the majority of the original draft of the paper. TTY and SD participated in writing the paper. All authors approved the final version of this paper.

Conflict of Interest: The author had no conflict of interest to declare.

Financial Disclosure: This work was funded by the Firat University Scientific Research Project Coordinatorship (DHF.15.02) Elazığ, Turkey.

References

- Saglam M, Koseoglu S, Hatipoglu M, Esen HH, Koksali E. Effect of sumac extract on serum oxidative status, RANKL/OPG system and alveolar bone loss in experimental periodontitis in rats. *J Appl Oral Sci* 2015;23(1):33-41. [\[CrossRef\]](#)
- Papageorgiou SN, Hagner M, Nogueira AV, Franke A, Jager A, Deschner J. Inflammatory bowel disease and oral health: systematic review and a meta-analysis. *J Clin Periodontol* 2017. [\[CrossRef\]](#)
- Bostanci V, Toker H, Senel S, Ozdemir H, Aydin H. Effect of chronic periodontitis on serum and gingival crevicular fluid oxidant and antioxidant status in patients with familial Mediterranean fever before and after periodontal treatment. *J Periodontol* 2014;85(5):706-12. [\[CrossRef\]](#)
- Arabaci T, Kermen E, Ozkanlar S, Kose O, Kara A, Kizildag A, Duman SB, Ibisoglu E. Therapeutic effects of melatonin on alveolar bone resorption after experimental periodontitis in rats: a biochemical and immunohistochemical study. *J Periodontol* 2015;86(7):874-81. [\[CrossRef\]](#)
- Ozcan E, Isil Saygun N, Serdar MA, Umut Bengi V, Kantarci A. Non-Surgical Periodontal Therapy Reduces Saliva Adipokine and Matrix Metalloproteinase Levels in Periodontitis. *J Periodontol* 2016;87(8):934-43. [\[CrossRef\]](#)
- Yang D, Wang J, Ni J, Shang S, Liu L, Xiang J, Li C. Temporal expression of metalloproteinase-8 and -13 and their relationships with extracellular matrix metalloproteinase inducer in the development of ligature-induced periodontitis in rats. *J Periodontol* 2013;48(4):411-9. [\[CrossRef\]](#)
- Bassil J, Senni K, Changotade S, Baroukh B, Kassis C, Naaman N, Godeau G. Expression of MMP-2, 9 and 13 in newly formed bone after sinus augmentation using inorganic bovine bone in human. *J Periodontol* 2011;46(6):756-62. [\[CrossRef\]](#)
- Karakan NC, Akpınar A, Goze F, Poyraz O. Investigating the effects of systemically administered strontium ranelate on alveolar bone loss histomorphometrically and histopathologically on experimental periodontitis in Rats. *J Periodontol* 2016;88(2):1-17. [\[CrossRef\]](#)
- Silva N, Dutzan N, Hernandez M, Dezerega A, Rivera O, Aguilon JC, Aravena O, Lastres P, Pozo P, Vernal R, Gamonal J. Characterization of progressive periodontal lesions in chronic periodontitis patients: levels of chemokines, cytokines, matrix metalloproteinase-13, periodontal pathogens and inflammatory cells. *J Clin Periodontol* 2008;35(3):206-14. [\[CrossRef\]](#)
- Padilha MM, Vilela FC, Rocha CQ, Dias MJ, Soncini R, dos Santos MH, Alves-da-Silva G, Giusti-Paiva A. Anti-inflammatory properties of *Morus nigra* leaves. *Phytother Res* 2010;24(10):1496-500. [\[CrossRef\]](#)
- Naderi GA, Asgary S, Sarraf-Zadegan N, Oroojy H, Afshin-Nia F. Antioxidant activity of three extracts of *Morus nigra*. *Phytother Res* 2004;18(5):365-9. [\[CrossRef\]](#)
- Volpato GT, Calderon IM, Sinzato S, Campos KE, Rudge MV, Damasceno DC. Effect of *Morus nigra* aqueous extract treatment on the maternal-fetal outcome, oxidative stress status and lipid profile of streptozotocin-induced diabetic rats. *J Ethnopharmacol* 2011;138(3):691-6. [\[CrossRef\]](#)
- Ozan F, Tepe B, Polat ZA, Er K. Evaluation of in vitro effect of *Morus rubra* (red mulberry) on survival of periodontal ligament cells. *Oral Surg Oral Med Oral Pathol Oral Radiol Endod* 2008;105(2):e66-9. [\[CrossRef\]](#)
- Aral CA, Kesim S, Greenwell H, Kara M, Cetin A, Yakan B. Alveolar bone protective and hypoglycemic effects of systemic propolis treatment in experimental periodontitis and diabetes mellitus. *J Med Food* 2015;18(2):195-201. [\[CrossRef\]](#)
- Akman S, Canakci V, Kara A, Tozoglu U, Arabaci T, Dagsuyu IM. Therapeutic effects of alpha lipoic acid and vitamin C on alveolar bone resorption after experimental periodontitis in rats: a biochemical, histochemical, and stereologic study. *J Periodontol* 2013;84(5):666-74. [\[CrossRef\]](#)
- Cuzzocrea S, Zingarelli B, Hake P, Salzman AL, Szabo C. Antiinflammatory effects of mercaptoethylguanidine, a combined inhibitor of nitric oxide synthase and peroxynitrite scavenger, in carrageenan-induced models of inflammation. *Free Radic Biol Med*. 1998;24(3):450-9. [\[CrossRef\]](#)
- Lucinda LM, de Oliveira TT, Salvador PA, Peters VM, Reis JE, Guerra Mde O. Radiographic evidence of mandibular osteoporosis improvement in Wistar rats treated with *Ginkgo biloba*. *Phytother Res* 2010;24(2):264-7. [\[CrossRef\]](#)
- Remmele W, Stegner HE. [Recommendation for uniform definition of an immunoreactive score (IRS) for immunohistochemical estrogen receptor detection (ER-ICA) in breast cancer tissue]. *Pathologie* 1987;8(3):138-40.
- Zelova H, Hanakova Z, Cermakova Z, Smejkal K, Dall Acqua S, Babula P, Cvacka J, Hosek J. Evaluation of anti-inflammatory activity of prenylated substances isolated from *Morus alba* and *Morus nigra*. *J Nat Prod* 2014;77(6):1297-303. [\[CrossRef\]](#)
- Balli U, Cetinkaya BO, Keles GC, Keles ZP, Guler S, Sogut MU, Erisgin Z. Assessment of MMP-1, MMP-8 and TIMP-2 in experimental periodontitis treated with kaempferol. *J Periodontol Implant Sci* 2016;46(2):84-95. [\[CrossRef\]](#)
- Mukherjee PK, Saha K, Das J, Pal M, Saha BP. Studies on the anti-inflammatory activity of rhizomes of *Nelumbo nucifera*. *Planta Med* 1997;63(4):367-9. [\[CrossRef\]](#)
- Gupta MB, Nath R, Srivastava N, Shanker K, Kishor K, Bhargava KP. Anti-inflammatory and antipyretic activities of beta-sitosterol. *Planta Med* 1980;39(2):157-63. [\[CrossRef\]](#)
- de Queiroz GT, Santos TR, Macedo R, Peters VM, Leite MN, de Cassia da Silveira e Sa R, de Oliveira Guerra M. Efficacy of *Morus nigra* L. on reproduction in female Wistar rats. *Food Chem Toxicol* 2012;50(3-4):816-22. [\[CrossRef\]](#)
- Bastos MF, Tucci MA, de Siqueira A, de Faveri M, Figueiredo LC, Vallim PC, Duarte PM. Diabetes may affect the expression of matrix metalloproteinases and their inhibitors more than smoking in chronic periodontitis. *J Periodontol* 2016. [\[CrossRef\]](#)
- Johnson N, Ebersole JL, Kryscio RJ, Danaher RJ, Dawson D, 3rd, Al-Sabbagh M, Miller CS. Rapid assessment of salivary MMP-8 and periodontal disease using lateral flow immunoassay. *Oral Dis* 2016;22(7):681-7. [\[CrossRef\]](#)
- de Aquino SG, Guimaraes MR, Stach-Machado DR, da Silva JA, Spolidorio LC, Rossa C, Jr. Differential regulation of MMP-13 expression in two models of experimentally induced periodontal disease in rats. *Arch Oral Biol* 2009;54(7):609-17. [\[CrossRef\]](#)
- Gorska R, Gregorek H, Kowalski J, Laskus-Perendyk A, Syczewska M, Madalinski K. Relationship between clinical parameters and cytokine profiles in inflamed gingival tissue and serum samples from patients with chronic periodontitis. *J Clin Periodontol* 2003;30(12):1046-52. [\[CrossRef\]](#)
- Dong Y, Huihui Z, Li C. Piperine inhibit inflammation, alveolar bone loss and collagen fibers breakdown in a rat periodontitis model. *J Periodontol* 2015;50(6):758-65. [\[CrossRef\]](#)
- Behfarnia P, Saied-Moallemi Z, Javanmard SH, Naseri R. Serum, saliva, and GCF concentration of RANKL and osteoprotegerin in smokers versus nonsmokers with chronic periodontitis. *Adv Biomed Res* 2016;5:80. [\[CrossRef\]](#)
- Garlet GP, Martins W, Jr., Fonseca BA, Ferreira BR, Silva JS. Matrix metalloproteinases, their physiological inhibitors and osteoclast factors are differentially regulated by the cytokine profile in human periodontal disease. *J Clin Periodontol* 2004;31(8):671-9. [\[CrossRef\]](#)