

Delayed Splenic Rupture; Normal Appearing Spleen on the Initial Multidetector Computed Tomography (MDCT) Can Sometimes Be Misleading

Alireza Hamidian Jahromi,¹ Matias Migliaro,² Melisa Romano,³ and Guillermo Sangster^{4,*}

¹Department of Surgery, Louisiana State University Health-Shreveport, LA, United States

²Department of Radiology, Fundacion Escuela de Medicina Nuclear, Mendoza, Argentina

³Department of Radiology, El Carmen Hospital, Mendoza, Argentina

⁴Department of Radiology, Louisiana State University Health Shreveport, LA, United States

*Corresponding author: Guillermo Sangster, Department of Radiology, Louisiana State University Health Shreveport, LA, United States. Tel: +318-6756345, E-mail: gsangs@lsuhsc.edu

Received 2014 October 11; Revised 2014 December 17; Accepted 2014 December 23.

Abstract

Introduction: Delayed splenic rupture (DSR) is an unusual outcome following blunt abdominal trauma. Although DSR is defined as bleeding more than 48 hours after blunt trauma in a previously hemodynamically stable patient, a review of the reported cases in the literature shows that in almost all of the cases the initial CT imaging revealed some form of damage to the spleen.

Case Presentation: Here we describe an extremely rare condition in a case that presented with a DSR following blunt trauma and had a normal appearing spleen in the initial post trauma MDCT scan.

Conclusions: DSR is a serious consequence of trauma and is associated with a significantly higher mortality rate compared with the overall mortality for acute splenic injuries. A High index of suspicion along with the liberal serial utilization of the imaging studies are the essential elements for early detection of DSR. We propose that DSR be considered as a differential diagnosis in patients presenting with hemodynamic instability late post trauma, even when the immediate post trauma MDCT scan has shown a normal appearing spleen. We suggest that every patient with a high impact injury or injuries to peri-splenic organs should have a repeat MDCT scan 2-3 days post trauma or before the patients is discharged from hospital.

Keywords: Delayed Splenic Rupture, Spleen, Blunt Trauma, Complications, CT Scan, Imaging, Multidetector Computed Tomography, MDCT

1. Introduction

The spleen, the most commonly injured solid organ following blunt abdominal trauma, is generally a fragile organ and manifests its damage mostly in the early period post injury with lacerations, sub-capsular and intra-parenchymal hematoma, and/or symptoms of intra-peritoneal hemorrhage and shock (1). Delayed post traumatic rupture of the spleen is an unusual outcome and has been reported to occur between two and 70 days post trauma (mostly happens 4-8 days post injury) (2-4). Along with pseudocysts, abscesses, and pseudoaneurysms, delayed splenic rupture (DSR) is considered as a complication of splenic injuries (3).

Although DSR is defined as bleeding more than 48 hours after blunt trauma in a previously hemodynamically stable patient (4,5), a review of the reported cases in the literature shows that in almost all of the cases the initial multidetector computed tomography (MDCT) imaging has re-

vealed some form of damage to the spleen. The importance of delayed splenic rupture lies in its significantly higher mortality rate (5% -15%), compared with the 1% overall mortality for acute splenic injuries (4). Kluger et al. (5) proposed that a high index of suspicion along with the liberal serial utilization of the imaging studies were the essential elements for early detection of DSR and called these injuries "injuries in evolution" in which the extent of organ damage has not been appreciated enough in the initial films.

MDCT is currently considered as the imaging modality of choice for detecting splenic injuries with a sensitivity and specificity reaching 95% (6). DSR in the setting of normal appearance of spleen in the initial post trauma MDCT is extremely rare and has not been reported before.

2. Case Presentation

A 49-year-old male was a restrained driver of a motor vehicle when he had a rollover and was partially ejected through the windshield. On arrival to our trauma center, he had a Glasgow Coma Scale of 15, neurologically intact, and complained of spine tenderness. On admission, a MDCT of the neck, chest, abdomen and pelvis was performed. Imaging findings included a non-displaced C2 fracture and a right posterior 9th rib fracture. No other acute findings were seen in the initial abdomen and pelvis imaging (Figure 1). The patient was admitted to the Intensive Care Unit for further evaluation and treatment.

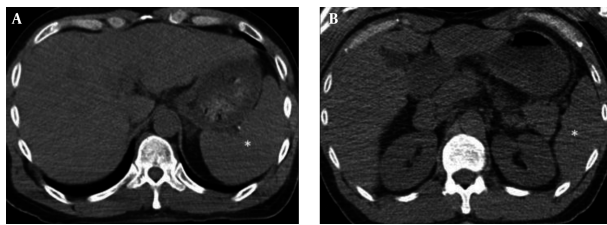


Figure 1. Axial Unenhanced MDCT of the Abdomen (A, B) Which Shows a Normal Splenic Parenchyma (*) With no Free Fluid in the Abdomen

Three days after admission, the patient had an abrupt drop in his hemoglobin from 16.2 to 6.5 mg/dL. A repeat abdomen and pelvis MDCT with intravenous contrast revealed a grade three splenic laceration with peri-splenic and peri-hepatic hemoperitoneum (Figure 2). The patient was taken to the operating room for emergent exploratory laparotomy and splenectomy was performed. Fourteen days after trauma the patient was discharge home.

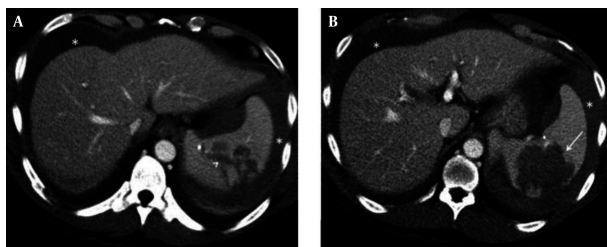


Figure 2. Grade Three Splenic Laceration Axial contrast-enhanced MDCT of the abdomen demonstrates multiple low-density lines in the spleen (arrowhead) the largest measuring more than 3 cm (A) consistent with intraparenchymal lacerations. A large poorly marginated intraparenchymal hematoma with areas of devascularization (arrow) is also seen (B). Hemoperitoneum is noted (*).

3. Discussion

While there has been a paradigm shift towards non-operative management of hemodynamically stable pa-

tients with blunt splenic injuries over the last three decades, non-operative management of blunt splenic injuries is now widely practiced. The decision to attempt non-operative management is largely determined by the initial image findings among other clinical factors, including patient's age, presence of concurrent injuries, and the ability to perform reliable serial clinical assessments.

While no reliable predicting factor for a DSR has been recognized, the risk of DSR should always be highly considered when deciding to go down the non-operative route for management in the patients. Our case is one such example for the fact that a normal appearance of the spleen on the initial MDCT scan could well have been a false reassurance. If the MDCT scan was done before the subcapsular hematoma formation, or before its growth was a visible size, the MDCT may have failed to detect the splenic injury. In cases with high impact injuries, and in the presence of surrounding organ injuries (i.e., left lower rib fractures), a repeat MDCT scan 2 - 3 days post trauma or before the patients get discharged could potentially detect the hidden splenic injury.

The classic triad associated with blunt splenic rupture left hemidiaphragm elevation, left lower lobe atelectasis, and left pleural effusion is frequently absent and cannot be considered a reliable indicator. Any patient who does have left hemidiaphragm elevation after blunt trauma should be considered as having a hidden splenic injury until it is proven otherwise (7).

While the exact mechanism of DSR is not known, there are several theories proposed to explain the pathophysiology of DSR. These theories include: (1) increased capsular pressure secondary to clot lysis and subsequent increased oncotic pressure causing a free rupture of the spleen capsule; (2) tamponade of the a perisplenic hematoma by surrounding organs or omentum which will later rupture freely into the peritoneal cavity; (3) delayed bleeding that may be caused by the rupture of a post traumatic intraparenchymal pseudoaneurysm or splenic pseudocyst.

The treatment of choice for DSR is splenectomy, as splenorrhaphy can be extremely difficult especially in the group of patients in whom non-surgical treatment has failed. Some centers have successfully performed angioembolization in hemodynamically stable patients as well.

3.1. Conclusion

In conclusion, we propose that DSR be considered as a differential diagnosis in patients presenting with hemodynamic instability late post trauma, even when the immediate post trauma MDCT has showed a normal appearing spleen. While high index of suspicion is essential for early

detection of DSR, patients with high impact injuries or surrounding organs damage should be considered for a follow up MDCT scan 2 - 3 days post trauma or before the patients discharge from hospital.

Acknowledgments

The authors would like to thank Ms. Talicia Tarver who provided us editorial assistance.

References

1. Chan CKM, Chiu HS, Chung CH. Delayed rupture of occult splenic injury: a case report. *Hong Kong J Emerg Med.* 2003;**10**(3):188-90.
2. Resteghini N, Nielsen J, Hoimes ML, Karam AR. Delayed splenic rupture presenting 70 days following blunt abdominal trauma. *Clin Imaging.* 2014;**38**(1):73-4. doi: [10.1016/j.clinimag.2013.09.003](https://doi.org/10.1016/j.clinimag.2013.09.003). [PubMed: [24139835](https://pubmed.ncbi.nlm.nih.gov/24139835/)].
3. Hassan R, Abd Aziz A, Md Ralib AR, Saat A. Computed tomography of blunt spleen injury: a pictorial review. *Malays J Med Sci.* 2011;**18**(1):60-7. [PubMed: [22135575](https://pubmed.ncbi.nlm.nih.gov/22135575/)].
4. Marincek B, Dondelinger RF. Emergency radiology: imaging and intervention. Germany: Springer-Verlag Berlin Heidelberg; 2007. pp. 75-80.
5. Kluger Y, Paul DB, Raves JJ, Fonda M, Young JC, Townsend RN, et al. Delayed rupture of the spleen—myths, facts, and their importance: case reports and literature review. *J Trauma.* 1994;**36**(4):568-71. [PubMed: [8158722](https://pubmed.ncbi.nlm.nih.gov/8158722/)].
6. Khan SA, Muhammad I, Laabei F, Rothwell J. An unusual presentation of non pathological delayed splenic rupture: a case report. *Cases J.* 2009;**2**:6450. doi: [10.4076/1757-1627-2-6450](https://doi.org/10.4076/1757-1627-2-6450). [PubMed: [19829806](https://pubmed.ncbi.nlm.nih.gov/19829806/)].
7. Freiwald S. Late-presenting complications after splenic trauma. *Perm J.* 2010;**14**(2):41-4. [PubMed: [20740116](https://pubmed.ncbi.nlm.nih.gov/20740116/)].