

Endoscopic closure of tympanic membrane anterior perforation using a strip-type chondroperichondrial graft

Ao Li, PhD^{a,b}, Zheng Liang, MD^{a,b}, Hong Chen, MD^{a,b}, Ye Yang, MD^{a,b}, Yuqin Xu, MD^{a,b}, Xia Gao, PhD^{a,b}, Jie Chen, PhD^{a,b,*} 

Abstract

Myringoplasty is a surgical procedure to reconstruct tympanic perforation. However, repair of anterior perforations is still challenging. To analyze the anatomical and hearing outcomes of myringoplasty with a new technique of chondroperichondrial graft via endoscopy, 23 adult patients were retrospectively analyzed. All patients had anterior perforations of tympanic membranes that were repaired with a composite strip-type cartilage-perichondrium graft through a total endoscopic transcanal approach. The anatomical graft success rate at postoperative 1 month was 86.96% (20/23) and reached 100% at the 6- and 12-month follow-up. Compared to the preoperative air conduction threshold (44.7 ± 13.56 dB) and air-bone gap (ABG) (22.35 ± 6.54 dB), the postoperative air conduction threshold and ABG decreased to 33.52 ± 10.88 dB and 12.52 ± 3.94 dB, respectively ($P < .0001$). Twenty-two (95.65%) patients had an ABG below 20 dB postoperatively. The mean ABG improvement in our cohort was 9.83 ± 5.00 dB. The functional graft success rate was 95.65% (22/23). The convenience, reliability, time, and labor savings accrued from the approach described here make it a good choice for repair of anterior perforation of tympanic membrane.

Abbreviations: ABG = air-bone gap, ACT = air conduction threshold, TM = tympanic membrane.

Keywords: endoscopic ear surgery (EES), myringoplasty, strip-type chondroperichondrial graft, tympanic membrane perforation

1. Introduction

Several conditions may lead to tympanic membrane perforation, such as acute otitis media, chronic otitis media, trauma, or ear tuberculosis.^[1,2] Ever since Wullstein^[3] and Zöllner^[4] first introduced the modern tympanoplasty techniques, numerous studies have introduced novel surgical techniques and choices of graft materials for tympanoplasty or myringoplasty. Most surgical methods for repair of tympanic membrane (TM) perforation are associated with a success rate of over 90%.^[5] Temporalis fascia and cartilage are the commonly used autografts for myringoplasty. In the last 20 years, various studies have demonstrated that stiffness of cartilage helps achieve better stability and long-term uptake than fascia, making it a better choice in some difficult situations, such as poor eustachian tube function, infection, anterior perforation, and revision surgeries. Cartilage not only provides firm scaffolding but also leads to a high rate of perforation closure and satisfactory hearing results. However, the process for shaping the cartilage

graft increases the operative time. Moreover, the opacity of cartilage tissue makes it difficult to examine the tympanic cavity postoperatively.

Myringoplasty performed in an underlay fashion is more commonly used because it is easier to perform and less time consuming.^[6] Achieving complete closure of a TM perforation depends on its location and the graft and techniques used. Studies have shown that TM perforations in the anterior quadrant are associated with lower surgical success rates than those in other quadrants because of insufficient visualization, poor vascularization, and poor stabilization.^[7] The modifications of the underlay method include the mediolateral graft, window shade, loop overlay, and hammock techniques. Although improved, these operations necessitate postauricular incision, which extends the operating time and prolongs the postoperative recovery.

Endoscopic tympanoplasty has been popular since the 1990s. In contrast to microscopy, it provides panoramic vision with sufficient exposure of the anterior margins and satisfactory

AL and ZL have contributed equally to this work. XG and JC are co-correspondents.

This study was supported by the Fellowship of China Postdoctoral Science Foundation under Grant [2020M681561]; and the National Natural Science Foundation of China under Grant [82101223, 81970884].

The authors have no conflicts of interest to disclose.

The datasets generated during and/or analyzed during the current study are not publicly available, but are available from the corresponding author on reasonable request.

^a Department of Otolaryngology Head and Neck Surgery, Nanjing Drum Tower Hospital, The Affiliated Hospital of Nanjing University Medical School, Jiangsu Provincial Key Medical Discipline (Laboratory), Nanjing, China, and ^b Research Institute of Otolaryngology, Nanjing, China.

*Correspondence: Jie Chen, PhD, Department of Otolaryngology Head and Neck Surgery, Nanjing Drum Tower Hospital, The Affiliated Hospital of Nanjing

University Medical School, Jiangsu Provincial Key Medical Discipline (Laboratory), No. 321 Zhongshan Road, Nanjing 210008 (e-mail: njjichen@yeah.net).

Copyright © 2022 the Author(s). Published by Wolters Kluwer Health, Inc. This is an open-access article distributed under the terms of the Creative Commons Attribution-Non Commercial License 4.0 (CCBY-NC), where it is permissible to download, share, remix, transform, and buildup the work provided it is properly cited. The work cannot be used commercially without permission from the journal.

How to cite this article: Li A, Liang Z, Chen H, Yang Y, Xu Y, Gao X, Chen J. Endoscopic closure of tympanic membrane anterior perforation using a strip-type chondroperichondrial graft. *Medicine* 2022;101:33(e30037).

Received: 15 February 2022 / Received in final form: 7 June 2022 / Accepted: 27 June 2022

<http://dx.doi.org/10.1097/MD.000000000030037>

audiologic results, and it is minimally invasive.^[6,7] Although anterior perforations can be safely managed with a transcanal endoscopic approach, the 1-handed mode of operation is often challenging for otologists. In particular, graft displacement and dislocation is liable to occur after placement of the graft, or when the flap is lifted to fill the cavity with a gelatin sponge. Moreover, a 1-handed maneuver is less supportive and requires assistance.

In this study, we propose a modified graft called a “strip-type chondroperichondrial graft,” which has cartilage at the anterior side while the remaining part is comprised of perichondrium. This technique not only offers the advantages of translucency of the perichondrium and the rigidity of cartilage to reinforce the anterior margin but may also expedite and standardize graft placement. We aimed to evaluate the feasibility and outcomes of myringoplasty for anterior perforations using this technique performed via an endoscopic transcanal approach.

2. Materials and Methods

2.1. Patients

In this study, we retrospectively analyzed 23 adult patients who underwent endoscopic transcanal myringoplasty (tympanoplasty type I) between December 2019 and April 2020 at our center. The study protocol was approved by the Ethics Committee of the Nanjing Drum Tower Hospital.

The inclusion criteria were as follows: (1) Patients with a TM anterior quadrant perforation (minimum 3 mm in size but no >50% of the TM area) requiring primary surgery; (2) Patients with a minimum follow-up period of 1 year; (3) Patients without ossicular chain disease, middle-ear cholesteatoma (as assessed by temporal bone computed tomography or magnetic resonance imaging), retraction pockets or active infection. Strip-type chondroperichondrial grafts were used in all patients. Graft placement was done according to our own surgical techniques.

2.2. Clinical outcomes

The presence of graft perforation, lateralization, and retraction was evaluated endoscopically at postoperative 1, 6, and 12 months. Standard pure-tone audiometry (PTA) at frequencies of 0.5, 1, 2, and 4 kHz was performed 1 week before surgery and 12 months after surgery. Pre- and postoperative air conduction thresholds (ACTs) and air-bone gaps were calculated according to the PTA of the patients. ABG closure (improvement) was also calculated postoperatively. Any postoperative complications were recorded. The duration of the operation (defined as the time from graft harvesting to the insertion of NasoPores in the ear canal) was noted. The functional graft success criteria were complete closure of the TM (anatomical graft success without perforation, retraction, or lateralization) with a reduction in the ABG to < 20 dB.

2.3. Surgical techniques

All operations were performed under general anesthesia by the same otologist with >20 years of surgical experience, and all patients provided written informed consent for operation. Rigid endoscopes (Karl Storz, 4.0-mm, 0°, 18-cm-long lens) and a high-resolution monitor (XiON GmbH, 24 INCH Full HD) were used in our surgical process. The general procedure was similar to that of traditional type 1 tympanoplasty (with elevation of the tympanomeatal flap). The key steps involved graft harvest and placement. Briefly, 1% lidocaine hydrochloride and 1:100,000 epinephrine were injected for local infiltration of the tragus and external auditory canal under direct endoscopic visualization. The perforation margins were freshened circumferentially with a fine needle. An incision was carefully made 5 mm

away from the tympanic annulus posteriorly and extended from the 12 o'clock position to the 8 o'clock position (Fig. 1A). The tympanomeatal flap was subsequently lifted, then the tympanic membrane was peeled off the malleus, which provided enough room to operate. Next the integrity and mobility of the ossicular chain were confirmed. After a 5-mm skin incision to the medial of the tragus, a composite cartilage-perichondrium graft (with only 1 side of the perichondrium remaining) was harvested. The cartilage was shaped into a strip (without thinning out), leaving cartilage only on 1 side of the perichondrium and only the perichondrium on the other side. The remaining unused cartilage after clipping was placed back to the tragus, and the tragus incision was cemented with biological glue. This was the so-called strip-type cartilage-perichondrium graft (Fig. 1C and D). Then, the graft was placed horizontally in the tympanum along the external auditory canal and positioned so that the cartilage was on the inside of the anterior tympanic ring and the perichondrium was located on the lateral side of the manubrium mallei (Fig. 1E, F). Following adjustment of the angle, the graft was gently lifted to facilitate subsequent tamponade steps (Fig. 1G). After packing of the tympanic cavity with NasoPores to prevent graft removal (Fig. 1H), the graft was repositioned and flattened in sequence to their original positions (Fig. 1I–K). The cartilage was 2 mm larger than the edge of the perforation and was placed in the anterior lower quadrant of the tympanum (Fig. 1M). Finally, the external auditory canal was packed with NasoPores. Packing in the external ear canal was removed on postoperative days 10–14. The tragal incision healed 1 week postoperatively in all patients. Patients were evaluated postoperatively in an outpatient room. A schematic illustration of our surgical technique is shown and summarized in Figures 1A–K and 2.

2.4. Statistical analyses

Statistical analyses were performed using SPSS software (version 21.0 for Windows; Inc/IBM). Continuous variables are expressed as mean \pm standard deviation, while categorical variables are presented as frequency (%). Preoperative and postoperative ACT and ABG were compared using the Wilcoxon signed-rank test. *P* values < .05 were considered indicative of statistical significance.

3. Results

3.1. Characteristics of patients

We retrospectively analyzed 23 patients (23 ears; 13 on the left and 10 on the right; 19 females and 4 males, mean age: 42.7 \pm 12.3 years) diagnosed with chronic otitis media who required unilateral TM perforation repair. All perforations were located in the anterior quadrant. There were 16 medium-size perforations (25–50% of the TM area) in our cohort, 6 of which were marginal perforations. The remainder were nonmarginal perforations and were <25% of the TM area (Table 1). The follow-up duration in our cohort ranged from 12 to 14 months (mean: 12.4 months).

3.2. Anatomic and graft uptake results

The technique proposed in this study consisted of several key steps indicated in the diagram and flow chart (Figs. 1 and 2). In skilled hands, the procedure can be completed in <15 minutes (22 of 23, not shown in the table), beginning from the extraction of the chondroperichondrial graft from the tragus to the filling of the external auditory canal. The graft placement procedure is time and labor saving. By virtue of the shape of the strip-type graft, the folded graft can be easily and quickly delivered into the ear canal at the site of

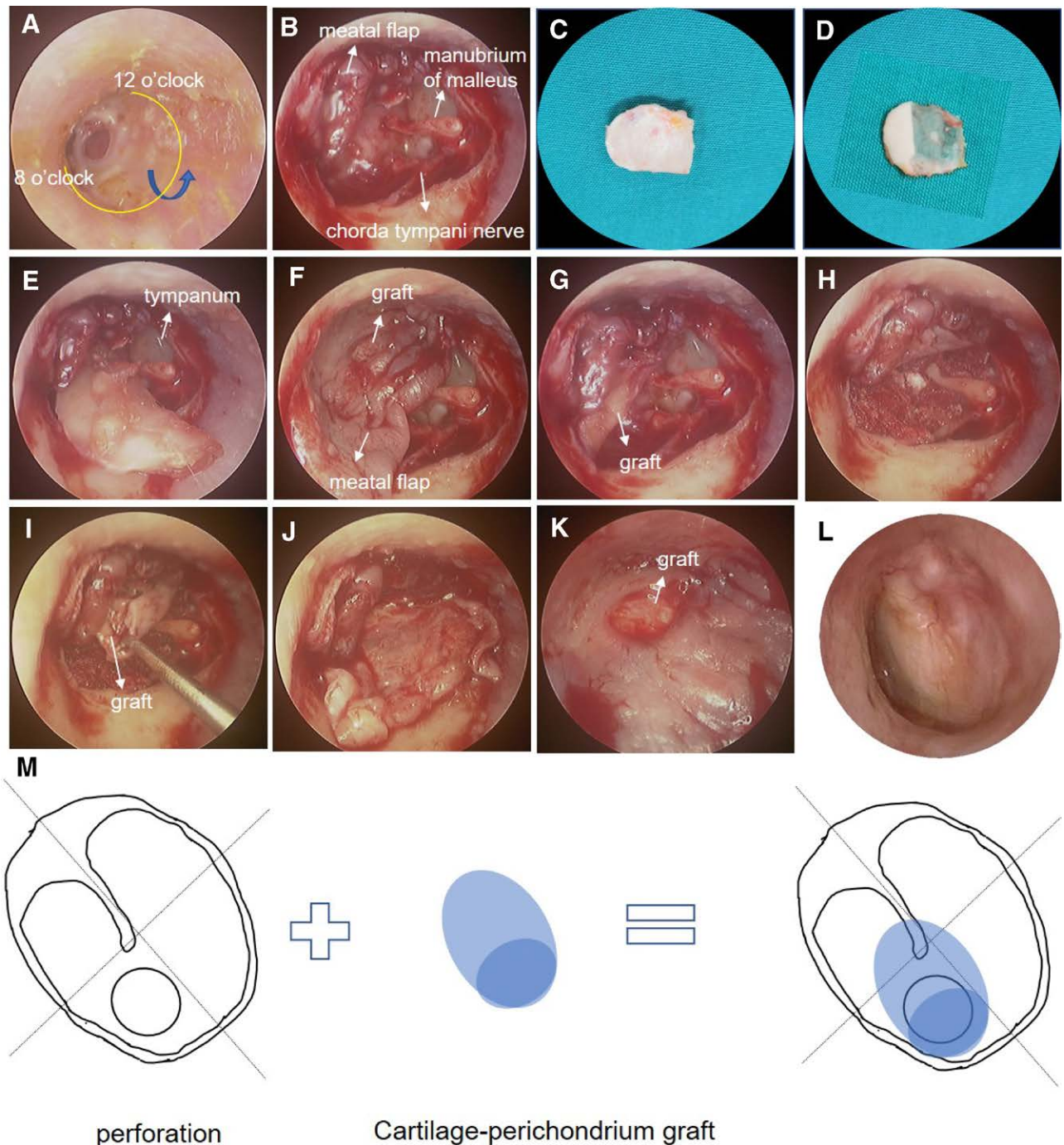


Figure 1. Succinct generalization of the operation process and results described in this study. (A) Selected anterior TM perforation from the left ear. (B) Lifting of the tympanomeatal flap. (C, D) Harvesting and shaping the graft. (E–G) Insertion and second lift before tamponade. (H–K) Repositioning and flattening of the perichondrium and tympanomeatal flaps in turn. (L) Twelve-month postoperative otoscopic view of the eardrum. (M) A schematic illustration of left ear graft insertion; the blue dark circle represents the cartilage and the light part represents the perichondrium. TM = tympanic membrane.

tympanic perforation. At the same time, the cartilage portion of the graft generally fits well in the anterior or anterior-inferior annulus. This lays a good foundation for subsequent tamponade. Anatomically, the graft success rate at the end of the first-month follow-up period was 86.96% (20/23) (Table 2). One patient with a medium-sized marginally located perforation had a small crevice located near the anteroinferior margin of the TM, which may have been caused by graft shifting and lateralization. We used gelatin sponge-infiltrating antibiotics to press on the surface of the crevice for 1 week and prescribed oral antibiotics. Two patients developed mild

otorrhea, which resolved following the application of topical ofloxacin otic solution and oral antibiotics. No reperforation occurred in these 3 patients during the subsequent follow-up period. Nearly normal vascularization and epithelialization occurred approximately 4 to 6 months postoperatively. At 6 and 12 months, the anatomical graft success rate was 100% (Table 1; Fig. 1). No cases of cholesteatoma, middle-ear infection, significant graft medialization, retraction, or perforation were observed as of the most recent follow-up. No major complications, such as sensorineural hearing loss, allotropicgia, or facial paralysis were observed during the follow-up.

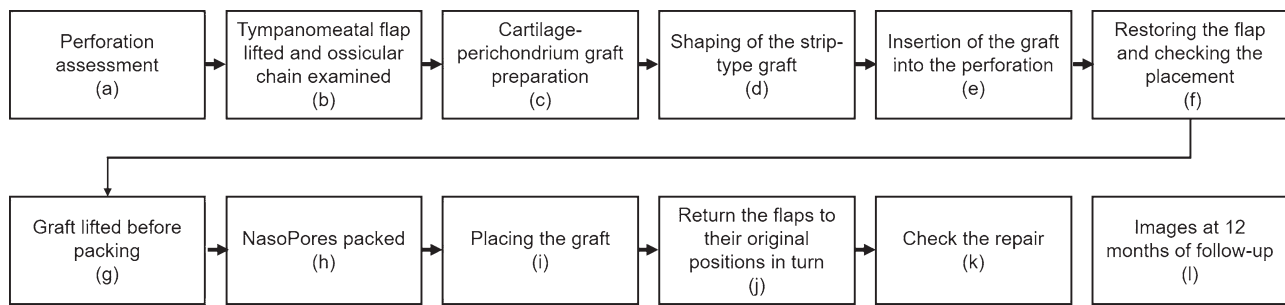


Figure 2. Flow chart showing the sequential steps of TM anterior perforation repair using strip-type cartilage-perichondrium grafts. (A–K) correspond to (A–K) in Figure 1, representing the normalized 11 steps of our technique for anterior TM perforation. TM = tympanic membrane.

Table 1

Patients information.

Male/female	Age	Left/right ear	Location of perforation	Size of perforations	Marginal perforation (Yes/No)
F	39	L	Anterior-superior	Medium	N
F	49	R	Anterior-inferior	Medium	N
F	25	R	Anterior-superior	Medium	N
F	31	L	Anterior-inferior	Medium	Y
M	51	L	Anterior-superior	Medium	N
F	21	L	Anterior-inferior	Small	N
F	50	L	Anterior-inferior	Medium	N
M	36	L	Anterior-superior	Medium	N
F	54	R	Anterior-inferior	Small	N
F	31	L	Anterior-inferior	Small	N
F	41	R	Anterior-inferior	Small	N
M	32	L	Anterior-inferior	Medium	Y
F	32	L	Anterior-inferior	Small	N
F	70	R	Anterior-superior	Medium	Y
F	56	L	Anterior-superior	Small	N
F	55	R	Anterior-inferior	Medium	N
F	58	R	Anterior-inferior	Medium	N
F	53	L	Anterior-superior	Small	N
M	46	L	Anterior-inferior	Medium	N
F	46	R	Anterior-inferior	Medium	Y
F	40	R	Anterior-inferior	Medium	Y
F	28	L	Anterior-inferior	Medium	Y
F	38	R	Anterior-superior	Medium	N

3.3. Auditory results

The auditory results were recorded at postoperative 12 months (Table 1). The mean postoperative ACT (33.52 ± 10.88 dB) was significantly lower than the mean preoperative ACT (44.7 ± 13.56 ; $P < .0001$). The mean postoperative ABG (12.52 ± 3.94 dB) was also significantly lower than the mean preoperative ABG (22.35 ± 6.54 dB; $P < .0001$) (Table 1; Fig. 3A). Preoperative ABG of at least 20 dB was found in 16 (69.57%) patients, while this number decreased to 1 (4.35%) patient postoperatively. Most patients (73.91%) achieved an ABG between 10 and 20 dB postoperatively, and 5 patients (21.74%) had an ABG <10 dB, which approximated the standard level for normal persons (Table 1; Fig. 3B). Altogether, 22 (95.65%) patients had an ABG below 20 dB. The mean improvement in ABG was 9.83 ± 5.00 dB. Of the 23 patients, 11 (47.83%) achieved an ABG closure of 10 to 19 dB, equal to the number of patients with an ABG closure of 0 to 9 dB, and 1 (4.25%) patient had an ABG closure of at least 20 dB. In summary, according to the graft success criteria mentioned above, the functional graft success rate reached 95.65% (1 patient had a postoperative ABG of >20 dB) (Table 1).

4. Discussion

A number of studies have documented high success rate of tympanoplasty. Özdamar et al^[8] enrolled 151 patients who

underwent transcanal endoscopic tympanoplasty. They reported cartilage fascia graft retention rate of 94.9% with an average postoperative hearing of 10.59 ± 4.47 dB; graft retention rate with fascia of the temporal muscle was 97.2% with an average postoperative hearing of 7.44 ± 6.11 dB. Hsu et al^[9] reported similar success rates >90% achieved with use of temporalis fascia for repair of TM perforation under the microscope and the endoscope. Huang et al^[10] performed a systematic review of outcomes of butterfly cartilage tympanoplasty. The reported closure rates ranged from 80% to 94% (median 91%), similar to that achieved with temporal fascia tympanoplasty and cartilage tympanoplasty, but higher than that achieved with fat graft myringoplasty. All groups showed improved auditory function suggesting similar hearing gains from these approaches. Tan et al^[11] conducted a larger meta-analysis of 214 studies (combined $n = 26,097$). The mean closure rate was 86.6% (range 46.8–100%) and the outcomes were not significantly different between different surgical approaches or techniques. However, soft grafts are not recommended in difficult settings such as atelectasis, revision surgeries, and anterior or large perforations, owing to the higher risk of graft resorption or retraction. The properties of rigidity and resistance from retraction make cartilage a better choice for myringoplasty in challenging situations. Mohanty et al^[12] reported better graft success rate and ABG closure ratio with use of cartilage graft compared with use of

Table 2
Auditory results and graft success rates.

	Preoperation	Postoperation	P value
ACT (Mean ± SD; dB)	44.7 ± 13.56	33.52 ± 10.88	<.0001*
ABG (Mean ± SD; dB)	22.35 ± 6.54	12.52 ± 3.94	<.0001*
ABG ≥ 20 dB	16/23 (69.57%)	1/23 (4.35%)	
ABG < 20 dB	7/23 (30.34%)	22/23 (95.65%)	
10 ≤ ABG < 20 dB	7/23 (30.43%)	17/23 (73.91%)	
ABG < 10 dB	None	5/23 (21.74%)	
ABG closure (Mean ± SD; dB)		9.83 ± 5.00	
ABG closure ≥ 20 dB		1/23 (4.35%)	
10 ≤ ABG closure < 20 dB		11/23 (47.83%)	
0 < ABG closure < 10 dB		11/23 (47.83%)	
Graft success rate (1 month)†		20/23 (86.96%)	
Graft success rate (6 and 12 months)†		100%	
Total success rate‡		22/23 (95.65%)	
Complications		None	

* Wilcoxon signed-rank test.

† and

‡ represent anatomical and functional graft success, respectively.

ACT, air conduction threshold; ABG, air-bone gap; SD, standard deviation

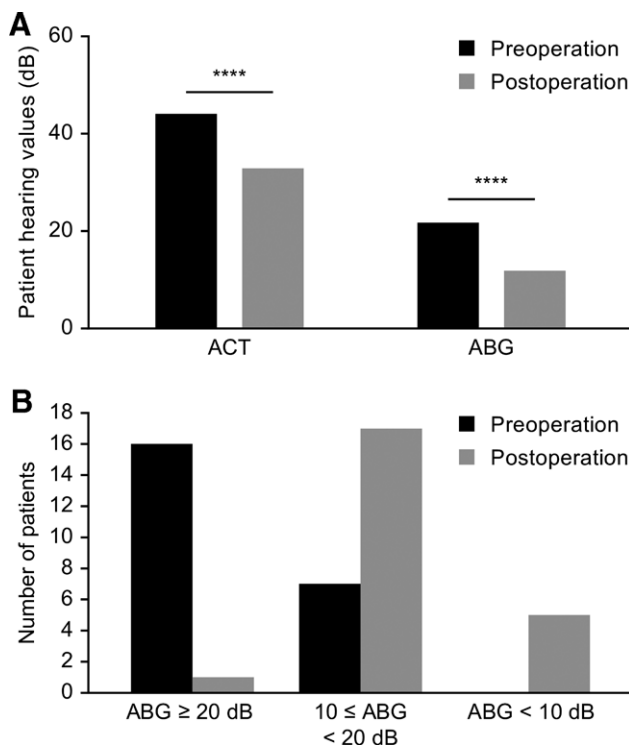


Figure 3. Pre- and postoperative hearing function. (A) Comparisons of the ACT and ABG pre- and postoperation, *****P* < .0001 using the Wilcoxon signed-rank test. (B) Pre- and postoperative distribution of the ABG. Values were obtained according to the PTA results. ABG = air-bone gap, ACT = air conduction threshold, PTA = pure-tone audiometry.

fascial graft. In the study by Fermi et al,^[13] the graft material was found to be the main determinant of the outcomes of endoscopic perforation repair; the use of hard grafts (cartilage or cartilage-perichondrium composite) was found more protective than soft grafts (fascia and perichondrium) alone, with an overall success rate of 91.2%. In a meta-analysis by Tan et al,^[11] use of cartilage increased the closure rate by 2.8% compared with fascia. We obtained similar or even better results, with a 100% graft success rate in the present study.

Of late, many techniques with use of modified cartilage grafts have been described. Of these, tragal cartilage-perichondrium composites with the perichondrium attached to 1 side, retaining

both the hardness of cartilage and ductility of the perichondrium, have become a popular source of grafts. Researchers have focused on the thickness of grafts because the thickness of the chondroperichondrial graft itself is different from that of the normal eardrum. They found that thinning or thickening of cartilage grafts did not prolong the operation or increased the technical difficulties; however, this did not lead to actual hearing gain or improved the success rate.^[7] Therefore, in this study, we did not manipulate the thickness of the graft but directly removed most of the cartilage, leaving only the anterior strip-type structure. The results showed that our modification not only reduced the time for required graft shaping but also ensured postoperative hearing improvement and improved the graft success rate.

Tos^[14] classified cartilage techniques for tympanoplasties into 6 groups that can be categorized into 2 main techniques: the palisade technique and island graft technique. Fernandes^[5] and Ahmed et al^[15] introduced the “triple C” technique, which resulted in 100% and 91.3% graft success rates, respectively. Genc^[6] described the perichondrium-preserved palisade island graft technique for tympanoplasty with a 93.61% success rate, while Larrosa et al^[17] found no obvious difference in hearing or graft take results obtained with the palisade cartilage graft technique compared to the endoscopic chondroperichondrial graft technique. Despite the ideal results provided by the palisade technique and island graft, these grafts are nontransparent, which makes it difficult to examine the middle-ear postoperatively. Mansour et al^[18] introduced the ring graft with the absence of cartilage at its center, and achieved complete closure of the perforations in all cases (18 cases), including anterior perforations. Dundar et al^[19] described a new graft called as boomerang-shaped chondroperichondrial graft, which left a boomerang-shaped cartilage island at the anterior and inferior parts of the graft and obtained ideal surgical results. Several other methods of cartilage modification have been used, such as butterfly cartilage, suspended cartilage, and palisade cartilage. Butterfly cartilage technique has been widely used with good success rate. However, in our clinical practice, patients with large perforations complained of occasional ear tightness and discomfort in the postoperative period. Lou^[20] found the suspended cartilage overlay technique was useful, as it reconstructed the central tympanic membrane perforation without elevation of the tympanomeatal flap. However, this presented a great challenge for graft fixation. The palisade cartilage modification entails retention of strip-shaped cartilages to provide better support. However, the placement of multiple strips of palisade cartilage increases the operation time and presents some difficulty for fixation. The strip-type chondroperichondrial graft used in the present study not only provides good support but also better fixation; it is suitable for both anterior perforations as well as for large and central perforations.

None of the studies mentioned above used the same surgical technique described herein. Compared with the strip-type grafts discussed herein, the time required for soft grafts is longer, and the technique is less cost effective because these grafts need to be harvested from the temporalis area and have to be dried prior to their placement; scar formation and postoperative care are also disadvantages of soft grafts. In contrast to the palisade island or ring graft technique, we trimmed the cartilage to leave only a strip shape on 1 side of the graft, leaving the original perichondrium. This step was performed easily, was timesaving, and did not warrant concerns of damaging the adjacent perichondrium during cutting of the cartilage. In contrast to boomerang-shaped grafts, strip-shaped grafts are foldable and can be clamped easily when deployed at the site of perforation from the external ear canal. In terms of the postoperative results, 3 patients did not achieve anatomically complete closure of the TM perforation at the 1-month follow-up. One patient had a small residual perforation that was completely repaired after treatment and did not require reoperation. At 12-month follow-up, no cases of

failure were observed in our study, which is similar to the results obtained with the “triple C” and “ring graft” techniques. Among patients treated with boomerang-shaped graft technique, there were 7 graft perforations and 4 graft retractions at the end of the 12-month follow-up.^[19] Our technique also ensures ideal hearing improvement for patients. Except for 1 patient who did not gain an ABG below 20 dB, all others achieved functional repair success (95.65%). The mean postoperative ABG was significantly lesser than the mean preoperative ABG, which is consistent with the outcomes achieved with the boomerang-shaped technique.

Anterior perforations are considered challenging for repair because of the difficulties associated with poor visualization, reduced vascularity, and graft instability. Visvanathan et al^[21] summarized 4 techniques for repair of anterior tympanic membrane perforation, that is, anterior anchoring techniques, lateral graft tympanoplasty, techniques for large and subtotal perforations, and endoscopic transcanal techniques. Use of an operating microscope for repair of anterior perforation is often hindered by the anterior wall of the external canal, which prevents adequate visualization of the anterior margin.^[21] Endoscopic ear surgery (ESS) has become increasingly popular in the past 2 decades owing to the distinct leverage offered by wider visual access to the whole margin of the perforation and better depth perception, which helps improve surgical outcomes. Gülşen and Arici^[22] concluded that the endoscopic tympanoplasty technique offers great advantage over the microscopic technique with respect to better graft success rate, shorter duration of surgery, and fewer operative complications. Although different endoscopic tympanoplasty techniques, such as the butterfly, push-through, perichondrium-reinforced cartilage, and composite cartilage-perichondrium island techniques, offer advantages for anterior perforation closure, none of these surgical methods is perfect. In the butterfly-inlay or push-through technique, the tympanomeatal flap is not raised, which hinders the assessment of the ossicular status; in addition, insertion and fixation of the graft is very difficult for perforations smaller than 5 mm. Push-through technique is more appropriate for patients with large perforation and spacious external auditory canal. The critical aspects during graft placement include adjustment of the angle to make the graft fit perfectly with the annulus and flattening of the anterior skirt edges from the remnant of the perforation to allow optimal positioning of the graft; after placement of the graft, it needs to be lifted again for tympanic tamponade. Regardless of the type of graft (soft or hard graft), coiling and crimping are difficult to avoid during graft placement, resulting in time-consuming repeated graft adjustment; moreover, graft displacement, floatation, or poor placement may lead to TM repair failure. Use of an operating microscope allows for better stability than endoscopic repair as the former technique allows the surgeon to use both hands. Few of the studies mentioned above focused on the techniques to simplify the graft insertion and placement process. In the present study, we focused on the process from graft shaping to placement; in particular, we described the technique to insert the graft in a folded form and how to pull the graft back into placed position from folded form safely and handily (Fig. 1). First, the tympanomeatal flap was lifted in the routine manner. Second, owing to the strip-type graft, the folded graft easily passed through the narrow external auditory canal. The anterior cartilaginous part can not only act as a pivot anchored across the anterior perforated area, which is convenient for the second tympanic tamponade lift, but also provides better support to resist retraction. It also facilitates the repositioning of the perichondrium after tamponade. In our cohort, excluding the time required to lift the tympanomeatal flap, the time required from graft harvesting to completion of tamponade was <15 minutes; this was approximately half the time required in the “triple C” tympanoplasty

procedure in previous studies.^[15] The series of modified techniques allowed the surgeon to accomplish all placement procedures and ensured satisfactory postoperative outcomes similar to those obtained in other studies.

Some limitations of our study should be acknowledged. First, the relatively small sample size limits the generalizability of our findings. Second, this was a retrospective study with all its inherent limitations. A larger multicenter prospective study will provide more definitive evidence. Although we reached a 100% anatomic graft success rate, this may be due to the careful selection criteria used.

In summary, in this study, we not only employed strip-type chondroperichondrial grafts to repair anterior TM perforations under endoscopy in selected patients but also simplified the graft insertion and placement process. The approach is easy to operate, reliable, time and labor saving, and therefore highly recommendable.

Authors' contributions

AL, ZL, JC, and XG designed the study. JC performed the surgeries. YY and HC were responsible for the otoscopic and auditory tests of patients during the study. ZL and YX collected the information of patients. AL performed statistical analyses. AL and ZL drafted the article and contributed equally to this work. All authors revised the article and approved submission.

References

- [1] Hay A, Blanshard J. The anterior interlay myringoplasty: outcome and hearing results in anterior and subtotal tympanic membrane perforations. *Otol Neurotol*. 2014;35:1569–76.
- [2] Chmielik LP, Ziolkowski J, Koziolok R, et al. Ear tuberculosis: clinical and surgical treatment. *Int J Pediatr Otorhinolaryngol*. 2008;72:271–4.
- [3] Wullstein HL. Funktionelle operationen im mittelohr mit hilfe des freien spaltlappen-transplantates. *Arch Otorhinolaryngol*. 1952;161:422–35.
- [4] Zollner F. The principles of plastic surgery of the sound-conducting apparatus. *J Laryngol Otol*. 1955;69:637–52.
- [5] Fernandes SV. Composite chondroperichondrial clip tympanoplasty: the triple “C” technique. *Otolaryngol Head Neck Surg*. 2003;128:267–72.
- [6] Tseng CC, Lai MT, Wu CC, et al. Endoscopic transcanal myringoplasty for anterior perforations of the tympanic membrane. *JAMA Otolaryngol Head Neck Surg*. 2016;142:1088–93.
- [7] Shakya D, Nepal A. Total endoscopic perichondrium reinforced cartilage myringoplasty for anterior perforation. *Ear Nose Throat J*. 2022;101:158–64.
- [8] Ozdamar K, Sen A. Comparison of the anatomical and functional success of fascia and perichondrium grafts in transcanal endoscopic type I tympanoplasty. *J Otolaryngol Head Neck Surg*. 2019;48:67.
- [9] Hsu YC, Kuo CL, Huang TC. A retrospective comparative study of endoscopic and microscopic tympanoplasty. *J Otolaryngol Head Neck Surg*. 2018;47:44.
- [10] Huang J, Teh BM, Shen Y. Butterfly cartilage tympanoplasty as an alternative to conventional surgery for tympanic membrane perforations: a systematic review and meta-analysis [published online ahead of print May 31, 2021]. *Ear Nose Throat J*. doi: 10.1177/01455613211015439.
- [11] Tan HE, Santa Maria PL, Eikelboom RH, et al. Type I tympanoplasty meta-analysis: a single variable analysis. *Otol Neurotol*. 2016;37:838–46.
- [12] Mohanty S, Manimaran V, Umamaheswaran P, et al. Endoscopic cartilage versus temporalis fascia grafting for anterior quadrant tympanic perforations - a prospective study in a tertiary care hospital. *Auris Nasus Larynx*. 2018;45:936–42.
- [13] Fermi M, Maccarrone F, Villari D, et al. Endoscopic tympanoplasty type I for tympanic perforations: analysis of prognostic factors. *Eur Arch Otorhinolaryngol*. 2021; 278:4715–22.
- [14] Tos M. Cartilage tympanoplasty methods: proposal of a classification. *Otolaryngol Head Neck Surg*. 2008;139:747–58.
- [15] Ahmed S, Raza N, Ullah S, et al. Chondroperichondrial clip myringoplasty: a new technique for closure of tympanic membrane perforations. *J Laryngol Otol*. 2013;127:562–7.

- [16] Genc SA. different cartilage graft technique: perichondrium-preserved palisade island graft in tympanoplasty. *J Craniofac Surg.* 2016;27:e166–70.
- [17] Larrosa F, de Osso JT, Dura MJ, et al. Palisade cartilage tympanoplasty compared to one-piece composite cartilage-perichondrium grafts for transcanal endoscopic treatment of subtotal tympanic membrane perforations: a retrospective study. *Eur Arch Otorhinolaryngol.* 2020;277:1955–9.
- [18] Mansour MH, Askar MH, Albirmawy OA. Repair of tympanic membrane perforation using a modified cartilage-perichondrium composite ring graft. *J Laryngol Otol.* 2006;120:952–4.
- [19] Dundar R, Soy FK, Kulduk E, et al. A new grafting technique for tympanoplasty: tympanoplasty with a boomerang-shaped chondroperichondrial graft (TwBSCPG). *Eur Arch Otorhinolaryngol.* 2014;271:2687–94.
- [20] Lou Z. Endoscopic suspended cartilage myringoplasty for the repair of central tympanic membrane perforation. *Ear Nose Throat J.* 2021;100(5_suppl):816s–21s.
- [21] Visvanathan V, Vallamkondu V, Bhimrao SK. Achieving a successful closure of an anterior tympanic membrane perforation: evidence-based systematic review. *Otolaryngol Head Neck Surg.* 2018;158:1011–5.
- [22] Gulsen S, Arici M. Endoscopic transcanal versus conventional microscopic tympanoplasty in treatment of anterior tympanic membrane perforations. *Eur Arch Otorhinolaryngol.* 2019;276:3327–33.