



Contents lists available at ScienceDirect

International Journal of Surgery Case Reports

journal homepage: www.casereports.com

Broad ligament pregnancy in the presence of an intrauterine contraceptive device: A case report

Samaneh Rokhgireh^a, Mansoureh Gorginzadeh^a, Abolfazl Mehdizadehkashi^a, Kobra Tahermanesh^a, Shima Alizadeh^{b,*}

^a Endometriosis Research Center, Iran University of Medical Sciences (IUMS), Tehran, Iran

^b Department of Obstetrics & Gynecology, Emam Complex, Vali-e-Asr Hospital, Tehran University of Medical Science (TUMS), Tehran, Iran

ARTICLE INFO

Article history:

Received 1 January 2021

Received in revised form 15 January 2021

Accepted 15 January 2021

Keywords:

Broad ligament

Case report

Ectopic pregnancy

Intrauterine device

Laparoscopy

ABSTRACT

INTRODUCTION: Abdominal pregnancy though scarce is associated with considerable morbidity and mortality. Few cases till now have been diagnosed or managed by laparoscopy.

CASE PRESENTATION: In this study, a case of an abdominal pregnancy in a woman with intrauterine contraceptive device (IUD) in situ and a history of cesarean section is described.

CLINICAL DISCUSSION: Our case was a brief description of a broad ligament pregnancy as a subcategory of abdominal pregnancy. It was located medial to the pelvic sidewall, lateral to the uterus, inferior to the fallopian tube and superior to the pelvic floor.

CONCLUSION: The pregnancy was in the location of the left broad ligament which was diagnosed on laparoscopic evaluation.

© 2021 The Author(s). Published by Elsevier Ltd on behalf of IJS Publishing Group Ltd. This is an open access article under the CC BY-NC-ND license (<http://creativecommons.org/licenses/by-nc-nd/4.0/>).

1. Introduction

Implantation of a blastocyst anywhere other than the endometrium of the uterine cavity is defined as ectopic pregnancy (EP) [1]. Despite its low incidence, high maternal morbidity and mortality due to hemorrhage has categorized it as an obstetrical emergency [1,2]. Regarding tubal pregnancies, in a woman with abnormal uterine bleeding or abdominal pain and positive pregnancy test, ultrasound often offers the accurate diagnosis [1,2]. With regards to non-tubal pregnancies, however, the diagnosis is more challenging [3]. Abdominal pregnancy as a form of non-tubal EP, constitutes a small percentage (less than 2%) of all EPs [4,5]. Abdominal EP could be developed either through primary implantation of a fertilized ovum on the peritoneal surfaces or via secondary attachment of the blastocyst following tubal abortion or rupture [3,6]. Pelvic sidewall, broad ligament and large pelvic vessels are all among the probable locations of abnormal implantation [6,7]. There are only a few studies in the literature concerning laparoscopic diagnosis and management of abdominal pregnancy. Here, we present a case of an early broad ligament pregnancy diagnosed and successfully managed by laparoscopy. This case report has been reported in line with the improved SCARE checklist. The SCARE Guidelines were published in 2020 [8].

2. Case description

A 27-year-old Gravida 2 para 1 woman with no medical, allergy history and drug use referred to the emergency ward of Obstetrics and gynecologic of university-based Hospital. Her chief complaints were vaginal bleeding and abdominal pain. She had a cesarean section for twin pregnancy 7 years ago and inserted a copper T IUD since then. On arrival, her initial vital signs were normal. On detailed examination, slight vaginal bleeding was noted and IUD string could be seen in the usual place. Bimanual pelvic examination was normal, except for mild tenderness in the left adnexal area. Due to her positive pregnancy test and persistent pain she was admitted and IUD was removed. Based on her last menstrual period (LMP), she was estimated to be in 5th weeks of gestation. On transvaginal sonography, uterus size was 90 × 55 × 50 mm with endometrial thickness of 10 mm. No evidence of gestational sac could be seen in the endometrial cavity. Both ovaries had normal size. However, a mass of 29 × 20 mm size with vascularity was detected in the left adnexal region which was tender on probe pressure. Her human chorionic gonadotropin (HCG) titer of 18059 IU/L strongly suggested an EP probably of tubal origin. Hence, she was scheduled for laparoscopic surgery. Laparoscopy was done by two fellows of minimally invasive gynecologic surgery under the direct supervision of their attending surgeon. On initial inspection, uterus was larger than normal. There was a thick fibrotic band from the fundal to cervical region which was densely adhered to the anterior abdominal wall. Both ovaries and fallopian tubes appeared normal. Approximately 50–60 ml of blood was suctioned from the poste-

* Corresponding author.

E-mail address: Alizadeh.shima@gmail.com (S. Alizadeh).

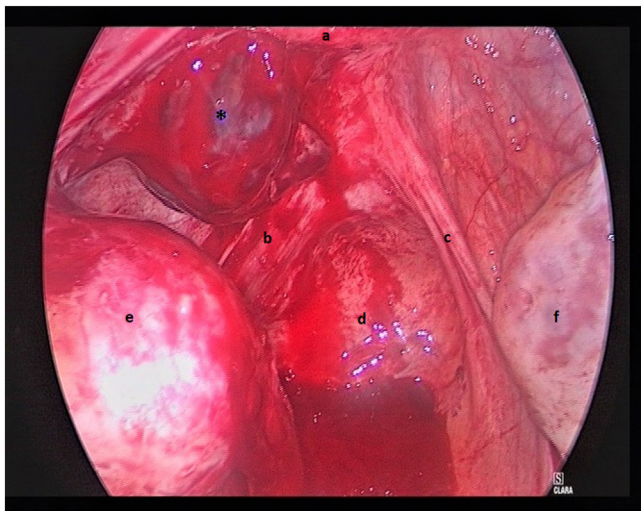


Fig. 1. Laparoscopic view of ectopic pregnancy (posterior view).

*Trophoblastic tissue.

- a: Uterus.
- b: Left uterosacral ligament.
- c: Right uterosacral ligament.
- d: Posterior cul-de-sac.
- e: Left ovary.
- f: Right ovary.

rior cul-de-sac. On more detailed inspection, a hemorrhagic lesion lateral to the left uterine artery with active bleeding was observed. It was about 4–5 cm in size consisting mainly of trophoblastic tissue and clot which located lateral to the left uterosacral ligament (Fig. 1). Due to the vicinity of the ureter, first, ureteral dissection was performed. After adhesiolysis and lateralizing the left ureter, most of the lesion was resected and sent for pathologic evaluation. The remaining area was cauterized and SURGICEL® powder (Ethicon, Johnson & Johnson Medical Devices Companies, USA) was applied for better hemostasis. There were also some endometriotic lesions on the right uterosacral ligament which were ablated. Given the high titer of HCG which was suspicious for gestational trophoblastic disease, the patient was given an intramuscular injection of 60 mg methotrexate (MTX) following surgery. After two days, HCG titer decreased to 5096 IU/L and ultrasound revealed no abnormality. Subsequently, our patient was discharged and was weekly followed by HCG titer until it was undetectable in blood. Histologic assessment confirmed conceptional products without any cellular invasion.

3. Discussion

Non-tubal and in particular abdominal EP is exceedingly rare [5]. Our case was a brief description of a broad ligament pregnancy as a subcategory of abdominal pregnancy. This diagnosis was based on its definition with regards to anatomic location of EP. As for our case, the broad ligament pregnancy is located somewhere medial to the pelvic sidewall, lateral to the uterus, inferior to the fallopian tube and superior to the pelvic floor [5]. Regarding the common risk factors for EP, she had at least two predisposing factors, her past cesarean surgery and IUD usage. Although intrauterine contraceptive devices (IUD)s are effective in prevention of both intrauterine and extrauterine pregnancies, in case of failure, the risk of EP is elevated [1,9]. Among different methods of contraception, history of IUD insertion has been associated with increased risk of EP which is also positively correlated with the years of usage [2]. This is believed to be the result of inflammation caused in the pelvic region [2]. The EP in our case could have resulted from tubal abortion or from migration of the blastocyst via a fistulous tract in the fal-

lopian tube or the uterine wall. Also, according to a similar study by Kutlešić et al., a false route could have been developed as a result of incomplete uterine healing following cesarean section through which the embryo could have passed [10]. The presence of dense adhesions at the site of cesarean scar was already indicative of poor healing process. What should be considered in surgical management of abdominal EP is the possibility of heavy intraoperative bleeding especially when serum HCG levels are more than expected [10]. For our patient, blood reserve had been done and the possibility of conversion of surgery to laparotomy had been explained to her beforehand. Moreover, anesthesia team were fully informed and other attending surgeons were requested to be available in case of massive bleeding. Various methods have been suggested for controlling the bleeding of EP site including injection of vasopressin, applying electro surgery or temporary ligation of hypogastric artery [7,10,11]. For the present case, the ectopic tissue was resected using harmonic scalpel (Harmonic ACE; Ethicon, Somerville, NJ) and the remaining oozing points were controlled by using SURGICEL® powder. Another key point in managing abdominal EP is the proximity of these lesions to the vital organs like major blood vessels or ureter as for our case [11]. Laparoscopy as a mode of minimally invasive surgery with desirable magnification helped us for complete and delicate ureteral dissection and separation of the gestational products from adjacent tissues. Since 200 years ago when the first abdominal pregnancy was reported, several case reports have been published, but most of them were managed by open surgery rather than laparoscopy [5,11]. Early detection of abdominal EP, therefore, is crucial in order to be able employ less invasive surgical methods [11]. For those who have no intention to have children, bilateral salpingectomy is recommended to reduce both the risk of EP recurrence and ovarian malignancy [1,2,11]. This procedure was not carried out for this patient given her desire to become pregnant. Any discussion on this case would be incomplete without commenting on the ethical aspects of the consent process. Her mother played an important part in the decision-making process. Finally, she was agreed to a minimally invasive procedure. In the end she was thankful to the doctors and medical staff, she declared that she would be happy the other doctors and medical students learn from the case and didn't mind her condition being discussed.

4. Conclusion

Although broad ligament pregnancy is an unusual and uncommon form of EP, it should be reflected on whenever abnormal pregnancy especially with high HCG titers is encountered or some particular risk factors like previous surgeries and prolonged IUD usage have been accompanied. With early detection, it could be safely and effectively managed by minimally invasive methods. In conclusion what this study adds to the literature apart from describing a rare condition is that even when we are encountered with non-tubal types of ectopic pregnancy like broad ligament pregnancy, minimally invasive surgical methods could be safely applied in proper management of these cases.

Funding

There are currently no funding sources.

Ethical approval

The clinical case is exempt from ethical approval

Consent

Written informed consent was obtained from the patient for publication of this case report and accompanying images. A copy of the written consent is available for review by the Editor-in-Chief of this journal on request

Author contribution

Rokhgireh S: study concept or design, data collection, performed the surgery. Gorginzadeh M: Investigation, Writing - Original Draft, performed the surgery. Mehdizadehkashi A: Supervision, In Validation. Tahermanesh K: analysis and interpretation of data. Alizadeh SH: Writing - Review & Editing; critical revision and approved the final version.

Registration of research studies

Not Applicable.

Guarantor

Dr, Mansoureh Gorginzadeh.

Provenance and peer review

Not commissioned, externally peer reviewed.

CRediT authorship contribution statement

Samaneh Rokhgireh: Conceptualization, Data curation. **Mansoureh Gorginzadeh:** Project administration, Investigation, Writing - original draft. **Abolfazl Mehdizadehkashi:** Supervision, Validation. **Kobra Tahermanesh:** Resources, Software. **Shima Alizadeh:** Investigation, Writing - review & editing.

Declaration of Competing Interest

The authors report no declarations of interest.

References

- [1] C. Li, W.H. Zhao, Q. Zhu, S.J. Cao, H. Ping, X. Xi, G.J. Qin, M.X. Yan, D. Zhang, J. Qiu, J. Zhang, Risk factors for ectopic pregnancy: a multi-center case-control study, *BMC Pregnancy Childbirth* 15 (December (1)) (2015) 187.
- [2] C. Li, W.H. Zhao, C.X. Meng, H. Ping, G.J. Qin, S.J. Cao, X. Xi, Q. Zhu, X.C. Li, J. Zhang, Contraceptive use and the risk of ectopic pregnancy: a multi-center case-control study, *PLoS One* 9 (December (12)) (2014), e115031.
- [3] A.V. Dolinko, R.A. Vrees, G.N. Frishman, Non-tubal ectopic pregnancies: overview and treatment via local injection, *J. Minim. Invasive Gynecol.* 25 (February (2)) (2018) 287–296.
- [4] H.K. Atrash, A. Friede, C.J. Hogue, Abdominal pregnancy in the United States: frequency and maternal mortality, *Obstet. Gynecol.* 69 (March (3 Pt 1)) (1987) 333–337.
- [5] A. Poole, D. Haas, E.F. Magann, Early abdominal ectopic pregnancies: a systematic review of the literature, *Gynecol. Obstet. Invest.* 74 (4) (2012) 249–260.
- [6] R.W. Dover, M.C. Powell, Management of a primary abdominal pregnancy, *Am. J. Obstet. Gynecol.* 172 (May (5)) (1995) 1603–1604.
- [7] S.W. Shaw, J.J. Hsu, H.Y. Chueh, C.M. Han, F.C. Chen, Y.L. Chang, A.S. Chao, P.J. Cheng, T.S. Hsieh, Y.K. Soong, Management of primary abdominal pregnancy: twelve years of experience in a medical centre, *Acta Obstet. Gynecol. Scand.* 86 (September (9)) (2007) 1058–1062.
- [8] R.A. Agha, T. Franchi, C. Sohrabi, G. Mathew, for the SCARE Group, The SCARE 2020 guideline: updating consensus surgical CAse REport (SCARE) guidelines, *Int. J. Surg.* 84 (2020) 226–230.
- [9] X. Xiong, P. Buekens, E. Wollast, IUD use and the risk of ectopic pregnancy: a meta-analysis of case-control studies, *Contraception* 52 (July (1)) (1995) 23–34.
- [10] R.M. Kutlešić, B. Lukić, M.S. Kutlešić, J. Popović, M. Stefanović, P. Vukomanović, G. Lilić, Unruptured retroperitoneal pregnancy implanted in the left broad ligament: a case report, *Vojnosanitetski pregled* 74 (2) (2017) 177–183.
- [11] M. Yang, L. Cidan, D. Zhang, Retroperitoneal ectopic pregnancy: a case report and review of the literature, *BMC Pregnancy Childbirth* 17 (December (1)) (2017) 358.

Open Access

This article is published Open Access at [sciencedirect.com](https://www.sciencedirect.com). It is distributed under the [IJSCR Supplemental terms and conditions](#), which permits unrestricted non commercial use, distribution, and reproduction in any medium, provided the original authors and source are credited.